Clinical Trial/Experimental Study

Medicine®

OPEN

Different *RET* gene mutation-induced multiple endocrine neoplasia type 2A in 3 Chinese families

Qiuli Liu, MD[a], Dali Tong, MD, PhD[a], Wenqiang Yuan, MD[a], Gaolei Liu, MD[a], Gang Yuan, MD[a], Weihua Lan, MD, PhD[a], Dianzheng Zhang, PhD[b], Jun Zhang, MD, PhD[a], Zaoming Huang, MD[a], Yao Zhang, MD, PhD[a], Jun Jiang, MD, PhD[a,*]

Abstract

Backgroud: Multiple endocrine neoplasia type 2A (MEN2A) is a condition with inherited autosomal dominant mutations in *RET* (rearranged during transfection) gene that predisposes the carrier to extremely high risk of medullary thyroid cancer (MTC) and other MEN2A-associated tumors such as parathyroid cancer and/or pheochromocytoma. Little is reported about MEN2A syndrome in the Chinese population.

Methods: All members of the 3 families along with specific probands of MEN2A were analyzed for their clinical, laboratory, and genetic characteristics. Exome sequencing was performed on the 3 probands, and specific mutation in *RET* was further screened on each of the family members.

Results: Different mutations in the *RET* gene were identified: C634S in Family 1, C611Y in Family 2, and C634Y in Family 3. Proband 1 mainly showed pheochromocytoma with MTC, both medullary thyroid carcinoma and pheochromocytoma were seen in proband 2, and proband 3 showed medullary thyroid carcinoma.

Conclusion: The genetic evaluation is strongly recommended for patients with a positive family history, early onset of age, or multiple sites of masses. If the results verified the mutations of *RET* gene, thyroidectomy should be undertaken as the guide for better prognosis.

Abbreviations: ALD = aldosterone, CEA = carcinoembryonic antigen, CT = computed tomography, FMTC = familial medullary thyroid carcinoma, GFRa = GDNF-family receptor alpha, H&E = hematoxylin and eosin, MAX = MYC associated factor X, MEN2A = multiple endocrine neoplasia type 2A, MN = noradrenaline, MTC = medullary thyroid cancer, NF1 = neurofibromin 1, PCT-1 = procalcitonin, PTH = parathyroid hormone, RET = rearranged during transfection, SDHAF2 = succinate dehydrogenase complex assembly factor 2, SDHB = succinate dehydrogenase subunit B, SDHC = succinate dehydrogenase subunit C, SDHD = succinate dehydrogenase subunit D, VHL = Von Hippel–Lindau, VMA = vanillylmandelic acid.

Keywords: medullary thyroid carcinoma, multiple endocrine neoplasia type 2A, pheochromocytoma, *RET* gene mutation

1. Introduction

Multiple endocrine neoplasia type 2 (MEN2) is an autosomal dominant inherited syndrome, affecting about 1 in 30,000 individuals.[1] MEN2 can be categorized into 3 subtypes: MEN2A, MEN2B, and familial medullary thyroid carcinoma (FMTC). MEN2A is characterized by medullary thyroid carcinoma, pheochromocytoma, and primary hyperparathyroidism. MEN2B is defined by the presence of medullary thyroid carcinoma, pheochromocytoma, marfanoid habitus, mucosal neuromas, and ganglioneuromatosis of the gut and intestine. FMTC is associated with simple medullary thyroid carcinoma. All MEN2 cases occur due to the *RET* (rearranged during transfection) gene mutations. Of these, more than 95% of MEN2A cases present a single point mutation in the *RET* gene.[2] The protooncogene *RET*, residing on chromosome 10q11.2 with 21 exons, encodes a transmembrane receptor tyrosine kinase[3] with 3 functional domains: an extracellular ligand-binding domain, a transmembrane domain, and a cytoplasmic tyrosine kinase domain. As a response to specific ligand stimulation, RET dimerizes and interacts with coreceptors, GDNF-family receptor alpha (GFRa1–GFRa4).[4] The intracellular domain, which contains 2 tyrosine kinase subdomains, is involved in several downstream intracellular signal transductions, including the PI3K–AKT and MAPK–ERK kinase signaling pathways.[5] In the wild-type RET, phosphorylation of its tyrosine kinase domain stimulates the receptor and consequently the downstream signaling pathways. However, nucleotide mutations in 7 exons (exons 8, 10, 11, 13, 14, 15, or 16) of the *RET* gene resulting in Cys to Tyr in the RET protein have been found. All these gain-of-function mutations lead to a constitutive activation of RET,[6] which consequently causes hyperplasia and cancerization of the affected cells.

Although multiple endocrine neoplasia type 2A (MEN2A) can result in medullary thyroid carcinoma, pheochromocytoma, or primary hyperparathyroidism alone or combination, not all MEN2A patients show similar symptoms. Results from different

Editor: Gaurav Malhotra.

The authors have no conflicts of interest to disclose.

[a] Department of Urology, Institute of Surgery Research, Daping Hospital, Third Military Medical University, Chongqing, PR China, [b] Department of Bio-Medical Sciences, Philadelphia College of Osteopathic Medicine, Philadelphia, PA.

[*] Correspondence: Jun Jiang, 10#, Changjiang Zhilu, Yuzhong District, Chongqing 400042, PR China (e-mail: jiangjun_64@163.com).

Copyright © 2017 the Author(s). Published by Wolters Kluwer Health, Inc. This is an open access article distributed under the terms of the Creative Commons Attribution-Non Commercial License 4.0 (CCBY-NC), where it is permissible to download, share, remix, transform, and buildup the work provided it is properly cited. The work cannot be used commercially without permission from the journal.

Medicine (2017) 96:3(e5967)

Received: 2 September 2016 / Received in final form: 30 December 2016 / Accepted: 2 January 2017

http://dx.doi.org/10.1097/MD.0000000000005967

studies collectively indicate that diverse phenotypes are highly related to the site of the mutation. For example, substitution of Met918Thr in the tyrosine kinase domain is responsible for MEN2B.[7,8] Any 1 of the 5 cysteine residues (609, 611, 618, 620, and 634) in the cysteine-rich region of the RET extracellular domain can cause MEN2A and FMTC.[3,9] Nevertheless, alterations in the downstream pathways also contribute to diverse phenotypes. Little is reported about MEN2A syndrome in the Chinese population. Herein, we present the findings of different *RET* gene mutation-induced MEN2A in 3 Chinese families with diverse medical histories, as well as clinical, laboratory, and genetic characteristics.

2. Materials and methods

2.1. Patients

Proband 1 is a 19-year-old male suffering from chronic dizziness and palpitation for about half a year. A computed tomography (CT) scan revealed a suprarenal mass approximately 4.3 cm in the left abdominal area (Fig. 1A). The calcitonin level was also elevated, suggesting an abnormality in the thyroid. The genetic evaluation identified a mutation in the *RET* gene. In addition, bilateral pheochromocytomas and medullary thyroid cancer (MTC) had been diagnosed in the proband's father who is currently 59-years-old. Since the parathyroid hormone (PTH) level in the father was high, hyperparathyroidism was suspected, and further examination found a rare ectopic pheochromocytoma in his abdomen. He was found to carry the same mutation as proband 1. Further genetic tests on the other family members found the same mutation in proband's half-brother, who is currently 27-years-old but does not show any MEN2-related abnormality.

Proband 2 is a 42-year-old female who was admitted to Daping Hospital of Third Military Medical University Hospital in November 2013 for the elucidation of the cause of headache and dizziness over a period of 1 year. The blood pressure was 220/110 mm Hg, and Amlodipine Besylate tablet was prescribed for oral administration. A CT scan discovered bilateral adrenal (Fig. 1B) and thyroid (Fig. 1C and D) masses. The genetic test identified a different mutation in the *RET* gene. The 44-year-old sister of proband 2 was diagnosed with MTC and pheochromocytoma several years ago, following which, thyroidectomy was conducted. However, due to the incomplete procedure, the tumor

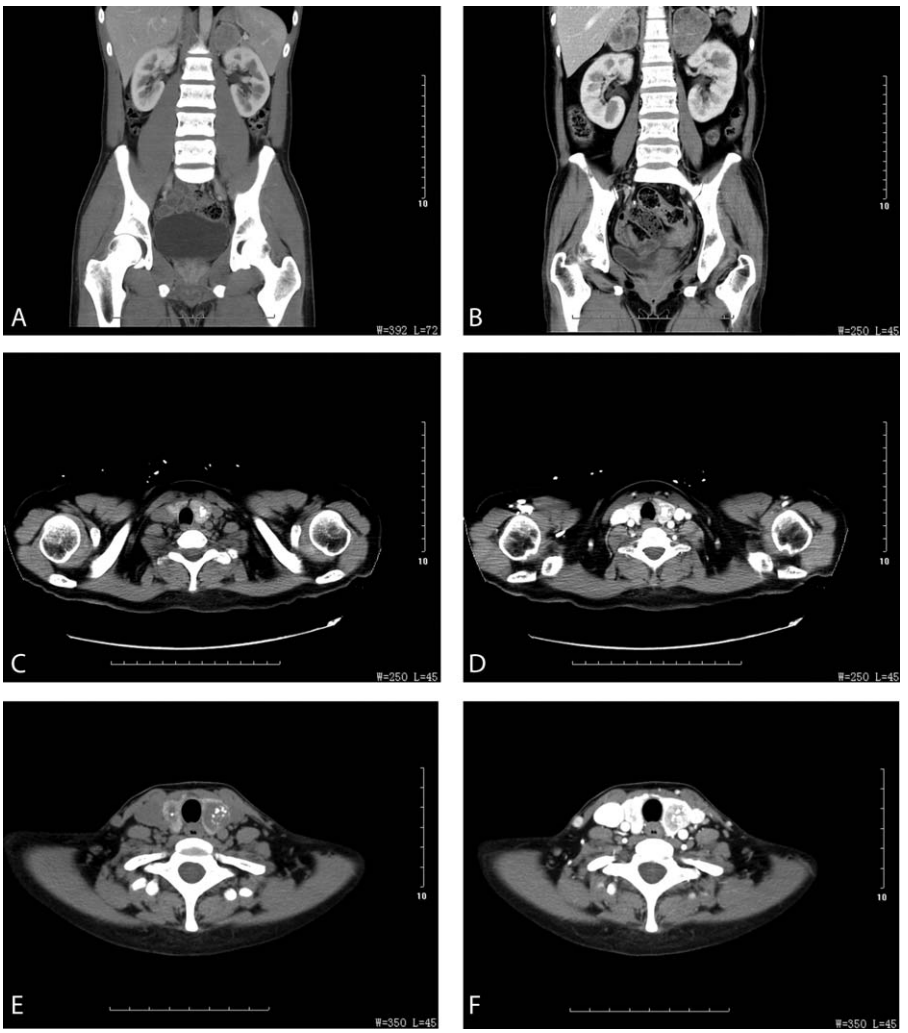

Figure 1. CT of the probands: (A) CT enhancement scan of the abdomen in proband 1. (B) CT enhancement scan of the abdomen in proband 2. (C) CT scan of the thyroid in proband 2. (D) CT enhancement scan of the thyroid in proband 2. (E) CT scan of the thyroid in proband 3. (F) CT enhancement scan of the thyroid in proband 3.

recurred in the thyroid, and a total thyroidectomy was performed. As described later, she also carried the same mutation as proband 2. A mass was also found in the thyroid of the probands mother, who is 65-years-old with increased calcitonin and carried the same mutation. However, the son, currently 17-years-old, also carried the same mutation but did not show any MEN2-related abnormality.

Proband 3 is a 35-year-old female admitted to our hospital for the carcinoembryonic antigen (CEA) at 204.06 ng/mL. CT and PET-CT scans revealed masses on the left thyroid (Fig. 1E and F) and enhanced lymph node along the left sternocleidomastoid muscles. Genetic analysis revealed a mutation in the *RET* gene, which was different from that in probands 1 and 2. The paternal uncle of proband 3, currently 55-years-old suffered from MTC 18 years earlier. As discussed below, he also carried the same mutation as proband 3, suggesting that the father of the proband likely harbors the same mutation. However, he did not yet display any MEN2-related abnormality.

2.2. Ethical review and patient consent

The Institutional Review Board of Daping Hospital of Third Military Medical University waived the IRB approval for the study; however, the written informed consent was obtained from the patients for the use of medical records and related images, before the publication of the study.

2.3. Laboratory and pathological examinations

When MEN2A was suspected, a series of examinations were undertaken, including levels of calcitonin, PCT-1 (procalcitonin), PTH, VMA (vanillylmandelic acid), MN (noradrenaline), and ALD (aldosterone). The cortisol levels were monitored for 24 at 8 h intervals. Moreover, whole-body CT scanning was conducted for potential tumors. In the event that tumors were identified, resected tumor tissues were submitted to the licensed pathologist for confirmation of the lesions. All the tissues were embedded in paraffin, sectioned, deparaffinized, and analyzed by the standard hematoxylin and eosin (H&E) staining procedures.

2.4. Mutation analysis of RET

Total DNA isolated from the peripheral blood of all the probands was used for screening the potential mutations in the following genes: *SDHAF2* (succinate dehydrogenase complex assembly factor 2), *SDHB* (succinate dehydrogenase subunit B), *SDHC* (succinate dehydrogenase subunit C), *SDHD* (succinate dehydrogenase subunit D), *MAX* (MYC associated factor X), *NF1* (neurofibromin 1), *RET*, and *VHL* (Von Hippel–Lindau) using Target Capture-Based Deep Sequencing (BGI Health, Shenzhen, Guangdong, China). Upon identification of the mutation, the same putative mutations in the members of the probands' families were tested.

3. Results

3.1. Clinical features of the 3 probands

The characteristics of the 3 probands identified in this study are summarized in Table 1. In addition, the masses in the adrenal and/or thyroid were confirmed by CT scans (Fig. 1), and the postoperative pathological examinations further verified the diagnoses (Fig. 2). A pheochromocytoma was identified in the left

Table 1

The laboratory parameters of the probands.

	Proband 1	Proband 2	Proband 3
Time of operation	**2015-3-10**	**2015-3-6 for the first time, 2015-5-8 for the second time**	**2015-5-12**
Cacitonin	8.58 (2015-4-16), 11.7 (2015-8-5), 28.53 (2015-12-23)	2062.7 (2015-5-7), 74.95 (2015-5-14), 15.84 (2015-6-24), 619.3 (2015-9-23)	611.2 (2015-5-21), 860.2 (2015-6-23), 650.0 (2015-10-30), 408.1 (2015-11-17)
PTH	30.87 (2015-4-16), 15.08 (2015-8-5), 30.37 (2015-12-23)	36.10 (2015-5-7), 2.91 (2015-5-14), 14.41 (2015-6-24)	4.99 (2015-5-21), 5.06 (2015-11-17)
PCT-1	0.28 (2015-3-9)	3.71 (2015-3-5), 3.98 (2015-5-7)	—
VMA	83.2 (2015-3-9)	107.8 (2015-3-5)	—
MN	5.2 (2015-3-9)	5.50 (2015-3-5)	—
Cor8	272 (2015-3-9)	280.0 (2015-3-5)	—
Cor16	177 (2015-3-9)	219.0 (2015-3-5)	—
Cor24	75 (2015-3-9)	116.0 (2015-3-5)	—
Orthostatic ALD	0.25 (2015-3-9)	0.14 (2015-3-5)	—
Clinostatism ALD	0.21 (2015-3-9)	0.12 (2015-3-5)	—
CEA	2.74 (2015-3-9)	38.81 (2015-3-5), 13.45 (2015-6-24), 11.23 (2015-9-23)	204.06 (2015-5-1), 32.46 (2015-10-30), 37.45 (2015-11-17)
hTSH	—	1.58 (2015-3-5),0.74 (2015-5-7), 35.36 (2015-5-14), 4.27 (2015-6-24), 2.03 (2015-9-23)	2.12 (2015-5-1), 12.36 (2015-5-21), 0.15 (2015-6-23), 0.04 (2015-11-17)
FT3	—	3.61 (2015-3-5), 3.51 (2015-5-7), 3.18 (2015-5-14), 3.91 (2015-6-24), 4.20 (2015-9-23)	5.26 (2015-5-1), 2.21 (2015-5-21), 5.06 (2015-6-23), 4.72 (2015-11-17)
FT4	—	10.32 (2015-3-5), 14.03 (2015-5-7), 8.74 (2015-5-14), 16.61 (2015-6-24), 12.50 (2015-9-23)	12.78 (2015-5-1), 5.86 (2015-5-21), 14.38 (2015-6-23), 14.78 (2015-11-17)
T3	—	1.51 (2015-3-5), 0.85 (2015-5-7), 0.84 (2015-5-14)	1.6 (2015-5-1), 0.63 (2015-5-21), 1.89 (2015-6-23), 1.49 (2015-11-17)
T4	—	85.94 (2015-3-5), 84.26 (2015-5-7), 67.23 (2015-5-14)	106.22 (2015-5-1), 34.12 (2015-5-21), 153.25 (2015-6-23), 124.97 (2015-11-17)
TG-Ab	—	0.00 (2015-3-5), 0.00 (2015-5-7), 0.00 (2015-5-14)	0.80 (2015-5-1), 0.50 (2015-5-21), 0.00 (2015-6-23), 0.00 (2015-11-17)

ALD = aldosterone, CEA = carcinoembryonic antigen, Cor = cortisol, FT3 = free triiodothyronine, FT4 = free thyroxine, hTSH = human thyroid-stimulating hormone, MN = noradrenaline, PCT-1 = procalcitonin, PTH = parathyroid hormone, T3 = triiodothyronine, T4 = thyroxine, TG-Ab = throglobulin antibody, VMA = vanillylmandelic acid.

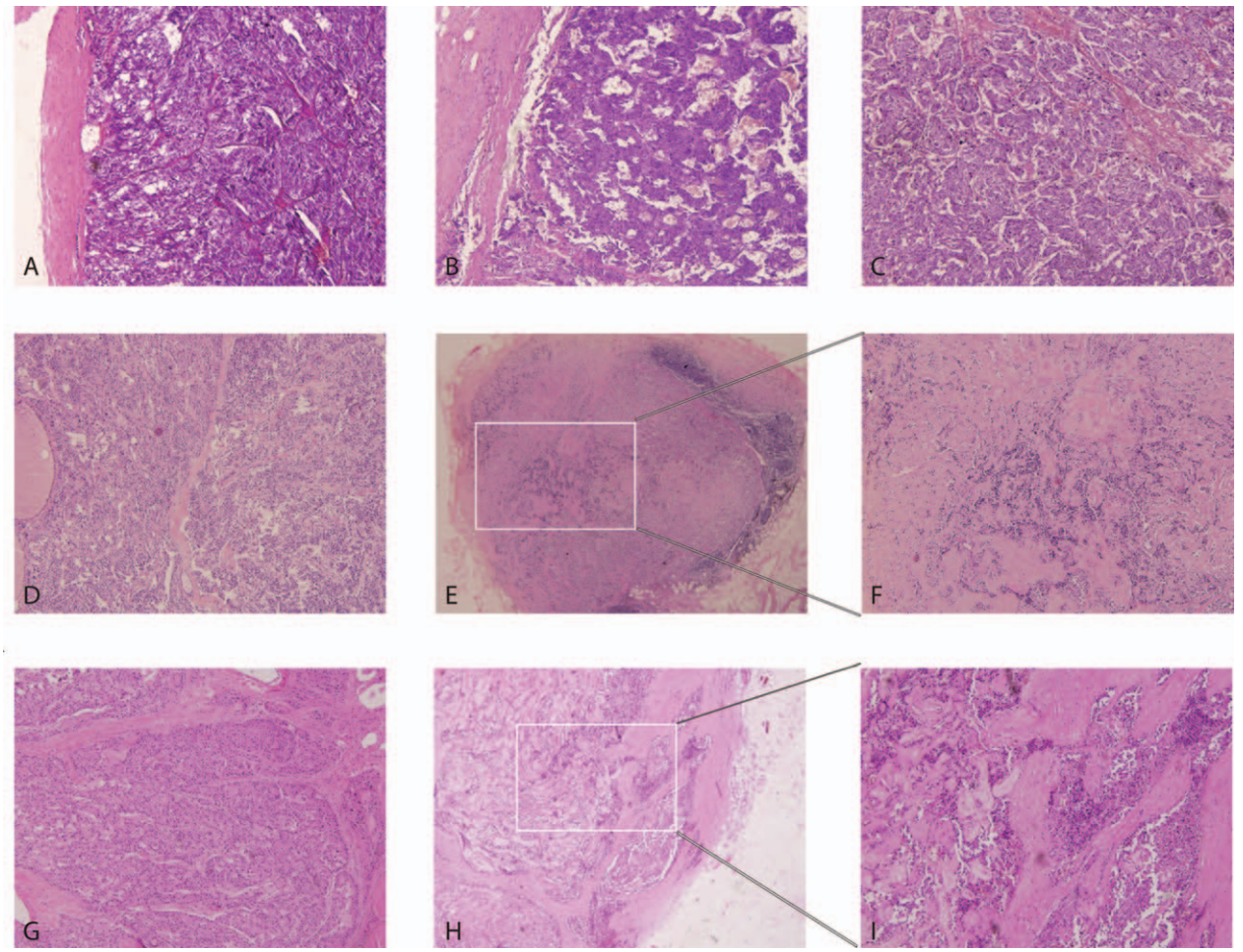

Figure 2. Pathological features of the probands: (A) Pathological biopsy of left adrenal pheochromocytoma stained with H&E (×100) in proband 1. (B) Pathological biopsy of left adrenal pheochromocytoma stained with H&E (×100) in proband 2. (C) Pathological biopsy of right adrenal pheochromocytoma stained with H&E (×100) in proband 2. (D) Pathological biopsy of MTC stained with H&E (×100) in proband 2. (E) Pathological biopsy of positive lymph node in the neck stained with H&E (×40) in proband 2. (F) Pathological biopsy of positive lymph node in the neck stained with H&E (×100) in proband 2. (G) Pathological biopsy of MTC stained with H&E (×100) in proband 3. (H) Pathological biopsy of positive lymph node in the neck stained with H&E (×40) in proband 3. (I) Pathological biopsy of positive lymph node in the neck stained with H&E (×100) in proband 3.

adrenal gland of proband 1 (Fig. 2A). The pheochromocytoma in proband 2 is shown in Fig. 2B and C; the medullary thyroid carcinoma is shown in Fig. 2D, and a positive lymph node in the neck is shown in Fig. 2E and F. In the case of proband 3, the MTC and positive lymph nodes are shown in Fig. 2G–I.

3.2. Identification of mutations in RET gene

Among all the genes screened, including *SDHAF2*, *SDHB*, *SDHC*, *SDHD*, *MAX*, *NF1*, *VHL*, and *RET*, mutations have only been identified in *RET* for all the 3 probands. Notably, the sites and/or substitutions of the mutations among the 3 families were different. The mutation in the *RET* gene in proband 1 was Cys634Ser (Fig. 3A), proband 2 resented Cys611Tyr (Fig. 3B), whereas proband 3 harbored a Cys634Tyr (Fig. 3C) mutation. Furthermore, after the mutation had been identified, all the family members of the probands were screened to substantiate if they carried the same mutation. Additional screening found that the father and one of the half-brothers also carried the same mutation as proband 1. As mentioned earlier, bilateral pheochromocytomas and MTC had been diagnosed in the proband's father who is currently 59-years-old. Since his PTH level was high, hyperparathyroidism was suspected, and further examination found a rare ectopic pheochromocytoma in his abdomen. However, the half-brother with the same mutation who did not show any MEN2-related abnormality. Further screening of the proband 2's family members found that her mother, son, and one of her sisters carried the same mutation. Proband 2's 44-year-old sister was diagnosed with MTC and pheochromocytoma several years ago, and thyroidectomy was conducted. However, due to incomplete thyroidectomy, the tumor recurred in the thyroid, following which, she underwent a complete procedure. A mass was also found in the thyroid of the mother, with increased calcitonin. However, the son showed no MEN2-related abnormality. The paternal uncle of proband 3 suffered from MTC before 18 years. He also carried the same mutation as proband 3, suggesting that the father of proband 3 putatively harbored the same mutation. However, any MEN2-related abnormity was not yet observed. In these 3 families, other family members without the mutation did not exhibit any MEN2A phenotype.

3.3. Diverse phenotypes of patients with RET mutations

The probands, as well as their family members carrying the *RET* gene mutations, were shown with their family pedigrees (Fig. 4).

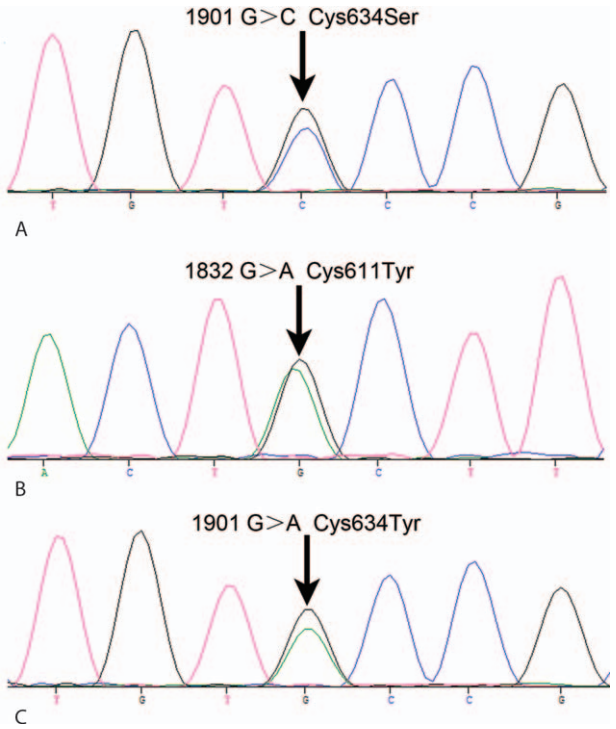

Figure 3. Mutations in *RET* gene in proband 1 (A), proband 2 (B), and proband 3 (C).

In addition, the diverse phenotypes and related clinical information of the probands and their families are summarized in Table 2. All the 3 mutations had been reported previously.[10–15] In our cases, along with positive family history, the 3 different mutations in *RET* genes displayed different spectrums of disease. Proband 1 (Cys634Ser) mainly showed pheochromocytoma with MTC being indicated, proband 2 (Cys611Tyr) presented MTC and pheochromocytoma, whereas the only symptom of proband 3 (Cys634Tyr) was MTC. Interestingly, probands 1 and 3 both had a young age onset while proband 2 showed multiple tumors simultaneously. Therefore, we concluded that the cysteine substitution by tyrosine was predisposed to induce MTC, which metastasized easily while the cysteine substitution by serine was inclined to induce pheochromocytoma. Moreover, the mutation of residue 634 could induce lesions at an early age. Notably, proband 1's father presented with a parathyroid disease and a rare ectopic pheochromocytoma.

4. Discussion

In this case report, we presented the clinical, laboratory, and genetic characteristics of 3 Chinese families with different *RET* gene mutation-induced MEN2A. The 3 probands harbor Cys634Ser, Cys611Tyr, and Cys634Tyr mutations in the gene, respectively. Paun et al[16] suggested that pheochromocytoma rarely precedes the development of MTC and is the initial manifestation of MEN2A. If the patients underwent regular screening, pheochromocytoma typically becomes evident about 10 years later than C-cell hyperplasia or MTC.[17] Thus, it is unusual for pheochromocytoma to be the first manifestation of MEN2A, similar to our cases 1 and 2. The underlying causes of different manifestations remain to be further elucidated.

Of the 3 *RET* gene mutation-induced MEN2A syndromes reported in this study, 2 included the mutation on residue 634 and the third on residue 611; however, they showed diverse phenotypes. What leads to these diversifications? Also, different mutations could result in different degrees of RET activation. Carlomagno et al[18] found that different phenotypes of MEN2A and FMTC resulting from Cys-634 mutation of MEN2A could lead to higher activity of RET as compared to Cys-620 mutation of FMTC. On the other hand, diversified sensitivities of different tissues and individuals to mutations activating RET may also give

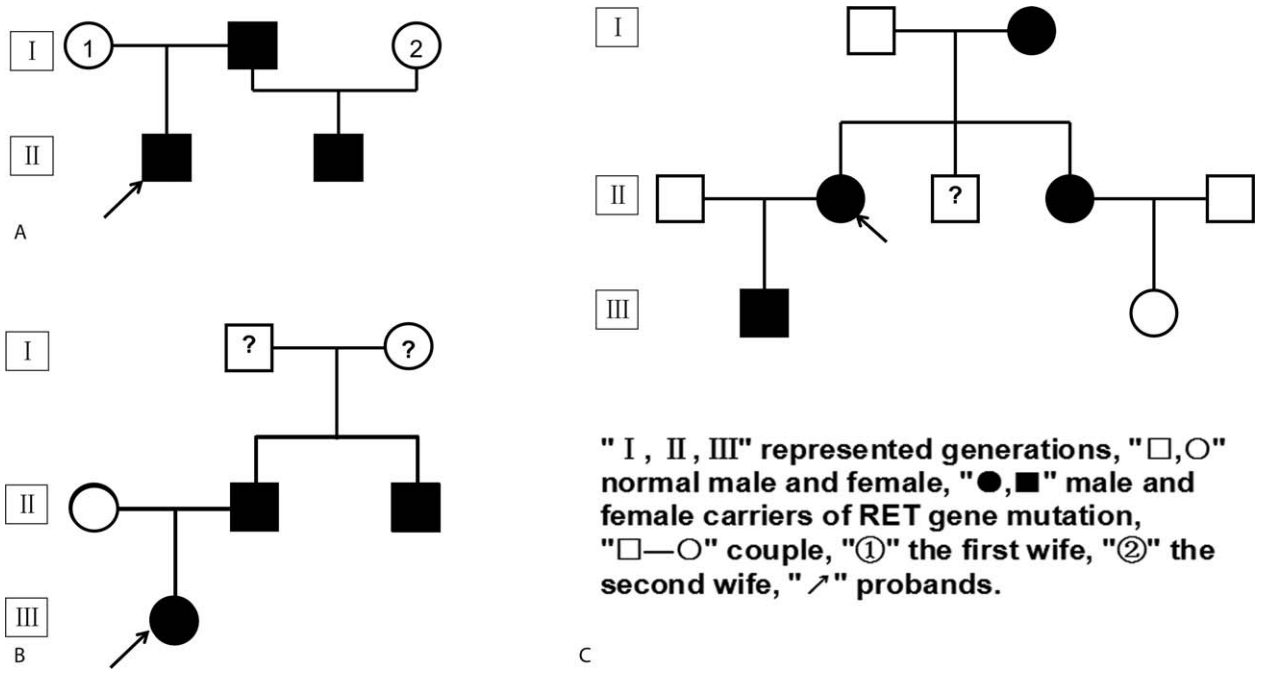

Figure 4. Family's pedigrees of proband 1 (A), proband 2 (B), and proband 3 (C).

Table 2

The phenotypes of the patients carrying the RET mutation.

	Family 1			Family 2				Family 3		
	Proband	Father	brother	Proband	Sister	Mother	Son	Proband	Uncle	Father
Age	19	59	27	42	44	65	17	35	55	60
MTC	−	+	−	+	+	+	−	+	+	−
Pheochromocytoma	+	++	−	++	+	−	−	−	−	−
Hyperparathyroidism	−	+	−	−	−	−	−	−	−	−
Hirschsprung	−	−	−	−	−	−	−	−	−	−
Cutaneous lichen amyloidosis	−	−	−	−	−	−	−	−	−	−
Increased cacitonin	+	+	−	+	+	+	−	−	−	−
Increased VMA	+	+	−	+	+	−	−	−	−	−
Increased MN	−	+	−	+	+	−	−	−	−	−
Increased PTH	−	+	−	−	−	−	−	−	−	−

"+" represented existence of this phenotype, "−" nonexistence (unilateral +, bilateral ++).
MN = noradrenaline, MTC = medullary thyroid cancer, PTH = parathyroid hormone, VMA = vanillylmandelic acid.

rise to different phenotypes. For instance, thyroid C-cells may have a low transformation threshold, being sensitive also to the low activity of RET mutation. Conversely, the alteration of only certain amino acids (634 in MEN2A and 918 in MEN2B) effectuates a sufficiently high RET stimulation to cause a neoplastic transformation of adrenal chromaffin cells,[18] indicating that even in the MEN2A phenotype, pheochromocytomas have been observed less frequently than MTCs.[19] Although similar mutation in proband 2 and the family members was noted, different phenotypes were observed. The proband and her sister were diagnosed with metastasized MTC and adrenal pheochromocytoma at about 40 years of age while their mother was diagnosed with MTC at about 70 years of age. This exhibition of phenotype at different ages could be attributed to the proband and her sister showing increased sensitivity to the Cys611Tyr mutation than their mother. Thus, the different sensitivities could be related to the RET downstream pathway. AKT was found to be activated in cells expressing RET-MEN2A, which was PI3K-dependent. Moreover, the expression of dominant-negative forms of AKT has been recently reported to inhibit RET-MEN2A oncogenic activity,[20] indicating that the second family members could harbor different AKT activities. Notably, the mechanisms of the diverse phenotypes are extremely complicated, necessitating further investigation.

The major manifestation of MEN2 is MTC. Patients with MEN2 are posed with a 70% to 100% risk of developing MTC by the age of 70 years[21]; once MTC spreads beyond the thyroid, the prognosis is extremely poor. Therefore, a majority of the treatments for MEN2 were focused on MTC.[22] For the same reason, screening of RET mutation and prediction of MEN2 with high-risk of pheochromocytoma should be carried out at the earliest. Given the high penetrance of this disease, family members of the patient should also be screened. In the case of MEN2A patients with early manifestation of pheochromocytoma, screening and confirming the RET mutation followed by a timely treatment at an early stage is suggested to prevent the development of MTC. A consensus guideline for the diagnosis and management of neuroendocrine tumors issued by North American Neuroendocrine Tumor Society suggests that RET mutation should be classified by the locus of the mutations that may serve as guidelines for the treatment of MTC. In order to improve prognosis, thyroidectomy should be conducted by 5 to 10 years of age in children carrying the *RET* gene mutations at codons 609, 630, 768, 790, 791, 804, and 891 (referred as level 1). For patients with level 2 (mutations of codons 611, 618, 620, 634), operations should be done by 5 years of age and for those with level 3 (mutations of codons 883, 918, 922), thyroidectomy should be conducted in the first month but no later than 6 months of life.

MEN2A has a poor prognosis with MTC developing silently to its later stage. Therefore, screening, early diagnosis, and timely treatment of this disease at the early stages are the key factors for a better prognosis. In addition, early onset of the disease should also raise suspicion on possible gene mutations. The appearance of masses on multiple sites including simultaneous MTC and adrenal pheochromocytoma or bilateral adrenal pheochromocytoma are other indications of the disease. If a mutation in the gene is suspected, next generation sequencing, which has been widely used for the identification of rare causative mutations, should be undertaken immediately. To collect all the pedigree data, the members of the proband should be screened for potential carriers of the mutation. Such a targeted screening could allow an efficient utilization of bioinformatics information.[23] In addition, data from knockout and/or transgenic animals[24] mimicking different diseases including MEN1,[25] MEN2,[26] and MENX[27] demonstrated that animal models are valuable for the enhanced understanding of the molecular mechanisms in specific mutation-caused diseases. Therefore, transgenic mice carrying each of these 3 mutations could be established and used for studying the underlying mechanisms in *RET* gene mutation-induced MEN2A. Moreover, we could use cell models with the corresponding mutations for the functional analysis. We might also aspire to explore the diverse functions and phenotypes by transfecting thyroid or chromaffin cell lines with plasmids expressing different RET mutations.

In summary, by comparing the clinical, laboratory, genetic characteristics, and diverse phenotypes of the 3 Chinese families harboring different *RET* gene mutations, we conclude that further application of genetic testing is essential in order to detect the disease at a curable stage.

Acknowledgment

Written informed consent was obtained from the patients for publication of these case reports as well as the accompanying images.

References

[1] Brandi ML, Gagel RF, Angeli A, et al. Guidelines for diagnosis and therapy of MEN type 1 and type 2. J Clin Endocrinol Metab 2001;86:5658–71.
[2] Ghazi AA, Bagheri M, Tabibi A, et al. Multiple endocrine neoplasia type 2A in an Iranian family: clinical and genetic studies. Arch Iran Med 2014;17:378–82.

[3] Mulligan LM, Kwok JB, Healey CS, et al. Germ-line mutations of the RET proto-oncogene in multiple endocrine neoplasia type 2A. Nature 1993;363:458–60.
[4] Jing S, Wen D, Yu Y, et al. GDNF-induced activation of the ret protein tyrosine kinase is mediated by GDNFR-alpha, a novel receptor for GDNF. Cell 1996;85:1113–24.
[5] Wagner AJ, Remillard SP, Zhang YX, et al. Loss of expression of SDHA predicts SDHA mutations in gastrointestinal stromal tumors. Mod Pathol 2013;26:289–94.
[6] Favier J, Amar L, Gimenez-Roqueplo AP. Paraganglioma and phaeochromocytoma: from genetics to personalized medicine. Nat Rev Endocrinol 2015;11:101–11.
[7] Hofstra RM, Landsvater RM, Ceccherini I, et al. A mutation in the RET proto-oncogene associated with multiple endocrine neoplasia type 2B and sporadic medullary thyroid carcinoma. Nature 1994;367:375–6.
[8] Carlson KM, Dou S, Chi D, et al. Single missense mutation in the tyrosine kinase catalytic domain of the RET protooncogene is associated with multiple endocrine neoplasia type 2B. Proc Natl Acad Sci USA 1994;91:1579–83.
[9] Donis-Keller H, Dou S, Chi D, et al. Mutations in the RET proto-oncogene are associated with MEN 2A and FMTC. Hum Mol Genet 1993;2:851–6.
[10] Poturnajova M, Altanerova V, Kostalova L, et al. Novel germline mutation in the transmembrane region of RET gene close to Cys634Ser mutation associated with MEN 2A syndrome. J Mol Med (Berl) 2005;83:287–95.
[11] Patocs A, Klein I, Szilvasi A, et al. Genotype-phenotype correlations in Hungarian patients with hereditary medullary thyroid cancer. Wien Klin Wochenschr 2006;118:417–21.
[12] Mahesh DM, Nehru AG, Seshadri MS, et al. RET mutations in a large Indian family with medullary thyroid carcinoma. Indian J Endocrinol Metab 2014;18:516–20.
[13] Bahlo M, Schott M, Kaminsky E, et al. [Multiple endocrine neoplasia 2a: late manifestation of a newly-discovered mutation]. Dtsch Med Wochenschr 2008;133:464–6.
[14] Prazeres HJ, Rodrigues F, Figueiredo P, et al. Occurrence of the Cys611Tyr mutation and a novel Arg886Trp substitution in the RET proto-oncogene in multiple endocrine neoplasia type 2 families and sporadic medullary thyroid carcinoma cases originating from the central region of Portugal. Clin Endocrinol (Oxf) 2006;64:659–66.
[15] Ishizu K, Shiraishi K, Kawamura H, et al. [A case of multiple endocrine neoplasia type 2A (MEN2A) with a mutation in the RET gene]. Hinyokika Kiyo 1999;45:407–10.
[16] Paun DL, Poiana C, Petris R, et al. Multiple endocrine neoplasia type 2A: case report. Chirurgia (Bucur) 2013;108:900–3.
[17] Utiger RD. Medullary thyroid carcinoma, genes, and the prevention of cancer. N Engl J Med 1994;331:870–1.
[18] Carlomagno F, Salvatore G, Cirafici AM, et al. The different RET-activating capability of mutations of cysteine 620 or cysteine 634 correlates with the multiple endocrine neoplasia type 2 disease phenotype. Cancer Res 1997;57:391–5.
[19] Smith DP, Eng C, Ponder BA. Mutations of the RET proto-oncogene in the multiple endocrine neoplasia type 2 syndromes and Hirschsprung disease. J Cell Sci Suppl 1994;18:43–9.
[20] Segouffin-Cariou C, Billaud M. Transforming ability of MEN2A-RET requires activation of the phosphatidylinositol 3-kinase/AKT signaling pathway. J Biol Chem 2000;275:3568–76.
[21] Krampitz GW, Norton JA. RET gene mutations (genotype and phenotype) of multiple endocrine neoplasia type 2 and familial medullary thyroid carcinoma. Cancer 2014;120:1920–31.
[22] Moline J, Eng C. Multiple endocrine neoplasia type 2: an overview. Genet Med 2011;13:755–64.
[23] Black M, Wang W, Wang W. Ischemic stroke: from next generation sequencing and GWAS to community genomics? Omics 2015;19: 451–60.
[24] Wiedemann T, Pellegata NS. Animal models of multiple endocrine neoplasia. Mol Cell Endocrinol 2016;421:49–59.
[25] Crabtree JS, Scacheri PC, Ward JM, et al. A mouse model of multiple endocrine neoplasia, type 1, develops multiple endocrine tumors. Proc Natl Acad Sci USA 2001;98:1118–23.
[26] Smith-Hicks CL, Sizer KC, Powers JF, et al. C-cell hyperplasia, pheochromocytoma and sympathoadrenal malformation in a mouse model of multiple endocrine neoplasia type 2B. EMBO J 2000;19:612–22.
[27] Fritz A, Walch A, Piotrowska K, et al. Recessive transmission of a multiple endocrine neoplasia syndrome in the rat. Cancer Res 2002;62: 3048–51.