

## Insertion of a Preserflo microshunt inside a non-valved glaucoma shunt to treat late-onset hypotony

Huzaiifa Malick, Di Zou, Richard Stead

We present a case of advanced glaucoma with previously failed trabeculectomy who underwent a Baerveldt tube (BVT) insertion, with initial success. However, 9 months post BVT insertion he developed profound clinically significant hypotony. Two attempts at controlling this with suture exchange led to episodes of significant ocular hypertension, followed by hypotony each time. We describe a technique of using a cut segment of the novel, polystyrene-block-isobutylene-block-styrene (SIBs) based Preserflo Microshunt (Santen Inc., Miami, FL) inserted into the tip of a BVT to control late onset hypotony with success. IOP at 6 weeks was 12mmHg on two drops with complete resolution of the choroidal maculopathy.

**Key words:** Glaucoma, glaucoma shunt, hypotony

Glaucoma drainage implants (GDIs) are frequently used for glaucoma filtering surgery. Despite their efficacy and favorable risk profile, complications arising from GDIs can be difficult to manage, especially in high-risk eyes requiring tight intraocular pressure control. Late-onset postoperative hypotony (intraocular pressure (IOP)  $\leq 5$  mm Hg) is a particularly difficult complication to manage after GDI surgery. Hypotony poses a risk of permanent visual reduction after GDI surgery.<sup>[1-4]</sup> Previously reported successful interventions include tube ligation<sup>[5]</sup> and tube removal as well as the introduction of a stenting suture into the lumen of the tube.<sup>[6]</sup> Insertion of a Xen gel stent (Xen, Allergan Inc. NJ) into the posterior end of a non-valved shunt after capsule dissection has also been described with success.<sup>[7]</sup>

We present a case of advanced glaucoma with previously failed trabeculectomy who underwent a Baerveldt tube (BVT) insertion, with initial success. However, 9 months post BVT insertion, he developed profound clinically significant hypotony following 3-0 Supramid suture removal. Our initial treatment for such cases involves re-stenting the tube with a simple occluding suture, as described first in 1993.<sup>[8]</sup> However, two attempts of stabilizing the IOP with ab-interno occluding sutures were unsuccessful: the first using an 8-mm segment of 3-0 Prolene suture led to a high IOP and the second procedure replacing this suture with an 8-mm segment of 4-0 Prolene suture caused hypotony again. We describe a technique of using a cut segment of the novel, polystyrene-block-isobutylene-block-styrene (SIBs) based, Preserflo Microshunt (Santen Inc., Miami,

FL) inserted into the tip of a BVT to control late-onset hypotony with success.

The Preserflo Microshunt is a novel SIBs based device measuring 8.5 mm in length, with a 350- $\mu$ m outer diameter and 70- $\mu$ m lumen. SIBs is a novel and bioinert material with high biocompatibility.<sup>[9]</sup> The distal segment of the shunt from the fin to the tip measures 4.5 mm and the external lumen diameter is 350  $\mu$ M.<sup>[10]</sup> The internal lumen diameter of the Baerveldt tube is 300  $\mu$ M.<sup>[11]</sup> Using the technique outlined below, we externalized the tip of the Baerveldt tube near the limbus and successfully inserted a 4-mm segment of the Preserflo tube into the end. Day 1 IOP was 32 mm Hg, and with medication at week 1 was 17 mm Hg with resolution of the hypotony maculopathy and choroidal effusions. The Preserflo/Baerveldt complex has remained stable inside the eye at the most recent follow-up at 6 weeks.

### Surgical Technique

After a peribulbar anesthetic block and dual superotemporal traction suture placement adjacent to the BVT site location, a clear corneal shelved incision was made into the anterior chamber approximately 1 mm from the limbus. The BVT end was directed out from the AC and the tip dilated with a punctum seeker. The beveled, distal end of the cut Preserflo tube was inserted with approximately 2 mm of its length inside

This is an open access journal, and articles are distributed under the terms of the Creative Commons Attribution-NonCommercial-ShareAlike 4.0 License, which allows others to remix, tweak, and build upon the work non-commercially, as long as appropriate credit is given and the new creations are licensed under the identical terms.

**For reprints contact:** WKHLRPMedknow\_reprints@wolterskluwer.com

**Cite this article as:** Malick H, Zou D, Stead R. Insertion of a Preserflo microshunt inside a non-valved glaucoma shunt to treat late-onset hypotony. Indian J Ophthalmol 2022;70:2180-2.

#### Access this article online

##### Website:

www.ijo.in

##### DOI:

10.4103/ijo.IJO\_22\_22

#### Quick Response Code:



Department of Ophthalmology, Queens Medical Centre, Lenton, Nottingham, United Kingdom

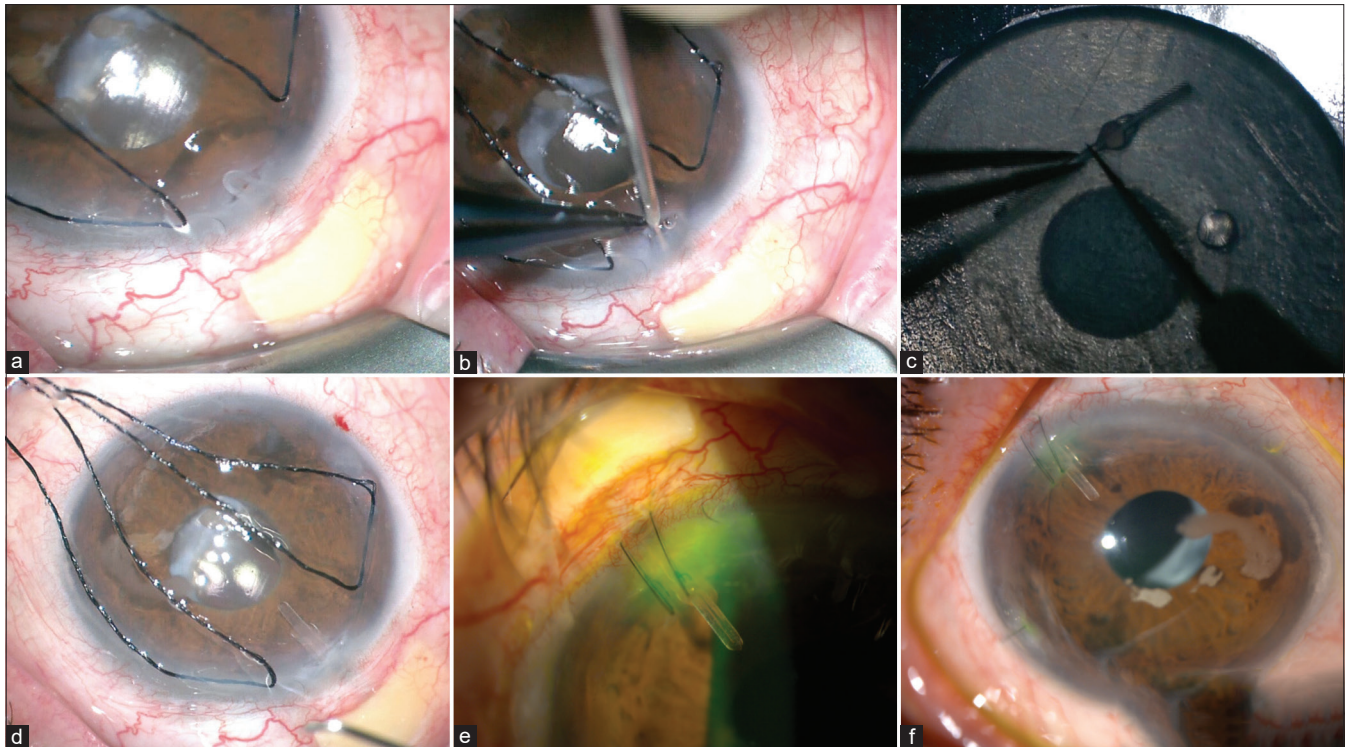
**Correspondence to:** Mr. Richard Stead, Queens Medical Centre, Department of Ophthalmology, Nottingham, UK. E-mail: richard.stead@nuh.nhs.uk

Received: 16-Jan-2022

Revision: 21-Feb-2022

Accepted: 16-Mar-2022

Published: 31-May-2022



**Figure 1:** (a) Limbal incision to access BVT tip. (b) Punctum seeker used to widen BVT lumen. (c) Preserflo Microshunt cut below the central fin. (d) View of externalized BVT tip. (e) Day 1 postoperative picture. (f) Week 1 postoperative picture

the BVT tube and 2 mm externalized beyond the tip [Fig. 1]. The complex was then reintroduced into the AC and the corneal entry site was closed using two 10-0 Nylon interrupted sutures.

## Results

Pre-op visual acuity (VA) was 0.50 LogMAR with an IOP of 4 mm Hg with hypotonic maculopathy. Day 1 VA was 0.30 with an IOP of 15 mm Hg. Week 1 IOP crept up to 26 mm Hg (VA 0.32); thus, glaucoma eyedrops were introduced with a reduction in the IOP to 12 mm Hg and VA of 0.30. IOP at 6 weeks was 12 mm Hg on two eyedrops with complete resolution of the choroidal maculopathy.

## Discussion

Early hypotony post non-valved GDIs has been reported to be as high as 39%.<sup>[12,13]</sup> However, late-onset hypotony is much less common, with reported rates of up to 13%.<sup>[14,15]</sup> Previous attempts in our case to use more traditional methods of hypotony treatment were unsuccessful; specifically, insertion of an 8 mm 3-0 Prolene suture led to high pressures, and a 4-0 Prolene suture led to persistent hypotony. Significant variability of the IOP is not uncommon in these advanced glaucomatous eyes. Tube removal remained an option in our case but would only have been a short-term option, especially as a low pressure was required. Inserting a Xen to the posterior tube end as previously described has reported success,<sup>[7]</sup> but we were keen to avoid both conjunctival and capsule dissection in this case. Our technique described here is relatively quick, with no conjunctival dissection required and is technically relatively easy.

If we need further IOP reduction in our patient, we plan to trim the distal end of the Preserflo tip to provide less

resistance to aqueous flow (as this reduces the length of the flow resisting segment). This will be straightforward and can be done ab interno. This has been offered to our patient who is keen to avoid further intervention currently and is happy to continue with a combination glaucoma drop twice daily. Longer-term results with this and any subsequent cases using this intervention will help to both refine the technique and identify any late complications. We postulate that future cases using this method may be performed totally ab interno, although insertion of the Preserflo into the Baerveldt lumen securely may prove problematic. Corneal endothelial count measurements would also be beneficial.

## Conclusion

Despite the lack of long-term follow-up yet, this novel technique appears to be both successful and safe in the short-term follow-up of late-onset persistent hypotony post BVT insertion.

The authors would like to point out that this is an off-label use of the Preserflo Microshunt in the United Kingdom.

## Financial support and sponsorship

Nil.

## Conflicts of interest

There are no conflicts of interest.

## References

- Patel S, Pasquale LR. Glaucoma drainage devices: A review of the past, present, and future. *Semin Ophthalmol* 2010;25:265-70.
- Välämäki J. Surgical management of glaucoma with Molteno3 implant. *J Glaucoma* 2012;21:7-11.

3. Budenz DL, Feuer WJ, Barton K, Schiffman J, Costa VP, Godfrey DG, *et al.* Postoperative complications in the Ahmed Baerveldt comparison study during five years of follow-up. *Am J Ophthalmol* 2016;163:75-82.
4. Christakis PG, Kalenak JW, Tsai JC, Zurakowski D, Kammer JA, Harasymowycz PJ, *et al.* The Ahmed versus Baerveldt study: Five-year treatment outcomes. *Ophthalmology* 2016;123:2093-102.
5. Feinstein M, Moussa K, Han Y. Ab interno tube occlusion for postoperative hypotony in a patient with an Ahmed glaucoma drainage device. *J Glaucoma* 2018;27:e61-3.
6. Kuruvilla S, Landers J, Craig JE. Secondary stenting of glaucoma drainage implant: A novel technique for treatment of late hypotony. *Clin Exp Ophthalmol* 2016;44:860-1.
7. Välimäki J. Xen gel stent to resolve late hypotony after glaucoma drainage implant surgery: A novel technique. *J Glaucoma* 2018;27:926-8.
8. Sherwood MB, Smith MF. Prevention of early hypotony associated with Molteno implants by a new occluding stent technique. *Ophthalmology* 1993;100:85-90.
9. Batlle JF, Corona A, Albuquerque R. Long-term results of the PRESERFLO microshunt in patients with primary open-angle glaucoma from a single-center nonrandomized study. *J Glaucoma* 2021;30:281-6.
10. Pinchuk L, Riss I, Batlle JF, Kato YP, Martin JB, Arrieta E, *et al.* The use of poly (styrene- block -isobutylene- block -styrene) as a microshunt to treat glaucoma. *Regen Biomater* 2016;3:137-42.
11. Lim KS, Allan BD, Lloyd AW, Muir A, Khaw PT. Glaucoma drainage devices; past, present, and future. *Br J Ophthalmol* 1998;82:1083-9.
12. Mandalos A, Sung V. Glaucoma drainage device surgery in children and adults: A comparative study of outcomes and complications. *Graefes Arch Clin Exp Ophthalmol* 2017;255:1003-11.
13. Siegner SW, Netland PA, Urban RC Jr, Williams AS, Richards DW, Latina MA, *et al.* Clinical experience with Baerveldt glaucoma drainage implant. *Ophthalmology* 1995;102:1298-307.
14. Barton K, Feuer WJ, Budenz DL, Schiffman J, Costa VP, Godfrey DG, *et al.* Three-year treatment outcomes in the Ahmed Baerveldt comparison study. *Ophthalmology* 2014;121:1547-57.e1. doi: 10.1016/j.ophtha. 2014.01.036.
15. Vergados A, Mohite AA, Sung VC. Ab interno tube ligation for refractory hypotony following non-valved glaucoma drainage device implantation. *Graefes Arch Clin Exp Ophthalmol* 2019;257:2271-8.