


CASE REPORT

Open Access



# Addison's disease triggered by infection with *mycobacterium abscessus*, but not by adrenal tuberculosis or MAC pulmonary disease, in a subject with type 2 diabetes mellitus: case report

Hideaki Kaneto\* , Fuminori Tatsumi, Mana Ohnishi, Yuichiro Iwamoto, Yukino Katakura, Masashi Shimoda, Shuhei Nakanishi, Kohei Kaku and Tomoatsu Mune

## Abstract

**Background:** Addison's disease is primary adrenal dysfunction and is characterized by decrease of cortisol level and increase of adrenocorticotropic hormone (ACTH) level. It is known that infection is one of main causes of Addison's disease. Among various infections, tuberculous infection accounts for the majority of them. Recently the number of subjects with non-tuberculous mycobacterial infection has been increased, and the infection can also bring about Addison's disease. *Mycobacterium avium* complex (MAC) pulmonary disease accounts for the majority of non-tuberculous mycobacterial infection.

**Case presentation:** An 83-year-old female was suspected of having adrenal failure in our outpatient care and hospitalized in our institution. There was pigmentation in her face, hands and legs, especially in auricle and nail beds in her hands and legs. In rapid ACTH load test (0.25 mg of 1–24 ACTH), cortisol level was not increased at all. An abdominal computed tomography (CT) showed swelling of both adrenal glands accompanied by calcification. QuantiFERON test was negative and *mycobacterium tuberculosis* complex was negative in PCR test using bronchial lung lavage fluid. These data ruled out the possibility of adrenal tuberculosis. It is known that MAC pulmonary disease accounts for the majority of non-tuberculous mycobacterial infection. In this subject, however, anti-MAC antibody was negative and MAC-related bacteria were not detected in PCR test using bronchial lung lavage fluid. These data ruled out the possibility of MAC pulmonary disease. *Mycobacterium abscessus* (Mab) was positive in bronchial lung lavage fluid culture. Based on these data, we diagnosed this subject with Addison's disease triggered by infection with *mycobacterium abscessus*, but not by adrenal tuberculous or MAC pulmonary disease. Decreased sodium level and increased eosinophil number were normalized and appetite loss was markedly mitigated after starting hydrocortisone therapy. A chest CT which was taken about 6 months later showed drastic reduction of consolidation in the upper lobe of the left lung although calcification in the adrenal gland was still observed.

\*Correspondence: kaneto@med.kawasaki-m.ac.jp

Department of Diabetes, Endocrinology and Metabolism, Kawasaki Medical School, 577 Matsushima, Kurashiki 701-0192, Japan



© The Author(s) 2022. **Open Access** This article is licensed under a Creative Commons Attribution 4.0 International License, which permits use, sharing, adaptation, distribution and reproduction in any medium or format, as long as you give appropriate credit to the original author(s) and the source, provide a link to the Creative Commons licence, and indicate if changes were made. The images or other third party material in this article are included in the article's Creative Commons licence, unless indicated otherwise in a credit line to the material. If material is not included in the article's Creative Commons licence and your intended use is not permitted by statutory regulation or exceeds the permitted use, you will need to obtain permission directly from the copyright holder. To view a copy of this licence, visit <http://creativecommons.org/licenses/by/4.0/>. The Creative Commons Public Domain Dedication waiver (<http://creativecommons.org/publicdomain/zero/1.0/>) applies to the data made available in this article, unless otherwise stated in a credit line to the data.

**Conclusions:** We should bear in mind the possibility of Addison's disease triggered by another type of infection rather than adrenal tuberculosis or MAC pulmonary disease.

**Keywords:** Case report, Addison's disease, *Mycobacterium abscessus*, Non-tuberculous mycobacterial infection, *Mycobacterium avium* complex pulmonary disease

## Background

Addison's disease is primary adrenal dysfunction and is characterized by marked decrease of cortisol level accompanied by increase of adrenocorticotrophic hormone (ACTH) level. Hyponatremia, hypoglycemia and hypotension are often observed in subjects with Addison's disease. Pigmentation in face and hands is sometimes observed, although the frequency of pigmentation is relatively low. It is thought that such pigmentation is brought about by the increment of ACTH and/or melanocyte-stimulating hormone through the cortisol deficiency-mediated feedback system.

It is known that infection is one of main causes of Addison's disease. Among various infections, tuberculous infection accounts for the majority of them [1]. In subjects with typical Addison's disease due to adrenal gland tuberculous, swelling of both adrenal glands together with calcification is observed in some imaging examination. Recently, the number of subjects with non-tuberculous mycobacterial infection has been increasing [2]. It is known that the infection can also bring about Addison's disease whose characteristics are similar to those of adrenal gland tuberculous [3]. In Japan, *mycobacterium avium* complex (MAC) pulmonary disease after infection with *mycobacterium avium* or *mycobacterium intracellulare* accounts for the majority (more than 90%) of non-tuberculous mycobacterial infection [4, 5].

Here we show a subject who had non-tuberculous mycobacterial infection and Addison's disease triggered by the infection. Furthermore, while MAC pulmonary disease accounts for the majority of non-tuberculous mycobacterial infection, pathogen bacteria in this subject were *mycobacterium abscessus* (Mab), but not MAC. It is noted here that Mab is very rare as a cause of Addison's disease.

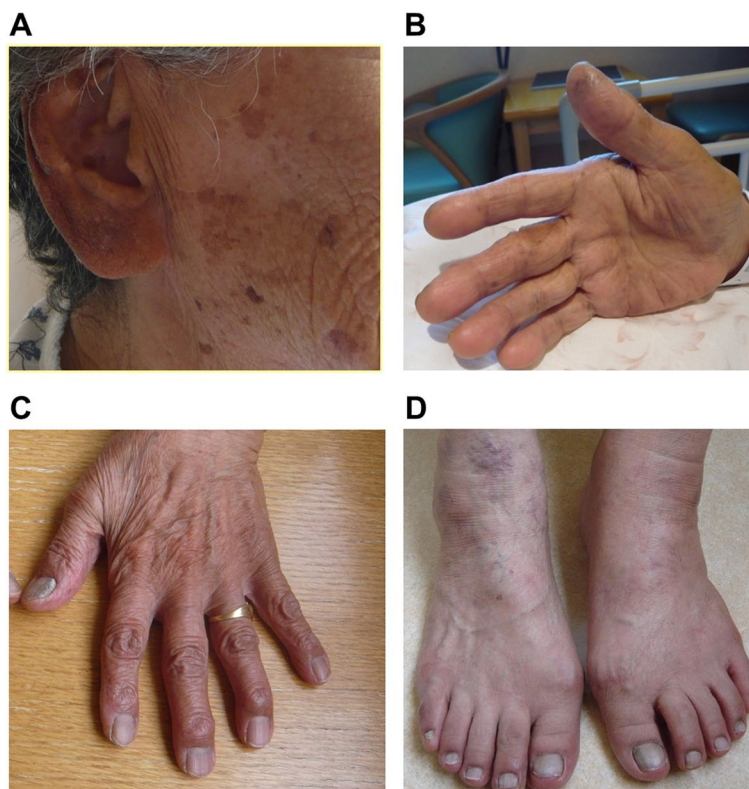## Case presentation

An 83-year-old female noticed pigmentation in her face, hands and legs. In particular, there was dark pigmentation in auricle and nail beds in her hands and legs. She had appetite loss, general fatigue and a sense of exhaustion. Her body weight was reduced by 10 kg for about 1 year. She was suspected of having adrenal failure in our outpatient care and hospitalized in our institution.

On admission, her height, body weight and body mass index were 155 cm, 48.8 kg and 20.3 kg/m<sup>2</sup>, respectively.

Blood pressure, heart rate and body temperature were 122/72 mmHg, 78 /min and 36.2°C, respectively. After admission, blood pressure was relatively low (approximately 100–120/50–60 mmHg). Figure 1 shows the picture of her face (Fig. 1A), palm (Fig. 1B), and nail beds in her hands and legs (Fig. 1C, D). There was pigmentation in her face, hands and legs. In particular, dark pigmentation was observed in auricle and nail beds in her hands and legs. Mild pigmentation was observed throughout the whole body. She had type 2 diabetes mellitus and was treated with 0.5 mg of glimepiride and 100 mg of sitagliptin. She had dyslipidemia and was treated with 10 mg of fluvastatin. Table 1 shows the clinical data on admission in this subject. ACTH was high (336.0 pg/mL) (reference range: 7.2–63.3 pg/mL), and cortisol and aldosterone were low as follows: cortisol, 4.8 µg/dL (6.24–18.0 µg/dL); aldosterone < 10 pg/mL (4.0–82.1 pg/mL). Hyponatremia and eosinophilia were observed: sodium, 123 mmol/L (138–145 mmol/L), eosinophils, 12.8% (1.0–5.0%) (white blood cells, 5060 /µL (3300–8600 /µL)). Liver function and renal function were within normal range. Glucose and lipid metabolism were almost normalized with the above-mentioned treatment. Hemoglobin A1c (HbA1c) was 6.2% (4.9–6.0%) and fasting plasma glucose was 95 mg/dL (73–109 mg/dL). In rapid ACTH load test (0.25 mg of 1–24 ACTH), cortisol level was not increased at all (4.8 µg/dL (6.24–18.0 µg/dL)) (Fig. 2A). There was no daily variation in ACTH and cortisol levels. Based on these findings, we diagnosed her with Addison's disease. After admission, glycemic control was good. It seemed that the presence of adrenal dysfunction increased the possibility of hypoglycemia risk. Therefore, we stopped glimepiride to avoid possible hypoglycemia.

An abdominal computed tomography (CT) showed swelling of both adrenal glands accompanied by calcification (Fig. 2B). We suspected her of having adrenal tuberculosis and performed QuantiFERON test. However, QuantiFERON test was negative and she had no past or family history of tuberculosis. These data ruled out the possibility of adrenal tuberculosis. A chest CT showed marked consolidation in the upper lobe of the left lung (Fig. 3A). Saturation of percutaneous oxygen (SpO<sub>2</sub>) was 97%. We thought that she had non-tuberculous mycobacterial infection and that adrenal failure was brought about by the infection. Since it is known that MAC pulmonary disease accounts for the majority of non-tuberculous



**Fig. 1** The picture of face (A), palm (B), and nail beds in her hands and legs (C, D) in this subject. There was pigmentation in her face, hands and legs. In particular, dark pigmentation was observed in auricle and nail beds in her hands and legs

mycobacterial infection (more than 90% in Japan), we checked anti-MAC antibody. In this subject, however, anti-MAC antibody was negative. There is idiopathic Addison's disease which is usually induced by autoimmunity, but in subjects with the disease, calcification is seldom observed in the adrenal gland and adrenal gland often tends to be atrophied. In consideration of these points, it was not likely that this subject had idiopathic Addison's disease. We started treatment with 10 mg of hydrocortisone and increased it to 20 mg. Sodium level was increased up to 142 mmol/L (138–145 mmol/L), and eosinophil number was decreased from 647 / $\mu$ L to 309 / $\mu$ L (33–430 / $\mu$ L) 4 days after starting hydrocortisone therapy. Appetite loss was markedly reduced at that time, and she was finally discharged from our institution.

Twenty days after discharge, bronchoscopy was performed. In polymerase chain reaction (PCR) test using bronchial lung lavage fluid, *mycobacterium tuberculosis* complex was negative. It is known that MAC pulmonary disease is induced mainly by infection with *mycobacterium avium* or *mycobacterium intracellulare*. In this subject, however, *mycobacterium avium* and *mycobacterium intracellulare* were both negative in PCR test. *Mycobacterium abscessus* was positive in bronchial lung lavage fluid

culture. We finally diagnosed this subject with *mycobacterium abscessus* (Mab) pulmonary disease and Addison's disease triggered by the infection.

A chest CT taken about 6 months later showed drastic reduction of the consolidation in the upper lobe of the left lung (Fig. 3B). Adrenal function was normalized at that time (ACTH, 44.6 pg/mL; cortisol, 8.2  $\mu$ g/dL). Calcification in the adrenal gland was still observed. Therefore, we continued hydrocortisone therapy (15 mg of hydrocortisone) for about 6 months after discharge.

### Discussion and conclusions

In this case report, we showed a subject who had non-tuberculous mycobacterial infection and Addison's disease triggered by the infection. It is known that MAC pulmonary disease accounts for a majority of lung non-tuberculous mycobacterial infection. In this subject, however, pathogen bacteria were *mycobacterium abscessus* (Mab), but not MAC. It is noted here that Mab is very rare as a cause of Addison's disease. Addison's disease is primary adrenal failure in which cortisol secretion from the adrenal gland is markedly reduced. In this subject, it is likely that the development of calcification was closely associated with destruction of the adrenal gland.

**Table 1** Clinical data on admission in this subject

Peripheral blood		Reference range	Diabetes markers		Reference range
Red blood cells	396 × 10 <sup>4</sup> /μL	435–555	Plasma glucose	95 mg/dL	73–109
Hemoglobin	12.3 g/dL	13.7–16.8	HbA1c	6.2%	4.9–6.0
White blood cells	5060 /μL	3300–8600	Lipid markers		
Neutrophils	39.6%	50.0–70.0	LDL-cholesterol	93 mg/dL	65–139
Eosinophils	12.8%	1.0–5.0	HDL-cholesterol	33 mg/dL	40–90
Lymphocytes	40.7%	20.0–40.0	Triglyceride	98 mg/dL	40–149
Platelet	17 × 10 <sup>4</sup> /μL	15.8–34.8	Endocrine markers		
Blood biochemistry			ACTH	336.0 pg/mL	7.2–63.3
Total protein	6.1 g/dL	6.6–8.1	Cortisol	4.8 μg/dL	6.24–18.0
Albumin	3.6 g/dL	4.1–5.1	DHEA-S	< 2 μg/dL	76–386
Total bilirubin	0.7 mg/dL	0.4–1.5	PRA	8.0 ng/mL/h	0.2–3.9
AST	27 U/L	13–30	PAC	< 10.0 pg/mL	4.0–82.1
ALT	14 U/L	10–42	Inflammation marker		
γ-GTP	21 U/L	13–64	CRP	0.31 mg/dL	< 0.14
LDH	226 U/L	124–222	Urinalysis		
Creatinine	0.53 mg/dL	0.65–1.07	pH	7.0	5.0–7.5
BUN	8 mg/dL	8–20	Protein	(–)	(–)
Electrolytes			Glucose	(–)	(–)
Sodium	123 mEq/L	138–145	Ketone body	(±)	(–)
Potassium	4.4 mEq/L	3.6–4.8	Occult blood	(–)	(–)
Chloride	98 mEq/L	101–108	Bilirubin	(–)	(–)
Calcium	8.3 mg/dL	8.8–10.1			
Corrected calcium	8.7 mg/dL				
Phosphorous	2.5 mg/dL	2.7–4.6			
Magnesium	2.4 mg/dL	1.9–2.6			

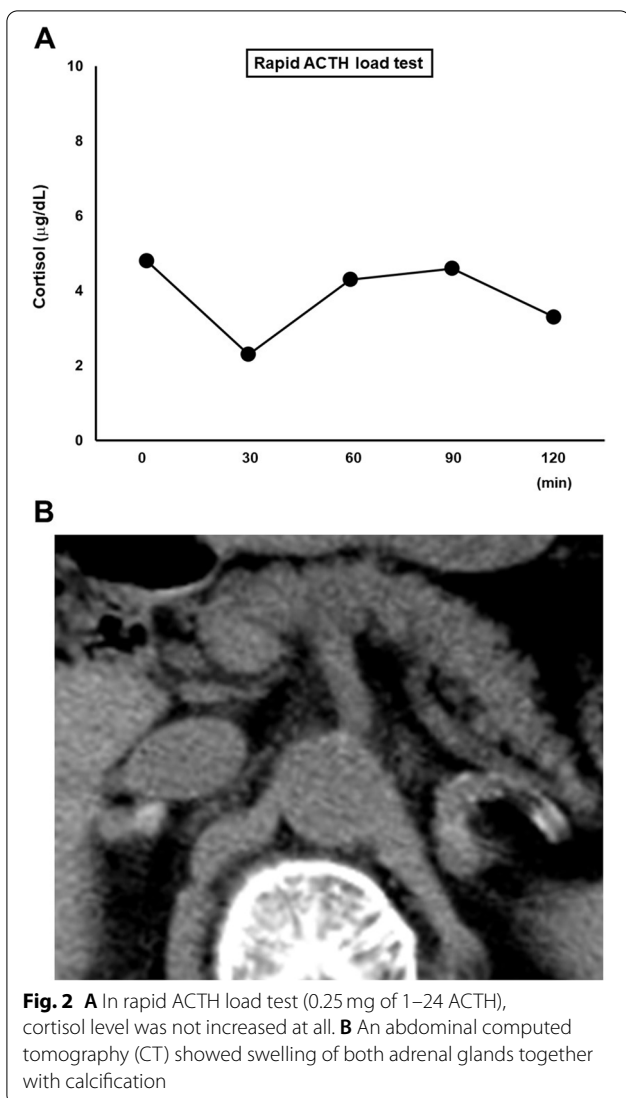
**Abbreviation:** AST aspartate aminotransferase, ALT alanine aminotransferase, γ-GTP γ-glutamyl transpeptidase, LDH lactate dehydrogenase, BUN blood urea nitrogen, HbA1c hemoglobin A1c, LDL low density lipoprotein, HDL high density lipoprotein, ACTH adrenocorticotropic hormone, DHEA-S dehydroepiandrosterone sulfate, PRA plasma renin activity, PAC plasma aldosterone concentration, CRP C-reactive protein

Although the consolidation in the left lung was drastically reduced in this subject, endogenous adrenal function was not recovered even after steroid therapy. Therefore, we continued hydrocortisone therapy. It seems that once calcification is developed to some extent, it is difficult to restore adrenal function. We assume that if we had found Addison's disease at an earlier stage before the development of calcification in the adrenal gland, we might have, at least in part, restored adrenal function to some extent in this subject.

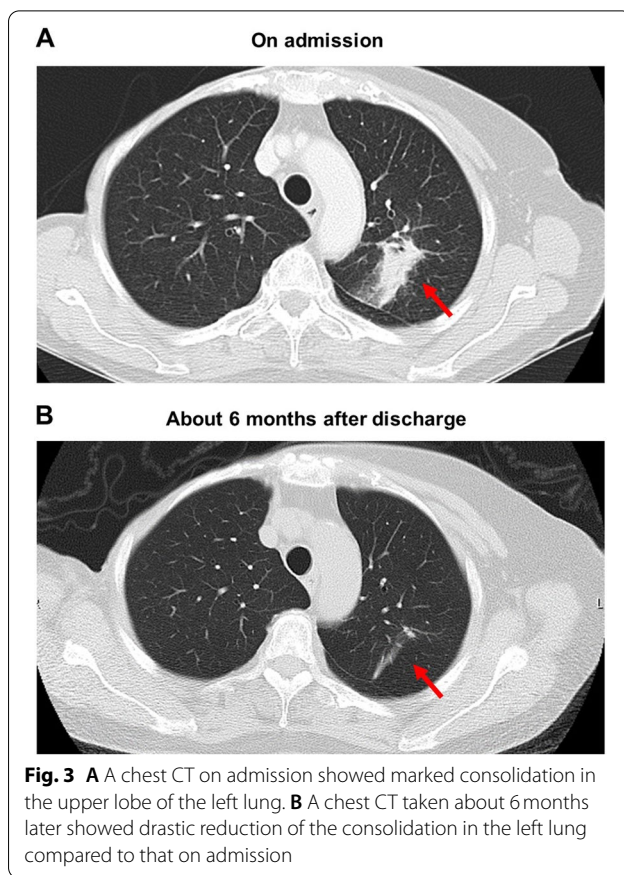
Infection, especially tuberculous infection, is one of main causes of Addison's disease. In typical Addison's disease due to adrenal gland tuberculous, swelling of both adrenal glands together with calcification is observed in some imaging examination. Therefore, we suspected this subject of having adrenal tuberculosis, but she had no past or family history of tuberculosis and QuantiFERON test was negative. In PCR test using bronchial lung lavage fluid, *Mycobacterium tuberculosis* complex was negative. These findings ruled out the possibility of adrenal tuberculosis. It is known that MAC pulmonary disease

accounts for the majority of non-tuberculous mycobacterial infection. Therefore, we suspected her of having MAC pulmonary disease, but anti-MAC antibody was negative. It is also known that *Mycobacterium avium* and *Mycobacterium intracellulare* are main pathogen bacteria of MAC pulmonary disease. In this subject, however, both bacteria were negative in PCR test using bronchial lung lavage fluid. These findings ruled out the possibility that this subject had MAC pulmonary disease. *Mycobacterium abscessus* (Mab) was positive in bronchial lung lavage fluid culture. We finally diagnosed this subject with Addison's disease triggered by infection with Mab, but not by tuberculous mycobacterial infection or MAC pulmonary disease. If adrenal gland biopsy had been performed, the biopsy data would have strengthened the above-mentioned diagnosis. However, we did not perform the biopsy in consideration of her age (83 years old), possible risk of infection and the hope of this subject that she did not want us to perform such biopsy.

The incidence of Mab pulmonary disease is slightly increasing, but it is still very rare [6–10]. Indeed, it was



reported that Mab infection accounted for only 3% in non-tuberculous mycobacteriosis [5]. Mab infection is more often observed in female compared to male, although its reason remains unknown. Mab infection is usually treated with various kind of antibiotics, and it is often difficult to appropriately control the infection especially in subjects with serious underlying disease who are compromised host [11–13]. In serious cases, surgical operation is needed to treat Mab pulmonary disease. MAC infection is often found as an underlying disease of Mab pulmonary disease. In this subject, after starting hydrocortisone therapy, sodium level was increased and eosinophil number was decreased and her symptoms were markedly mitigated. Finally, she was discharged. *Mycobacterium abscessus* was detected in bronchial lung lavage fluid culture 20 days after discharge. She had no subjective symptoms at that time. Mab infection is usually



treated with antibiotics. It has been reported, however, that Mab pulmonary disease is not aggravated even without any treatment in some subjects without serious underlying disease [11–13]. Therefore, we did not start any therapy with antibiotics in this subject. Fludrocortisone is sometimes used in subjects with Addison’s disease, but since salt intake in Japanese is higher compared to other countries, hydrocortisone, but not fludrocortisone, is used as a first-line drug in Japan. Therefore, we used hydrocortisone. However, Mab pulmonary disease in this subject was mitigated without any specific treatment. Since Mab pulmonary disease is sub-classified into three subtypes (*M. abscessus* subsp. *abscessus*, *M. abscessus* subsp. *massiliense*, *M. abscessus* subsp. *Bolletii*) based on gene sequence analysis [14], we assume that the prognosis, at least in part, depends on such subtype of bacteria. It has been also reported that the prognosis depends on host immune response in each subject. For example, when subjects have diabetes mellitus with poor glycemic control, the prognosis of Mab pulmonary disease would be poor. This subject had type 2 diabetes mellitus but glycemic control was good (HbA1c, 6.2%). We assume that good glycemic control was associated with the recovery from Mab pulmonary disease without any specific

treatment. As described above, MAC infection is often found as an underlying disease of Mab pulmonary disease, and it is known that bacteria can change from MAC to Mab. In this subject, however, since anti-MAC antibody was negative. We think that this ruled out the possibility that this subject suffered from MAC infection.

There is a limitation in this case report. Autoimmune origin of adrenal insufficiency is the most common cause for adrenal failure in developed countries. In the present case, autoimmunity was excluded based upon CT adrenal image. We failed to examine serum level of adrenal autoantibody. We should have examined adrenal antibody in this subject in order to completely exclude the possibility of autoimmunity.

Taken together, we should bear in mind the possibility of Addison's disease triggered by non-tuberculous mycobacterial infection. We should check other pathogen bacteria carefully even when we exclude the possibility of adrenal tuberculous and MAC pulmonary disease.

#### Abbreviations

ACTH: adrenocorticotropic hormone; CT: computed tomography; MAC: *Mycobacterium avium* complex; PCR: polymerase chain reaction; Mab: *Mycobacterium abscessus*.

#### Acknowledgements

Not applicable.

#### Authors' contributions

H.K., F.T., M.O., Y.I., T.M. substantially contributed to the acquisition, analysis, or interpretation of data for the work. Y.K., M.S., S.N., K.K. critically revised the work for important intellectual content. All authors have read and approved the final manuscript.

#### Funding

The authors declare that there is no funding associated with this manuscript.

#### Availability of data and materials

All datasets on which the conclusions of the paper rely is described in this manuscript and is available to readers.

#### Declarations

##### Ethics approval and consent to participate

Not applicable.

##### Consent for publication

Written informed consent was obtained from the patient for publication of this case report and any accompanying images.

##### Competing interests

We do not have any potential conflicts of interest relevant to this article.

Received: 12 April 2021 Accepted: 16 October 2022

Published online: 23 October 2022

#### References

1. Ma E-S, Yang ZG, Li Y, Guo YK, Deng YP, Zhang XC. Tuberculous Addison's disease: morphological and quantitative evaluation with multidetector-row CT. *Eur J Radiol.* 2007;62:352–8.

- Morimoto K, Hasegawa N, Izumi K, Namkoong H, Uchimura K, Yoshiyama T, et al. A laboratory-based analysis of Nontuberculous mycobacterial lung disease in Japan from 2012 to 2013. *Ann Am Thorac Soc.* 2017;2017(214):49–56.
- Griffith DE, Aksmit T, Brown-Elliott BA, Catanzaro A, Daley C, Gordin F, et al. An official ATS/IDSA statement: diagnosis, treatment, and prevention of Nontuberculous mycobacterial diseases. *Am J Respir Crit Care Med.* 2007;175:367–416.
- Morimoto K, Iwai K, Uchimura K, Okumura M, Yoshiyama T, Yoshimori K, et al. A steady increase in nontuberculous mycobacteriosis mortality and estimated prevalence in Japan. *Ann Am Thorac Soc.* 2014;11:1–8.
- Ide S, Nakamura S, Yamamoto Y, Kohno Y, Fukuda Y, Ikeda H, et al. Epidemiology and clinical features of pulmonary Nontuberculous Mycobacteriosis in Nagasaki, Japan. *PLoS One.* 2015;10:e0128304.
- Nakanaga K, Sekizuka T, Fukano H, Sakakibara Y, Takeuchi F, Wada S, et al. Discrimination of mycobacterium abscessus subsp. massiliense from mycobacterium abscessus subsp. abscessus in clinical isolates by multiplex PCR. *J Clin Microbiol.* 2014;52:251–9.
- Ruger K, Hampel A, Billig S, Rucker N, Suerbaum S, Bang F-C. Characterization of rough and smooth morphotypes of mycobacterium abscessus isolates from clinical specimens. *J Clin Microbiol.* 2014;52:244–50.
- Bala K, Kumari S, Guleria R, Singh U. Recurrent bilateral breast abscess due to mycobacterium abscessus in an immune-competent woman. *BMJ Case Rep.* 2020;13:e235857.
- Gopaldaswamy R, Padmapriyadarsini C, Sekar K, Vijayaragavan V, Bhavani PK, Lokanathan LM, et al. Pulmonary mycobacterium abscessus and response to treatment in an outpatient setting: case series. *Int J Mycobacteriol.* 2021;10:93–7.
- Cheng A, Sun HY, Tsai YT, Lu PL, Lee SS, Lee YT, et al. Longitudinal non-cystic fibrosis trends of pulmonary mycobacterium abscessus disease from 2010 to 2017: spread of the "globally successful clone" in Asia. *ERJ Open Res.* 2021;7:1–11.
- Nagano H, Amitani R, Okamoto N, Yoshida M, Taki M, Hanaoka K, et al. A clinical study of pulmonary mycobacterium abscessus infection. *Kansenshoshi.* 2013;87:726–31.
- Numata T, Inaki S, Kojima J, Ishikawa T, Hara H, Nakayama K, et al. A retrospective study of mycobacterium abscessus. *Kekkaku.* 2017;92:587–93.
- Davidson LB, Nessar R, Kempaiah P, Perkins DJ, Byrd TF. Mycobacterium abscessus glycopeptidolipid prevents respiratory epithelial TLR2 signaling as measured by H $\beta$ D2 gene expression and IL-8 release. *PLoS One.* 2011;6:e29148.
- Harada T, Akiyama Y, Kurashima A, Nagai H, Tsuyuguchi K, Fujii T, et al. Clinical and microbiological differences between mycobacterium abscessus and Mycobacterium massiliense lung diseases. *J Clin Microbiol.* 2012;50:3556–61.

#### Publisher's Note

Springer Nature remains neutral with regard to jurisdictional claims in published maps and institutional affiliations.

#### Ready to submit your research? Choose BMC and benefit from:

- fast, convenient online submission
- thorough peer review by experienced researchers in your field
- rapid publication on acceptance
- support for research data, including large and complex data types
- gold Open Access which fosters wider collaboration and increased citations
- maximum visibility for your research: over 100M website views per year

At BMC, research is always in progress.

Learn more [biomedcentral.com/submissions](https://biomedcentral.com/submissions)

