

Development of acquired factor V inhibitor after treatment with ceftazidime: a case report and review of the literature

Qing-ya Cui¹
Hong-shi Shen¹
Tian-qin Wu¹
Hai-fei Chen¹
Zi-qiang Yu²
Zhao-yue Wang²

¹Department of Hematology, PLA 100th Hospital, ²Jiangsu Institute of Hematology, The First Affiliated Hospital of Soochow University, Suzhou, People's Republic of China

Correspondence: Hong-shi Shen
Department of Hematology,
PLA 100th Hospital,
53 Wuqueqiao Street, Suzhou 215006,
People's Republic of China
Tel +86 512 6506 3541
Fax +86 512 6506 3541
Email shs10@163.com

Zhao-yue Wang
Jiangsu Institute of Hematology, The First
Affiliated Hospital of Soochow University,
188 Shizi Street, Suzhou 215006,
People's Republic of China
Tel +86 512 6778 0872
Fax +86 512 6511 3556
Email zwang11@sina.com

Abstract: We report the case of a 59-year-old Chinese man who showed an asymptomatic coagulation factor V deficiency pattern after second intravenous treatment with ceftazidime. Normal pooled plasma failed to correct the abnormalities in a mixing test, and the presence of factor V inhibitor was confirmed by the Bethesda method. The coagulopathy was not corrected by transfusion of fresh frozen plasma and prothrombin complex concentrate, but rather by treatment with prednisone and withdrawal of dubious drugs. The findings reported here should prompt clinicians to watch for drug-induced coagulation factor deficiency.

Keywords: acquired factor V deficiency, coagulopathy, prednisone

Introduction

Developing an inhibitor against coagulation factor V (FV) is a rare phenomenon, and its clinical manifestations are multifarious, from no bleeding manifestations to potentially life-threatening bleeding.¹ In the past, the appearance of FV inhibitors has been most frequently related to the use of topical bovine thrombin during surgical procedures.² In addition, the appearance of these inhibitors may be associated with idiopathic condition, surgery, transfusion of blood components, drug exposure, bacterial infections, malignancy, and autoimmune disorders.³

A prolongation of both activated partial thromboplastin time (APTT) and prothrombin time (PT) is usually observed in patients with inhibitors against coagulation FV.¹ A mixing test is useful to distinguish acquired from hereditary FV deficiencies. In a mixing test, the patient's plasma is mixed with normal pooled plasma, and coagulation tests that include PT, APTT, and FV are repeated. The failure to correct abnormalities in the coagulation tests suggests the presence of an inhibitor.⁴

Case report

A 59-year-old Chinese man complained of sudden headache, nausea, and vomiting while watching TV and was diagnosed with brainstem hemorrhage by computed tomography scan (Figure 1A). After confirmation of normal clotting screen tests and platelet count, he was successfully treated with lateral ventricle puncture drainage without any hemorrhagic tendency (Figure 1B). Ceftazidime was intravenously administered at 2 g daily to prevent postoperative infection for 3 days. Two weeks after the operation, cerebrospinal fluid and peripheral blood analysis showed elevated white cell count, which could indicate infection, although this patient had no fever. Thereafter, ceftazidime at 2 g every 12 hours was administered to help treat the intracranial infection for 14 days.

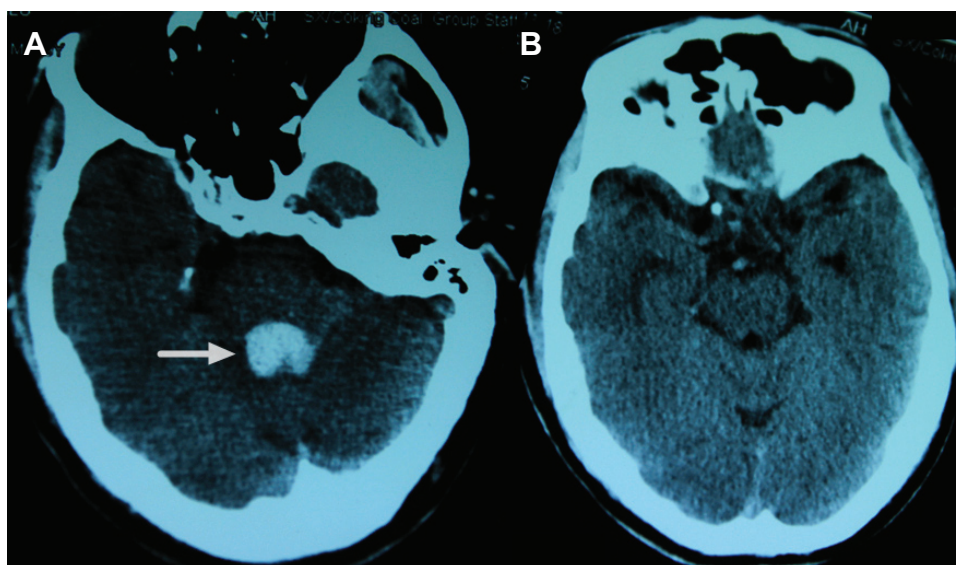


Figure 1 Brain computed tomography (CT) scan showing brain stem hemorrhage preoperatively (arrow) (A), and postoperative CT brain images (B).

However, the results of microbiological tests were negative, and clotting screen test results remained normal. Three weeks after the operation, routine coagulation monitoring showed markedly prolonged PT (45.8 seconds [normal range 11–15.1 seconds]) and APTT (95 seconds [normal range 24–40 seconds]). With the specific etiology unknown, daily transfusion of 5 units of fresh frozen plasma and 800 units of prothrombin complex concentrate for 1 week was administered, but coagulopathy was not improved. He was referred to our hematology clinic for evaluation of markedly prolonged PT (68.3 seconds) and APTT (200 seconds). The patient did not show any clinical sign of ongoing bleeding during his hospitalization. We confirmed that bovine thrombin was not used during surgical procedures. He had a normal diet and had been diagnosed approximately 10 years earlier with essential hypertension, which was controlled by a combination therapy composed of an angiotensin-converting enzyme inhibitor and a long-acting calcium channel blocker. The patient had no personal or family history consistent with a spontaneous bleeding diathesis. The patient's medical history and clinical examination did not indicate the presence of an autoimmune disease.

Clotting screen tests showed significantly prolonged PT and APTT and marked reduction of FV activity, whereas other coagulation indexes including thrombin time, fibrinogen, prothrombin, and factor X, as well as platelet count were normal. A mixing test with equal volume of normal plasma failed to correct prolonged PT, APTT, or reduced FV activity (Table 1). FV inhibitor titer was 10 Bethesda units.

However, the abnormal coagulation was dramatically corrected in 8 days after withdrawal of ceftazidime and treatment with prednisone 30 mg/day. Importantly, clotting test results in this patient remained normal during the 1-year follow-up period. A consent form was obtained from the reported patient.

Discussion

FV deficiency can be inherited or acquired. The patient described here was excluded from the diagnosis of congenital FV deficiency since he showed normal PT and APTT during his first hospitalization. Acquired FV deficiency is rare and

Table 1 Results of clotting screen after admission

Laboratory test	Patient's results (normal values)
PT (s)	54.5 (normal 11–14.5 s)
PT (s) (mixing test)	48.8 (normal 11–14.5 s)
APTT (s)	177.6 (normal 28–40 s)
APTT (s) (mixing test)	127.5 (normal 28–40 s)
TT (s)	11.7 (normal 14–21 s)
Factor V (%)	2 (normal 60–150)
Factor V (%) (mixing test)	2 (normal 60–150)
Factor II (%)	117 (normal 50–150)
Factor VII (%)	90 (normal 60–150)
Factor IX (%)	148 (normal 50–150)
Factor X (%)	89 (normal 50–150)
Fibrinogen (g/L)	5.49 (normal 2.0–4.0)
D-Dimer	1.52 (normal 0.01–0.5 µg/mL)
AT-III (%)	109 (normal 70–130)
Platelet count (/L)	200×10^9 (normal $100\text{--}300 \times 10^9$)
Lupus anticoagulant	Negative

Abbreviations: APTT, activated partial thromboplastin time; AT-III, antithrombin III; PT, prothrombin time; s, seconds; TT, thrombin time.

is associated with the development of inhibitors against FV. FV inhibitors may result from: 1) spontaneous autoantibodies to FV arising in previously healthy patients or in surgery; 2) alloantibodies in congenital FV-deficient patients following plasma infusions; or 3) cross-reacting anti-bovine FV antibodies in patients exposed to topical bovine thrombin preparations.⁵ Bovine thrombin has been used as a topical hemostatic agent in the last 20 years. Interestingly, inhibitory anti-FV antibodies induced by ectogenic FV from bovine thrombin bind to an epitope in the C2 domain of the FVa light chain.⁶ This patient was confirmed not to have been exposed to bovine thrombin after careful assessment of his medical chart. In addition, recent case reports of FV inhibitors in patients have been associated with malignancy, autoimmune diseases, surgery, or antibiotic therapy.⁷ He had no indicator or symptom of malignancy or autoimmune disease. He was not given blood transfusion before the occurrence of coagulopathy. After the appearance of prolonged PT and APTT, unnecessary medications such as dicynone, aminomethylbenzoic acid, vitmorningin K, omeprazole, and amino acids were withdrawn. PT and APTT lengthened even further, and lateral ventricle puncture drainage seemed not to be the cause of coagulopathy.

It is difficult to be certain that ceftazidime played a causative role in the development of the inhibitor in this patient. However, the change, worsening, and improvement of coagulation index during treatment with, and withdrawal of, ceftazidime implies a causal relationship.

The diagnosis of acquired inhibitor against coagulation FV was established based on prolonged PT and APTT, decreased plasma FV level, and no improvement in the

mixing test. The Bethesda assay can confirm the presence and intensity of a FV inhibitor.⁸ Unlike FVIII inhibitors, FV inhibitors inactivate FV almost immediately *in vitro*.⁹ The patient did not appear to have coagulation disorders after first treatment with ceftazidime. During the second treatment, PT and APTT were markedly altered in a short period of time (Figure 2).

The association between bleeding tendency and residual plasma FV activity is uncertain.⁹

The clinical variability may be partially explained by the inaccessibility of the inhibitors to platelet FV since FV in platelet α -granules accounts for 20% of circulating FV.¹⁰ This may explain why platelet concentrate infusions are effective in some patients.¹¹

As yet, there is no standard treatment protocol for FV inhibitors. The therapeutic regimens of acquired FV inhibitors consist of blood component replacement therapy, immunosuppression, high-dose intravenous immunoglobulin, and the use of extracorporeal methods.¹² In this patient, replacement therapy with fresh frozen plasma failed to correct the pronounced coagulopathy. Systemic administration of corticosteroids was successful to correct this ailment. However, the most important action for each patient is to actively investigate the latent cause of coagulopathy and withdraw the dubious drugs. Antibiotics are the most common factors involved in the induction of FV inhibitors. In addition to cephalosporins, other classes of antibiotics constitute a common cause of FV inhibitors.¹² At least six cases of FV inhibitors were attributed to first-generation cephalosporins, and each case was associated with the second-generation (cefmetazole) and third-generation

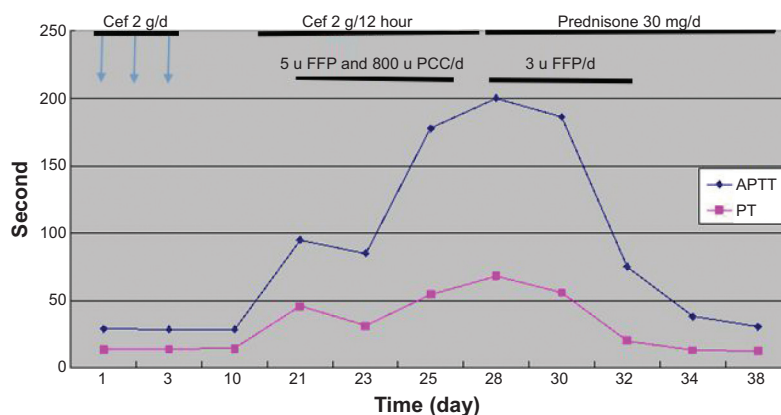


Figure 2 Clinical course of the patient after the operation.

Notes: The patient did not show coagulation disorders after the first ceftazidime injection. After the second treatment with ceftazidime, PT and APTT increased markedly in a short period of time. FFP and PCC did not correct the coagulopathy. Coagulation function tests were recovered after treatment with prednisone and ceftazidime withdrawal.

Abbreviations: APTT, activated partial thromboplastin time; Cef, ceftazidime; d, day; FFP, fresh frozen plasma; PCC, prothrombin complex concentrate; PT, prothrombin time; u, units.

(ceftriaxone) of cephalosporins.^{7,13,14} The emergence of FV deficiency following administration of the third-generation cephalosporin, ceftazidime, has not been reported. We report here the first case of acquired FV inhibitors after second exposure to ceftazidime. It is critical to identify harmful drugs and avoid further exposure to them.

Acknowledgments

This work was supported by the Priority Academic Program Development of Jiangsu Higher Education Institutions, Jiangsu Province's Key Medical Center (ZX201102), and Life and Health Special Funds of the Jiangsu Province's Science and Technology Bureau (BL2012005).

Disclosure

The authors report no conflicts of interest in this work.

References

1. Ang AL, Kuperan P, Ng CH, Ng HJ. Acquired factor V inhibitor. A problem-based systematic review. *Thromb Haemost*. 2009;101(5):852–859.
2. Streiff MB, Ness PM. Acquired FV inhibitors: a needless iatrogenic complication of bovine thrombin exposure. *Transfusion*. 2002;42(1):18–26.
3. Bayani N, Rugina M, Haddad-Vergnes L, Lelong F. High-titer acquired factor V inhibitor responsive to corticosteroids and cyclophosphamide in a patient with two malignant tumors. *Am J Hematol*. 2002;71(1):33–36.
4. Kamal AH, Tefferi A, Pruthi RK. How to interpret and pursue an abnormal prothrombin time, activated partial thromboplastin time, and bleeding time in adults. *Mayo Clin Proc*. 2007;82(7):864–873.
5. Lu L, Liu Y, Wei J, Zhang L, Zhang L, Yang R. Acquired inhibitor of factor V: first report in China and literature review. *Haemophilia*. 2004;10(5):661–664.
6. Ortel TL, Moore KD, Quinn-Allen MA, et al. Inhibitory anti-factor V antibodies bind to the factor V C2 domain and are associated with hemorrhagic manifestations. *Blood*. 1998;91(11):4188–4196.
7. de Raucourt E, Barbier C, Sinda P, Dib M, Peltier JY, Ternisien C. High-dose intravenous immunoglobulin treatment in two patients with acquired factor V inhibitors. *Am J Hematol*. 2003;74(3):187–190.
8. Cohen AJ, Kessler CM. Treatment of inherited coagulation disorders. *Am J Med*. 1995;99(6):675–682.
9. Emori Y, Sakugawa M, Niiya K, et al. Life-threatening bleeding and acquired factor V deficiency associated with primary systemic amyloidosis. *Blood Coagul Fibrinolysis*. 2002;13(6):555–559.
10. Nesheim ME, Nichols WL, Cole TL, et al. Isolation and study of an acquired inhibitor of human coagulation factor V. *J Clin Invest*. 1986;77(2):405–415.
11. Perdekamp MT, Rubenstein DA, Jesty J, Hultin MB. Platelet factor V supports hemostasis in a patient with an acquired factor V inhibitor, as shown by prothrombinase and tenase assays. *Blood Coagul Fibrinolysis*. 2006;17(7):593–597.
12. Wu MT, Pei SN. Development of cephadrine-induced acquired factor V inhibitors: a case report. *Ann Pharmacother*. 2010;44(10):1673–1676.
13. Lebrun A, Leroy-Matheron C, Arlet JB, Bartolucci P, Michel M. Successful treatment with rituximab in a patient with an acquired factor V inhibitor. *Am J Hematol*. 2008;83(2):163–164.
14. Tessier-Marteau A, Croquefer S, Meziani F, Cau S, Asfar P, Macchi L. Acquired factor V inhibitor in a context of sepsis and disseminated intravascular coagulation. *Am J Hematol*. 2010;85(2):145–146.

Drug Design, Development and Therapy

Publish your work in this journal

Drug Design, Development and Therapy is an international, peer-reviewed open-access journal that spans the spectrum of drug design and development through to clinical applications. Clinical outcomes, patient safety, and programs for the development and effective, safe, and sustained use of medicines are a feature of the journal, which

Submit your manuscript here: <http://www.dovepress.com/drug-design-development-and-therapy-journal>

Dovepress

has also been accepted for indexing on PubMed Central. The manuscript management system is completely online and includes a very quick and fair peer-review system, which is all easy to use. Visit <http://www.dovepress.com/testimonials.php> to read real quotes from published authors.