

## A rare case of tertiary syphilis spondylodiscitis of the upper cervical spine: Diagnostic and therapeutic complexity, review of literature

Valerio Cipolloni,<sup>1</sup> Luigi Aurelio Nasto,<sup>2</sup> Luca Piccone,<sup>1</sup>

Domenico Alessandro Santagada,<sup>1</sup>

Virginia Sangiorgi,<sup>1</sup> Roberto Pola,<sup>3</sup>

Antonello Leone,<sup>4</sup> Pola Enrico<sup>1</sup>

<sup>1</sup>Spine Division, Department of Orthopaedics and Traumatology, A. Gemelli University Hospital, Catholic University of Rome; <sup>2</sup>Department of Pediatric Orthopaedics, IRCCS Istituto "G. Gaslini" Children's Hospital, Genova; <sup>3</sup>Department of Internal Medicine, Vascular Diseases, A. Gemelli University Hospital, Catholic University of Rome; <sup>4</sup>Department of Radiology and Diagnostic Imaging, A. Gemelli University Hospital, Catholic University of Rome, Italy

diagnosed. Primary syphilis presents with a single skin ulcer lesion or chancre. In secondary syphilis a diffuse skin rash with mucocutaneous lesions and lymphadenopathy is observed. Finally, in tertiary syphilis widespread granulomatous lesions (*i.e.* gummas) lead to end organ damage (*e.g.* hear failure). In its late presentation, syphilis can also cause damage to the central nervous system presenting with cranial nerve dysfunction, meningitis, stroke, loss of vibration sense, auditory or ophthalmic abnormalities.<sup>1,2</sup> The World Health Organization (WHO) has registered 5-6 million new cases of syphilis worldwide in 2012, affecting both teenagers and adults.<sup>3</sup> Nevertheless, there is a paucity of reports describing spinal involvement in tertiary syphilis. Syphilitic spinal lesions present as erosive bone lesions often simulating spondylodiscitis or cancer. Diagnosis is delayed and difficult on an imaging ground only. In this article we describe clinical features, diagnosis and treatment of a case of cervical osteolytic lesions secondary to tertiary syphilis in a young patient over the age of 40 and a review of literature.

### Abstract

Syphilis is a sexually transmitted disease caused by the spirochetes *Treponema pallidum*. Syphilitic spinal lesions present as erosive bone lesions often simulating spondylodiscitis or cancer. In this article we describe a rare case of cervical osteolytic lesion from tertiary syphilis. A 45-year-old male with axial neck pain, without fever presented with an isolated osteolytic lesion at C3. Tuberculous spondylitis was initially suspected. A new CT and contrast enhanced MRI of the cervical spine and of the neck showed an extension of the bone lesion at C3 with bilateral lymphadenomegaly. To confirm the diagnosis of tertiary syphilis, US-guided biopsy of the lymph nodes was performed. The patient was treated with i.m. benzylpenicillin 2.4 MIU and the follow-up showed clinical and radiological resolution of the condition. The aim of this case report is to raise awareness of tertiary syphilis in the differential diagnosis of lytic lesions of the spine among the spinal community.

### Introduction

Syphilis is a sexually transmitted disease caused by the spirochetes *Treponema pallidum*. Clinical signs and symptoms depend on which stage the condition is

### Case Report

A 45 years old man was admitted to undergo further elective diagnostic studies for an anterior osteolytic lesion of C3 (priorly seen on MRI and cervical CT studies). Patient had been complaining of axial neck pain and left paraspinal muscle spasms following physical activity (swimming) for the last 3 months. He also reported chronic unproductive cough associated with episodes of profuse sweating without fever. Neck pain had worsened over the course of the last month to the point that the patient had to stop any physical activity and working. Furthermore, he also complained of headache, dysphagia and odynophagia with a nevralgic *à poussée* pain at the cervical level. Three months before the onset of neck pain he suffered from truncal and plantar macular skin rashes which had been misdiagnosed as pityriasis rosea. Patient had a non-contributory medical history, on examination he had stable vital signs, and cardiac, pulmonary, and neurological clinical exams were normal. The musculoskeletal physical exam showed axial cervical pain and bilateral tenderness of cervical paraspinal muscles with segmental hypomobility and antalgic rigidity. Lhermitte, Spurling, and O'Donoghue signs were negative. Bone scintigraphy performed during the admission showed no pathological uptake of the C3

Correspondence: Enrico Pola, Spine Division, Department of Orthopaedics and Traumatology, A. Gemelli University Hospital, Catholic University of Rome, Rome 00168, Italy.

Tel.: +39.06-30154326 - Fax: +39.06-3051161.

E-mail: enrico.pola@tiscali.it

Key words: Tertiary syphilis; *Treponema pallidum*; Osteolytic spinal lesion; VDRL test; Benzylpenicillin.

Contributions: VC and LAN contributed equally to this work, generated the figures and wrote the manuscript; LP and DAS contributed to the writing of the manuscript; EP and AL reviewed and approved the manuscript.

Conflict of interest: The authors declare no conflict of interest.

Funding: none.

Availability of data and materials: address correspondence and reprint requests to Enrico Pola.

Ethics approval and consent to participate: Not applicable.

Informed consent: Not applicable.

Received for publication: 11 April 2020.

Accepted for publication: 17 June 2020.

This work is licensed under a Creative Commons Attribution NonCommercial 4.0 License (CC BY-NC 4.0).

©Copyright: the Author(s), 2020

Licensee PAGEPress, Italy

Orthopedic Reviews 2020; 12(s1):8675

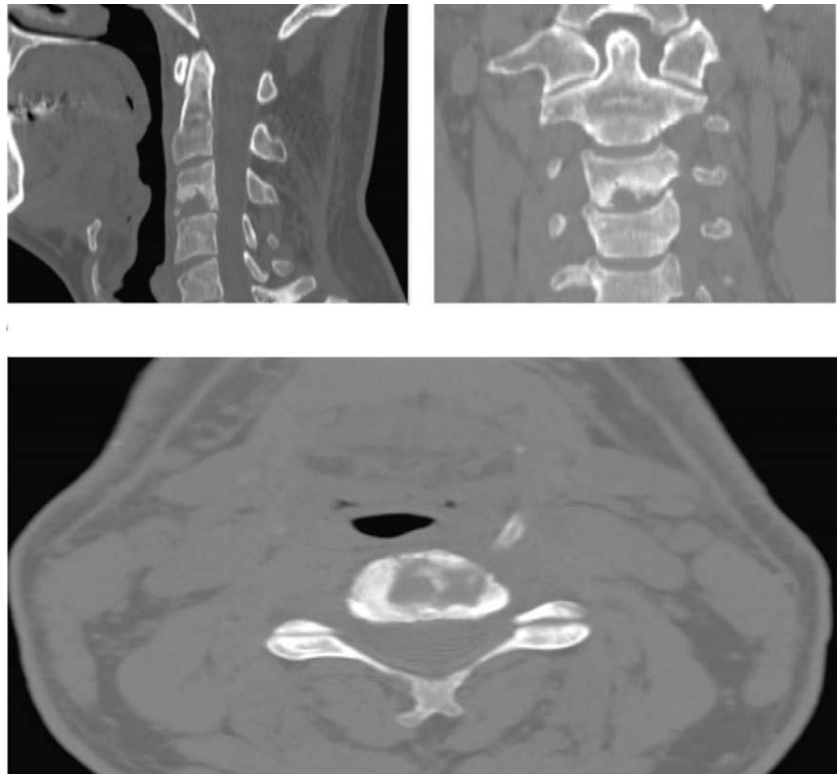
doi:10.4081/or.2020.8675

osteolytic lesion. Contrast enhanced MRI and CT scans of the head and spine demonstrated an increase in the extension of the erosive bony lesion at the level of the inferior endplate of C3 in the absence of abscessual lesions of the other cervical segments (Figures 1 and 2). Bilateral lymphadenomegaly was observed at the level of the submandibular, palatine, lingual tonsils and digastric plexus. Due to the continuous pain, patient was prescribed a cervical hard collar for pain comfort. Laboratory tests including serum dosage of ACE and lysozyme, tumor markers, Wright test, blood cultures and the serum/antigenic screening for HIV and hepatitis were negative. VDRL test was positive, as well as non-treponemal test (RPR 1/16) and the treponemal test (RPR 1/5120). To confirm diagnosis, US guided biopsy of the submandibular and digastric lymph nodes

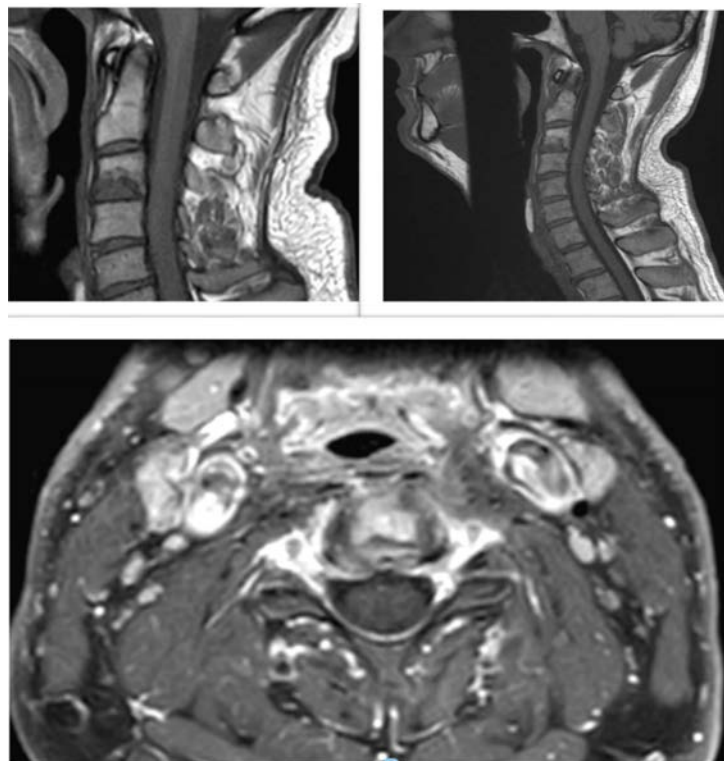
was performed. Pathological exam demonstrated a picture of chronic granulomatous inflammation with necrotic and degenerative fibrocartilaginous and bone tissue. *Treponema pallidum* infection was confirmed by identification of spirochetes at dark field optic microscopy on reactive lymph node tissue. Treatment consisted of i.m. benzylpenicillin 2.4 mu once a week for three weeks in an outpatient setting. At two months follow-up, the patient had clinically recovered with gradual attenuation of axial neck pain and return to working and sport activities. A repeat CT and MRI examination of the head and neck showed resorption of the erosive lesion of C3 and of the enlarged lymph nodes (Figure 3).

## Discussion

Historically, the incidence of syphilis significantly decreased following the introduction of the antibiotic therapy with penicillin, which is able to halt progression of the disease in the first two stages.<sup>4,5</sup> This was also possible thanks to the increased awareness of STDs among the general public. However, the recent increase of the sexually transmitted diseases due to sexual promiscuity, little use of contraceptive globally and decreased awareness of the risk of transmission of HIV in the individuals subjected to antiretroviral therapy has led to a resurgence of subclinical syphilis.<sup>6-10</sup> Tertiary form of syphilis is particularly difficult to diagnose due to the slow clinical evolution of the symptoms and scarce signs at the onset of the condition. Tertiary syphilis can present with an incubation period that varies between 3 and 15 years after an acute infection. Tertiary syphilis describes patients with late syphilis who have symptomatic manifestation involving the cardiovascular system or gummatous disease (granulomatous disease of the skin and subcutaneous tissues, bones or viscera). The understanding of *T. pallidum* pathophysiology is crucial to the understanding of the clinical, histopathological and molecular characteristics of the disease. Cellular immunity is important for control of syphilis in experimental infection and probably contributes to the pathogenesis of tertiary syphilis.<sup>11</sup> The prolonged latent period that is fundamental of most types of late syphilis suggest that immune mechanisms may be involved in one of two ways. Waning immunity with aging may facilitate recrudescence of a small number of treponemes that had survived in sequestered sites. Alternatively, a partially immune hypersensitive host may react to the presence



**Figure 1.** CT scan of the cervical spine in the sagittal, coronal, and axial plane showing an osteolytic lesion of the lower half of the vertebral body of C3 before definitive diagnosis was made and treatment was started.

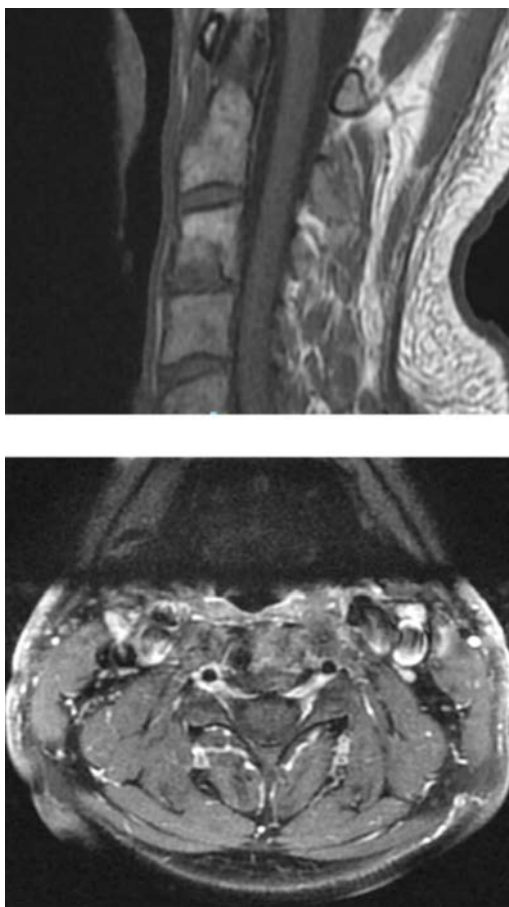


**Figure 2.** Magnetic Resonance imaging (MRI) of the cervical spine in the sagittal and axial plane revealed bone destruction and erosion in the anterior-inferior part of the body of C3, with enhancement in T1-weight, and STIR sequences before treatment.

of treponemes, engendering a chronic inflammatory response. Gummas often involving the skin, viscera, or other tissue (e.g. bone, brain, abdominal viscera), are characterized pathologically by the presence of granulomas, a finding that is consistent with a cellular hypersensitivity reaction.<sup>12</sup>

Incidence of spinal involvement is unknown due to the lack of systematic reporting of this condition in literature, in fact there are only occasional case report. Although diagnosis can be made by serologic tests, erosive lesions found on CT and MRI scan remain hard to interpret and easily mistaken with other condition like Pott's disease or spondylitis due to low virulence common germs. The radiologic pattern of bone syphilis includes osteolytic, erosive or destructive lesions and subchondral sclerosis which is caused by chronic erosion by gummas. It is described in literature a case of polyostotic tertiary syphilis with involvement of lumbar spine and bilateral Charcot's arthropathy of the tibiotalar and knee joints, in an immunocompetent 44-years-old patient.<sup>13</sup> The patient was treated initially with surgery

through a posterior fusion and decompression of the osteolytic lesion in the lumbar spine due to symptomatic spinal canal stenosis, and later with medical therapy (only after the result of the intraoperative biopsy established the correct diagnosis) with intramuscular penicillin. Other authors reported a case of polyostotic tertiary syphilis with involvement of the dens of the axis and tibia in a homosexual, HIV positive, 24-years-old patient, successfully treated with farmacological therapy. In this case report we presented a rare case of spondylitis due to *Treponema Pallidum* in a 45 years old, immuno-competent patient, in the absence of any epidemiologic risk factors related to the infection. The erosive lesion could have been mistaken for secondary lesion of chronic inflammatory lesion by low virulence germs.<sup>14</sup> However, the results of the serologic test guided execution of a confirmatory lymph node biopsy which clarified final diagnosis of the condition. Intramuscular penicillin therapy is the currently accepted gold standard for treatment of tertiary syphilis and was able to stop progression of the condition in our patient.



**Figure 3.** Magnetic Resonance imaging (MRI) of the cervical spine in the sagittal and axial plane at the end of the medical treatment demonstrated resolution of the osteolytic lesion of the lower half of C3 vertebral body.

## Conclusions

This case report must raise awareness of tertiary syphilis in the differential diagnosis of chronic erosive lesions of the spine among spinal community. Syphilis has also been known as “the great imitator” due to the scarce clinical findings and overlapping signs and symptoms with other conditions. It should always be suspected in young, sexually active patients, even if immunocompetent and with no other risk factors for this disease.

## References

1. Clement M, Okeke NL, Hicks CB. Treatment of syphilis: a systematic review. *JAMA* 2014;312:1905-17.
2. Workowski KA, Bolan GA. Sexually transmitted diseases treatment guidelines, 2015. *MMWR Recomm Rep* 2015;64:1-137.
3. Newman L, Rowley J, Vandem Hoom S. et al. Global Estimates of the Prevalence and Incidence of Four Curable Sexually Transmitted Infections in 2012 Based on Systematic Review and Global Reporting. *PLoS One* 2015;10: e0143304.
4. Lyubomir A, Dourmishev DM, Assen L. Syphilis: uncommon presentations in adults. *Clin Dermatol* 2005;23:555-64.
5. Hercogova J, Vanousova D. Syphilis and borreliosis during pregnancy. *Dermatol Ther* 2008;21:205-9.
6. Andersen PH. No 23- 2009. *Statens Serum Institut*, 2009.
7. Søborg B, Cowan S, Hoffmann S, et al. No 35a – 2011. *Statens Serum Institut*, 2011.
8. Savage EJ, Hughes G, Ison C, Lowndes CM. Syphilis and gonorrhoea in men who have sex with men: a European overview. *Euro Surveill* 2009;14:19417.
9. Wicher K, Wicher V, Nakeeb SM, Dubinski S. Studies of rabbit testes infected with *Treponema pallidum*. I Immunopathology. *Br J Vener Dis* 1983;59:349-58.
10. Gaudio PA. Update on ocular syphilis. *Curr Opin Ophthalmol*, 2006;17:562-6.
11. Flood JM, Weinstock HS, Guroy ME. et al. Neurosyphilis during the AIDS epidemic, San Francisco, 1985-1992. *J Infect Dis* 1998;177:931-40.
12. Firlag-Burkacka E, Swiecki P, Cielniak I. et al. High frequency of neurosyphilis in HIV-positive patients diagnosed with early syphilis. *HIV Med* 2016;17:323-6.
13. Bai Y, Niu F, Sha H. et al. Tertiary syphilis in the lumbar spine: a case report . *BMC Infect Dis* 2017;17:513.
14. Fabricius T, Winther C, Ewertsen C. et al. Osteitis in the dens of axis caused by *Treponema pallidum*. *BMC Infect Dis* 2013;13:347.