

Life-threatening large subcutaneous hematoma after minor head trauma: A young female patient who was suspected of having new Ehlers–Danlos syndrome

So Fujimoto, Takahiro Ota, Tohru Mizutani¹

Department of Neurosurgery, Tokyo Metropolitan Tama Medical Center, ¹Department of Neurosurgery, Faculty of Medicine, Showa University, Tokyo, Japan

ABSTRACT

Life-threatening large subcutaneous hematomas after minor injury are rare clinical states for young people; however these patients may have hidden diseases, which can cause a tendency to bleed. A 31-year-old woman visited our hospital after minor injury. The first computed tomography (CT) scan revealed a small subcutaneous hematoma, but her head bulged and the second CT scan revealed her subcutaneous hematoma had become enlarged. Two surgeries were needed to stop the bleeding and. Though she received intensive care, she died 48 days after onset. The new Ehlers–Danlos syndrome (EDS), known as EDS Kosho type (EDSKT), is a connective tissue disease, in which patients often experience large subcutaneous hematomas. We suspected our patient had EDSKT because her clinical features were compatible with this syndrome. Our findings support the notion that large subcutaneous hematomas in young patients with connective tissue disease can be fatal; a careful follow-up is required.

Key words: Ehlers–Danlos syndrome Kosho type, large subcutaneous hematoma, minor head injury, tendency of bleeding

Introduction

Life-threatening large subcutaneous hematomas after minor head injury are rare clinical states for young people while taking anticoagulant or antiplatelet agents is the major cause of large subcutaneous hematomas in elderly people.^[1-3] The causes of large subcutaneous hematomas in young patients considered to be hereditary connective tissue disease, neurofibromatosis I, and Ehlers–Danlos syndrome (EDS).^[4]

In this report, we describe a rare case of a large subcutaneous hematoma in a young female patient who was suspected of

having connective tissue disease, and we discuss the cause and treatment of her large subcutaneous hematoma.

Case Report

History and presentation

A 31-year-old woman visited our emergency room after a minor hit to her occipital region. At the first examination, her consciousness was clear without neurological deficits. Computed tomography (CT) scans showed only a subcutaneous hematoma in her occipital region [Figure 1a]. However 2 h later, her consciousness got worse drastically and second CT scan revealed remarkable enlargement of her subcutaneous hematoma [Figure 1b and c]. Her scalp ruptured leading to massive external bleeding, and she went into hemorrhagic shock, so an emergent surgery was performed to stop the bleeding.

First surgery

After the evacuation of the hematoma, the sources of the bleeding were identified as the occipital artery and the entire surface of the subcutaneous connective tissue. They were cauterized, and the bleeding was controlled. We resected her extended skin for effective striction. The next day, soon after the removal of her bandage, her head bulged again, and a second emergent surgery was performed.

Access this article online	
Quick Response Code:	Website: www.asianjns.org
	DOI: 10.4103/1793-5482.154985

Address for correspondence:

Dr. Takahiro Ota, Department of Neurosurgery, Tokyo Metropolitan Tama Medical Center, 2-8-29 Musashidai, Fuchu-shi, Tokyo 183-8524, Japan. E-mail: toota-tky@umin.org

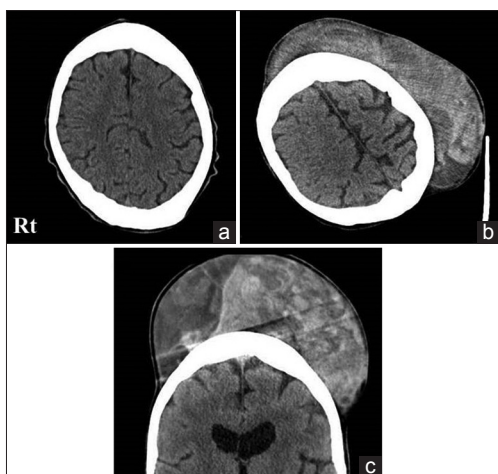


Figure 1: (a) Computed tomography (CT) scan taken up on admission showing a small subcutaneous hemorrhage. (b) Axial CT scan taken 2 h after the first CT scan. (c) Coronal CT scan taken on the same time as (b)

Second surgery

Diffuse bleeding from subcutaneous connective tissues continued. They were cauterized entirely, and a collagen sheet coated with bovine thrombin, and bovine aprotinin (TachoComb®) was used [Figure 2b]. Her extended skin was cut off adequately by plastic surgeons and wrapped in bandages again [Figure 2c].

Postoperative course

After the second surgery, her subcutaneous hematoma did not expand. She received blood transfusions in the intensive care unit but bled from her back to the thoracic cavity. She died of cardiac tamponade 48 days after onset.

Our patient was suspected of having a connective tissue disease because her clinical findings suggested multiple system fragilities. She had hypertelorism, short and downslanting palpebral fissures, a long philtrum, and thin upper lip. Her fingers were slender, and her vertebral column showed the scoliosis. In addition, she repeated dislocations of the shoulder joint and diverticulitis. Autopsy findings showed hyperextension of the skin, a massive subcutaneous hemorrhage and repeated dislocations of the shoulder joint. Autopsy diagnosis was compatible with EDS.

Discussion

Ehlers–Danlos syndrome is a heritable connective tissue disease characterized by joint and skin laxity, and tissue fragility. EDS type IV, the vascular type, was suspected as a cause of an abnormal tendency to bleed. Our patient's clinical symptoms and findings of easy bruising, facial features, and rupture of the arteries are included as criteria of EDS type IV. However, the arteries that rupture in EDS type IV patients are usually major blood vessels or intracranial vessels, not the

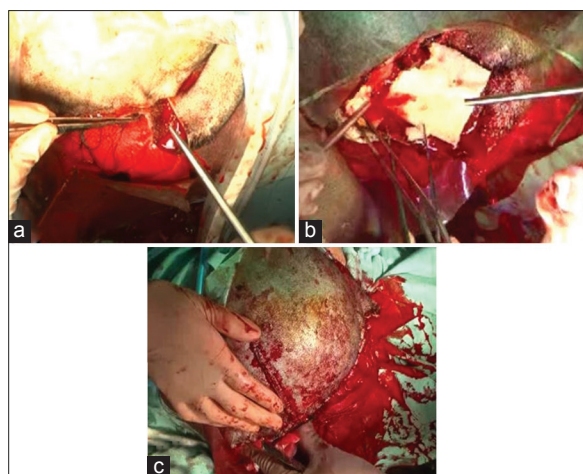


Figure 2: (a) First surgery: Abnormal skin hyperextensibility was observed. (b) Second surgery: TachoComb® was placed on the bleeding surface. (c) The patient's skin was trimmed by plastic surgeons

occipital artery. Hyperextensibility of the skin is uncommon in patients with EDS type IV patients.^[5]

Recently, a new type of EDS (EDS Kosho type [EDSKT]) was reported, the main feature of which was the recurrence of large subcutaneous hematomas.^[6] Patients with EDSKT are characterized by distinct craniofacial features, multiple congenital contractures, progressive joint and skin laxity, and multisystem fragility-related manifestations, as were observed in our patient. Thus, EDSKT was a possible diagnosis for our patient.

Genetic testing is needed to make a definite diagnosis of EDSKT. Dermatan 4-O-sulfotransferase 1 (D4ST1) is a regulatory enzyme in glycosaminoglycan biosynthesis. Carbohydrate sulfotransferase 14, localized on 15q12, is the gene encoding D4ST1. D4ST1 deficiency causes EDSKT.^[7] Unfortunately, our patient's family would not permit us to perform the test.

A large subcutaneous hematoma over the head, which is the most serious complication in patients with EDSKT, was reported in five out of seven patients.^[8] Most patients needed blood transfusions, emergent surgical treatments, and admission to the intensive care unit [Table 1].

In the second operation, we used TachoComb® and obtained good hemostatic efficacy. Placing TachoComb® over the surface of subcutaneous tissue has been reported effective and safe.^[9] Using these hemostatic materials can be helpful when it is difficult to stop the bleeding in patients with connective tissue disease.

Our findings suggest that caution should be taken if patients with head trauma have the craniofacial or skin features of EDS, because these patients can develop massive subcutaneous hematomas. In particular, for patients with EDSKT, where large

Table 1: Clinical features of large subcutaneous hematoma in EDSKT patients

Patient	Age of onset	Location of hemorrhage	Admission in ICU	Surgical drainage	Blood transfusion	Intranasal DDAVP	Hemoglobin concentration
1	4	Head	-	-	+	-	-
	6	Head	-	-	+	-	-
	7	Buttock	-	+	-	+	-
	12	Head	+	-	-	+	7.7
2	6	Knee	-	+	-	-	-
	11	Head	-	+	+	-	-
3	8	Head	-	+	+	-	-
4	23	Buttock	-	-	+	+	4.9
5	6	Buttock	-	-	-	-	-
	16	Calf	+	-	+	-	-
6	3	Head	-	-	-	-	-
Our patient	31	Head	+	+	+	-	4.0

DDAVP – 1-desamino-8-D-arginine vasopressin; ICU – Intensive Care Unit; EDSKT – Ehlers-Danlos syndrome Kosho type

subcutaneous hematoma can be fatal, a careful follow-up is required even after minor head injury.

References

- Hagiwara A, Matsuda T, Shimazaki S. Life-threatening subcutaneous hemorrhage following minor blunt trauma in an elderly patient taking ticlopidine and aspirin: A case report. *Emerg Radiol* 2005;12:47-9.
- Hudcova J, Talmor D. Life-threatening hemorrhage following subcutaneous heparin therapy. *Ther Clin Risk Manag* 2009;5:51-4.
- Incalzi RA. Life-threatening subcutaneous hematoma caused by an axillary pad in an anticoagulated patient. *South Med J* 2000;93:315-6.
- Baek SH, Kim JH, Kim JS, Han SB, Cho JS, Yoon YH, et al. Recurrent massive subcutaneous hemorrhage in neurofibromatosis type 1: A case report. *J Korean Med Sci* 2007;22:728-30.
- Pepin M, Schwarze U, Superti-Furga A, Byers PH. Clinical and genetic features of Ehlers-Danlos syndrome type IV, the vascular type. *N Engl J Med* 2000;342:673-80.
- Kosho T, Miyake N, Hatamochi A, Takahashi J, Kato H, Miyahara T, et al. A new Ehlers-Danlos syndrome with craniofacial characteristics, multiple congenital contractures, progressive joint and skin laxity, and multisystem fragility-related manifestations. *Am J Med Genet A* 2010;152A: 1333-46.
- Miyake N, Kosho T, Mizumoto S, Furuichi T, Hatamochi A, Nagashima Y, et al. Loss-of-function mutations of CHST14 in a new type of Ehlers-Danlos syndrome. *Hum Mutat* 2010;31:966-74.
- Shimizu K, Okamoto N, Miyake N, Taira K, Sato Y, Matsuda K, et al. Delineation of dermatan 4-O-sulfotransferase 1 deficient Ehlers-Danlos syndrome: Observation of two additional patients and comprehensive review of 20 reported patients. *Am J Med Genet A* 2011;155A: 1949-58.
- Ofose FA, Crean S, Reynolds MW. A safety review of topical bovine thrombin-induced generation of antibodies to bovine proteins. *Clin Ther* 2009;31:679-91.

How to cite this article: Fujimoto S, Ota T, Mizutani T. Life-threatening large subcutaneous hematoma after minor head trauma: A young female patient who was suspected of having new Ehlers-Danlos syndrome. *Asian J Neurosurg* 2015;10:148-50.
Source of Support: Nil, **Conflict of Interest:** None declared.