

Linked Double-Row Equivalent Arthroscopic Rotator Cuff Repair Leads to Significantly Improved Patient Outcomes

Atsushi Endo,* MD, MPH, Paul Hoogervorst,* MD, Conrad Safranek,[†] BS, Kyle R. Sochacki,[‡] MD, Marc R. Safran,[‡] MD, Seth L. Sherman,[‡] MD, and Joseph Donahue,*[§] MD

Investigation performed at Sports Orthopedic and Rehabilitation, Redwood City, California, USA

Background: Biomechanical studies have demonstrated that arthroscopic rotator cuff repair using a linked double-row equivalent construct results in significantly higher load to failure compared with conventional transosseous-equivalent constructs.

Purpose: To determine the patient-reported outcomes (PROs), reoperation rates, and complication rates after linked double-row equivalent rotator cuff repair for full-thickness rotator cuff tears.

Study Design: Case series; Level of evidence, 4.

Methods: Consecutive patients who underwent linked double-row equivalent arthroscopic rotator cuff repair with minimum 2-year follow-up were included. The primary outcome was the American Shoulder and Elbow Surgeons (ASES) score at final follow-up. Secondary outcomes included the Simple Shoulder Test (SST), shortened Disabilities of the Arm, Shoulder and Hand (QuickDASH) questionnaire, visual analog scale (VAS), reoperations, and complications. Clinical relevance was defined by the minimally clinically important difference (MCID). Comparisons on an individual level that exceeded MCID (individual-level scores) were deemed clinically relevant. Comparisons between preoperative and postoperative scores were completed using the Student *t* test. All *P* values were reported with significance set at *P* < .05.

Results: A total of 42 shoulders in 41 consecutive patients were included in this study (21 male patients [51.2%]; mean age, 64.5 ± 11.9 years; mean follow-up, 29.7 ± 4.5 months). All patients (100%) completed the minimum 2-year follow-up. The rotator cuff tear measured on average 15.2 ± 8.9 mm in the coronal plane and 14.6 ± 9.8 mm in the sagittal plane. The ASES score improved significantly from 35.5 ± 18.2 preoperatively to 93.4 ± 10.6 postoperatively (*P* < .001). The QuickDASH (*P* < .001), SST (*P* < .001), and VAS (*P* < .001) scores also significantly improved after surgery. All patients (42/42 shoulders; 100%) achieved clinically relevant improvement (met or exceeded MCID) on ASES and SST scores postoperatively. There were no postoperative complications (0.0%) or reoperations (0.0%) at final follow-up.

Conclusion: Arthroscopic repair of full-thickness rotator cuff tears with the linked double-row equivalent construct results in statistically significant and clinically relevant improvements in PRO scores with low complication rates (0.0%) and reoperation rates (0.0%) at short-term follow-up.

Keywords: rotator cuff repair; arthroscopy; linked suture anchors; outcomes

Rotator cuff disease is one of the most common causes of shoulder dysfunction, with prevalence rates ranging from 13% to 50% with increasing age.^{45,46} The rotator cuff functions to provide active shoulder motion and dynamic glenohumeral stability. As such, anatomic repair of symptomatic rotator cuff tears is often necessary to restore normal shoulder biomechanics.^{13,19} Despite several advances in rotator cuff repair over the past several years, studies^{1,5,15,17,18,22,31} have demonstrated inconsistent outcomes, with failure rates of up to 94% in some patient populations.

In order to improve success rates, several techniques have been described for rotator cuff repair. Biomechanical studies^{2,23,29,32,34-36} have demonstrated that double-row, transosseous-equivalent repairs are superior to single-row repairs that only provide partial footprint restoration. These biomechanical advantages have also translated to improved clinical function and histologic healing in patients undergoing double-row rotator cuff repair.^{8,11,30} However, these come at a higher cost because of the increased number of anchors used.

In order to reduce cost and anchor usage and improve construct strength, several studies have reported on the biomechanical advantages of medial row linkage in rotator cuff repair; the medial anchor linkage functions to provide increased load sharing, contact area, and stability of the

The Orthopaedic Journal of Sports Medicine, 8(7), 2325967120938311
DOI: 10.1177/2325967120938311
© The Author(s) 2020

This open-access article is published and distributed under the Creative Commons Attribution - NonCommercial - No Derivatives License (<https://creativecommons.org/licenses/by-nc-nd/4.0/>), which permits the noncommercial use, distribution, and reproduction of the article in any medium, provided the original author and source are credited. You may not alter, transform, or build upon this article without the permission of the Author(s). For article reuse guidelines, please visit SAGE's website at <http://www.sagepub.com/journals-permissions>.

repair.^{3,7,12,16,24,37} However, these techniques often require arthroscopic knot tying to link the 2 medial anchors. This knot prevents the linked sutures from sliding freely, thus inhibiting load sharing and proper tensioning between the 2 anchors of the medial row.³⁷

A linked double-row equivalent rotator cuff repair has been developed to maintain the potential advantage of linked medial row anchors and allow for adequate tensioning and force distribution across the repair. A recent biomechanical study using bovine tendons demonstrated that this linked double-row equivalent construct had significantly higher load to failure and increased survivorship with cyclic loading compared with conventional transosseous-equivalent techniques.⁴¹ Despite the biomechanical advantages, there are limited data on the clinical outcomes using these anchors. The purpose of this study was to determine the patient-reported outcomes (PROs), reoperation rates, and complication rates after linked double-row equivalent rotator cuff repair for full-thickness rotator cuff tears. We hypothesized that this technique would result in statistically significant and clinically relevant improvement in PROs, with low reoperation and complication rates.

METHODS

Institutional review board approval was obtained for this retrospective review of consecutive patients who underwent linked double-row equivalent arthroscopic rotator cuff repair from April 2015 to April 2016 by a single fellowship-trained orthopaedic surgeon (J.D.). Patients with clinical signs and imaging findings consistent with a diagnosis of full-thickness supraspinatus and/or infraspinatus tear and who had completed 2-year minimum follow-up were included in the study. All (100%) patients were initially treated nonoperatively with activity modification, home exercise program, or formal physical therapy depending on patient preference for a minimum of 6 weeks after presentation. Patients who continued to have pain or functional deficits were then indicated for surgical repair of their rotator cuff. Patients with irreparable rotator cuff tears were excluded from this study, as they did not undergo rotator cuff repair. Patients with complete or incomplete subscapularis and/or teres minor tears were also excluded.

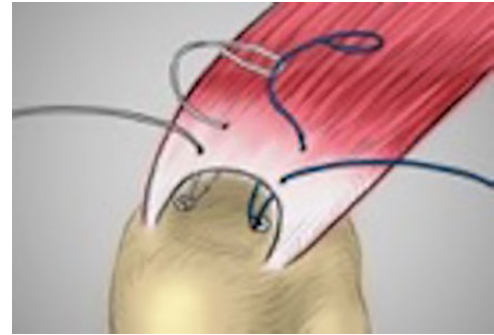


Figure 1. A pass is made with 1 suture from either anchor approximately 5 mm medially into the rotator cuff. One of these sutures has a loop where the suture from the other anchor can be shuttled through.

Surgical Technique

All patients were positioned in the lateral decubitus position and underwent diagnostic shoulder arthroscopy, with confirmation of full-thickness supraspinatus and/or infraspinatus tears. A subacromial decompression was performed followed by preparation of the rotator cuff footprint. The rotator cuff was repaired according to a previously described method.⁴¹ Two double-loaded 5.5-mm suture anchors (Stabili-lynx) were inserted at the articular margin of the greater tuberosity (1 anterior and 1 posterior) to function as the medial row. Each anchor is double loaded with nonabsorbable No. 2 braided polyester suture. One suture from each anchor was removed, leaving each anchor with a single suture to be used during the rotator cuff repair.

A pass was made with 1 suture from either anchor approximately 5 mm medially into the rotator cuff using an arthroscopic suture passer (Figure 1). The sutures have a loop where the suture from the other anchor can be shuttled through. The suture with the loop was pulled, and the contralateral suture was shuttled through the path of that suture pass and then through the suture anchor, thereby creating a knotless medial bridge (Figure 2). Next, the suture ends that remained were each passed approximately 5 mm lateral to the anchors. The lateral suture ends were then tied using an arthroscopic sliding knot, thereby creating a lateral knotted bridge in a double-row configuration (Figure 3). The end result was a knotless medial

[§]Address correspondence to Joseph Donahue, MD, Department of Orthopaedic Surgery, Stanford University, 450 Broadway, M/C 6342, Redwood City, CA 94063, USA (email: donahue@stanfordalumni.org).

*Sports Orthopedic and Rehabilitation, Redwood City, California, USA.

†Stanford University, Bioengineering, Stanford, California, USA.

‡Department of Orthopaedic Surgery, Stanford University, Redwood City, California, USA.

Final revision submitted February 23, 2020; accepted March 26, 2020.

One or more of the authors has declared the following potential conflict of interest or source of funding: M.R.S. has received research support from Smith & Nephew; consulting fees from Anika Therapeutics, Linvatec, Medacta, and Smith & Nephew; speaking fees from Linvatec, Medacta, and Smith & Nephew; and royalties from DJO, Saunders/Mosby-Elsevier, Smith & Nephew, Stryker, and Wolters Kluwer Health-Lippincott Williams & Wilkins; and has stock/stock options in Biomimmedica. S.L.S. has received research support from Arthrex, grant support from DJO, educational support from Elite Orthopaedics, hospitality payments from Smith & Nephew, and consulting fees from Arthrex, Ceterix Orthopaedics, ConMed Linvatec, Flexion Therapeutics, GLG Consulting, JRF Ortho, Moximed, Olympus, RTI Surgical, and Vericel. J.D. has received educational support from Arthrex and consulting fees from DePuy; and has stock/stock options in Stabili-lynx. AOSSM checks author disclosures against the Open Payments Database (OPD). AOSSM has not conducted an independent investigation on the OPD and disclaims any liability or responsibility relating thereto.

Ethical approval for this study was obtained from Stanford University (protocol No. 53266).

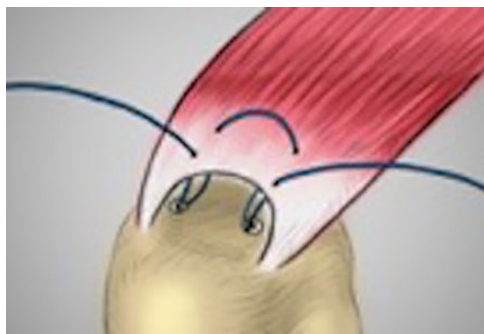


Figure 2. The suture with the loop was pulled, and the contralateral suture was shuttled through the path of that suture pass and then through the suture anchor, thereby creating a knotless medial bridge.

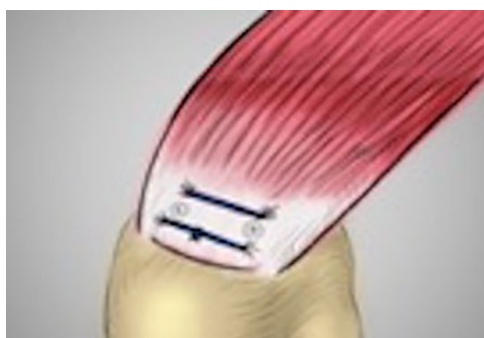


Figure 3. The suture ends that remained were each passed approximately 5 mm lateral to the anchors. The lateral suture ends were then tied using an arthroscopic sliding knot, thereby creating a lateral knotted bridge in a double-row configuration.

bridge with a lateral knotted bridge over the rotator cuff tendon. The lateral knot functions as the final tensioner.

The postoperative protocol was standardized for all patients. The patients were placed in a sling with abduction pillow for 6 weeks. Physical therapy was started at 2 weeks postoperatively, beginning with passive range of motion and then progressing to active assisted range of motion and active range of motion at 2 weeks, 4 weeks, and 8 weeks, respectively. Strengthening was started 3 months after surgery. Patients were cleared for all activities by 6 months postoperatively.

Patients completed PRO scores before surgery and at final follow-up. When the postoperative records were not available through retrospective review, telephone interviews were conducted to gather subjective information and PRO scores and inquire about any complications or further surgery on the operative shoulder. PROs included the American Shoulder and Elbow Surgeons (ASES) score, Simple Shoulder Test (SST), shortened Disabilities of the Arm, Shoulder, and Hand (QuickDASH) questionnaire, and visual analog scale (VAS) for pain.

Patient characteristics were recorded preoperatively and included age, sex, and tear size based on preoperative

TABLE 1
Patient Characteristics^a

Age, y, mean \pm SD	64.5 \pm 11.9
Male sex, n (%)	21 (51.2)
Tear size (ML), mm, mean \pm SD	15.2 \pm 8.9
Tear size (AP), mm, mean \pm SD	14.6 \pm 9.8
Follow-up, mo, mean \pm SD	29.7 \pm 4.5

^aAP, anterior-posterior; ML, medial-lateral.

magnetic resonance imaging. Surgical complications and reoperations were recorded. The complications sought included, but were not limited to, infection, bleeding, wound dehiscence, pain, shoulder stiffness, nerve injury, deep-vein thrombosis, fluid extravasation, hardware failure, and death.⁶ Reoperation was defined as any return to the operating room. The primary outcome measure was the ASES score at final follow-up. Secondary outcomes included the QuickDASH, SST, VAS, reoperations, and complications. Clinical relevance, when applicable, was defined by the minimally clinically important difference (MCID) for the ASES (MCID 12) and SST (MCID 2).⁴³ Comparisons on an individual level that exceeded MCID (individual-level scores) were deemed clinically relevant.

Statistical analysis was performed using R version 3.3.1. Comparisons between preoperative and postoperative scores were completed using the Student *t* test. All *P* values were reported with significance set at *P* < .05.

RESULTS

A total of 42 shoulders in 41 consecutive patients were included in the study (Table 1). All patients (100%) completed the minimum 2-year follow-up (9 by telephone interview). There were 21 male patients (51.2%) and 20 female patients (48.8%), with a mean age of 64.5 \pm 11.9 years and an average follow-up of 29.7 \pm 4.5 months. The rotator cuff tear measured on average 15.2 \pm 8.9 mm in the coronal plane and 14.6 \pm 9.8 mm in the sagittal plane.

The preoperative and postoperative PRO scores are shown in Table 2. The mean ASES score improved significantly from 35.5 \pm 18.2 preoperatively to 93.4 \pm 10.6 postoperatively (*P* < .001). Scores on the QuickDASH (*P* < .001), SST (*P* < .001), and VAS (*P* < .001) also significantly improved after surgery. All patients (42/42 shoulders, 100%) achieved clinically relevant improvement (met or exceeded MCID) in ASES and SST scores postoperatively. There were no postoperative complications or reoperations at final follow-up.

DISCUSSION

In the current study, linked double-row equivalent arthroscopic rotator cuff repair resulted in statistically significant and clinically relevant improvement in PROs, with low complication and reoperation rates. Thus, all study hypotheses were confirmed.

TABLE 2
Preoperative and Postoperative Outcome Scores^a

	Preoperative	Postoperative	Mean difference (95% CI)	P
ASES	35.5 ± 18.2	93.4 ± 10.6	57.9 (51.8-63.9)	<.001
QuickDASH	55.2 ± 19.8	8.6 ± 12.5	46.6 (40.4-52.8)	<.001
SST	3.1 ± 2.4	10.9 ± 1.7	7.8 (7.0-8.6)	<.001
VAS	67.5 ± 20.6	5.6 ± 10.3	61.8 (55.7-68.0)	<.001

^aASES, American Shoulder and Elbow Surgeons; Quick DASH, shortened Disabilities of the Arm, Shoulder and Hand; SST, Simple Shoulder Test; VAS, visual analog scale.

Several biomechanical studies^{3,7,12,16,37} have previously demonstrated the utility of linked medial anchors in rotator cuff repair. However, they are technically more demanding and often require medial knots for the anchor linkage. The present technique for rotator cuff repair utilizing a linked double-row equivalent construct combines the advantages of linked medial sutures with a double-row repair without having to tie medial knots. As such, it has been shown to be biomechanically superior to double-row repairs alone.⁴¹ Each suture from the medial row anchor has a built-in loop at 1 end. This can be used to shuttle the end of 1 suture from 1 anchor through the other anchor, creating a free-sliding running suture through multiple anchors. The knotless linkage allows equal load sharing across the repair by using the anchors as pulleys to potentiate the strength of repair.^{3,9,10,16,20,24,42}

Prior studies utilizing linked medial row anchors have been limited to biomechanical studies and technique papers, making the present study the first to report on clinical outcomes after a linked double-row equivalent rotator cuff repair. There were statistically significant improvements in all PRO scores, with the ASES score significantly improving from 35.5 ± 18.2 preoperatively to 93.4 ± 10.6 postoperatively. This result is similar to previously published reports investigating knotless double-row rotator cuff repairs in patients with similar-sized rotator cuff tears at up to 2-year follow-up. All previous studies^{14,26,28,33} reported significant improvement in ASES scores after surgery, which ranged from 87.4 before surgery to 97.0 at final follow-up.

The improvements in PROs were also clinically relevant, with 100% of patients achieving the MCID for the ASES score and SST score. A 2019 study by Dukan et al¹⁴ had similar results after a knotless suture bridge technique, with 98.5% of patients achieving the MCID for the ASES score. The MCID used in the present study is specific to rotator cuff pathology, with a range from 12 to 17 points.⁴³ This compares with the MCID of 6.4 points used in the study by Dukan et al. Without the raw data, it is difficult to determine whether the same number of patients in their study would have reached the more stringent MCID guidelines for rotator cuff disease that were used in the current study.

Despite these excellent clinical outcomes in double-row repairs, there still remains a relatively high retear rate on postoperative imaging that ranges from 5.9% to 22.7%.^{14,21,26,28,33,40} This is compared with single-row rotator cuff repairs, which had a pooled failure rate of 40.2% in a 2014 meta-analysis by Xu et al.⁴⁴ Additionally, these same

studies demonstrated equivalent or superior ASES scores in the double-row groups compared with single-row groups, indicating that patients with improved healing rates have improved outcome scores compared with those that failed.⁴⁴ Based on the superior biomechanical strength and excellent PROs with the linked double-row equivalent technique, we believe that the healing rate is equivalent or superior to that of the conventional double-row rotator cuff repair. However, this needs further investigation in comparative studies using postoperative imaging.

There are limitations to this study. The study was retrospective and had a relatively small sample size, possibly leading to selection bias. Despite the small population, the current study was still able to detect statistically significant improvement in patient outcomes that translated to clinical relevance. All surgeries were performed by a single fellowship-trained orthopaedic surgeon with extensive experience in shoulder arthroscopy. Thus, the results of this investigation may not be extrapolated to all patient and surgeon populations. Additionally, we did not directly compare the linked double-row equivalent repair with conventional rotator cuff repairs. However, indirect comparison with previous studies using similar PRO measures showed comparable improvement in scores postoperatively.^{4,25,27,38,39} The current study only included small to large rotator cuff tears, so it is unclear if these outcomes will extrapolate to massive rotator cuff tears. In addition, we only evaluated clinical outcomes and did not assess the retear rates after repair using imaging modalities. However, there were no clinical failures according to the PROs, symptoms, and physical examination. Finally, 21.4% of the patients could not be assessed in person at the 2-year follow-up and were evaluated instead by telephone interview.

CONCLUSION

Arthroscopic repair of full-thickness rotator cuff tears with the linked double-row equivalent technique results in statistically significant and clinically relevant improvements in PRO scores, with low complication (0.0%) and reoperation (0.0%) rates at short-term follow-up.

REFERENCES

1. Anderson K, Boothby M, Aschenbrenner D, van Holsbeeck M. Outcome and structural integrity after arthroscopic rotator cuff repair

- using 2 rows of fixation: minimum 2-year follow-up. *Am J Sports Med.* 2006;34(12):1899-1905.
2. Apreleva M, Ozbaydar M, Fitzgibbons PG, Warner JJ. Rotator cuff tears: the effect of the reconstruction method on three-dimensional repair site area. *Arthroscopy.* 2002;18(5):519-526.
 3. Arrigoni P, Brady PC, Burkhart SS. The double-pulley technique for double-row rotator cuff repair. *Arthroscopy.* 2007;23(6):675.
 4. Black EM, Lin A, Srikumaran U, Jain N, Freehill MT. Arthroscopic transosseous rotator cuff repair: technical note, outcomes, and complications. *Orthopedics.* 2015;38(5):e352-358.
 5. Boileau P, Brassart N, Watkinson DJ, Carles M, Hatzidakis AM, Krishnan SG. Arthroscopic repair of full-thickness tears of the supraspinatus: does the tendon really heal? *J Bone Joint Surg Am.* 2005;87(6):1229-1240.
 6. Brislin KJ, Field LD, Savoie FH 3rd. Complications after arthroscopic rotator cuff repair. *Arthroscopy.* 2007;23(2):124-128.
 7. Burkhart SS, Denard PJ, Obopilwe E, Mazzocca AD. Optimizing pressurized contact area in rotator cuff repair: the diamondback repair. *Arthroscopy.* 2012;28(2):188-195.
 8. Charoussat C, Grimberg J, Duranthon LD, Bellaiche L, Petrover D. Can a double-row anchorage technique improve tendon healing in arthroscopic rotator cuff repair?: a prospective, nonrandomized, comparative study of double-row and single-row anchorage techniques with computed tomographic arthrography tendon healing assessment. *Am J Sports Med.* 2007;35(8):1247-1253.
 9. Chauhan A, Regal S, Frank DA. Hybrid repair of large crescent rotator cuff tears using a modified SpeedBridge and double-pulley technique. *Arthrosc Tech.* 2014;3(3):e409-e412.
 10. Choi CH, Kim SK, Cho MR, et al. Functional outcomes and structural integrity after double-pulley suture bridge rotator cuff repair using serial ultrasonographic examination. *J Shoulder Elbow Surg.* 2012;21(12):1753-1763.
 11. Christoforetti JJ, Krupp RJ, Singleton SB, Kissenberth MJ, Cook C, Hawkins RJ. Arthroscopic suture bridge transosseous equivalent fixation of rotator cuff tendon preserves intratendinous blood flow at the time of initial fixation. *J Shoulder Elbow Surg.* 2012;21(4):523-530.
 12. Chung NS, Cho JH, Han KJ, Han SH, Lee DH. Tendon trap technique for rotator cuff repair. *Orthopedics.* 2012;35(12):1035-1038.
 13. Curtis AS, Burbank KM, Tierney JJ, Scheller AD, Curran AR. The insertional footprint of the rotator cuff: an anatomic study. *Arthroscopy.* 2006;22(6):609.
 14. Dukan R, Ledinot P, Donadio J, Boyer P. Arthroscopic rotator cuff repair with a knotless suture bridge technique: functional and radiological outcomes after a minimum follow-up of 5 years. *Arthroscopy.* 2019;35(7):2003-2011.
 15. Fealy S, Adler RS, Drakos MC, et al. Patterns of vascular and anatomical response after rotator cuff repair. *Am J Sports Med.* 2006;34(1):120-127.
 16. Franceschi F, Longo UG, Ruzzini L, Rizzello G, Maffulli N, Denaro V. The Roman bridge: a "double pulley-suture bridges" technique for rotator cuff repair. *BMC Musculoskelet Disord.* 2007;8:123.
 17. Galatz LM, Ball CM, Teefey SA, Middleton WD, Yamaguchi K. The outcome and repair integrity of completely arthroscopically repaired large and massive rotator cuff tears. *J Bone Joint Surg Am.* 2004;86(2):219-224.
 18. Gwak HC, Kim CW, Kim JH, Choo HJ, Sagong SY, Shin J. Delaminated rotator cuff tear: extension of delamination and cuff integrity after arthroscopic rotator cuff repair. *J Shoulder Elbow Surg.* 2015;24(5):719-726.
 19. Hansen ML, Otis JC, Johnson JS, Cordasco FA, Craig EV, Warren RF. Biomechanics of massive rotator cuff tears: implications for treatment. *J Bone Joint Surg Am.* 2008;90(2):316-325.
 20. Hotta T, Yamashita T. Osteolysis of the inferior surface of the acromion caused by knots of the suture thread after rotator cuff repair surgery: knot impingement after rotator cuff repair. *J Shoulder Elbow Surg.* 2010;19(8):e17-e23.
 21. Hug K, Gerhardt C, Haneveld H, Scheibel M. Arthroscopic knotless-anchor rotator cuff repair: a clinical and radiological evaluation. *Knee Surg Sports Traumatol Arthrosc.* 2015;23(9):2628-2634.
 22. Iannotti JP, Deutsch A, Green A, et al. Time to failure after rotator cuff repair: a prospective imaging study. *J Bone Joint Surg Am.* 2013;95(11):965-971.
 23. Kim DH, ElAttrache NS, Tibone JE, et al. Biomechanical comparison of a single-row versus double-row suture anchor technique for rotator cuff repair. *Am J Sports Med.* 2006;34(3):407-414.
 24. Kim KC, Rhee KJ, Shin HD. Arthroscopic double-pulley suture-bridge technique for rotator cuff repair. *Arch Orthop Trauma Surg.* 2008;128(11):1335-1338.
 25. Kim KC, Shin HD, Lee WY, Han SC. Repair integrity and functional outcome after arthroscopic rotator cuff repair: double-row versus suture-bridge technique. *Am J Sports Med.* 2012;40(2):294-299.
 26. Kim KC, Shin HD, Lee WY, Yeon KW, Han SC. Clinical outcomes and repair integrity of arthroscopic rotator cuff repair using suture-bridge technique with or without medial tying: prospective comparative study. *J Orthop Surg Res.* 2018;13(1):212.
 27. Lapner PL, Sabri E, Rakhra K, et al. A multicenter randomized controlled trial comparing single-row with double-row fixation in arthroscopic rotator cuff repair. *J Bone Joint Surg Am.* 2012;94(14):1249-1257.
 28. Lee SH, Kim JW, Kim TK, et al. Is the arthroscopic suture bridge technique suitable for full-thickness rotator cuff tears of any size? *Knee Surg Sports Traumatol Arthrosc.* 2017;25(7):2138-2146.
 29. Lo IK, Burkhart SS. Double-row arthroscopic rotator cuff repair: re-establishing the footprint of the rotator cuff. *Arthroscopy.* 2003;19(9):1035-1042.
 30. Ma HL, Chiang ER, Wu HT, et al. Clinical outcome and imaging of arthroscopic single-row and double-row rotator cuff repair: a prospective randomized trial. *Arthroscopy.* 2012;28(1):16-24.
 31. McCarron JA, Derwin KA, Bey MJ, et al. Failure with continuity in rotator cuff repair "healing." *Am J Sports Med.* 2013;41(1):134-141.
 32. Meier SW, Meier JD. Rotator cuff repair: the effect of double-row fixation on three-dimensional repair site. *J Shoulder Elbow Surg.* 2006;15(6):691-696.
 33. Millett PJ, Espinoza C, Horan MP, et al. Predictors of outcomes after arthroscopic transosseous equivalent rotator cuff repair in 155 cases: a propensity score weighted analysis of knotted and knotless self-reinforcing repair techniques at a minimum of 2 years. *Arch Orthop Trauma Surg.* 2017;137(10):1399-1408.
 34. Park JY, Lhee SH, Choi JH, Park HK, Yu JW, Seo JB. Comparison of the clinical outcomes of single- and double-row repairs in rotator cuff tears. *Am J Sports Med.* 2008;36(7):1310-1316.
 35. Park MC, ElAttrache NS, Ahmad CS, Tibone JE. "Transosseous-equivalent" rotator cuff repair technique. *Arthroscopy.* 2006;22(12):1360.
 36. Park MC, ElAttrache NS, Tibone JE, Ahmad CS, Jun BJ, Lee TQ. Part I: footprint contact characteristics for a transosseous-equivalent rotator cuff repair technique compared with a double-row repair technique. *J Shoulder Elbow Surg.* 2007;16(4):461-468.
 37. Park MC, Peterson A, Patton J, McGarry MH, Park CJ, Lee TQ. Biomechanical effects of a 2 suture-pass medial inter-implant mattress on transosseous-equivalent rotator cuff repair and considerations for a "technical efficiency ratio." *J Shoulder Elbow Surg.* 2014;23(3):361-368.
 38. Potter MQ, Wylie JD, Granger EK, Greis PE, Burks RT, Tashjian RZ. One-year patient-reported outcomes after arthroscopic rotator cuff repair do not correlate with mild to moderate psychological distress. *Clin Orthop Relat Res.* 2015;473(11):3501-3510.
 39. Randelli P, Stoppani CA, Zaolino C, Menon A, Randelli F, Cabitza P. Advantages of arthroscopic rotator cuff repair with a transosseous suture technique: a prospective randomized controlled trial. *Am J Sports Med.* 2017;45(9):2000-2009.
 40. Rhee YG, Cho NS, Parke CS. Arthroscopic rotator cuff repair using modified Mason-Allen medial row stitch: knotless versus knot-tying suture bridge technique. *Am J Sports Med.* 2012;40(11):2440-2447.

41. Robinson S, Krigbaum H, Kramer J, Purviance C, Parrish R, Donahue J. Double row equivalent for rotator cuff repair: a biomechanical analysis of a new technique. *J Orthop*. 2018;15(2):426-431.
42. Sano H, Tokunaga M, Noguchi M, et al. Tight medial knot tying may increase retearing risk after transosseous equivalent repair of rotator cuff tendon. *Biomed Mater Eng*. 2017;28(3):267-277.
43. Tashjian RZ, Deloach J, Green A, Porucznik CA, Powell AP. Minimal clinically important differences in ASES and simple shoulder test scores after nonoperative treatment of rotator cuff disease. *J Bone Joint Surg Am*. 2010;92(2):296-303.
44. Xu C, Zhao J, Li D. Meta-analysis comparing single-row and double-row repair techniques in the arthroscopic treatment of rotator cuff tears. *J Shoulder Elbow Surg*. 2014;23(2):182-188.
45. Yamaguchi K, Ditsios K, Middleton WD, Hildebolt CF, Galatz LM, Teefey SA. The demographic and morphological features of rotator cuff disease. A comparison of asymptomatic and symptomatic shoulders. *J Bone Joint Surg Am*. 2006;88(8):1699-1704.
46. Yamamoto A, Takagishi K, Osawa T, et al. Prevalence and risk factors of a rotator cuff tear in the general population. *J Shoulder Elbow Surg*. 2010;19(1):116-120.