

## An interesting case of cystic prolactinomas

Sir,

Herein, we are describing a 52-year-old lady presented with blurring of vision for past 3 weeks presented to an ophthalmologist. Her evaluation showed optic atrophy in the left eye and hemianopia on the right side. MRI brain was ordered and it showed a pituitary macroadenoma along with suprasellar extension with a cystic area in the upper portion of macroadenoma [Figure 1]. She was referred to a neurosurgeon and he further referred her for endocrinology consultation. She was advised transsphenoidal surgery. However, due to financial constraints, she did not undergo surgery.

She was referred for review endocrine opinion. On enquiring further, she reported having a recurrent headache but no vomiting. She was postmenopausal and her prolactin level was 4549 ng/mL. Her thyroid function test was T3 83 ng/mL, T4 6.4 mcg/dl and TSH 1.41, cortisol 10.8 mcg/dL, FSH 1.57 mIU/mL, and LH 0.1 mIU/mL.

MRI showed a sellar mass of  $3.5 \times 2.5 \times 2.9$  cm, superiorly compressing optic chiasma and bilateral cavernous sinus invasion. In addition, the superior aspect of the tumor had a non-contrast enhancing area, probably cystic area [Figures 1 and 2].

After cautioning her about the success rates with medical therapy and carefully keeping her under observation for further worsening of eye symptoms, cabergoline 0.5 mg daily for 4 days was started. After 4 days, her visual symptoms were slightly better and her serum prolactin was 58 ng/mL; hence, the same dose of cabergoline was continued for 10 more days. After 2 weeks of the start of treatment, her diplopia completely subsided and vision improved. Ophthalmology review revealed better vision in the right eye; however, the field of vision could not be mapped. Her prolactin levels were 3.1 ng/mL and cabergoline dose was reduced to 1 mg thrice a week.

After one month, her prolactin level was 14 ng/mL and ophthalmology review showed visual acuity of 6/6 and significant improvement in the field of vision.

After 2 months her prolactin level was 0.97 ng/mL and cabergoline was reduced to 0.5 mg weekly twice and MRI was repeated. It showed sellar lesion reduced in size to  $2 \times 2.2 \times 2.2$  cm and cystic lesion completely disappeared [Figures 3 and 4].

Now after 6 months her eye symptoms and headache completely recovered and presently she is on cabergoline 0.5 mg weekly once.

Most of the prolactinomas are microadenomas which are more common in females; males, on the contrary, harbour more macroadenomas. Cystic prolactinomas are prolactinomas that harbor cystic regions, usually occupying  $\geq 50\%$  of the tumor volume. According to the pituitary society guidelines, surgery should be considered as a treatment for cystic macroadenomas causing neurological symptoms.<sup>[1]</sup> It is hypothesized that

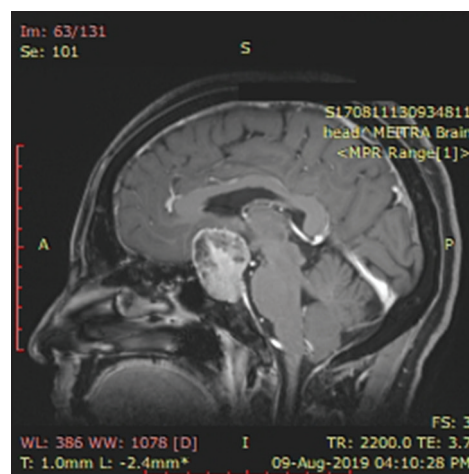
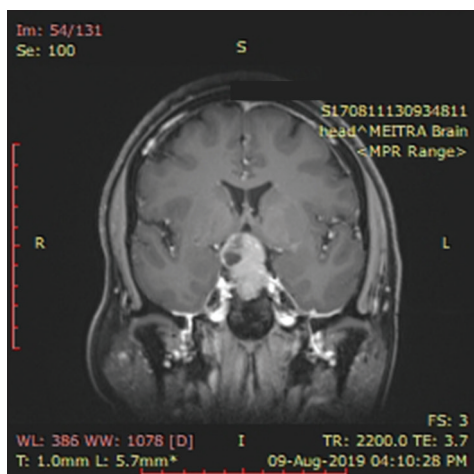
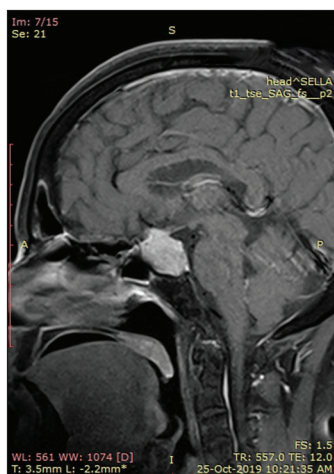


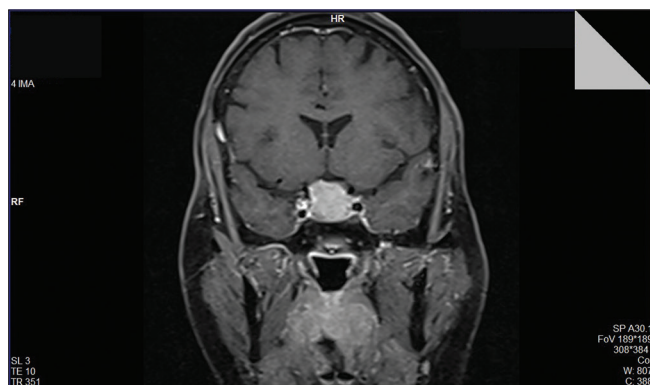
Figure 1: MRI pituitary with contrast- Before treatment - Sagittal view



**Figure 2:** MRI pituitary with contrast- Before treatment- Coronal view



**Figure 3:** MRI pituitary with contrast- After treatment- Sagittal view



**Figure 4:** MRI pituitary with contrast- After treatment- Coronal view

dopamine agonists are ineffective in reducing cystic tumor mass due to the absence of dopamine receptors in the cystic portion of the tumor.

In a recent review of cystic prolactinoma patients, 80% with compression of the optic chiasm evident on MRI (mostly without visual field defect) at presentation achieved resolution of chiasm compression with medical treatment.<sup>[2]</sup> In a large series of patients, the majority (80%) of the patients who presented chiasm compression and visual field impairment had undergone transsphenoidal surgical resection.<sup>[3]</sup>

Present guidelines recommend medical treatment of cystic prolactinoma and surgery is indicated only in case medical treatment fails or develops drug intolerance. However, patients with optic chiasma compression, surgery is the first-line of management.<sup>[2]</sup>

Here, we report a patient who had a macroprolactinoma with a cystic component on the superior aspect with optic chiasma compression and visual symptoms who were treated with cabergoline and had effective tumor reduction and resolution of visual symptoms. Interestingly, the cystic component of the tumor disappeared during repeat imaging done after 2 months.

Our patient demonstrates that even in patients with cystic prolactinomas with optic chiasm compression and visual impairment, a short trial with a dopamine agonist may be tried before proceeding with transsphenoidal surgery.

#### Declaration of patient consent

The authors certify that they have obtained all appropriate patient consent forms. In the form the patient(s) has/have given his/her/their consent for his/her/their images and other clinical information to be reported in the journal. The patients understand that their names and initials will not be published and due efforts will be made to conceal their identity, but anonymity cannot be guaranteed.

#### Financial support and sponsorship

Nil.

#### Conflicts of interest

There are no conflicts of interest.

**Raju A. Gopal, Joe George**

Senior consultant, Endodiab Clinic, Kozhikode, Kerala, India

**Address for correspondence:** Dr. Raju A. Gopal,  
Senior consultant Endocrinologist, Endodiab Clinic,  
3<sup>rd</sup> Floor, Sheikh Square, Parayencheri, Kozhikode - 673 016, Kerala, India.  
E-mail: drrajugopal@gmail.com

#### REFERENCES

1. Casanueva FF, Molitch ME, Schlechte JA, Abs R, Bonert V, Bronstein MD, *et al*. Guidelines of the pituitary society for the diagnosis and management of pro- lactinomas. *Clin Endocrinol* 2006;65:265-73.
2. Akhleh A, Shehadeh N, Hochberg I, Zloczower M, Zolotov S, Taher R,

*et al.* Management of cystic prolactinomas: A review. Pituitary 2018;21:425-30.

3. Faje A, Chunharojrith P, Nancy J, Biller BM, Swearingen B, Klibanski A, *et al.* Dopamine agonists can reduce cystic prolactinomas. J Clin Endocrinol Metab 2016;101:3709-15.

**Submitted:** 18-Feb-2020

**Revised:** 19-Feb-2020

**Accepted:** 19-Feb-2020

**Published:** 30-Apr-2020

This is an open access journal, and articles are distributed under the terms of the Creative Commons Attribution-NonCommercial-ShareAlike 4.0 license, which allows others to remix, tweak, and build upon the work non-commercially, as long as appropriate credit is given and the new creations are licensed under the identical terms.

Access this article online

Quick Response Code:



Website:

[www.ijem.in](http://www.ijem.in)

DOI:

10.4103/ijem.IJEM\_86\_20

**How to cite this article:** Gopal RA, George J. An interesting case of cystic prolactinomas. Indian J Endocr Metab 2020;24:217-9.

© 2020 Indian Journal of Endocrinology and Metabolism | Published by Wolters Kluwer - Medknow