

Functional medicine

## Enormous mucocele following colonic graft neovagina formation in a transwoman

James Brittain<sup>a,\*</sup>, Charlotte Dunford<sup>a</sup>, Saiful Miah<sup>a,b</sup>, Manjit Takhar<sup>a</sup>, Roland Morley<sup>a</sup>, Tina Rashid<sup>a</sup>

<sup>a</sup> Department of Urology, Charing Cross Hospital, Imperial College Healthcare NHS Trust, London, UK

<sup>b</sup> Division of Surgery and Interventional Science, University College London, 21 University Street, London, WC1E 6AU, UK

### Introduction

Genital reconstructive surgery (GRS) is required for conditions including vaginal agenesis, gender dysphoria in biological males, and genital trauma. GRS in male to female (MTF) transsexuals is the final step in aligning a person's body with their perceived gender. There is evidence to support the positive effects GRS has on a trans-person's sexual health and overall well-being.<sup>1,2</sup> Not all transgender people choose to undergo reconstructive surgery, but for those trans-women who chose to undergo genital reconstruction, this would involve orchidectomy, penectomy, clitoroplasty, urethral meatoplasty, labiaplasty and vaginoplasty. Not all people choose to have a functional neovagina for a variety of reasons. Just as in the general population, transgender people are asexual, bisexual, homosexual and heterosexual. Many will not feel they need a neovagina which requires a commitment from the patient to continue life-long regular dilatation and douching for cleanliness. Similarly, the inclusion of vaginoplasty in GRS, is associated with greater complications including intra-operative rectal injury, recto-vaginal fistula, vaginal or introital stenosis and prolapse.<sup>1–3</sup>

Surgical techniques have advanced considerably in the last 50 years and variation in technique occurs in how the vaginoplasty is performed. With natal females as the standard for aesthetic and functional outcomes, the neo-vagina must be moist, hairless and elastic or expansile to accommodate sexual intercourse.<sup>2,3</sup> There are 3 main techniques in primary GRS which include penile inversion, penoscrotal inlay or substitution graft using bowel (either colon or ileum). In secondary GRS, where the vaginal cavity has been lost previously due to complications, substitution graft using bowel is commonly undertaken. A consequence of using bowel in vaginoplasty is mucus production which provides moisture and lubrication.<sup>4</sup> However it is ever more important to regularly dilate the introitus to avoid stenosis and mucocele formation as a result.

We describe a case of a trans-woman post GRS with a colonic neovagina who as a result of poor compliance with lifelong dilatation, developed complete introital stenosis. The consequence of this was

enormous mucocele formation and we describe our novel technique to overcome this obstruction.

### Case report

A 59-year old trans-woman presented to her local hospital with recurrent intra-abdominal collections 20 years post GRS.

The patient underwent GRS including vaginoplasty in 2001 using the penile inversion technique. Postoperatively, she developed a wound infection which reduced her ability to adequately dilate her neovagina. In 2005 she underwent secondary GRS revision to construct a neo vagina using colon on a pedicle. This was to provide a functioning neovagina for penetrative intercourse.

In 2016 the patient presented to her local hospital with abdominal pain having stopped dilating her neovagina for the past 2 years. Computed tomography demonstrated a large collection within the neovagina (Fig. 1) which was drained under ultrasound guidance. She was transferred to our centre where she underwent an examination of her neovagina under anaesthetic. Attempts to dilate were unsuccessful and subsequently abandoned due to risk of rectal damage. She was discharged home with the percutaneous drain in situ, to be reviewed in an outpatient clinic for discussion of future management. Unfortunately, she was readmitted before then with a 11 × 10 × 14cm fluid collection lateral to the lower abdominal wall midline scar, and also the site of an incisional hernia. This collection was incised and drained in theatre therefore.

The options discussed with the patient for long term management of her neovaginal collection were:

- 1) Further examination under anaesthetic and dilation
- 2) Surgical removal of the neovagina
- 3) Formation of a cutaneous tract to allow the neo vagina to drain.

After lengthy discussion with the patient and her partner, it was felt that further attempts at dilation under anaesthetic were unlikely to be successful and the patient herself felt unable to continue to dilate at

\* Corresponding author. Department of Urology, Imperial College Healthcare NHS Trust, Charing Cross Hospital, W6 8RF, UK.  
E-mail address: [james.brittain@nhs.net](mailto:james.brittain@nhs.net) (J. Brittain).

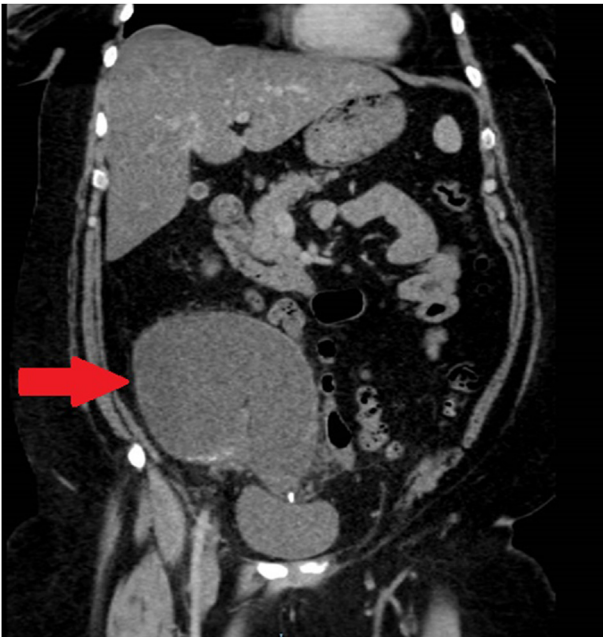


Fig. 1. A coronal slice of the computed tomography scan demonstrating the mucocele arising from colonic neovagina.

home due to poor dexterity. Surgical removal of the neovagina would be complicated by the large incisional hernia, the patient's body habitus and her co-existing medical comorbidities. It was therefore decided that formation of a cutaneous tract communicating the neovagina to the skin would allow the mucus produced by the colonic tissue to drain and was most likely the safest option. This cutaneous tract was developed by long-term placement of a 14 F × 35 cm Skater Drainage Catheter which was left in-situ for 4 months. She will be followed up with CT imaging 6 months post removal of the drain.

## Discussion

The incidence of gender dysphoria is increasing worldwide as more people seek help from ever expanding services.<sup>5</sup> NHS England commissions GRS and whilst the initial operation may be performed in a tertiary centre, trans-women live all over the UK and as healthcare providers we will see more and more patients in our local communities, who have undergone this type of reconstructive surgery. An understanding of the surgical techniques and familiarity with commitments of the patient to upkeep the neo-vagina will help the local healthcare provider identify complications earlier. This should facilitate prompt management and avoid catastrophic outcomes.

Substitution graft using bowel in vaginoplasty is currently not that common. However, the transgender community is not only increasing in number as more and more people identify themselves and seek help, but the age at presentation to services is decreasing. Children are aware of their gender identity as young as 2 years of age. More recently, healthcare professionals are facilitating children in halting puberty while they work through their gender identity. The impact of this is that a trans-girl would have very hypoplastic genital tissues and therefore minimal skin to use for subsequent reconstruction. The technical implications are such that more primary GRS will involve bowel substitution grafting for the neovaginal cavity. We are likely therefore to see more of these cases in our local communities and it is important therefore to educate not only the patient on the importance of dilation, but also the primary care physician on this serious complication of mucocele, with which a patient might present.

To our knowledge there are no published case reports of this complication or technique in management.

## Conclusion

This case demonstrates the importance of lifelong dilation in this subset of patients. Awareness of the potential complications in patients who struggle with dilation is needed, and we have outlined a potential management where surgical removal of the neovagina is not appropriate.

## Ethics

The patient has provided written consent for this publication.

## Conflicts of interest

None declared.

## References

1. Johansson A, Sundbom E, Höjerback T. A five-year follow-up study of Swedish adults with gender identity disorder. *Arch Sex Behav.* 2010;39:1429–1437.
2. Karim RB, Hage JJ, Bouman FG, de Ruyter R, van Kesteren PJ. Refinements of pre-, intra-, and postoperative care to prevent complications of vaginoplasty in male transsexuals. *Ann Plast Surg.* 1995 Sep 1;35(3):279–284.
3. Wangjiraniran B, Selvaggi G, Chokrungravanont P, Jindarak S, Khobunsongsorn S, Tiewtranon P. Male-to-female vaginoplasty: preecha's surgical technique. *Journal of plastic surgery and hand surgery.* 2015 May 4;49(3):153–159.
4. Bouman MB, van der Sluis WB, Buncamper ME, Özer M, Mullender MG, Meijerink WJ. Primary total laparoscopic sigmoid vaginoplasty in transgender women with penoscrotal hypoplasia: a prospective cohort study of surgical outcomes and follow-up of 42 patients. *Plast Reconstr Surg.* 2016 Oct 1;138(4) 614e–23e.
5. Hess J, Neto RR, Panic L, Rübber H, Senf W. Satisfaction with male-to-female gender reassignment surgery: results of a retrospective analysis. *Deutsches Ärzteblatt International.* 2014 Nov;111(47):795.