



Since January 2020 Elsevier has created a COVID-19 resource centre with free information in English and Mandarin on the novel coronavirus COVID-19. The COVID-19 resource centre is hosted on Elsevier Connect, the company's public news and information website.

Elsevier hereby grants permission to make all its COVID-19-related research that is available on the COVID-19 resource centre - including this research content - immediately available in PubMed Central and other publicly funded repositories, such as the WHO COVID database with rights for unrestricted research re-use and analyses in any form or by any means with acknowledgement of the original source. These permissions are granted for free by Elsevier for as long as the COVID-19 resource centre remains active.



## Original Article

## Clinical characteristics of the coronavirus disease 2019 (COVID-19) outbreak on a cruise ship

Yukihiro Yoshimura<sup>\*</sup>, Hiroaki Sasaki, Hiroshi Horiuchi, Nobuyuki Miyata, Natsuo Tachikawa

Department of Infectious Disease, Yokohama Municipal Citizen's Hospital, Japan

## ARTICLE INFO

## Article history:

Received 12 March 2020  
 Received in revised form  
 4 June 2020  
 Accepted 7 June 2020  
 Available online 12 June 2020

## Keywords:

Coronavirus infection  
 COVID-19  
 Cruise

## ABSTRACT

**Background:** A large COVID-19 outbreak occurred on the cruise ship Diamond Princess in February 2020. Little information has been reported about the clinical characteristics of the patients.

**Methods:** This single-center, retrospective, observational study was conducted in Yokohama, Japan. We included symptomatic patients who were infected on the ship and admitted to our hospital between 5 and 19 February 2020. All the cases were confirmed with SARS-CoV-2 infection by polymerase chain reaction (PCR).

**Results:** We confirmed 17 cases. The average age was 69 years; 10 patients were Asian and 7 were Caucasian. Eleven patients had one or more chronic diseases. The major symptoms were cough and fever. Chest computed tomography (CT) scans found bilateral ground-glass opacities predominantly in the peripheral area, which were similar to reports from cases in China. C-reactive protein (CRP) levels were higher in severe and critical cases than in mild to moderate cases. The moderate to severe cases reached symptomatic resolution; one of the three critical cases resulted in death due to multiple organ failure. SARS-CoV-2 was detected by PCR at an average of 7 days after symptomatic resolution.

**Conclusions:** Cough and fever, increased blood CRP levels, and CT findings of bilateral ground-glass opacities predominantly in the peripheral lung were characteristic of the COVID-19 cases in this study. These findings were compatible with those of previous reports.

© 2020 Japanese Society of Chemotherapy and The Japanese Association for Infectious Diseases. Published by Elsevier Ltd. All rights reserved.

## 1. Introduction

The novel coronavirus disease (COVID-19) was first reported from Wuhan, China, on 31 December 2019 and has been expanding globally with 78,811 confirmed cases [1]. The cruise ship Diamond Princess took a travel route that originated in Yokohama on 20 January and included stops in Japan (Kagoshima), Hong Kong, Vietnam, Taiwan, and Japan (Okinawa), before returning to Yokohama on 3 February. A passenger who disembarked on 25 January in Hong Kong presented with a cough that had been present since 19 January; the patient was diagnosed as having COVID-19 on 1 February. The Japanese government requested the ship to stay in the port, with no passengers or crew disembarking, when it arrived in Yokohama on 3 February. On 5 February, a laboratory

confirmation of a case of COVID-19 led to the quarantine of the Diamond Princess for 14 days beginning at 7 a.m., with passengers requested to stay in their cabins. As of 5 February, there were a total of 3,711 individuals on board the ship, including 2,666 passengers and 1,045 crew members. Among the 3,711 persons on board on 5 February, 301 symptomatic cases and 318 asymptomatic cases were confirmed to have severe acute respiratory syndrome coronavirus 2 (SARS-CoV-2) infection by polymerase chain reaction (PCR) [2]. Some of the symptomatic cases were referred to our hospital; we describe the clinical characteristics of the COVID-19 patients here.

## 2. Methods

We conducted a retrospective observational study of the COVID-19 cases who were admitted to the Yokohama Municipal Citizen's Hospital between 5 and 19 February 2020. A case is defined as a person who had a fever or respiratory symptoms occurring within 14 days after staying on the Diamond Princess with SARS-CoV-2

<sup>\*</sup> Corresponding author. Yokohama Municipal Citizen's Hospital, Yokohama, Japan.

E-mail address: [yu10-yoshimura@city.yokohama.jp](mailto:yu10-yoshimura@city.yokohama.jp) (Y. Yoshimura).

detection by PCR. PCR was performed on pharyngeal swabs, nasopharyngeal swabs, or sputum in the National Institute of Infectious Diseases or regional public health centers using a previously reported method [3]. Symptomatic resolution was defined as a temperature  $<37.5$  °C lasting more than 24 h and almost complete resolution of respiratory symptoms. Clinical severity was classified as mild, moderate, severe, or critical according to the National Health Commission of China [4].

### 3. Results

There were 17 cases (Table 1). The average age was 69 years; 9 were female, 10 were Asian, 7 were Caucasian, and none were from mainland China. The average period from the onset of symptoms to admission was 5.0 days. The average Charlson Comorbidity Index was 0.7. Six patients did not have any chronic diseases, and six had chronic respiratory diseases (chronic obstructive pulmonary disease, bronchial asthma, or interstitial pneumonia). Fever, cough, and sputum were common symptoms, and the maximum

**Table 1**  
Clinical characteristics of the patients.

Characteristic	Value
Number of cases	17
Average age $\pm$ SD [years]	69 $\pm$ 10
Male: female	8 : 9
Asian: Caucasian	10 : 7
Residence	
Japan	7
United States	5
Australia	2
Hong Kong	2
Taiwan	1
Comorbidities	
Hypertension	4
Cardiovascular	5
Diabetes	3
Malignancy	0
Cerebrovascular	1
Respiratory	6
Chronic kidney disease	1
Immunosuppressive	1
Average Charlson Comorbidity Index $\pm$ SD	0.7 $\pm$ 0.92
Average period from symptom onset to admission $\pm$ SD [days]	5 $\pm$ 4.5
Symptoms	
Cough	14 (82%)
Fever	14 (82%)
Sputum	9 (53%)
Fatigue	8 (47%)
Sore throat	7 (41%)
Dyspnea	6 (35%)
Runny nose	5 (29%)
Nausea/vomiting	4 (24%)
Muscle pain	2 (12%)
Drowsiness	2 (12%)
Diarrhea	1 (6%)
Chest X-ray	17
Bilateral ground-glass opacities	10 (59%)
Bronchial wall thickening	1 (6%)
No abnormality	6 (35%)
Chest computed tomography	7
Bilateral lesions	7 (100%)
Ground-glass opacities	7 (100%)
Peripheral dominance	6 (86%)
Reticular pattern	4 (57%)
Crazy paving pattern	3 (43%)
Consolidations	2 (9%)
Disease severity	
Mild	6 (35%)
Moderate	3 (18%)
Severe	5 (29%)
Critical	3 (18%)

temperature in their clinical course was 38.0 °C. Five patients needed oxygen therapy on admission, and another two patients needed oxygen therapy after admission. Blood tests on admission revealed that lymphocyte percent was lower than reference range in 9 cases and the absolute lymphocyte count was 457, 643 and 862/ $\mu$ L in the critical cases. C-reactive protein (CRP) levels were elevated in 11 cases, lactate dehydrogenase (LDH) and creatine kinase (CK) were elevated in 8 cases, and D-dimer was elevated in 7 cases (for 2 cases, blood tests were performed in the former hospitals) (Table 2). Chest X-rays showed a bilateral ground-glass shadow in 10 cases, thickened bronchial walls in 1 case, and no abnormal changes in 6 cases. A chest computed tomography (CT) scan was performed in seven cases and showed multiple ground-glass opacities predominantly in the peripheral area (Fig. 1). Consolidations were observed in two of the cases that were admitted to the intensive care unit (ICU). Antibiotics were provided in eight cases, antiviral agents (oseltamivir, peramivir or lopinavir/ritonavir) were provided in eight cases, and corticosteroid pulse therapy was provided in two cases (Table 3). Oseltamivir, peramivir or lopinavir/ritonavir was given because neuraminidase inhibitors and lopinavir/ritonavir were used in the previous reports and were expected to have some antiviral effects on the SARS-CoV-2 [5]. Lopinavir/ritonavir was introduced in four severe to critical cases, but it was stopped in two cases because of drug interaction. Six, three, five, and three cases had mild, moderate, severe, and critical illness, respectively. All the critical patients were cared for in the ICU; all of them had chronic diseases. Two of them were on invasive mechanical ventilation, one received high-flow nasal cannula oxygen therapy, and one received continuous renal replacement therapy.

After the cases had been followed for 16  $\pm$  5.8 days on average, all of the cases, except for the critical cases, reached symptomatic resolution. One of the critical cases resulted in death due to multiple organ failure. The patient was an Asian man in his seventies who had hypertension, cardiovascular disease, cerebrovascular disease, diabetes, and chronic kidney disease. The average period from symptom onset and symptomatic resolution to the last detection of SARS-CoV-2 in respiratory samples was 15 days (minimum 4, maximum 29) and 6.3 days (minimum 0, maximum 17), respectively.

### 4. Discussion

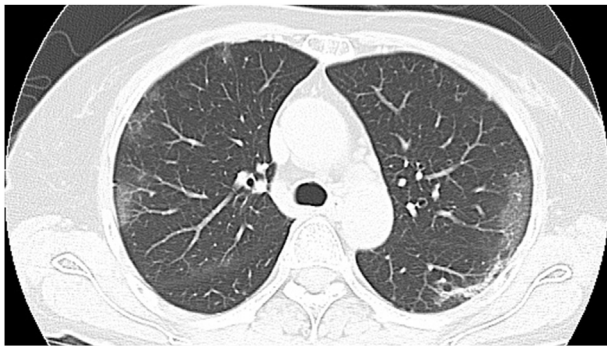
This is a large case series of a COVID-19 outbreak on the cruise ship. In our cases, the major symptoms were fever and cough, and the frequency of these symptoms was similar to those in previous reports from China [5,6]. However, sputum was more frequent in this study (nine cases, 53%). One patient suffered from watery diarrhea for seven days and was referred to our hospital because of dehydration. A bacterial culture, glutamate dehydrogenase antigen, and norovirus antigen from a stool sample were negative, suggesting that diarrhea may be a symptom of COVID-19. Digestive symptoms appeared in 50.5% of COVID-19 cases according to a report [7], the frequency of diarrhea and nausea/vomiting varied depending on the reports, 2.0–17% and 1.0–10%, respectively [5–8]. Additionally, patients with digestive symptoms had a significantly longer time from onset to admission than patients without digestive symptoms (9.0 days vs 7.3 days) [7].

The laboratory findings were similar to those of previous studies [5,6]. On admission, CRP was elevated in 11 cases (65%) and the percentage of lymphocytes was reduced in 9 cases (53%). The absolute lymphocyte number was very low ( $<900/\mu$ L) in all the critical cases, which was reported to be associated with poor prognosis [9]. The CRP levels in the critical cases were 20.1, 12.1, and 8.2 mg/dL, which tended to be higher than those in the noncritical cases

**Table 2**  
Laboratory findings.

Parameter	Higher	Normal	Lower	Reference range
AST (aspartate aminotransferase)	5	12	0	8–38 IU/L
ALT (alanine aminotransferase)	4	13	0	4–44 IU/L
LDH (lactate dehydrogenase)	8	9	0	106–211 IU/L
CK (creatinine kinase)	8	9	0	33–115 IU/L
BUN (blood urea nitrogen)	4	13	0	8–21 mg/dL
CRE (creatinine)	3	14	0	0.36–0.9 mg/dL
CRP (C-reactive protein)	12	5	NA	0–0.5 mg/dL
PCT (procalcitonin)	5	9	NA	0–0.05 ng/dL
WBC (white blood cells)	3	11	3	$3.5\text{--}9 \times 10^3/\mu\text{L}$
Lymphocytes	0	8	9	23–48%
PLT (platelets)	0	17	0	$130\text{--}370 \times 10^3/\mu\text{L}$
PT-INR (prothrombin time-international normalized ratio)	1	15	0	0.8–1.2
D-dimer	7	7	NA	0–1 $\mu\text{g/mL}$

NA, not applicable.

**Fig. 1.** Typical chest computed tomography (CT) image. The image of a severe COVID-19 case showed bilateral ground-glass opacities and reticular pattern in the left lower lobe. Both lesions were located predominantly in the periphery of the lung.**Table 3**  
Treatments and outcomes.

Variable	Value
Antibiotics	8
Azithromycin	6
Ceftriaxone	5
Tazobactam/piperacillin	3
Meropenem	1
Cefmetazole	1
Antiviral agents	8
Oseltamivir	5
Peramivir	3
Lopinavir/ritonavir	4
Corticosteroid therapy	2
Invasive mechanical ventilation	2
High-flow nasal cannula oxygen therapy	1
Renal replacement therapy	1
Extracorporeal membrane oxygenation (ECMO)	0
Outcomes	
Symptomatic resolution	14
No symptomatic resolution	2
Death	1
Length of disease and polymerase chain reaction (PCR) positivity	
Length from symptom onset to symptomatic resolution $\pm$ SD [days] ( $n = 14$ )	$7.9 \pm 6.0$
Length from symptom onset to last PCR positive finding $\pm$ SD [days] ( $n = 10$ )	$14.8 \pm 7.4$
Length from symptomatic resolution to last PCR positive finding $\pm$ SD [days] ( $n = 9$ )	$6.6 \pm 5.5$

(Fig. 2). We observed only one patient with a CRP level over 8.0 mg/dL (16.2 mg/dL) without ICU admission, and he progressed to severe illness with a maximum 4 L/min of oxygen therapy. CRP was elevated in 82% of the COVID-19 cases in a report from China, but the titer was not described [5]. A meta-analysis reported that CRP was significantly elevated in severe cases compared to non-severe cases and discussed that the elevation of interleukin 6 (IL-6), serum ferritin and CRP pointed to development of a systemic inflammatory response syndrome (SIRS) picture in patients with a severe form of COVID-19 [10]. A high level of CRP might be a marker of progression to severe or critical illness.

Chest images in previous studies showed rapid evolution from focal unilateral to diffuse bilateral ground-glass opacities that progressed to or coexisted with consolidations within 1–3 weeks [8]. The CT findings from our cases showed bilateral ground-glass opacities, with consolidation in two of the critical cases. These findings are compatible with the images reported from China [6,8].

Effective antiviral therapy for COVID-19 has not been established. China has more than 80 current or pending clinical trials of potential treatments for COVID-19 [11]. We used oseltamivir, peramivir, and lopinavir/ritonavir, but we did not observe any apparent clinical efficacy. A randomized, controlled, open-label trial involving hospitalized severe patients with COVID-19 showed that no benefit was observed with lopinavir–ritonavir treatment beyond standard care [12]; besides, this therapy might be difficult to introduce in critical cases because of drug interactions.

The crude fatality rate was reported to be 3.8% of 55,924 laboratory-confirmed cases in China [13]. Mortality is higher among males and increases with age and with comorbid conditions: 13.2% for those with cardiovascular disease, 9.2% for those with diabetes, 8.4% for those with hypertension, and 8.0% for those with chronic respiratory disease. The patient who died in our study was a man in his seventies with multiple comorbidities. The critical cases were admitted to the ICU 5, 7, and 7 days after symptom onset. A previous study reported a median of 10.5 days from symptom onset to ICU admission [14]. The delay between symptom onset and exacerbation to respiratory failure may be characteristic of this disease. In mice infected with SARS-CoV-2, early administration of an antiviral agent improved pulmonary function, and reduced virus titer and body weight loss [15]. Although promising antiviral therapy has not been developed, to improve the disease outcome we might have to start antiviral therapy as soon as possible.

SARS-CoV-2 was detected by PCR for 7 days after symptomatic resolution. The longest period from symptom onset to the last PCR positive result in respiratory samples in our cases was 29 days after symptomatic resolution. The time from symptom onset to recovery ranged from 12 to 32 days in a previous study [16]. That study

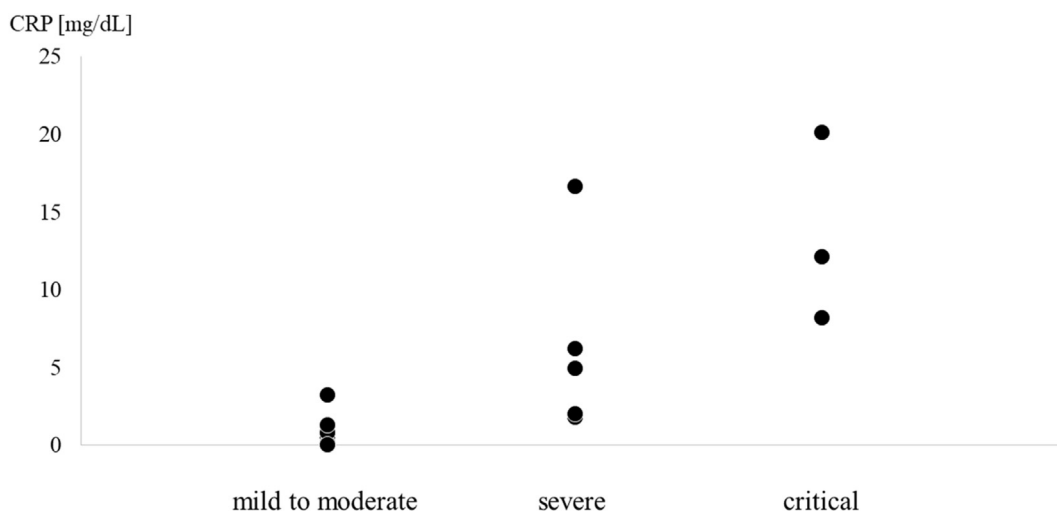


Fig. 2. C-reactive protein (CRP) titer according to disease severity. Critical cases tended to have higher levels of CRP on admission than noncritical cases.

reported that virus was detected again after recovery. We did not perform viral culture in this study and had difficulty in estimating the infectiousness. A study revealed that the virus was readily isolated during the first week of symptoms from a considerable fraction of samples, no isolates were obtained from samples taken after day 8 in spite of ongoing high viral loads [17]. Therefore, it is unclear whether the virus could be transmitted from patients to healthy people for a long time after symptomatic resolution.

This study has limitations. The number of cases was small and the duration of the study was short. Most cases were elderly, and we may not be describing all of the clinical characteristics of COVID-19 infection.

In conclusion, this study extensively describes the clinical characteristics of COVID-19 cases in an outbreak on the cruise ship Diamond Princess.

### Authorship

All authors meet the ICMJE authorship criteria. NT designed the study, and YY wrote the manuscript. NT, HH, HS, and NM provided medical care to the patients. All authors commented on the manuscript and approved the final version.

### Funding

None.

### Declaration of Competing Interest

None.

### Acknowledgments

We appreciate all the member supporting the cases' management in the Yokohama Municipal Citizen's Hospital and the laboratory work in the Yokohama City Institute of Public Health.

### References

- [1] World Health Organization. Coronavirus disease 2019 (COVID-19) situation report – 34. [https://www.who.int/docs/default-source/coronaviruse/situation-reports/20200223-sitrep-34-covid-19.pdf?sfvrsn=44ff8fd3\\_2](https://www.who.int/docs/default-source/coronaviruse/situation-reports/20200223-sitrep-34-covid-19.pdf?sfvrsn=44ff8fd3_2). [Accessed 28 February 2020].
- [2] National Institute of Infectious Diseases. Field briefing: Diamond princess COVID-19 cases. <https://www.niid.go.jp/niid/en/2019-ncov-e/9417-covid-dp-fe-02.html>. [Accessed 28 February 2020].
- [3] Shirato K, Nao N, Katano H, Takayama I, Saito S, Kato F, et al. Development of genetic diagnostic methods for novel coronavirus 2019 (nCoV-2019) in Japan. *Jpn J Infect Dis* 2020. <https://doi.org/10.7883/yoken.JJID.2020.061>.
- [4] National Health Commission of China. Diagnosis and treatment protocols for patients with novel coronavirus pneumonia (Trial version 6, revised). [http://www.kansensho.or.jp/uploads/files/topics/2019ncov/eng\\_clinical\\_protocols\\_v6.pdf](http://www.kansensho.or.jp/uploads/files/topics/2019ncov/eng_clinical_protocols_v6.pdf). [Accessed 19 February 2020].
- [5] Chen N, Zhou M, Dong X, Qu J, Gong F, Han Y, et al. Epidemiological and clinical characteristics of 99 cases of 2019 novel coronavirus pneumonia in Wuhan, China: a descriptive study. *Lancet* 2020;395:507–13.
- [6] Wang D, Hu B, Hu C, Zhu F, Liu X, Zhang J, et al. Clinical characteristics of 138 hospitalized patients with 2019 novel coronavirus-infected pneumonia in Wuhan, China. *JAMA* 2020. <https://doi.org/10.1001/jama.2020.1585>.
- [7] Pan L, Mu M, Yang P, Sun Y, Wang R, Yan J, et al. Clinical characteristics of COVID-19 patients with digestive symptoms in Hubei, China: a descriptive, cross-sectional, multicenter study. *Am J Gastroenterol* 2020 Apr 14. <https://doi.org/10.14309/ajg.0000000000000620>.
- [8] Shi H, Han X, Jiang N, Cao Y, Alwalid O, Gu J, et al. Radiological findings from 81 patients with COVID-19 pneumonia in Wuhan, China: a descriptive study. *Lancet Infect Dis* 2020. [https://doi.org/10.1016/S1473-3099\(20\)30086-4](https://doi.org/10.1016/S1473-3099(20)30086-4). pii: S1473-3099(20)30086-4.
- [9] Zhou F, Yu T, Du R, Fan G, Liu Y, Liu Z, et al. Clinical course and risk factors for mortality of adult inpatients with COVID-19 in Wuhan, China: a retrospective cohort study. *Lancet* 2020;395:1054–62.
- [10] Henry BM, de Oliveira MHS, Benoit S, Plebani M, Lippi G. Hematologic, biochemical and immune biomarker abnormalities associated with severe illness and mortality in coronavirus disease 2019 (COVID-19): a meta-analysis. *Clin Chem Lab Med* 2020 Apr 10. <https://doi.org/10.1515/cclm-2020-0369>. pii: j/cclm.ahead-of-print/cclm-2020-0369/cclm-2020-0369.xml.
- [11] Maxmen A. More than 80 clinical trials launch to test coronavirus treatments. *Nature* 2020;578:347–8.
- [12] Cao B, Wang Y, Wen D, Liu W, Wang J, Fan G, et al. A trial of lopinavir-ritonavir in adults hospitalized with severe covid-19. *N Engl J Med* 2020 Mar 18. <https://doi.org/10.1056/NEJMoa2001282>.
- [13] World Health Organization. Report of the WHO-China joint mission on coronavirus disease 2019 (COVID-19). <https://www.who.int/docs/default-source/coronaviruse/who-china-joint-mission-on-covid-19-final-report.pdf>. [Accessed 28 February 2020].
- [14] Huang C, Wang Y, Li X, Ren L, Zhao J, Hu Y, et al. Clinical features of patients infected with 2019 novel coronavirus in Wuhan, China. *Lancet* 2020;395:497–506.
- [15] Sheahan TP, Sims AC, Zhou S, Graham RL, Pruijssers AJ, Agostini ML, et al. An orally bioavailable broad-spectrum antiviral inhibits SARS-CoV-2 in human airway epithelial cell cultures and multiple coronaviruses in mice. *Sci Transl Med* 2020 Apr 6. <https://doi.org/10.1126/scitranslmed.abb5883>. pii: eabb5883.
- [16] Lan L, Xu D, Ye G, Xia C, Wang S, Li Y, et al. Positive RT-PCR test results in patients recovered from COVID-19. *JAMA* 2020. <https://doi.org/10.1001/jama.2020.2783>.
- [17] Wölfel R, Corman VM, Guggemos W, Seilmaier M, Zange S, Müller MA, et al. Virological assessment of hospitalized patients with COVID-2019. *Nature* 2020 Apr 1. <https://doi.org/10.1038/s41586-020-2196-x>.