

# TILT OF THE RADIUS FROM FOREARM ROTATIONAL AXIS RELIABLY PREDICTS ROTATIONAL IMPROVEMENT AFTER CORRECTIVE OSTEOTOMY FOR MALUNITED FOREARM FRACTURES

MASAHIRO TATEBE, TAKAAKI SHINOHARA, NOBUYUKI OKUI, MICHIRO YAMAMOTO, SHIGERU KURIMOTO, and HITOSHI HIRATA

*Department of Hand Surgery, Nagoya University School of Medicine*

## ABSTRACT

Forearm rotation occurs around an axis connecting the center of the radial head and the fovea of the distal ulna. The purpose of the present study was to demonstrate the usefulness of the difference between forearm and proximal radial axis in the treatment of malunited forearm fractures. We reviewed the results of eight corrective osteotomies for malunited fractures of the forearm without dislocations of the wrist or elbow. Subjects were 6 men and 2 women (mean age, 15 years; range, 10–21 years). Corrective osteotomy was performed at the fracture site. Preoperatively and at final follow-up, the arc of forearm rotation was recorded and anteroposterior and lateral X-rays were taken. Proximal radius tilt was defined as the angle between the rotational axis of the forearm and the axis of the proximal radius. Corrective osteotomy improved proximal radius tilt in all cases. Three patients were considered to have malrotation. Postoperative rotational arc correlated with proximal radial tilt ( $r = -0.83$ ). No significant difference in rotational arc was evident between malunited cases and the remaining cases. To improve forearm rotation, corrective osteotomy should be planned to minimize proximal radius tilt.

**Key words:** Forearm fracture, Corrective osteotomy, Malunion, Axis

This is an Open Access article distributed under the Creative Commons Attribution-NonCommercial-NoDerivatives 4.0 International License. To view the details of this license, please visit (<http://creativecommons.org/licenses/by-nc-nd/4.0/>).

## INTRODUCTION

The forearm is made of two bones, the radius and ulna. These bones have proximal and distal radioulnar joints that allow forearm rotation.<sup>1)</sup> Forearm rotation occurs around an axis connecting the center of the radial head and the fovea of the distal ulna.<sup>2)</sup> Once malunion occurs, forearm rotation becomes limited. Various treatments for malunion have been reported,<sup>1-4)</sup> but the optimal method for reduction remains controversial.<sup>5)</sup> We planned this study to determine numerical values indicative of healing treatment during deformation of the forearm. We therefore investigated cases in which corrective osteotomy was performed for malunion without dislocation of the elbow or wrist. Our hypothesis was that increased differences between the axes of forearm and proximal radius would be associated with increased deterioration of forearm rotational motion.

---

Corresponding Author: Masahiro Tatebe

Department of Hand Surgery, Nagoya University School of Medicine,

65 Tsurumaicho, Showaku, Nagoya 466-8550, Japan


Tel: +81-52-741-2111, Fax: +81-52-744-2964, E-mail: [tatebe@med.nagoya-u.ac.jp](mailto:tatebe@med.nagoya-u.ac.jp).

## MATERIALS AND METHODS

All study protocols were approved by the institutional review board. Data from patients with corrective osteotomies for malunited forearm fractures without dislocation of the elbow or wrist were reviewed retrospectively. Patient demographics were reviewed, including age, sex, and interval between injury and surgery. Mean interval between initial injury and surgery was 21 months (range, 3–47 months). Mean duration of follow-up was 12 months (range, 6–22 months). This retrospective study included eight cases (6 men, 2 women), and mean patient age was 15 years (range, 10–21 years). Fracture type was radioulnar shaft fracture in five cases and radial shaft fracture in three cases. Initial treatment of forearm fractures comprised conservative treatment in five cases and operative treatment in three cases. Pre- and postoperative ranges of motion were obtained from clinical charts. Assessment of forearm pronation-supination was measured using a hand-held goniometer. No patients showed any limitation of wrist or elbow range of motion. We performed corrective osteotomy of the radius alone in five cases, ulna alone in one case, and both radius and ulna in two cases. All osteotomy sites were fixed using plates. All osteotomies were situated at the fracture site, as determined by plain radiography. Intraoperatively, we attempted to restore the normal shape of both bones according to intraoperative fluoroscopic images and anteroposterior and lateral radiographs.

### *Radiological assessment*

We evaluated plain radiographic images using medical image analysis software (Rapideye; Toshiba Medical Systems, Tochigi, Japan). Anteroposterior and lateral radiographs of the forearm were obtained using the same position of forearm rotation (in the neutral position, if possible), with the elbow in 90° of flexion, and the wrist in neutral alignment. Two lines were drawn:



**Fig. 1** The longitudinal (rotational) axis of the forearm runs from the center of the radial head proximally to the fovea of the distal ulna. The axis of the proximal radius runs between the center of the radial head and the radial neck. Proximal radial tilt angle ( $\Delta$ ) represents the angle between the rotational axis of the forearm and the axis of the proximal radius.

the axis of the proximal radial head; and the forearm axis. The angle between these two lines was then measured on both lateral and anteroposterior radiographs (Fig. 1). Proximal radius tilt was defined as the larger angle from the two radiographs. If the tuberosity of the radius and styloid were not on opposite sides of the bone, we determined malrotation by plain radiography. With the ulna, the coronoid process of the ulna and the ulnar styloid process are normally on opposing sides, so we used this relationship to assess malrotation of the ulna.<sup>1)</sup>

#### Statistical analysis

Differences in forearm rotation and in radiological assessments were analyzed using the Mann-Whitney U test. For correlation between rotation and radiological factors, Spearman tests were used. All variables are reported as the mean value  $\pm$  standard deviation. Values of  $p < 0.05$  were considered statistically significant. All data analyses were performed using SPSS version 18 software.

## RESULTS

Mean forearm rotation increased from  $81^\circ$  (range,  $0-135^\circ$ ) preoperatively to  $138^\circ$  (range,  $108-175^\circ$ ) postoperatively. Mean proximal radial tilt angle improved from  $14^\circ$  to  $9.3^\circ$ , compared to  $3.3^\circ$  on the normal side. Postoperative rotation correlated with proximal radial tilt angle, and severe malunion affected the range of forearm rotation (Fig. 2). Three patients were considered to show radial malrotation and no patients displayed ulnar malrotation. Mean rotation in malrotation cases was  $128 \pm 17.2^\circ$ , compared to  $145 \pm 26.9^\circ$  in the remaining cases. No significant

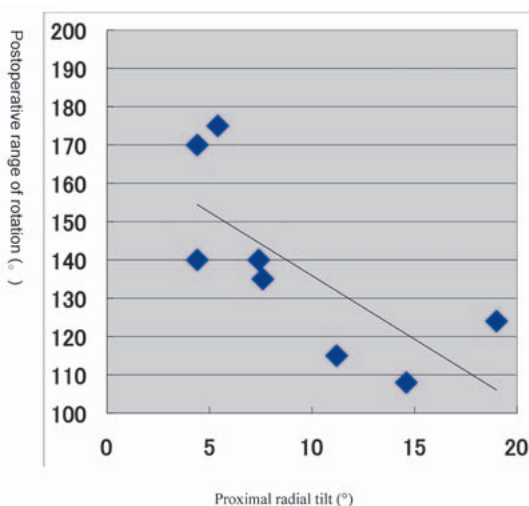


Fig. 2 Postoperative range of rotation versus proximal radial tilt.  $r = -0.825$

Table 1 Data summary

	Preoperative ( $^\circ$ )	Postoperative ( $^\circ$ )	Normal ( $^\circ$ )
Range of rotation	$81.25 \pm 42.57$	$138.38 \pm 24.01$	$173.33 \pm 6.06$
Proximal radial tilt	$14.11 \pm 8.11$	$9.25 \pm 5.28$	$3.25 \pm 1.28$

associations were identified between range of forearm rotation and malrotation. The data are summarized in Table 1.

## DISCUSSION

The forearm is composed of the radius and ulna, which are linked by the interosseous membrane and intercalated between the elbow and wrist.<sup>2)</sup> The forearm rotation axis runs through the center of the radial head to the ulnar head, and radial motion around the ulna results in forearm rotation.<sup>7)</sup> Angular deformity of the forearm affects forearm rotation, so the treatment for malunion of the forearm should be provided by treating the radius and ulna as bones of a joint. The alignment of both bones is essential for good rotational motion.<sup>1)</sup> Although corrective osteotomy can achieve good rotation within 1 year after injury,<sup>5)</sup> the factors contributing to clinical results remain unclear and no reports have clarified how deformity of the axis of rotational motion affects forearm rotation. The present study revealed that forearm axis and proximal radial axis affect forearm rotation. Alignment of the axis of rotation should therefore be performed primarily. The acceptable range of deformity at initial treatment for fracture remains contentious, particularly in pediatric cases, due to good remodeling ability. Our series included skeletally immature cases, but a previous report showed that in diaphyseal fractures, the distal radial epiphyseal plate realigned well only in children under 10 years of age,<sup>8)</sup> so our results appear reasonable.

Some recent papers have reported three-dimensional computed tomography (3DCT) and computer-assisted osteotomy for malunion.<sup>6)</sup> Indeed, we think that malunion of the forearm should be treated in 3D, but we investigated the indicators for corrective osteotomy only on plain radiographs in consideration of radiation exposure and usability. Our methods can thus be applied in the operating theater.

The limitations to this study need to be considered. First, the study was retrospective and the follow-up periods were short. Second, the number of cases was low. We tried to reduce malrotation, and only three cases showed malunion and the degrees of deformity were mild. Differences in each parameter were also relatively small and the small sample size could have limited the statistical power of the analyses. Third, we only investigated two-dimensional bone images. The cause of rotational limitation remains unclear. Bones, ligaments and soft tissues would affect rotation, but the rigid body element must provide the primary effects on forearm rotation. We therefore attempt to reduce forearm bone alignment first. A prospective study of 3D alignments is needed in the future.

We evaluated the results of corrective osteotomy for forearm fracture malunion using plain radiography. To improve the range of rotation, the alignment of both bones needs to be adjusted like a joint. We think the angle between the axis of rotation of the forearm and the axis of the proximal radius offers a useful indicator for corrective osteotomy. This method is simple and can be used during surgery.

## REFERENCES

- 1) Richard MJ, Ruch DS, Aldridge III JM: Malunions and Nonunions of the Forearm. *Hand Clin* 2007; 23: 235–243.
- 2) M. Soubeyrand, V. Wassermann, C. Hirsch, Oberlin C, Gagey O, Dumontier C. The middle radioulnar joint and triarticular forearm complex. *J Hand Surg Eu* 2011; 36: 447–454.
- 3) Price CT, Knapp DR.: Osteotomy for malunited forearm shaft fractures in children. *J Pediatr Orthop*. 2006; 26:193–196.
- 4) Schemitsch EH, Richards RR: The effect of malunion on functional outcome after plate fixation of fractures

## FOREARM AND PROXIMAL RADIAL AXIS

- of both bones of the forearm in adults. *J Bone Joint Surg Am.* 1992; 74: 1068–1078.
- 5) Trousdale RT, RL Linscheid: Operative treatment of malunited fractures of the forearm. *J Bone Joint Surg Am.* 1995; 77: 894–902.
  - 6) Oka K, Murase T, Moritomo H, Goto A, Nakao R, Sugamoto K, Yoshikawa H. Accuracy of corrective osteotomy using a custom-designed device based on a novel computer simulation system. *J Orthop Sci.* 2011; 16: 85–92.
  - 7) Hollister AM, Gellman H, Waters RL. The relationship of the interosseous membrane to the axis of rotation of the forearm. *Clin Orthop Relat Res.* 1994; 298: 272–6.
  - 8) Larsen E, Vistas D, Torp-Pedersen S. Remodeling of angulated distal forearm fractures in children. *Clin Orthop Relat Res* 1988; 237: 190–195.

