



OPEN ACCESS

CASE REPORT

Case of steroid-resistant Crohn's-associated bronchiolitis in the setting of quiescent gastrointestinal disease treated with infliximab

Cher Shiong Chuah,¹ Colin Noble,¹ Andrew Leitch²

¹Department of Gastroenterology, Western General Hospital, Edinburgh, UK
²Department of Respiratory Medicine, Western General Hospital, Edinburgh, UK

Correspondence to
Dr Cher Shiong Chuah,
chershiong@gmail.com

Accepted 24 October 2018

SUMMARY

A fit, 36-year-old man with a history of Crohn's disease previously treated with azathioprine, presented acutely with progressive shortness of breath on exertion and pleuritic chest pain. At the time of presentation, his Crohn's disease was quiescent, supported by a normal faecal calprotectin. The initial chest CT suggested the presence of a diffuse inflammatory disorder and he was subsequently started on high dose oral steroids. Despite 4 months of steroid therapy, there was minimal improvement. Following discussion at the inflammatory bowel disease multidisciplinary team meeting, a decision was made to commence infliximab. Subsequently, he made a dramatic clinical and physiological recovery. His forced expiratory volume in 1 s improved from 2.22 L/min (50% predicted) to 3.65 L/min (93% predicted) and he returned to baseline levels of exercise.

BACKGROUND

Primary pulmonary manifestations of inflammatory bowel disease (IBD) in the context of quiescent gastrointestinal disease are rare and it is even rarer to encounter steroid-resistance. There is limited evidence for therapy in this setting and this case report highlights a therapeutic intervention that resulted in a dramatic clinical and physiological recovery.

CASE PRESENTATION

This 36-year-old man was first diagnosed with colonic Crohn's disease in 2009. He had experienced no extraintestinal manifestations. He was started on azathioprine 125 mg once daily (OD) and remained in clinical remission from 2010 to 2016. At that point his azathioprine therapy was stopped. Unfortunately 8 months later, he had a flare and his faecal calprotectin was 1180 µg/g (<250 µg/g indicating biochemical remission).¹ This settled rapidly with oral steroids and the reintroduction of azathioprine.

A few months after this, he presented to the medical assessment unit with a 2-week history of progressive shortness of breath on exertion and right-sided pleuritic chest pain. His baseline activity levels included a 20 km per day cycle to and from work. At presentation, he could barely manage a single flight of 10 stairs. He had a non-productive cough but no fever.

At this point his Crohn's was inactive and he had no bowel symptoms. The patient's Harvey-Bradshaw Index score was 0.

Observations included: blood pressure 120/75 mm Hg, pulse 120 bpm, oxygen saturation 90% on room air. Examination of the chest revealed bibasal inspiratory crackles.

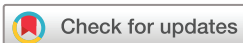He was on no regular medication apart from azathioprine 125 mg OD. There was no history of foreign travel and no history of previous respiratory disease. The patient worked in an office environment. He had a newborn baby at home who was well and there were no other significant respiratory exposures.

Initial investigations including routine blood tests and chest X-ray were unremarkable and he proceeded to CT pulmonary angiogram to exclude pulmonary embolism. The CT pulmonary angiogram revealed extensive ground glass nodularity throughout both lungs and concluded that the diffuse pulmonary parenchymal abnormality would be in keeping with a hypersensitivity pneumonitis or an atypical infection (figure 1). Initial microbiological testing (see the Investigations section) was negative.

His azathioprine was stopped in case it was provoking a hypersensitivity reaction, and he was started empirically on a course of clarithromycin. His oxygen saturations improved and he was discharged to recuperate at home. He was reviewed 2 weeks later but felt as unwell as at presentation. At this point, he was initiated on a reducing course of oral prednisolone starting at a dose of 40 mg OD.

Two weeks later, he was readmitted with worsening shortness of breath. A repeat CT pulmonary angiogram (figure 2) demonstrated no pulmonary embolism and showed ongoing ground glass with areas of significant air-trapping. The diagnosis of Crohn's associated bronchiolitis was made and his dose of prednisolone was fixed at 60 mg OD until further review. His oxygen saturations normalised and he was discharged.

The patient was reviewed regularly on an outpatient basis by the respiratory team but at 3 months later, he had not made a significant improvement in terms of exercise capacity or pulmonary physiology despite compliance with high dose oral steroids (the patient was obviously Cushingoid by this point). A faecal calprotectin was tested and it returned at a value of 53 µg/g (<250 µg/g indicating biochemical



© BMJ Publishing Group Limited 2018. Re-use permitted under CC BY-NC. No commercial re-use. See rights and permissions. Published by BMJ.

To cite: Chuah CS, Noble C, Leitch A. *BMJ Case Rep* 2018;**11**:e226934. doi:10.1136/bcr-2018-226934

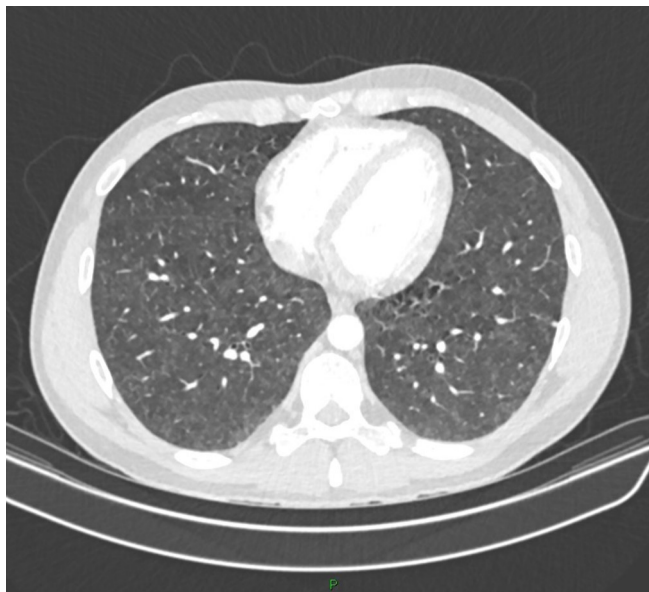

Figure 1 Initial CT pulmonary angiogram demonstrating ground-glass nodularity.

remission). Given the atypical nature of the case, he was discussed at the IBD multidisciplinary team meeting. The consensus of the meeting was that once infection (especially pulmonary tuberculosis) had been more robustly excluded at bronchoscopy (results below), an empirical trial of infliximab should be undertaken. The patient preferred not to have transbronchial lung biopsy (or indeed formal lung biopsy) performed because of the perceived risk of these interventions. Given there were still no bowel-related symptoms colonoscopic investigation was not undertaken.

INVESTIGATIONS

Initial microbiological investigations

Respiratory virus throat swab (PCR): Negative for common respiratory viruses and mycoplasma.
Sputum cultures x3: Negative for bacteria, mycobacteria and fungi.

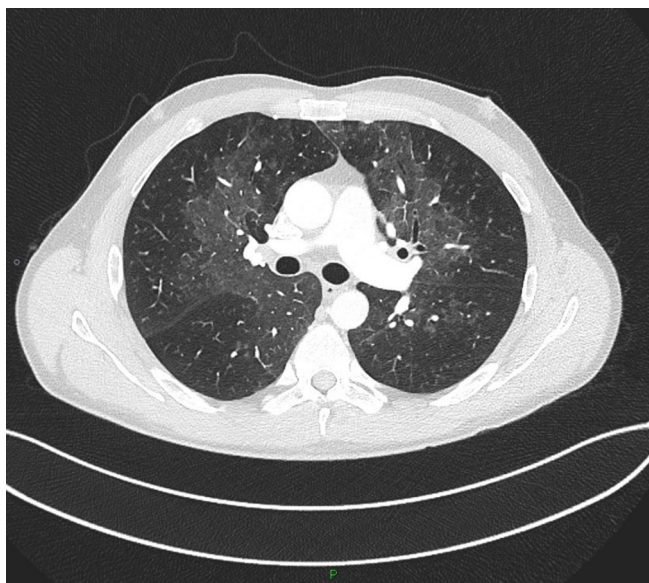


Figure 2 Repeat CT pulmonary angiogram 2 weeks later.

Blood cultures x2: Negative.
HIV test (PCR): Negative.

Further microbiological investigations

Bronchoscopy lavage: No acid-fast bacilli (AFB), mycobacterial culture negative, no bacteria, no fungi, viral PCR negative, pneumocystis PCR negative.
QuantiFERON gold testing: Negative.
Bronchoscopy airway wall biopsy: Mild, chronic inflammation.

DIFFERENTIAL DIAGNOSIS

The differential diagnosis initially included pulmonary infection, hypersensitivity pneumonitis to azathioprine and cryptogenic organising pneumonia. Despite extensive microbiological testing (including repeat isolates) no organisms were identified. Stopping the only potential causative agent (azathioprine) made no difference to the clinical picture. Pulmonary physiological testing revealed very significant airways obstruction with no gas transfer deficit. The initial CT scan demonstrated diffuse, nodular ground-glass shadowing but repeat CT demonstrated a mosaic attenuation pattern in keeping with gas-trapping and a bronchiolitis picture. While Crohn's is classically associated with large airway pathology (bronchiectasis) it can also manifest in small-airway form (bronchiolitis).

TREATMENT

Following the confident exclusion of infection (see the Investigations section) the patient was counselled and started on infliximab therapy at 5 mg/kg with loading at 0, 2 and 6 weeks and subsequently for eight weekly maintenance therapy.

OUTCOME AND FOLLOW-UP

Within a week of starting infliximab, he responded clinically and felt less breathless. Monitoring of his pulmonary function tests over the next 3 months revealed a dramatic improvement in his lung function, with an eventual return back to normality. This rapid response was in stark contrast to his time on oral steroid therapy (figure 3, table 1). His steroids were rapidly weaned following response to infliximab, and he continues to be followed up by both the gastroenterology and respiratory teams.

DISCUSSION

There are a wide variety of pulmonary abnormalities that can affect patients with IBD on immunosuppression including respiratory infection and direct drug toxicity.² However, primary

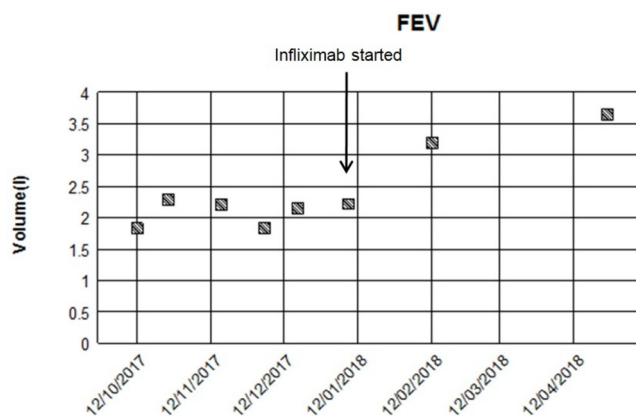


Figure 3 Forced expiratory volume in 1 s (FEV₁) over time. Infliximab was commenced in January 2018.

Table 1 Ventilatory capacity report from January 2018 (baseline) to April 2018 (postinfliximab)

Date	8 January 2018	12 February 2018	26 April 2018			Range
			Value	% Pred	Predicted	
Ventilatory capacity						
FEV ₁ (L)	2.22	3.19	3.65	93	3.94	3.10–4.78
VC (L)	4.93	5.83	5.89	124	4.74	3.73–5.75
FEV ₁ /VC (%)	45.00	55.00	62.00		80.70	68.80–92.50
PEFR (L/min)	633	710	707	127	556	436–677

FEV₁, forced expiratory volume in 1 s; PEFR, peak expiratory flow rate; VC, vital capacity.

pulmonary disease associated with IBD is rare. Within this subgroup, the most commonly described pulmonary extraintestinal manifestations are bronchiectasis and cryptogenic organising pneumonia.³

The approach to evaluating IBD patients with respiratory symptoms should begin with consideration of infectious and drug-related aetiologies. Appropriate investigations include extended range sputum testing, respiratory virus throat swab, chest X-ray, pulmonary physiology and bronchoscopy. This case demonstrates that highly active IBD luminal disease is not required for the emergence of an extraintestinal manifestation of the disease and absence of luminal disease activity should not be relied on to make or exclude the diagnosis. Interestingly, in a series of patients with IBD-associated pulmonary disease 80% developed the disease after colectomy suggesting pulmonary inflammation increased or emerged after the elimination of bowel inflammation.⁴ Other extraintestinal manifestations of IBD such as cutaneous, ocular and joint disease may flare independently of bowel disease or even present before IBD is diagnosed. Mechanistic elucidation of this phenomenon is beyond the scope of our report.

The mainstay of diagnosis of a pulmonary manifestation of IBD is CT scanning. Bronchoscopy with bronchoalveolar lavage may be helpful in excluding infection and transbronchial lung biopsy may be diagnostic in the presence of a diffuse parenchymal abnormality. Formal surgical lung biopsy may also provide a histological diagnosis but the risks associated with this procedure should not be underestimated and (as in this case) may not be acceptable to the patient.

Patient's perspective

In August of 2017 I developed inflammation within my lungs; over a period of 2–3 weeks I went from cycling c. 25 km 3–4 times a week to barely able to climb a flight of stairs. Several months of treatment with high doses of steroids had limited effect, I went from having to stop in the middle of a flight of stairs to potentially being able to climb a flight in one go but being left very out of breath by the exertion.

I had my first infusion of infliximab/inflextra in late January 2018. This had what seemed to me to be an immediate effect. Within days I felt significantly better and within a short number of weeks I was able to comfortably carry out activities which would have left me breathless prior to the infusion. This was an immense relief after many months of illness and worry. I have now been on Infliximab for a little over 6 months and the effect has been transformational; I feel I am healthy once again, I am back to commuting by bike and am rebuilding fitness after what was a long period of illness.

The evidence-base for treatment of pulmonary extraintestinal manifestations is very limited due to the rarity of this presentation. The literature is largely centred on the use of oral or inhaled corticosteroids.⁵ However, as this case demonstrates, treatment in the context of corticosteroid failure is an evidence-free zone.

Infliximab has been shown to be effective for a number of extraintestinal manifestations of IBD, including arthritis, pyoderma gangrenosum and uveitis.⁶ However, there are limited data in the literature surrounding the use of infliximab for IBD-related organising pneumonia and bronchiolitis in the form of case reports.^{7–11} It is important to point out that these all describe pulmonary manifestations in the context of active Crohn's disease, making it easier to justify the use of anti-tumour necrosis factor (TNF) therapy and suggest that resolution of the active disease is the prime driver of response to treatment.

An interesting feature of the present case is that the patient's Crohn's was quiescent when he developed significant respiratory compromise and an empirical trial of infliximab was solely targeting his pulmonary disease. An added benefit of infliximab in this situation is that it will allow maintenance of long-term luminal disease remission in a patient previously dependent on long-term azathioprine.

Learning points

- ▶ Pulmonary manifestations of inflammatory bowel disease (IBD) are rare and can occur despite quiescent disease.
- ▶ Infliximab can be a useful strategy for pulmonary inflammatory manifestations especially when response to conventional glucocorticoids is poor.
- ▶ It is important to fully exclude infection and drug-related causes of pulmonary disease in IBD before commencing infliximab.

Acknowledgements We would like to thank the patient involved for allowing us to share his experience with the wider medical community.

Contributors CSC drafted the manuscript and obtained consent and input from the patient. CN and AL supervised, reviewed and edited the draft. AL provided further critical revisions to the final version. All authors reviewed and approved the final manuscript.

Funding The authors have not declared a specific grant for this research from any funding agency in the public, commercial or not-for-profit sectors.

Competing interests None declared.

Patient consent Obtained.

Provenance and peer review Not commissioned; externally peer reviewed.

Open access This is an open access article distributed in accordance with the Creative Commons Attribution Non Commercial (CC BY-NC 4.0) license, which permits others to distribute, remix, adapt, build upon this work non-commercially, and license their derivative works on different terms, provided the original work

is properly cited and the use is non-commercial. See: <http://creativecommons.org/licenses/by-nc/4.0/>

REFERENCES

- 1 D'Haens G, Ferrante M, Vermeire S, *et al*. Fecal calprotectin is a surrogate marker for endoscopic lesions in inflammatory bowel disease. *Inflamm Bowel Dis* 2012;18:2218–24.
- 2 Schleiermacher D, Hoffmann JC. Pulmonary abnormalities in inflammatory bowel disease. *J Crohns Colitis* 2007;1:61–9.
- 3 Camus P, Colby TV. The lung in inflammatory bowel disease. *Eur Respir J* 2000;15:5–10.
- 4 Kelly MG, *et al*. Inflammatory bowel disease and the lung: is there a link between surgery and bronchiectasis? *Int J Colorectal Dis*.
- 5 Ji XQ, Wang LX, Lu DG. Pulmonary manifestations of inflammatory bowel disease. *World J Gastroenterol* 2014;20:13501–11.
- 6 Barrie A, Regueiro M. Biologic therapy in the management of extraintestinal manifestations of inflammatory bowel disease. *Inflamm Bowel Dis* 2007;13:1424–9.
- 7 Hayek AJ, Pfanner TP, White HD. Inflammatory bowel disease of the lung: the role of infliximab? *Respir Med Case Rep* 2015;15:85–8.
- 8 Pedersen N, Duricova D, Munkholm P. Pulmonary Crohn's disease: a rare extra-intestinal manifestation treated with infliximab. *J Crohns Colitis* 2009;3:207–11.
- 9 Alrashid AI, Brown RD, Mihalov ML, *et al*. Crohn's disease involving the lung: resolution with infliximab. *Dig Dis Sci* 2001;46:1736–9.
- 10 Kirkcaldy J, Lim WS, Jones A, *et al*. Stridor in Crohn disease and the use of infliximab. *Chest* 2006;130:579–81.
- 11 Krishnan S, Banquet A, Newman L, *et al*. Lung lesions in children with Crohn's disease presenting as nonresolving pneumonias and response to infliximab therapy. *Pediatrics* 2006;117:1440–3.

Copyright 2018 BMJ Publishing Group. All rights reserved. For permission to reuse any of this content visit <https://www.bmj.com/company/products-services/rights-and-licensing/permissions/>
BMJ Case Report Fellows may re-use this article for personal use and teaching without any further permission.

Become a Fellow of BMJ Case Reports today and you can:

- ▶ Submit as many cases as you like
- ▶ Enjoy fast sympathetic peer review and rapid publication of accepted articles
- ▶ Access all the published articles
- ▶ Re-use any of the published material for personal use and teaching without further permission

For information on Institutional Fellowships contact consortiasales@bmjgroup.com

Visit casereports.bmj.com for more articles like this and to become a Fellow