

## CASE REPORT

# Congenital duplicated incus in the mastoid cavity

Dorothy W. Pan  | Courtney C. J. Voelker 

Caruso Department of Otolaryngology  
– Head and Neck Surgery, Keck  
School of Medicine of the University  
of Southern California, Los Angeles,  
California, USA

**Correspondence**

Dorothy W. Pan, Caruso Department  
of Otolaryngology – Head and Neck  
Surgery, Keck School of Medicine of the  
University of Southern California, 1537  
Norfolk Street, Suite 5800, Los Angeles,  
CA 90033, USA.  
Email: dorothy.pan@med.usc.edu

**Funding information**

None

**Abstract**

Many congenital ossicular chain malformations exist, usually involving ossicular deformities, fixation, absence, or discontinuity. Duplication of ossicles has not been reported, much less a duplicated ossicle located in the mastoid. We present a case of a patient who had a duplicated incus in the mastoid antrum.

**KEYWORDS**

congenital ossicular malformation, mastoidectomy, otology, otorrhea, tympanoplasty

## 1 | INTRODUCTION

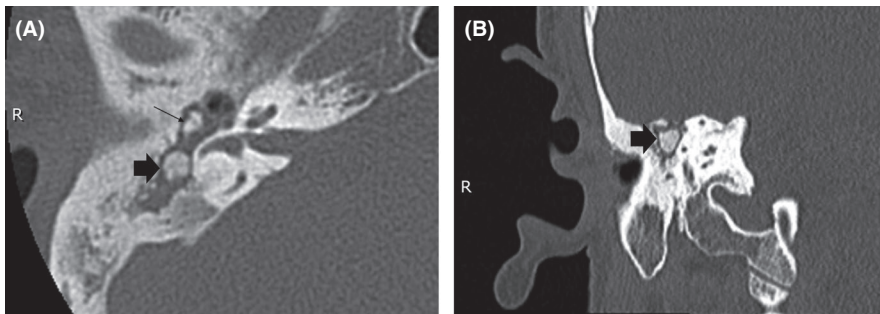
Many congenital ossicular chain malformations exist, usually involving ossicular deformities, fixation, absence, or discontinuity.<sup>1</sup> Duplication of ossicles has not been reported in the literature, much less a duplicated ossicle located in the mastoid cavity. Osteomas are benign bony neoplasms which can occur in the mastoid or middle ear.<sup>2,3,4</sup> In some cases, an osteoma can obstruct the mastoid antrum or external auditory canal leading to otorrhea, infection, or cholesteatoma.<sup>2</sup> Tympanoplasty and mastoidectomy to remove the osteoma and thus the obstructed antrum or external auditory canal can resolve the chronic otorrhea and infection. We present a case of a patient with chronic otorrhea for years who had what appeared to be an osteoma on computed tomography (CT) imaging, which had the appearance of a duplicated incus in the mastoid antrum when removed intraoperatively. The otorrhea resolved after undergoing a tympanoplasty and mastoidectomy including removal of the duplicated incus.

## 2 | CASE REPORT

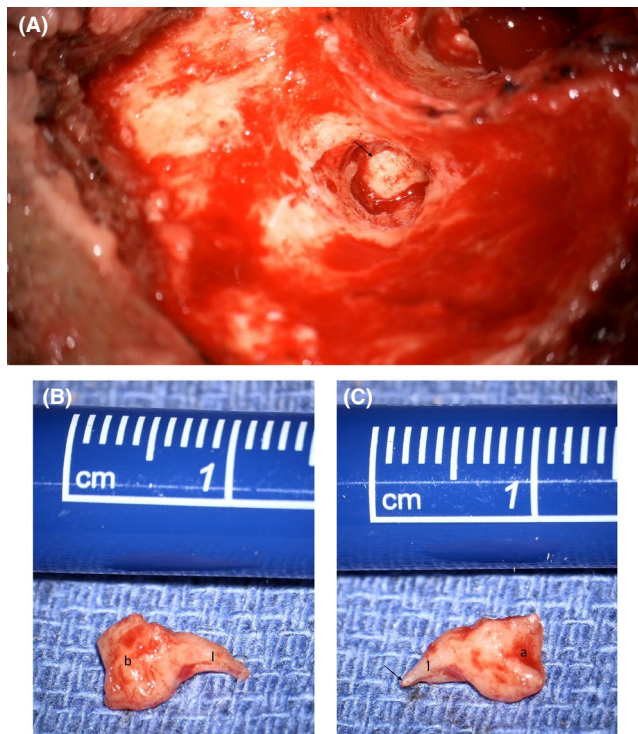
A 39-year-old man with a history of bilateral chronic otorrhea presented to our clinic. He had undergone multiple tympanoplasties bilaterally, 4 on the right and 2 on the left, at another institution. He complained of persistent right otorrhea for multiple years. On binocular otomicroscopy, his right ear canal and tympanic membrane were moist, and the tympanic membrane was thickened and opaque limiting visualization of the middle ear space. Cultures on multiple occasions showed both staphylococcus and aspergillus species. Treatment with antibiotic and antifungal drops and powder as well as dry ear precautions improved the ear drainage; however, the otorrhea would invariably recur. Because of the persistent otorrhea despite appropriate treatment, a CT scan was ordered. The CT scan (Figure 1) showed an abnormal radiopaque density in the right underpneumatized and sclerotic mastoid with similar density as the mastoid bone. His audiogram showed a right-sided mild-to-moderate mixed hearing loss with an air-bone gap of 15 dB.

This is an open access article under the terms of the Creative Commons Attribution-NonCommercial-NoDerivs License, which permits use and distribution in any medium, provided the original work is properly cited, the use is non-commercial and no modifications or adaptations are made.

© 2022 The Authors. *Clinical Case Reports* published by John Wiley & Sons Ltd.



**FIGURE 1** CT images of the right temporal bone showing a radiopaque density in the mastoid cavity. (A) Axial cut showing normal incus (arrow) in the middle ear with the duplicated incus in the antrum (arrowhead). (B) Coronal cut showing the duplicated incus (arrowhead) in the antrum



**FIGURE 2** Intraoperative photographs showing the duplicated incus in the right mastoid cavity. (A) Initial view through a small cortical mastoidectomy revealing an abnormal bony object (arrow) in the mastoid cavity. (B and C) Images of the duplicated incus which is approximately 8mm long after removal from the mastoid cavity. The duplicated incus includes an incus body (b), area for articulation with malleus (a), and incus long process (l), as well as possibly a lenticular process for articulation with the stapes (arrow)

Due to the persistent recurrent right-sided otorrhea and the mastoid ossification, the decision was made for surgery to undergo a right revision tympanoplasty with mastoidectomy. Intraoperatively, the external ear canal skin appeared unhealthy containing infected debris which grew staphylococcus and aspergillus species on wound culture. The tympanic membrane contained thickened scar tissue. The anterior external auditory canal skin and tympanic membrane were removed. The middle ear had tympanosclerosis and adhesions which were lysed to

reveal a foreshortened and medialized malleus with otherwise intact and mobile ossicular chain. The mastoid was underpneumatized and sclerotic, with absence of air cells except for one air cell surrounding an abnormal bony formation, which when removed en bloc appeared to be a duplicated incus (Figure 2). There was inflamed mucosa surrounding this duplicated incus which appeared to be blocking the antrum, but there was no evidence of any cholesteatoma. The tympanic membrane was reconstructed with periosteum using a lateral graft technique. Split thickness skin grafts were taken to reconstruct the anterior ear canal skin. The tympanic membrane graft healed well without recurrence of otorrhea at 6 months postoperatively.

### 3 | DISCUSSION

This report describes an unusual case of a congenital duplicated incus located in the mastoid cavity, which has not previously been reported in the literature. Congenital ossicular abnormalities are often associated with anomalies of the external, middle, or inner ear, however, can occur in isolation.<sup>1</sup> Isolated ossicular abnormalities most commonly involve congenital stapes fixation. There also could be abnormalities in the incus including discontinuity between the incus and stapes, and deformities in the malleus including malleus fixation. Though there is a possibility of duplicated external auditory canal in first branchial arch malformations, there were no reports of duplicated ossicles.

An osteoma presenting in the temporal bone is also a rare benign slow-growing neoplasm. These are more commonly found in the external auditory canal. Mastoid osteomas have been described, usually presenting on the surface of the outer cortex of the mastoid bone resulting in a slow-growing post-auricular mass.<sup>2</sup> More rarely, they can occur within the mastoid and middle ear including approximately 24 case reports of middle ear osteomas in the English literature.<sup>3,4</sup> These lesions can occur in the antrum and attic, which results in disruption of the ossicular chain or cholesteatoma. Osteomas

generally appear to be a well-circumscribed mass with bone density on CT scan. Intraoperatively, they have a convex rounded surface and are easily detached from surrounding structures. The etiology of these osteomas has been hypothesized to be congenital, inflammatory/infectious, or traumatic.

Our patient, however, does not appear to have a straightforward osteoma. It is possible the patient's chronic otitis media could have led to inflammation causing the development of an osteoma that has the appearance and shape of an incus. However, the shape appears to be that of an incus, raising questions about whether this is a duplicated incus in the mastoid antrum that was the initial cause of the chronic otitis media and otorrhea. After removal of the ossification from the mastoid en bloc, it was immediately apparent that it had structures resembling an incus including an incus body, an area for articulation with the malleus, and long process of the incus (Figure 2b and 2c). There was possibly a lenticular process that was fractured off during removal. The length of the osteoma also appears consistent to that of an incus, which is on average 7mm in humans. Histology of this duplicated incus is not available as the pathologist only performed a gross examination. Though there are reports of storing the incus in the mastoid during surgery for cholesteatoma for future use in a second look surgery with ossicular reconstruction,<sup>5</sup> in our patient, this was a second incus in the mastoid with a normal and intact ossicular chain. This appears to be a congenital duplicated incus blocking the antrum which resulted in a chronically inflamed middle ear leading to tympanic membrane perforations and ear infections.

## 4 | CONCLUSION

This is an unusual case of a patient who had a congenital duplicated incus which was blocking the mastoid antrum. Multiple tympanoplasties had not resolved his chronic infections and otorrhea, and in this case, obtaining imaging to visualize any mastoid abnormalities revealed the need to perform a mastoidectomy to remove this bony abnormality and improve middle ear aeration. In cases of revision tympanoplasties with recurrent perforations and otorrhea, imaging as well as performing a mastoidectomy based on imaging findings is warranted to resolve the chronic otorrhea and allow for a tympanic membrane graft to heal appropriately.

## ACKNOWLEDGMENTS

We thank our patient who granted us permission for his case and images to be published. This case report was deemed to be Not Human Subjects Research and approved by the USC IRB.

## CONFLICTS OF INTEREST

None.

## AUTHOR CONTRIBUTION

DWP performed the literature review, wrote the manuscript, and prepared the figures. CJV proposed the idea for the manuscript, revised the manuscript, and approved the submission.

## CONSENT

Written informed consent was obtained from the patient to publish this report in accordance with the journal's patient consent policy.

## ORCID

Dorothy W. Pan  <https://orcid.org/0000-0003-4066-7750>

Courtney C. J. Voelker  <https://orcid.org/0000-0001-7984-3630>

## REFERENCES

1. Yang F, Liu Y. Reporting and description for congenital middle ear malformations to facilitate surgical management. *Ann Otol Rhinol Laryngol*. 2018;127(10):717-725. doi:10.1177/0003489418792939
2. Abhilasha S, Viswanatha B. Osteomas of temporal bone: a retrospective study. *Indian J Otolaryngol Head Neck Surg*. 2019;71(S2):1135-1139. doi:10.1007/s12070-017-1244-9
3. Kim CW, Oh SJ, Kang JM, Ahn HY. Multiple osteomas in the middle ear. *Eur Arch Oto-Rhino-Laryngology*. 2006;263(12):1151-1154. doi:10.1007/s00405-006-0123-x
4. Domínguez Pérez ÁD, Romero RR, Durán ED, Montaña PR, Bernal RA, Rodríguez CM. The mastoid osteoma, an incidental feature? *Acta Otorrinolaringol*. 2011;62(2):140-143. doi:10.1016/s2173-5735(11)70024-2
5. Gyo K, Hato N, Shinomori Y, Hakuba N. Storage of the incus in the mastoid bowl for use as a columella in staged tympanoplasty. *Auris Nasus Larynx*. 2007;34(1):5-8. doi:10.1016/j.anl.2006.05.018

**How to cite this article:** Pan DW, Voelker CCJ. Congenital duplicated incus in the mastoid cavity. *Clin Case Rep*. 2022;10:e05279. doi:[10.1002/ccr3.5279](https://doi.org/10.1002/ccr3.5279)