

Laparoscopic Salpingectomy for an Isolated Case of Left Fallopian Tube Torsion in a Premenarcheal 13 years old

Annabelle Sabu Vadukkut*, Abhishek Mangeshikar, Sonam Jadhav, Sushil Kumar

Department of Obstetrics and Gynecology, MGM Medical College and Hospital, Navi Mumbai, Maharashtra, India

Abstract

Isolated torsion of the fallopian tube without an ovarian abnormality is an uncommon clinical finding even rarer before menarche and postmenopause, with an incidence of approximately 1 in 1.5 million women. Left fallopian tube torsion is infrequent as compared to right. Here, we report a rare case of a prepubertal girl who presented with acute left abdominal pain. Ultrasound suggested normal ovaries, and a significant left hydrosalpinx and color-Doppler was done, which confirmed signs of left-sided fallopian tube torsion. On laparoscopy, her left fallopian tube was twisted around its axis five times with the signs of necrosis, a laparoscopic salpingectomy was performed. Laparoscopy is the gold standard for the diagnosis and management of this condition. A high index of suspicion is necessary to make an early diagnosis allowing conservative surgical management and hence fertility preservation.

Keywords: Acute abdominal pain, isolated left fallopian tube torsion, laparoscopic salpingectomy, premenarcheal pelvic pain

INTRODUCTION

Acute pelvic pain has a wide spectrum of differential diagnosis. Isolated fallopian tube torsion with normal ovaries is one of the rarest causes in this spectrum. Isolated fallopian tube torsion is defined as the twisting of the fallopian tube by at least one complete turnaround over a center-line consisting of the infundibulopelvic ligament or tubo-ovarian ligament.^[1] It was primarily described by Bland-Sutton in 1890 and affects about 1 in 1.5 Million women.^[2] It is extremely rare before puberty, and after menopause, preoperative diagnosis is very difficult because of nonspecific clinical presentation with no ovarian abnormality on ultrasound.^[3] Hence, it is challenging for most clinicians to differentiate it from other causes of acute and subacute abdominal pain. Laparoscopy is the gold standard in the diagnosis and management.^[4] Early surgical intervention is essential to salvage the tube before the stage of necrosis occurs, for which only salpingectomy is the solution.

Article History:

Submitted: 2 October 2018

Revised: 13 November 2018

Accepted: 16 March 2020

Published: 15 October 2020

CASE REPORT

A 13-year-old female patient presented to our emergency room with complaints of left-sided lower abdominal pain for the past 3 days associated with episodes of vomiting. It was a sharp (shooting), nonradiating pain (in nature), with no associated complaints of fever/bowel/urinary symptoms/vaginal discharge. She had not yet achieved her menarche. No history of sexual intercourse/contacts. Secondary sexual characters were present. On abdominal examination, there was tenderness on deep palpation of the left iliac region with no evidence of any mass. No signs of hemoperitoneum.

Her hematological investigations were normal, and the urine pregnancy test was negative. Ultrasound revealed a (tender) cyst with few incomplete septae within measuring 6 cm × 3.4 cm in the left adnexal region and Pouch of Douglas

Address for correspondence: Dr. Annabelle Sabu Vadukkut, Department of Obstetrics and Gynecology, MGM Medical College and Hospital, Navi Mumbai, Maharashtra, India. E-mail: annabellesabu04@hotmail.com

This is an open access journal, and articles are distributed under the terms of the Creative Commons Attribution-NonCommercial-ShareAlike 4.0 License, which allows others to remix, tweak, and build upon the work non-commercially, as long as appropriate credit is given and the new creations are licensed under the identical terms.

For reprints contact: WKHLRPMedknow_reprints@wolterskluwer.com

How to cite this article: Vadukkut AS, Mangeshikar A, Jadhav S, Kumar S. Laparoscopic salpingectomy for an isolated case of left fallopian tube torsion in a premenarcheal 13 years old. Gynecol Minim Invasive Ther 2020;9:245-7.

Access this article online

Quick Response Code:



Website:
www.e-gmit.com

DOI:
10.4103/GMIT.GMIT_90_18

posterior to the uterus and left ovary, which was suggestive of hydrosalpinx. The uterus was normal, and the right ovary was poorly delineated. The Mantoux test was negative. Tumor marker tests were as follows: carcinoembryonic antigen: 0.51, cancer antigen (CA)-125: 15.95, CA 19.9: 7.02, alpha-fetoprotein: 1.11, beta-human chorionic gonadotropin: 5.6. A plain pelvis magnetic resonance imaging revealed a tortuous and dilated left fallopian tube with maximum diameter (measuring) of 2.6 cm appearing hyperintense on T2/short time inversion recovery with peripheral enhancement on postcontrast study which was suggestive of left-sided hydrosalpinx. As the above investigations (were suggestive of hydrosalpinx), she was admitted and treated as a case of suspected torsion of hydrosalpinx with a possible ovarian cyst and was planned for laparoscopic evaluation with de-torsion of the tube and ovarian cystectomy (A Doppler ultrasound was done only before the surgery). Doppler findings revealed a 5.8 cm × 3.2 cm mass in the left adnexa with absent vascularity in the fimbriae end. Absent vascularity was a red alert sign. On laparoscopy, a black, necrotic-appearing, edematous left fimbriae were noted with her left fallopian tube dilated and twisted along its axis five times. Figure 1 shows twisted left Fallopian tube. Her left ovary was not involved and was macroscopically normal (in appearance). Her uterus and right adnexa were also normal, and no paratubal or paraovarian cysts were noted. Figure 2

shows uterus with both Fallopian tubes. Untwisting of the tube was attempted [Figure 3]. Untwisting of the left Fallopian tube but her left Fallopian tube was irreversibly damaged; thus, salpingectomy was performed [Figure 4] left salpingectomy. She was discharged 3 days after the surgery and had an uncomplicated postoperative course. Histopathological examination (the frozen section was not performed) revealed hematosalpinx with hemorrhagic necrosis of tubal wall consistent with tubal torsion.

DISCUSSION

There are several hundred cases of Fallopian tube torsion mentioned in medical literature till date. The exact physiology and mechanism of fallopian tube torsion are unknown. Tubal torsion is more common on the right side, possibly because of the presence of the sigmoid mesentery on the left side, preventing the free mobilization of the tube and because right lower quadrant pain is more often surgically explored suspecting appendicitis.^[5] There are various intrinsic and extrinsic risk factors that could cause this event, such as pelvic inflammatory disease, hydrosalpinx, tubal neoplasm, and extrinsic risk factors such as adhesions, adjacent ovarian, and paraovarian masses, uterine masses, gravid uterus, and trauma.^[6] In our case, the main risk factors were ruled out, suggesting the possibility of a congenital long Fallopian tube or hydrosalpinx due to pelvic inflammatory disease. The authors mean to say that the patient

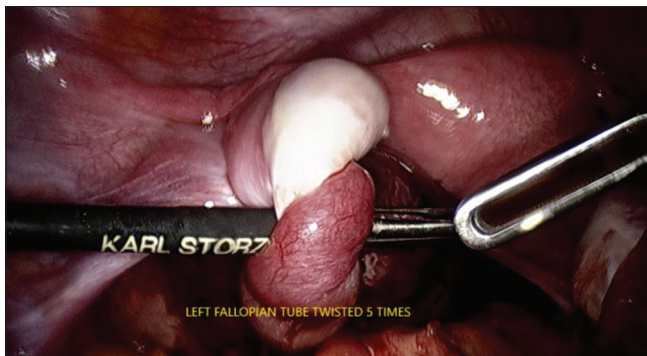

Figure 1: Twisted left fallopian tube

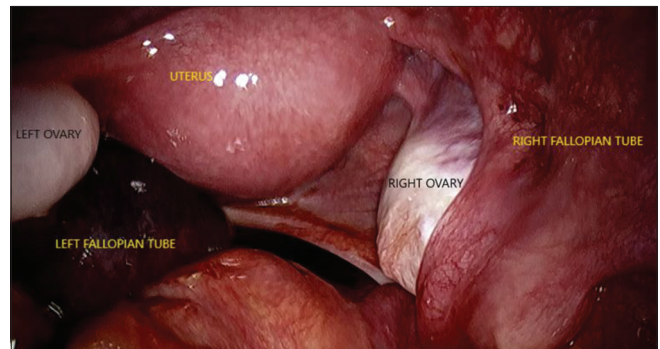


Figure 2: Uterus with both fallopian tubes

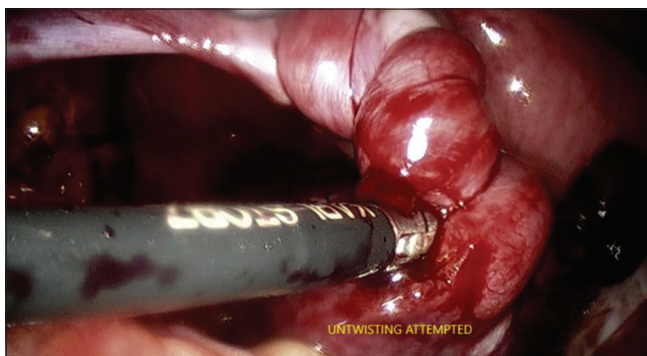

Figure 3: Untwisting of the left fallopian tube

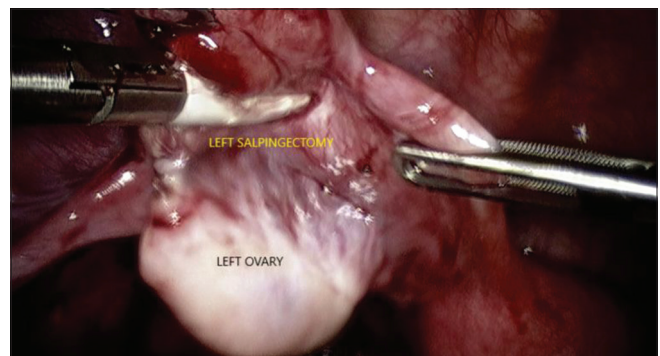


Figure 4: left salpingectomy

may be having chronic pelvic inflammatory disease possibly due to genital tuberculosis. Hence this is justified by absence of fever and normal total leucocyte counts. Complications include tube necrosis and gangrenous transformation, leading to superinfection and peritonitis.^[2] Local necrosis can also result in irreversible damage to the ipsilateral ovary.^[7] Hence it is important to diagnose this condition avoiding morbidity and irreversible damage to the adnexa. Laparoscopy is preferred over laparotomy since recovery after laparoscopy is faster, and it causes fewer pelvic adhesions.^[3] Therefore, Fallopian tube torsion should be kept in mind while investigating (and diagnosing) acute abdominal and pelvic pain in all adolescent girls. Prompt recognition and surgical management of this relatively uncommon source of pelvic pain may prevent unnecessary tubal resection and improve long-term fertility in this population.

Ethical approval

The Institutional Ethics Committee of MGM Medical College, Navi Mumbai has approved our study, and the approval number: N-EC/2019/09/85 was obtained on September 26th in 2019.

Declaration of patient consent

The authors certify that they have obtained all appropriate patient consent forms. In the form, the legal guardians have

given the consent for images and other clinical information to be reported in the journal. The understand that name and initials will not be published and due efforts will be made to conceal identity, but anonymity cannot be guaranteed.

Financial support and sponsorship

Nil.

Conflicts of interest

There are no conflicts of interest.

REFERENCES

1. Ahn JH, Chung J, Lee TS. Successful laparoscopic surgery for 14-month-old infant with ovarian torsion. *Obstet Gynecol Sci* 2014;57:160-3.
2. Ferrera PC, Kass LE, Verdile VP. Torsion of the fallopian tube. *Am J Emerg Med* 1995;13:312-4.
3. Monaghan JM. Torsion of the isolated Fallopian tube. *Br J Surg* 1973;60:70-2.
4. Jain N, Manchanda R, Chithra S, Lekhi A. Adnexal torsion-symptoms, diagnosis and management: A review of literature. *Int J Reprod Contracept Obstet Gynecol* 2016;5:1276-84.
5. Bondioni MP, McHugh K, Grazioli L. Isolated fallopian tube torsion in an adolescent: CT features. *Pediatr Radiol* 2002;32:612-3.
6. Provost MW. Torsion of the normal fallopian tube. *Obstet Gynecol* 1972;39:80-2.
7. Ghossain MA, Buy JN, Bazot M, Haddad S, Guinet C, Malbec L, *et al.* CT in adnexal torsion with emphasis on tubal findings: Correlation with US. *J Comput Assist Tomogr* 1994;18:619-25.