

# Evaluation of clinical use of indigenously developed delta plate in management of subcondylar fracture

Anroop Anirudhan,<sup>1</sup> Sherin A. Khalam,<sup>2</sup> Rakesh Koshy Zachariah<sup>2</sup>

<sup>1</sup>Indira Gandhi Institute of Dental Science, Nellikuzhi, Kothamangalam;

<sup>2</sup>PMS College of Dental Science & Research, Golden Hills, Vattapara, Trivandrum, Kerala, India

## Abstract

Condylar fractures account for 25-35% of mandibular fractures and deserve a special consideration apart from rest of the mandible due to their anatomical differences and healing potential. Previous clinical and biomechanical studies have recommended using two miniplates for fixation of condyle fractures. Two miniplates require a certain size of the proximal condyle fragment and thus are applicable mainly in cases involving low fractures. The present study evaluates the clinical use of indigenously developed titanium delta-shaped miniplate in open reduction and internal fixation of subcondylar fracture.

## Introduction

*Conventional wisdom* has suggested closed reduction as the treatment of choice for mandibular fractures for decades. With the cutting edge research and methodologies the *conventional wisdom* stands outdated.

Condylar fractures account for 25-35% of mandibular fractures and deserve a special consideration apart from rest of the mandible due to their anatomical differences and healing potential.<sup>1</sup> But the sequela of the condylar injuries cannot be considered suboptimal with regard to occlusion, reduced mouth opening, deviation of the mandible, impaired mastication, ankylosis and internal derangement.<sup>2</sup>

Consequently the need for accurate surgical anatomical reduction to achieve the desired outcome proves prudent. Different approaches (*e.g.*, preauricular, submandibular, retroauricular, retromandibular, transoral, or combinations thereof), and different fixation techniques (*e.g.*, plates, screws, or lag screws) are used. Previous clinical and biomechanical studies have recommended using two miniplates for fixation of condyle fractures.<sup>3</sup> Two miniplates require a certain size of the proximal condyle fragment and thus are applicable

mainly in cases involving low fractures. It also includes use of excess armamentarium and an increased exposure of the condylar region. The present study evaluates the clinical use of indigenously developed titanium delta-shaped miniplate in open reduction and internal fixation of subcondylar fracture.

## Materials and Methods

The mandibular condyle is approached by Risdon's or Hinds' incision. The design of the new delta-shaped miniplate is such that it is triangular in shape. This shape provides three-dimensional stability in open reduction and internal fixation of subcondylar fractures. Tensile strains occur mainly at the anterior and lateral borders of the condyle and compressive strains, at the posterior and medial borders. Due to the permanent mediolateral bending of the condyle during function, a stronger plate is recommended. In the delta-shaped plate (Figure 1), the base is oriented toward the angle of the mandible; thus, the lines of tensile and compressive stress distribution run parallel to both sides of the plate. The plate is 1 mm thick, 20 mm long, and 5 mm wide at the top and 12 mm wide at the base. At the top of the plate is an arm with two longitudinally arranged holes; two more holes form the 2 corners of the base of the plate. A finite-element analysis study done by Haim *et al.*<sup>4</sup> to evaluate the plate design shows the distribution of tensile strains in the plate, particularly at the anterior border, when masticatory forces are applied.

## Surgical procedure

General anesthesia is administered through naso-tracheal intubation. A preoperative orthopantomogram (OPG) is taken to assess the level of fracture (Figure 2). After preparing a sterile surgical field, the zygomatic arch, articular fossa and mandibular ramus till the angle are identified and marked on the skin. Then, the fracture end is outlined. A standard retromandibular, Risdon's, or Hinds' incision is placed (Figure 3). The skin is incised; the subcutaneous tissues are dissected superficial to the superficial muscular aponeurotic system in an anterosuperior direction using blunt and sharp dissection until masseter muscle fibres appear. Facial nerve fibres are not always visible, but should be preserved carefully and protected with a retractor when they are detected. The deeper muscle fibres lying underneath the facial nerve can be transected safely if necessary. When the bone surface is reached, the periosteum is elevated and the fracture is identified (Figure 4) and reduced (Figure 5) To facilitate fracture reduction, the distal stump is mobilised caudally by applying intraoral pressure to the last mandibular molars with

Correspondence: Anroop Anirudhan, Indira Gandhi Institute of Dental Science, Nellikuzhi, Kothamangalam, Kerala 68669, India.  
Tel: 00919846608528.  
E-mail: anroop.a@gmail.com

Key words: delta plate, subcondylar fracture.

Received for publication: 16 March 2013.

Revision received: 5 August 2013.

Accepted for publication: 12 August 2013.

This work is licensed under a Creative Commons Attribution NonCommercial 3.0 License (CC BY-NC 3.0).

©Copyright A. Anirudhan *et al.*, 2013

Licensee PAGEPress, Italy

Clinics and Practice 2013; 3:e28

doi:10.4081/cp.2013.e28

a finger. Once the fracture is reduced rigid plate osteosynthesis are performed using delta plate (Figure 6). Double layered closure is done and hemostasis is achieved (Figure 6). A postoperative OPG is taken to confirm the position of the condyle and stability of fixation (Figure 7).

## Discussion

The method of fixing the condylar fracture is either by open reduction or by closed reduction, which has always evoked controversies.<sup>5</sup> Although many systems of rigid fixation have been described, that with miniplates is the preferred technique today. Miniplate osteosynthesis provides rigid fixation that may be easily adapted to the curvature of the bone, and requires only a simple operation. Choi and Yoo compared the biomechanical stability of four different plating techniques (4-screw monocortical miniplate, 4-screw bicortical miniplate, 4-screw 2.4 mm plate, and a double monocortical miniplate) in mandibles from formalin fixed cadavers, and found the double miniplate to be the most.<sup>6</sup> Obviously, a 2-plate technique is better if there is adequate bony substance on either side of the fracture, but fixation with two miniplates might be a more traumatic procedure than fixation with a single miniplate. Two miniplates (double-plate technique) are the most reliable because these neutralize tension and pressure forces best and produce greater stability.<sup>7</sup> To gain more stability these two plates should be placed with a sufficient distance between the screws and the fracture line. This disadvantage was overcome by the decision of Meyer *et al.* to select a different design of trapezoidal shaped plate, having taken into account the

anatomical circumstances. The use of single resorbable plates are discouraged in mechanically heavy loaded areas in condyle where it has been found that the osteosynthesis is unstable and weak.<sup>8</sup>

The 3-dimensional osteosynthesis plates were introduced into maxillofacial surgery in the early 1990s. Advantages are the smaller size combined with greater stiffness of the plates. As alternative to the modified 2-mini-plate technique, specially designed plates such as the delta plate or the trapezoid plate are available, and biomechanical and clinical studies have confirmed that these plates allow for sufficient neutralization of strains. Therefore, these plates provide sufficient stabilization for open reduction and internal fixation of subcondylar and condylar neck fractures combined with the advantage of a smaller plate.<sup>4</sup>

In the delta-shaped plate, the base is oriented toward the angle of the mandible; thus, the lines of tensile and compressive stress distribution run parallel to both sides of the plate. The plate is 1 mm thick, 20 mm long, and 5 mm wide at the top and 12 mm wide at the base. At the top of the plate is an arm with 2 longitudinally arranged holes; two more holes form the 2 corners of the base of the plate.<sup>9</sup>

Using the new delta-shaped plate for condylar neck fractures has 3 main advantages: i) neutralization of changing strains at the anterior, lateral, and posterior borders; ii) the additional stabilization provided by a compression miniplate; and iii) a small osteosynthesis plate.<sup>9</sup> *Delta plating system* can transmit the demanded loads in all directions of movement. This plate allows a functionally stable osteosynthesis in the condylar neck region of the mandible and that this type of osteosynthesis can resist physiologic strains in the injured temporomandibular joint as described by Lauer *et al.*<sup>9</sup> In nine cases, two risdons incision and seven retromandibular incision was given to expose the condyle, fracture site identified and fixed using delta plate. All the clinical subjects studied showed excellent stability and reduction in the condylar region. Recovery to function was immediate and postoperative intermaxillary fixation period was minimal. In one subject the condyle was displaced medially and was out of the glenoid fossa. Extracorporeal approach plating was done and the condylar head was fixed to the rest of the ramus. This patient showed signs of plate infection after 2 weeks and thereafter the infected plate was removed.

Plate fracture or bending and screw loosening are considered signs of either inadequate fracture stabilization or incorrect fracture reduction. In all the subjects studied we did not encounter any of these problems.<sup>10</sup>

Postoperative edema and hemorrhage are usually encountered in the condylar region due to presence of internal maxillary artery and

superficial temporal artery, in all our patients the postoperative edema and swelling was considerably less. Only one patient in whom extracorporeal approach of plating was done had an extended period of edema. He was managed with postoperative steroids.

The role of antibiotics and steroids are significant. All the patients were given higher antibiotics. Steroids were avoided in almost all cases except one in which extracorporeal approach was needed. There was no incidence of postoperative wound infection in any of the cases.

Out of nine cases five patients were put in postoperative intermaxillary fixation for a period of one to two weeks. Restoration of



Figure 1. Delta plate.

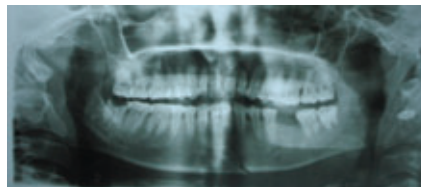


Figure 2. Preoperative orthopantomogram.

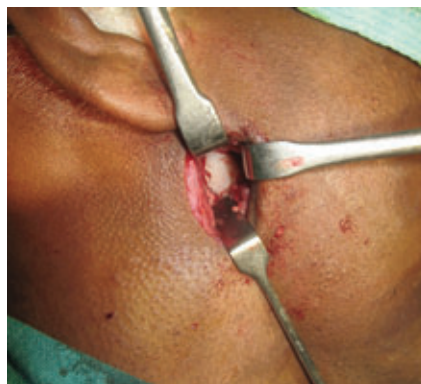

Figure 3. Hinds incision.

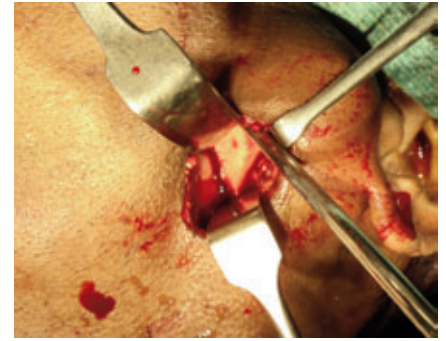

Figure 4. Fracture site.

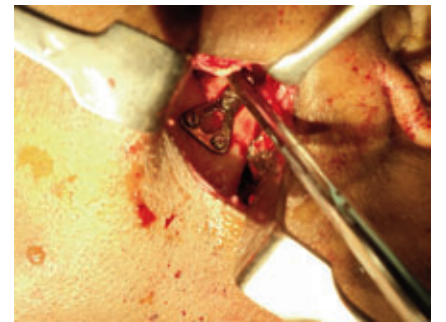

Figure 5. Fracture reduction.

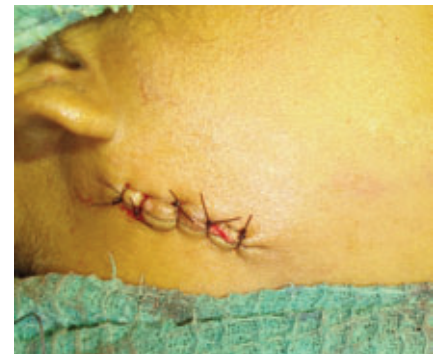

Figure 6. Closure.

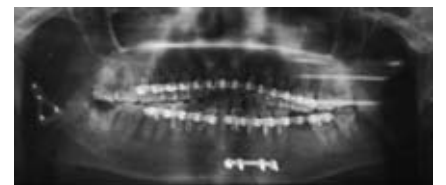


Figure 7. Postoperative orthopantomogram.

function and immediate functional loading was possible within one week of surgery.<sup>11</sup> Branches of the facial nerve, retromandibular vein and substance of the parotid may be encountered intraoperatively but at the same time it can be retracted safely avoiding any damage to the vital structures. We did not encounter any transient facial nerve palsy in any of our cases.

Postoperative follow up was done in all nine cases for a period of six months to one year. Radiographic evaluation showed that the osteosynthesis is relatively stable. All the patients treated with *delta plating* system were functionally stable and well rehabilitated. Only one patient had incidence of plate infection and the infected plate was subsequently removed. In our opinion fracture reduction of condyle is best treated with the new three-dimensional delta plating system, which gives excellent stability and neutralises the changing strains in the condylar region.

## Conclusions

The conclusions of our study can be summarized as follow:

- Though various literatures conclude that closed reduction and immobilization is the treatment of choice for condylar fractures, adaptation of open reduction and internal fixation always gives improved results.<sup>6</sup>
- The retromandibular approach was considered the standard and preferred approach to the neck of the condyle.<sup>3</sup>
- Open reduction and rigid internal fixation with three-dimensional stability is absolutely necessary for any subcondylar fractures for early functional rehabilitation.<sup>12</sup>
- Three-dimensional plates are considered to give more stability than conventional mini plates.
- The geometric pattern of three-dimensional plate, which readily adapts to the anatomy of the fracture, gives better stability and function.
- The *delta plate* that was used in our study

was a non-compression plate made up of titanium. The size and shape of the plate favours the operating surgeon for easy adaptation and fixation of subcondylar fractures.

- The modified *delta plate* with compression holes, trilock system adds more advantages to the present system used.
- This *delta plate* can also be used through an intraoral approach, which was endoscopically assisted procedure.
- The complications associated with this plating system are very minimal and as it is for any other surgical procedures for the condyle.<sup>10</sup>
- The early rehabilitation and functional loading was possible after a week of immobilization. On a long term follow up the condylar fracture managed with *delta plate* had a comfortable function and aesthetics.

The surgical ease, comfortable adaptation and adequate stability were achieved by these plates. The functional and aesthetic outcome with this procedure has proved beyond doubt that this plating system is one of the emerging trends in managing subcondylar fractures. No special armamentarium was required as only the shape of the plate differs and the screw and screw holes are the same as the routine mini plating system. A simple mouth opening exercise and range of movements with no active physiotherapy rehabilitated all our patients at the earliest. In this review, the majority of study was conducted on a small sample sizes. Studies with larger sample sizes would be beneficial in future studies.

## References

1. Banks P. A pragmatic approach to the management of condylar fractures. *Int J Oral Maxillofac Surg* 1998; 27:244-6.
2. Jensen T, Jensen J, Nørholt SE, et al. Open reduction and rigid internal fixation of mandibular condylar fractures by an intraoral approach: a long-term follow-up study of 15 patients. *J Oral Maxillofac Surg* 2006;

64:1771-9.

3. Chossegras C, Cheynet F, Blanc J-L, et al. Clinical and radiological long term evaluation. Short retromandibular approach of subcondylar fractures. *Oral Surg Oral Med Oral Pathol* 1996;82:3.
4. Haim D, Muller A, Leonhardt H, et al. Biomechanical study of the Delta Plate and the Trilock delta condyle trauma plate. *J Oral Maxillofac Surg* 2011;10:2619- 25.
5. Assael LA. Open versus closed reduction of adult condyle fractures: an alternative interpretation of evidence. *J Oral Maxillofac Surg* 2003;61:1333-9.
6. Choi BH, Yi CK, Yoo JH, et al. Clinical evaluation of 3 types of plate osteosynthesis for fixation of condylar neck fractures. *J Oral Maxillofac Surg* 2001;59:734.
7. De Riu G, Gamba U, Anghioni M, et al. A comparison of open and closed treatment of condylar fractures: a change in Philosophy. *Int J Oral Maxillofac Surg* 2001;30:384-9.
8. Pilling E, Eckelt U, Loukota R, et al. Comparative evaluation of ten different condylar base fracture osteosynthesis techniques. *Br J Oral Maxillofac Surg* 2010;48:527-31.
9. Lauer G, Pradel W, Schneider M. A new 3-dimensional plate for transoral endoscopic-assisted osteosynthesis of condylar neck fractures. *J Oral Maxillofac Surg* 2007;65:964-71.
10. Ellis III E. Complications of mandibular condyle fractures. *Int J Oral Maxillofac Surg* 1998;27:255-7.
11. Throckmorton GK. Recovery of mandibular motion after closed and open reduction of unilateral condylar process fractures. *Int J Oral Maxillofac Surg* 2000;29:421-7.
12. Santler G, Karcher H, Ruda C, et al. Fractures of the condylar process: surgical versus nonsurgical treatment. *J Oral Maxillofac Surg* 1999;57:392-7.