

Non-small cell lung cancer with multiple brain metastases remains relapse-free for more than 13 years: A case report

TATSU MATSUZAKI¹, SHINNOSUKE IKEMURA¹, TARO SHINOZAKI¹, ERI IWAMI¹,
TAKAHIRO NAKAJIMA¹, MASATERU KATAYAMA², YOSHINORI SHIMAMOTO²,
AYA SASAKI³, TORU SERIZAWA⁴ and TAKESHI TERASHIMA¹

Departments of ¹Respiratory Medicine, ²Neurosurgery and ³Pathology and Laboratory Medicine,
Tokyo Dental College Ichikawa General Hospital, Ichikawa, Chiba 272-8513;
⁴Tokyo Gamma Unit Center, Tsukiji Neurological Clinic, Tokyo 104-0045, Japan

Received November 15, 2019; Accepted September 13, 2021

DOI: 10.3892/mco.2021.2448

Abstract. Brain metastasis (BM) in patients with non-small cell lung cancer (NSCLC) is usually associated with a poor prognosis. A 55-year-old Japanese man visited Tokyo Dental College Ichikawa General Hospital with complaints of motor aphasia and fatigue. Enhanced magnetic resonance imaging of the brain revealed multiple tumors. The patient's medical history included lung cancer surgery performed at another hospital 3 months prior to his visit to our hospital. Total resection of the left frontal tumor revealed BM from lung adenocarcinoma. Stereotactic radiosurgery (SRS) was performed for the remaining three BMs. At 9 months after SRS, another new BM was discovered, and SRS was again performed. More than 13 years have elapsed since the last SRS was performed, and the patient has remained relapse-free. To the best of our knowledge, this is the first case report describing a patient with NSCLC with multiple BMs who has remained relapse-free for >13 years with no neurological dysfunction, including cognitive deficit.

Introduction

The brain is a common metastatic site for non-small cell lung cancer (NSCLC). In patients surgically treated for early-stage (stage I/II) NSCLC, the 5-year risk of developing brain metastasis (BM) is 10% (1). In advanced-stage NSCLC (stage IIIB/IV), BM occurs in 36% of the patients throughout the course of their disease (2). BM in patients with NSCLC is usually associated with a poor prognosis, with a median survival time (MST) of 7 months (3).

Although whole brain radiation therapy (WBRT) has historically been performed as a standard therapy for multiple BMs (4), cognitive dysfunction may develop as a side effect of WBRT (5). At present, not only WBRT, but also stereotactic radiosurgery (SRS), surgical resection, drug therapy, and combinations of these modalities, have been performed according to the clinical background of each patient (5-11).

We herein present a rare case of a patient with multiple BMs from NSCLC who was treated using a combination of resection and SRS and has remained relapse-free for >13 years without cognitive dysfunction.

Case report

In October 2005, a 55-year-old Japanese man visited the Department of Neurosurgery of Tokyo Dental College Ichikawa General Hospital (Ichikawa, Japan) with complaints of motor aphasia and fatigue. Enhanced brain MRI examination revealed multiple brain tumors (Fig. 1A). A 3-cm tumor was identified in the left frontal lobe, with an enhancement effect in the periphery, accompanied by edema of the surrounding tissue. A nodule 4 mm in diameter was observed in the right parietal lobe. The Eastern Cooperative Oncology Group performance status (ECOG PS) score was 1, and the Karnofsky performance score (KPS) was 70. The patient had a history of lung cancer, hypertension and smoking (35 pack-years), and was working as a civil service employee.

According to information obtained from the previous doctor, the patient had undergone lung surgery 3 months before visiting our hospital (July 2005). The primary lung tumor was 4 cm in diameter and was located in segment 2 of the right

Correspondence to: Dr Tatsu Matsuzaki, Department of Respiratory Medicine, Tokyo Dental College Ichikawa General Hospital, 5-11-13 Sugano, Ichikawa, Chiba 272-8513, Japan
E-mail: 75matsuzaki@gmail.com

Abbreviations: BM, brain metastasis; CEA, carcinoembryonic antigen; CK, cytokeratin; DS-GPA, diagnosis-specific graded prognostic assessment; ECOG, Eastern Cooperative Oncology Group; KPS, Karnofsky performance score; MMSE, mini-mental status examination; MST, median survival time; NSCLC, non-small cell lung cancer; OS, overall survival; PS, performance status; RCT, randomized controlled trial; SRS, stereotactic radiosurgery; TTF-1, thyroid transcription factor-1; WBRT, whole brain radiation therapy

Key words: NSCLC, adenocarcinoma, multiple brain metastases, SRS, WBRT

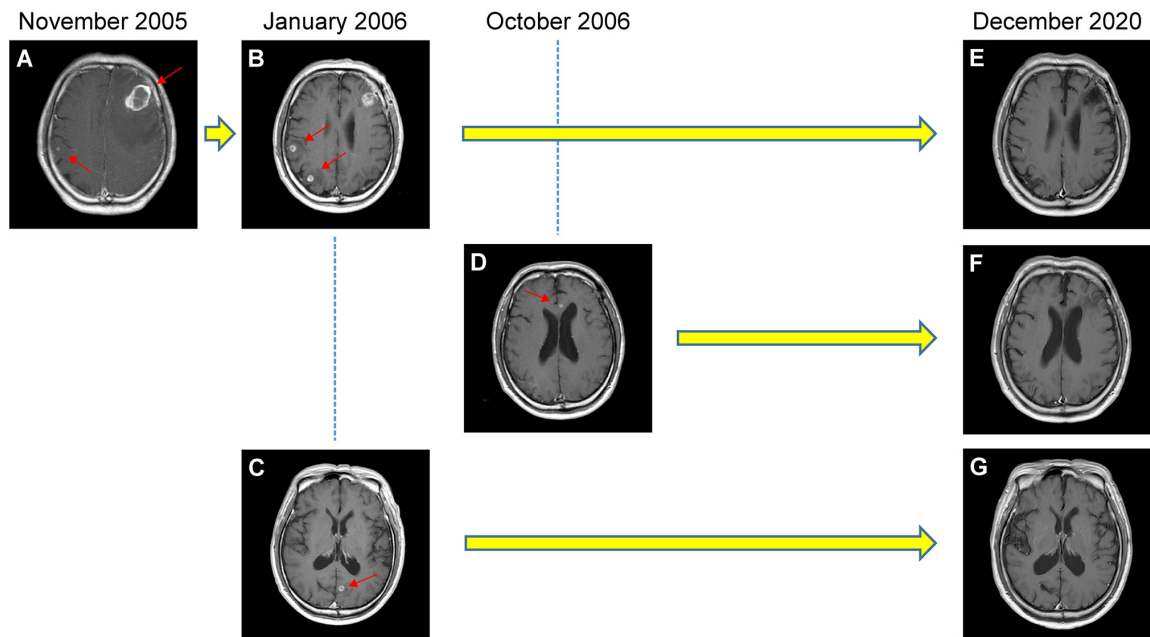


Figure 1. Findings on enhanced brain MRI scans. (A) Brain MRI performed in November 2005 revealed a 3-cm tumor in the left frontal lobe and a small nodule in the right parietal lobe. A second brain MRI performed in January 2006 revealed nodules in the (B) right parietal and (C) left occipital lobes. (D) In October 2006, a nodule in the left frontal lobe was identified on brain MRI. (E-G) Comparative MRI examination performed in December 2020 indicated no signs of recurrence in any of the lobes. Red arrows indicate the brain lesions.

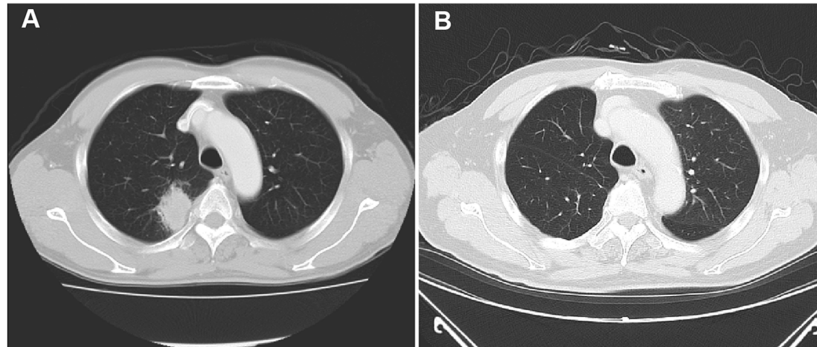


Figure 2. Chest CT examination. (A) A chest CT performed in July 2005 revealed a 4-cm tumor in the upper lobe of the right lung. (B) A chest CT performed in December 2020 revealed no signs of tumor recurrence.

upper lobe (Fig. 2A); the carcinoembryonic antigen (CEA) level was 12.8 ng/ml (reference range, 0-5 ng/ml). A right upper lobectomy with lymph node dissection was performed, and the tumor was diagnosed as lung adenocarcinoma and pathologically classified as T2N2Mx according to the 6th edition of the TNM classification (12). The patient declined adjuvant chemotherapy.

It was considered likely that these brain tumors were metastases from the NSCLC. Brain MRI, which is usually performed, had not been performed prior to lung surgery; thus, it was unknown whether any BMs existed prior to surgery.

To reduce the risk of cognitive dysfunction as a side effect of WBRT, surgical resection of the 3-cm brain tumor in the left frontal lobe was performed, while the remaining small nodule was treated with SRS.

In December 2005, the left frontal lobe tumor was completely removed at our hospital. On histological examination, the brain tumor was an adenocarcinoma exhibiting papillary, acinar

and solid growth patterns (Fig. 3A-D), while the primary lung tumor had been diagnosed as an adenocarcinoma exhibiting acinar and solid growth patterns based on information obtained from the previous doctor, and no neoplastic lesions were found in organs other than the lungs. Hence, the brain tumors were diagnosed as metastatic lesions from lung cancer. Furthermore, immunohistochemistry (IHC) performed later revealed that the tumor cells were positive for cytokeratin (CK)7, thyroid transcription factor-1 (TTF-1) and napsin A, whereas CK20 was negative (Fig. 3E-H), which were findings characteristic of metastasis from lung adenocarcinoma. The brain tumor did not harbor any mutations in the *EGFR* gene.

In January 2006, the 4-mm nodule in the right parietal lobe increased to a diameter of 8.5 mm, and a second new 8.5-mm nodule was observed in the same lobe (Fig. 1B). An 8-mm nodule was also observed in the left occipital lobe (Fig. 1C). SRS using Leksell Gamma Knife was performed for the three BMs at a peripheral dose of 20 Gy (50%).

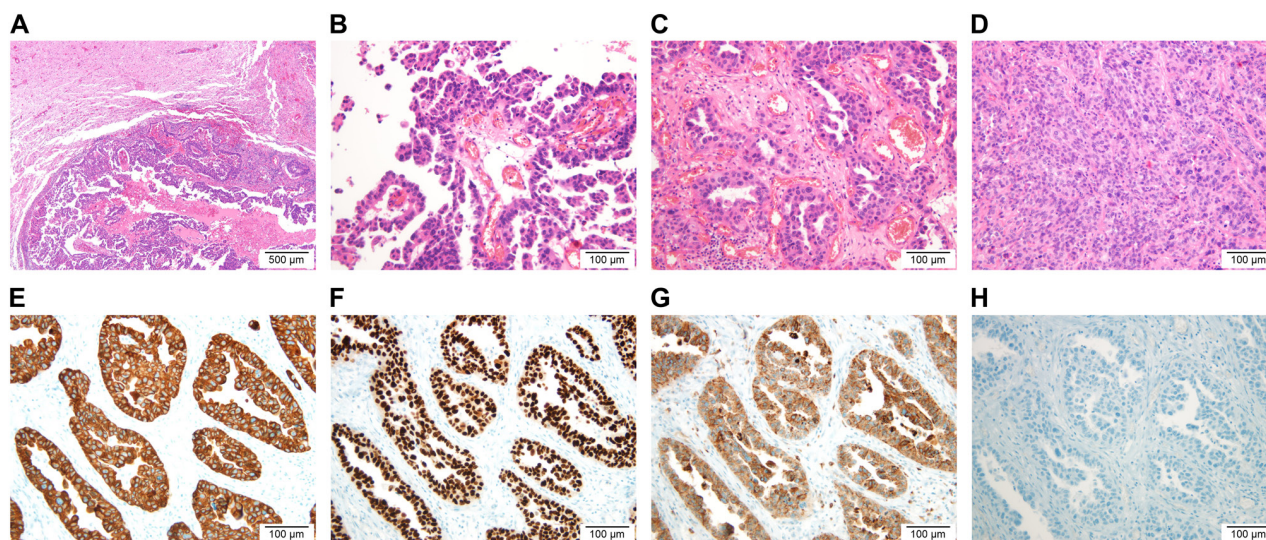


Figure 3. Pathological characteristics of the brain tumor. (A) Hematoxylin-eosin staining of the left frontal lobe tumor revealed an adenocarcinoma exhibiting (B) papillary, (C) acinar and (D) solid growth patterns. Immunohistochemistry revealed that the tumor was positive for (E) CK7, (F) thyroid transcription factor-1 and (G) napsin A and (H) negative for CK20. Scale bars, (A) 500 μm ; (B-H) 100 μm . CK, cytokeratin.

At 9 months after SRS, enhanced brain MRI revealed a new 3.5-mm nodule in the left frontal lobe (Fig. 1D), and SRS was performed again in January 2007. The patient did not wish to receive the subsequent systemic chemotherapy.

In December 2020, enhanced brain MRI (Fig. 1E-G), enhanced chest and abdominal CT (Fig. 2B) and bone scintigraphy (data not shown) did not show any recurrence. The patient's CEA level in March 2021 was within the normal range (4.2 ng/ml). His ECOG PS score was 0, his KPS was 100 and his mini-mental status examination (MMSE) score was 30. The patient was considered to be clinically cured, as he had remained relapse-free for >13 years since the last SRS treatment.

Discussion

Lutterbach *et al* (13) retrospectively analyzed patients with NSCLC who had single or multiple BMs and reported a survival rate of 2.6% at 3 years and <1% at 5 years. There have been few reports of long-term survival (>10 years) in patients with NSCLC who had multiple BMs. Kotecha *et al* (14) reviewed the records of 1,953 patients who underwent treatment for BMs; among those, only two with multiple BMs from NSCLC survived for ≥ 10 years: One survived for 10.1 years and died due to systemic disease; however, there was no information regarding neurological symptoms after treatment. The other patient survived for 15.3 years, and the cause of death was unknown. The KPS after treatment was 50, and the patient required the assistance of a wheelchair. In the present case, the patient suffered from NSCLC with multiple BMs and has remained relapse-free for >13 years, with no neurological dysfunction, including cognitive deficit.

The questions that remain in the rare clinically cured cases, such as the present case, are whether the brain lesion was actually a tumor and whether it was a BM from lung cancer. In patients with NSCLC who exhibit metastases on enhanced brain MRI, if there are no concerns regarding the diagnosis, it is common to proceed to treatment of the brain tumors without

a definitive histological diagnosis (15,16). In the present case, since surgery was performed, the brain lesion was histologically confirmed as an adenocarcinoma, and IHC staining for CK7, TTF-1, napsin A and CK20 strongly suggested that the primary origin was lung adenocarcinoma (17-20).

It was herein considered that the following reasons may have contributed to the long-term lack of relapse in the present case: i) High diagnosis-specific graded prognostic assessment (DS-GPA) score; ii) controlled primary lung lesion; and iii) combination of resection and SRS for multiple BMs. In particular, our decision to combine resection and SRS to avoid WBRT may be the reason why there was no cognitive dysfunction.

The DS-GPA score is a prognostic factor for the analysis of patients with BMs. For patients with lung cancer, the DS-GPA score is determined by scoring four factors: KPS, age, presence of extracranial metastases and number of BMs. According to Sperduto *et al* (3), in NSCLC, the MST in the poor prognosis group with low DS-GPA scores (0-1.0) was 3.02 months. The score in our case was 2.5, and the MST in patients with scores of 2.5-3.0 is hypothesized to be relatively better at 9.43 months.

Some studies have investigated prognostic factors in patients with NSCLC who have a small number of BMs. Kim *et al* (21) retrospectively reviewed patients with NSCLC treated with SRS for 1-4 BMs and determined the following five factors as significant predictors of OS: i) Status of systemic disease, ii) presence of neurogenic deficits, iii) size of the brain tumor(s), iv) initial imaging appearance of intratumoral necrosis and v) initial resection of the primary lung lesion. Won *et al* (22) performed a retrospective study of patients undergoing SRS for 1-5 BMs from NSCLC. Primary disease control and ECOG PS were found to significantly affect survival. The common prognostic factor between the two studies was that the primary lung lesion was controlled. In our case, the primary lung cancer was excised and controlled.

Andrew *et al* (6) performed a randomized controlled trial (RCT) comparing WBRT alone to WBRT plus SRS for 1-3 BMs. Although there was no difference in MST, WBRT plus SRS achieved longer survival compared with WBRT alone among patients with a single BM. Brown *et al* (5) conducted an RCT comparing SRS alone to SRS plus WBRT among patients with 1-3 BMs. Although there was no difference in OS, there was less cognitive deterioration at 3 months after SRS alone compared with that after SRS plus WBRT. A similar pattern was also observed at 12 months in long-term survivors. Yamamoto *et al* (7) performed a prospective observational study in patients with BMs (largest tumor <10 cm³ in volume and <3 cm in longest diameter; total cumulative volume ≤15 cm³). SRS without WBRT in patients with 5-10 BMs was non-inferior to that in patients with 2-4 BMs in terms of OS. Shuto *et al* (23) analyzed a subset of patients with BMs from NSCLC in their study. The 60-month post-SRS rates of neuro-cognitive preservation were at least 85.7%, with no difference between the two groups. Thus, if the number and size of BMs are limited, SRS may be a better treatment option compared with WBRT for patients with BMs, resulting in comparable OS and less prominent cognitive dysfunction.

In our case, total resection of the 3-cm tumor was performed, and SRS was selected for the remaining small nodules. Kayama *et al* (11) conducted an RCT comparing WBRT to salvage SRS in patients with 1-4 BMs and only one surgically resected lesion ≥3 cm in diameter. Salvage SRS was not inferior to WBRT in terms of OS after resection of the BM. Although the proportion of patients with MMSE scores that did not worsen at 12 months was similar between the two treatments, the incidence of grade 2-4 cognitive dysfunction at 91 days after WBRT was significantly higher compared with that after SRS. It was therefore concluded that salvage SRS can be established as a standard therapy for patients with 1-4 BMs.

To the best of our knowledge, this is the first case report in the literature to describe a patient with multiple BMs from NSCLC who has remained relapse-free for >13 years with no neurological dysfunction, including cognitive deficit. Even in patients with NSCLC and multiple BMs, long-term survival is probable if the DS-GPA score is high and the lung lesion is controlled. To reduce the risk of cognitive dysfunction in such cases, we recommend local treatment without WBRT as the most viable option, such as combining resection and SRS, if possible. Moreover, to better understand the clinical and biological background of patients with multiple BMs from NSCLC who achieve long-term survival, it is necessary to accumulate data from cases similar to the one presented herein.

Acknowledgements

Not applicable.

Funding

No funding was received.

Availability of data and materials

The datasets used and/or analyzed during the current study are available from the corresponding author on reasonable request.

Authors' contributions

TM designed the study and drafted the initial manuscript. YS performed surgery for the brain metastasis in our patient. TSE performed stereotactic radiosurgery for the brain metastases in our patient. AS evaluated the pathological specimens. TM, SI, TSh, EI, TN, MK and TT were involved in the patient's medical care. SI, TSh, EI, TN, MK and TT reviewed and edited the manuscript. SI and TT confirm the authenticity of the data. All authors have read and approved the final manuscript.

Ethics approval and consent to participate

The Ethics Committee of Tokyo Dental College Ichikawa General Hospital approved this case report. The patient has provided informed written consent.

Patient consent for publication

Written informed consent was obtained from the patient for publication of the case details and any accompanying images.

Competing interests

The authors declare that they have no competing interests.

References

- Hubbs JL, Boyd JA, Hollis D, Chino JP, Saynak M and Kelsey CR: Factors associated with the development of brain metastases: analysis of 975 patients with early stage nonsmall cell lung cancer. *Cancer* 116: 5038-5046, 2010.
- Hsiao SH, Chung CL, Chou YT, Lee HL, Lin SE and Liu HE: Identification of subgroup patients with stage IIIB/IV non-small cell lung cancer at higher risk for brain metastases. *Lung Cancer* 82: 319-323, 2013.
- Sperduto PW, Kased N, Roberge D, Xu Z, Shanley R, Luo X, Sneed PK, Chao ST, Weil RJ, Suh J, *et al*: Summary report on the graded prognostic assessment: An accurate and facile diagnosis-specific tool to estimate survival for patients with brain metastases. *J Clin Oncol* 30: 419-425, 2012.
- Coia LR, Aaronson N, Linggood R, Loeffler J and Priestman TJ: A report of the consensus workshop panel on the treatment of brain metastases. *Int J Radiat Oncol Biol Phys* 23: 223-227, 1992.
- Brown PD, Jaeckle K, Ballman KV, Farace E, Cerhan JH, Anderson SK, Carrero XW, Barker FG II, Deming R, Burri SH, *et al*: Effect of radiosurgery alone vs radiosurgery with whole brain radiation therapy on cognitive function in patients with 1 to 3 brain metastases: A randomized clinical trial. *JAMA* 316: 401-409, 2016.
- Andrew DW, Scott CB, Sperduto PW, Flanders AE, Gaspar LE, Schell MC, Werner-Wasik M, Demas W, Ryu J, Bahary JP, *et al*: Whole brain radiation therapy with or without stereotactic radiosurgery boost for patients with one to three brain metastases: Phase III results of the RTOG 9508 randomised trial. *Lancet* 363: 1665-1672, 2004.
- Yamamoto M, Serizawa T, Shuto T, Akabane A, Higuchi Y, Kawagishi J, Yamanaka K, Sato Y, Jokura H, Yomo S, *et al*: Stereotactic radiosurgery for patients with multiple brain metastases (JLGK0901): A multi-institutional prospective observational study. *Lancet Oncol* 15: 387-395, 2014.
- Bindal RK, Sawaya R, Leavens ME and Lee JJ: Surgical treatment of multiple brain metastases. *J Neurosurg* 79: 210-216, 1993.
- Iuchi T, Shingyoji M, Sakaida T, Hatano K, Nagano O, Itakura M, Kageyama H, Yokoi S, Hasegawa Y, Kawasaki K and Iizasa T: Phase II trial of gefitinib alone without radiation therapy for Japanese patients with metastases from EGFR-mutant lung adenocarcinoma. *Lung Cancer* 82: 282-287, 2013.

10. Reungwetwattana T, Nakagawa K, Cho BC, Cobo M, Cho EK, Bertolini A, Bohnet S, Zhou C, Lee KH, Nogami N, *et al*: CNS response to osimertinib versus standard epidermal growth factor receptor tyrosine kinase inhibitors in patients with untreated EGFR-mutated advanced non-small-cell lung cancer. *J Clin Oncol*: Aug 28, 2018 (Epub ahead of print).
11. Kayama T, Sato S, Sakurada K, Mizusawa J, Nishikawa R, Narita Y, Sumi M, Miyakita Y, Kumabe T, Sonoda Y, *et al*: Effects of surgery with salvage stereotactic radiosurgery versus surgery with whole-brain radiation therapy in patients with one to four brain metastases (JCOG0504): A phase III, noninferiority randomized controlled trial. *J Clin Oncol*: Jun 20, 2018 (Epub ahead of print).
12. Soblin LH and Wittekind C (eds): *TNM Classification of Malignant Tumours (UICC)*. 6th edition. Wiley-Liss, New York, NY, 2002.
13. Lutterbach J, Bartelt S and Ostertag C: Long-term survival in patients with brain metastases. *J Cancer Res Clin Oncol* 128: 417-425, 2002.
14. Kotecha R, Vogel S, Suh JH, Barnett GH, Murphy ES, Reddy CA, Parsons M, Vogelbaum MA, Angelov L, Mohammadi AM, *et al*: A cure is possible: A study of 10-year survivors of brain metastases. *J Neurooncol* 129: 545-555, 2016.
15. National Comprehensive Cancer Network: *NCCN Clinical Practice Guidelines in Oncology for Non-Small Cell Lung Cancer Version 6.2021*. http://www.nccn.org/professionals/physician_gls/pdf/nscl.pdf. Accessed October 19, 2021.
16. Nabors LB, Portnow J, Ahluwalia M, Baehring J, Brem H, Brem S, Butowski N, Campian JL, Clark SW, Fabiano AJ, *et al*: Central nervous system cancers, version 3.2020, NCCN clinical practice guidelines in oncology. *J Natl Compr Canc Netw* 18: 1537-1570, 2020.
17. Travis WD, Brambilla E, Noguchi M, Nicholson AG, Geisinger KR, Yatabe Y, Beer DG, Powell CA, Riely GJ, Van Schil PE, *et al*: International association for the study of lung cancer/American thoracic society/European respiratory society international multidisciplinary classification of lung adenocarcinoma. *J Thorac Oncol* 6: 244-285, 2011.
18. Varadhachary GR, Abbruzzese JL and Lenzi R: Diagnostic strategies for unknown primary cancer. *Cancer* 100: 1776-1785, 2004.
19. Bishop JA, Sharma R and Illei PB: Napsin A and thyroid transcription factor-1 expression in carcinomas of the lung, breast, pancreas, colon, kidney, thyroid, and malignant mesothelioma. *Hum Pathol* 41: 20-25, 2010.
20. Bekaert L, Emery E, Levallet G and Lechapt-Zalcman E: Histopathologic diagnosis of brain metastases: Current trends in management and future considerations. *Brain Tumor Pathol* 34: 8-19, 2017.
21. Kim YS, Kondziolka D, Flickinger JC and Lunsford LD: Stereotactic radiosurgery for patients with nonsmall cell lung carcinoma metastatic to the brain. *Cancer* 80: 2075-2083, 1997.
22. Won YK, Lee JY, Kang YN, Jang JS, Kang JH, Jung SL, Sung SY, Jo IY, Park HH, Lee DS, *et al*: Stereotactic radiosurgery for brain metastasis in non-small cell lung cancer. *Radiat Oncol J* 33: 207-216, 2015.
23. Shuto T, Akabane A, Yamamoto M, Serizawa T, Higuchi Y, Sato Y, Kawagishi J, Yamanaka K, Jokura H, Yomo S, *et al*: Multiinstitutional prospective observational study of stereotactic radiosurgery for patients with multiple brain metastases from lung cancer (JL GK0901 study-NSCLC). *J Neurosurg* 129 (Suppl 1): S86-S94, 2018.



This work is licensed under a Creative Commons Attribution-NonCommercial-NoDerivatives 4.0 International (CC BY-NC-ND 4.0) License.