

En-bloc Resection of a Giant Cell Tumor Causing Cervical Vertebral Collapse

Abstract

Giant cell tumors (GCTs) are rare, benign, and locally aggressive primary bone neoplasms. Spine is seldom affected, especially above the level of sacrum. In this report, we describe a case with GCT of the cervical vertebrae which causes collapse of the corpus. A 32-year-old female presented with gradual neck pain and abrupt paresthesia of the left hand. Computed tomography scan showed C6 vertebral collapse and magnetic resonance imaging demonstrated vertebral plana of C6 by a low signal intensity lesion on T1- and T2-weighted images. Emergent surgical intervention was taken due to the possibility of spinal injury. The tumor was removed by en-bloc resection and histopathological investigation confirmed GCT. In most of the cases, en-bloc resection of GCTs of the spine is not feasible. Despite the location and close contact of the lesion with spinal cord, later approach was successful for our case; thus, appropriate differential diagnosis for vertebral column lesions as well as selecting an optimum treatment is mandatory.

Keywords: Cervical spine, en-bloc resection, giant cell tumor

Introduction

Giant cell tumor (GCT) of the bone was first described by Cooper and Travers in 1818.^[1] These lesions are uncommon and are characterized by the presence of multinucleated giant cells.^[2] In a review of literature done by Shankman *et al.* in 1988, 2.7% of GCTs were located in the spine.^[3] Most of these benign neoplasms occur at sacrum followed by thoracic and cervical spine in a descending manner.^[4] GCT has tendency for various behaviors; it can range from local bone destruction to local and distant metastasis or malignant transformation.^[5] Vertebral GCTs may extend into the spinal canal and compress the spinal cord, resulting in neurological deficits.^[6] The anatomical features of spinal GCT still present challenges to surgeons.^[7] The ideal treatment modality for spinal GCTs is complete, extralesional surgical resection.^[8] In en-bloc resection, tumor is surgically removed in a single, intact piece with a continuous shell of healthy tissue, termed “margin.”^[9] Since the tumor is extremely close to neurovascular structures and has usually broken through the cortex by the time it is diagnosed, en-bloc resection is challenging.^[10]

We report a case of GCT invading cervical vertebrae of a female patient which causes vertebral collapse and spinal injury, who treated by en-bloc resection of the tumor and C6 corpectomy along with C5-C6 and C6-C7 discectomy and cervical spine stabilization.

Case Report

The patient was a 32-year-old female presenting with gradual neck pain followed by sudden paresthesia of the left hand. Her medical history was unremarkable. Physical examination revealed hyperreflexia of both proximal and distal limbs and positive Hoffman’s sign of the left hand. Computed tomography (CT) scan of cervical spine showed collapse of the C6 body with posterior subluxation of C5 vertebrae. Bony retropulsion along with canal stenosis is also obvious at C6 level [Figure 1]. Also a magnetic resonance imaging (MRI) was performed for further evaluation. MRI showed vertebral plana of C6 with compressive effect on cord, but myelopathy was not detected. Lesion appears as low signal intensity mass on both T1- and T2-weighted MRI [Figure 2]. Based on the clinical scenario and imaging findings, decision was made to perform C6 corpectomy with C5-C6

**Seddighi Afsoun,
Seddighi Amir
Saied,
Nikouei Amir,
Javadian Hamed**

Shohada Tajrish Neurosurgical Center of Excellence, Functional Neurosurgery Research Center of Shohada Tajrish Hospital, Shahid Beheshti University of Medical Sciences, Tehran, Iran

Address for correspondence:
Prof. Seddighi Amir Saied,
Shohada Tajrish Neurosurgical Center of Excellence, Functional Neurosurgery Research Center of Shohada Tajrish Hospital, Shahid Beheshti University of Medical Sciences, Tehran, Iran.
E-mail: a_seddighi@sbmu.ac.ir

Access this article online

Website: www.asianjns.org

DOI: 10.4103/1793-5482.181136

Quick Response Code:



How to cite this article: Afsoun S, Saied SA, Amir N, Hamed J. En-bloc resection of a giant cell tumor causing cervical vertebral collapse. *Asian J Neurosurg* 2018;13:150-3.

This is an open access article distributed under the terms of the Creative Commons Attribution-NonCommercial-ShareAlike 3.0 License, which allows others to remix, tweak, and build upon the work non-commercially, as long as the author is credited and the new creations are licensed under the identical terms.

For reprints contact: reprints@medknow.com

and C6-C7 discectomy [Figure 3]. Excised lesion which had brown color at first look to the surgeon was sent for histopathological examination. Histopathology of the lesion revealed multiple irregular pieces of tan brown elastic to hard tissue in macroscopic view. Degenerated fibrocartilaginous tissue and a giant cell-rich lesion composed of large multinucleated cells admixed with regular and uniform stromal cells with foci of new bone formation with multiple areas of necrosis and hemorrhage were noted as microscopic features [Figure 4]. Based on clinical, imaging, and histopathological study, diagnosis of GCT was established.

Written informed consent was obtained from the patient with ethical approval of the Ethics Committee of Shohada Tajrish Hospital.

Discussion

The multinucleated giant cells appear similar to osteoclasts, which led to the older term “osteoclastoma”.^[11] GCT of bone is a benign lesion that is usually solitary and locally aggressive.^[12] GCT is commonly seen in the 20–45 years age group.^[13] Pain in the area of the tumor is the most common symptom for the patients; however swelling and limited range of motion in the affected joint is noticed.^[14] As in our case, the incidence of pathologic

fracture at presentation is <15%.^[15] GCTs often show heterogeneous signal intensity on the MRI. Since GCTs have relative collagen content of fibrous components and hemosiderin within the tumor, this lesion generally shows low to intermediate signal intensity on the T1-weighted MR images. GCTs have low to similar signal intensity to the normal spinal cord on the T2-weighted MR images in more than 75% of cases.^[16] Since GCT does not have specific imaging features, lesions such as aneurysmal bone cyst, chondroblastoma, brown tumor in the setting of hyperparathyroidism and metastasis should be kept in mind. Although appearance of GCTs of the spine is not unique, it is useful in making a differential diagnosis because most other spinal neoplasms (metastases, myeloma, lymphoma, and chordoma) show high signal intensity on the long-TR MR images.^[17] However, low signal intensity on both T1- and T2-weighted MRI was noted for our presented case. Whole spine MRI (T1 and T2 weighted) showed no other synchronous lesion, since there is approximately 1% chance of multiple GCTs, especially in case of Paget’s disease.^[18]

Tumor is seen as soft or firm and friable brown mass with areas of hemorrhage which appear dark red and areas of collagen which appear gray. Microscopically, the nuclei are generally hypochromatic with inconspicuous nucleoli and mitotic figures are uncommon. Foci of hemorrhage

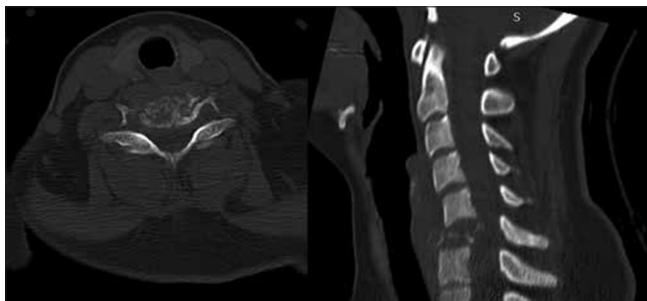


Figure 1: Computed tomography scan of cervical spine shows collapse of the C6 body with posterior subluxation of C5 vertebrae

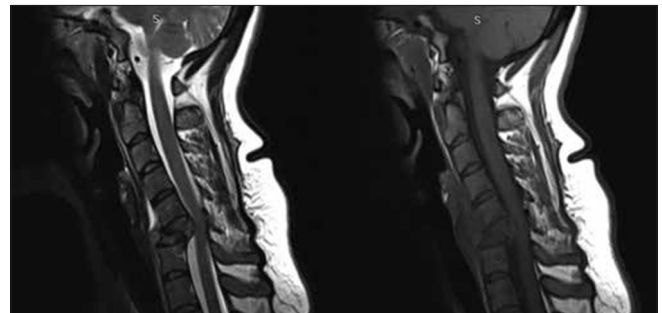


Figure 2: Magnetic resonance imaging shows vertebral plana of C6 with compressive effect on cord, but myelopathy was not detected

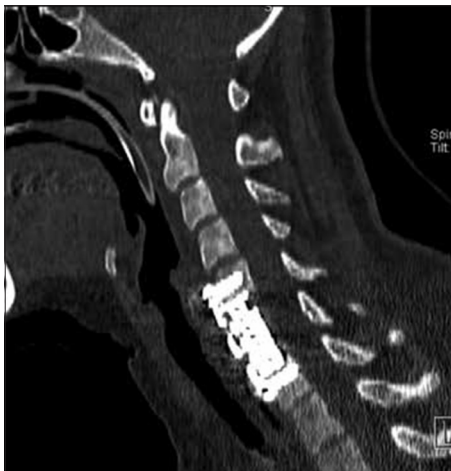

Figure 3: Computed tomography shows C6 corpectomy with C5-C6 and C6-C7 discectomy

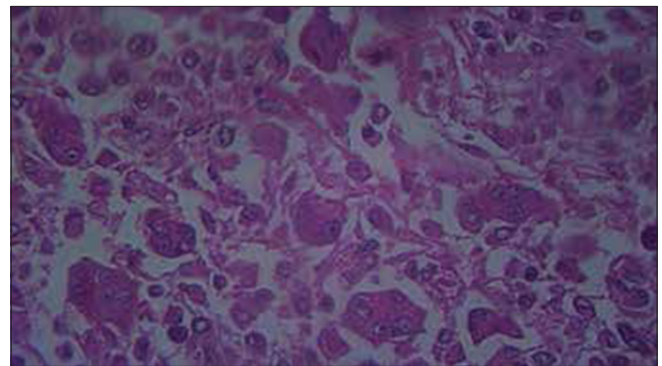


Figure 4: Degenerated fibrocartilaginous tissue and a giant cell-rich lesion composed of large multinucleated cells admixed with regular and uniform stromal cells with foci of new bone formation with multiple areas of necrosis and hemorrhage were noted as microscopic features

and activated stromal cells along with large thin-walled, markedly dilated vessels and evidence of hemorrhage and few giant cells are seen.^[19] However, these findings are not pathognomonic of GCT and there is a relatively wide differential diagnosis such as giant cell repetitive granuloma, brown tumor and nonossifying fibroma,^[20] thus every aspect of the clinical scenario should be considered for definite diagnosis.

There are different treatment modalities for spinal GCTs such as surgery, radiotherapy, embolization, and chemical adjuvants.^[21] In the spine, one vertebra could be regarded a single oncologic compartment and surrounding tissues as barriers to tumor spread.^[22] Thus, Boriani *et al.* have described total en-bloc resection for reducing local recurrence of a vertebral tumor, with excellent clinical results.^[23] Other study showed 95% recurrence free until death or last follow-up by the mentioned technique.^[24] Although total en-bloc surgical excision is generally agreed to be the best treatment option,^[25] but it is not always possible due to potential technical obstacles such as excessive bleeding, injury of the major vessels during blunt dissection of the vertebral body, spinal cord injury, possible contamination by tumor cells especially intralesional cutting at the pedicle and complete spinal instability resulting from spinal osteotomy.^[26]

Despite vertebral plana of C6 with compression on cervical cord, en-bloc resection of the tumor was successful for our presented case. The efficacy of radiotherapy in spinal GCTs remains controversial due to recurrence and malignant transformation;^[27] thus, en-bloc resection of the tumor without radiotherapy was done for our case. Although rare, lung metastasis has been reported in 3% of patient with GCT.^[28] Low-dose spiral CT scan of the patient's lungs showed no lesion.

Since local recurrence of GCT can usually manifest 3–5 years after initial surgery,^[29] close follow-up is required. The significance of GCT in cervical vertebrae which causes collapse of the corpus is that it may cause direct damage to the spinal cord and devastating consequence such as paraplegia occurs. Therefore, diagnosis and differentiation of GCTs from other lesions and emergent treating may prevent unwanted sequela.

Financial support and sponsorship

Nil.

Conflicts of interest

There are no conflicts of interest.

References

- Cooper AS, Travers B. Surgical Essays. London, England: Cox Longman and Co.; 1818. p. 178-9.
- Wülling M, Engels C, Jesse N, Werner M, Delling G, Kaiser E. The nature of giant cell tumor of bone. *J Cancer Res Clin Oncol* 2001;127:467-74.
- Shankman S, Greenspan A, Klein MJ, Lewis MM. Giant cell tumor of the ischium. A report of two cases and review of the literature. *Skeletal Radiol* 1988;17:46-51.
- Bidwell JK, Young JW, Khalluff E. Giant cell tumor of the spine: Computed tomography appearance and review of the literature. *J Comput Tomogr* 1987;11:307-11.
- Present DA, Bertoni F, Springfield D, Braylan R, Enneking WF. Giant cell tumor of bone with pulmonary and lymph node metastases. A case report. *Clin Orthop Relat Res* 1986;209:286-91.
- Sanjay BK, Sim FH, Unni KK, McLeod RA, Klassen RA. Giant-cell tumours of the spine. *J Bone Joint Surg Br* 1993;75:148-54.
- Yang SC, Chen LH, Fu TS, Lai PL, Niu CC, Chen WJ. Surgical treatment for giant cell tumor of the thoracolumbar spine. *Chang Gung Med J* 2006;29:71-8.
- Boriani S, Weinstein JN, Biagini R. Primary bone tumors of the spine. Terminology and surgical staging. *Spine (Phila Pa 1976)* 1997;22:1036-44.
- Enneking WF. *Musculoskeletal Tumor Surgery*. New York: Churchill Livingstone; 1983. p. 69-122.
- Fisher CG, Keynan O, Boyd MC, Dvorak MF. The surgical management of primary tumors of the spine: Initial results of an ongoing prospective cohort study. *Spine (Phila Pa 1976)* 2005;30:1899-908.
- Balke M, Schremper L, Gebert C, Ahrens H, Streitbuenger A, Koehler G, *et al.* Giant cell tumor of bone: Treatment and outcome of 214 cases. *J Cancer Res Clin Oncol* 2008;134:969-78.
- Pai SB, Lalitha RM, Prasad K, Rao SG, Harish K. Giant cell tumor of the temporal bone – A case report. *BMC Ear Nose Throat Disord* 2005;5:8.
- Kafchitsas K, Habermann B, Proschek D, Kurth A, Eberhardt C. Functional results after giant cell tumor operation near knee joint and the cement radiolucent zone as indicator of recurrence. *Anticancer Res* 2010;30:3795-9.
- Enneking W. *Musculoskeletal Tumor Surgery*. New York: Churchill Livingstone; 1983. p. 87-8.
- Hudson TM, Schiebler M, Springfield DS, Enneking WF, Hawkins IF Jr, Spanier SS. Radiology of giant cell tumors of bone: Computed tomography, arthro-tomography, and scintigraphy. *Skeletal Radiol* 1984;11:85-95.
- Resnick D. *Diagnosis of Bone and Joint Disorders*. 3rd ed. Philadelphia, PA: Saunders; 1995. p. 3785-806.
- Kwon JW, Chung HW, Cho EY, Hong SH, Choi SH, Yoon YC, *et al.* MRI findings of giant cell tumors of the spine. *AJR Am J Roentgenol* 2007;189:246-50.
- Pathak HJ, Nardi PM, Thornhill B. Multiple giant cell tumors complicating Paget's disease. *AJR Am J Roentgenol* 1999;172:1696-7.
- Haque AU, Moatasim A. Giant cell tumor of bone: A neoplasm or a reactive condition? *Int J Clin Exp Pathol* 2008;1:489-501.
- Murphey MD, Nomikos GC, Flemming DJ, Gannon FH, Temple HT, Kransdorf MJ. From the archives of AFIP. Imaging of giant cell tumor and giant cell reparative granuloma of bone: Radiologic-pathologic correlation. *Radiographics* 2001;21:1283-309.
- Gortzak Y, Kandel R, Deheshi B, Werier J, Turcotte RE, Ferguson PC, *et al.* The efficacy of chemical adjuvants on giant-cell tumour of bone. An *in vitro* study. *J Bone Joint Surg Br* 2010;92:1475-9.
- Tomita K, Kawahara N, Murakami H, Demura S. Total en bloc spondylectomy for spinal tumors: Improvement of the technique and its associated basic background. *J Orthop Sci* 2006;11:3-12.

23. Boriani S, Biagini R, De Iure F, Di Fiore M, Gamberini G, Zanoni A. Lumbar vertebrectomy for the treatment of bone tumors: Surgical technique. *Chir Organi Mov* 1994;79:163-73.
24. Abdel-Wanis Mel-S, Tsuchiya H, Kawahara N, Tomita K. Tumor growth potential after tumoral and instrumental contamination: An *in-vivo* comparative study of T-saw, Gigli saw, and scalpel. *J Orthop Sci* 2001;6:424-9.
25. Su YP, Chen WM, Chen TH. Giant-cell tumors of bone: An analysis of 87 cases. *Int Orthop* 2004;28:239-43.
26. Toribatake Y. The effect of total en bloc spondylectomy on spinal cord circulation. *J Jpn Orthop Assoc* 1993;67:1070-80.
27. Caudell JJ, Ballo MT, Zagars GK, Lewis VO, Weber KL, Lin PP, *et al.* Radiotherapy in the management of giant cell tumor of bone. *Int J Radiat Oncol Biol Phys* 2003;57:158-65.
28. Connell D, Munk PL, Lee MJ, O'Connell JX, Janzen D, Vu M, *et al.* Giant cell tumor of bone with selective metastases to mediastinal lymph nodes. *Skeletal Radiol* 1998;27:341-5.
29. Hart RA, Boriani S, Biagini R, Currier B, Weinstein JN. A system for surgical staging and management of spine tumors. A clinical outcome study of giant cell tumors of the spine. *Spine (Phila Pa 1976)* 1997;22:1773-82.