



Contents lists available at ScienceDirect

International Journal of Surgery Case Reports

journal homepage: www.casereports.com

Hypoglycemia with a large retroperitoneal mass – Case report



Jennifer A. Hawasli*, Jacob R. Hopping, Eddy C. Hsueh

Department of Surgery, Saint Louis University School of Medicine, St. Louis, MO, United States

ARTICLE INFO

Article history:

Received 27 July 2014

Received in revised form 5 November 2014

Accepted 5 November 2014

Available online 11 November 2014

Keywords:

Hypoglycemia

Retroperitoneal mass

Insulin-like growth factor

ABSTRACT

INTRODUCTION: Retroperitoneal sarcomas have rarely been reported to secrete insulin-growth factor II (IGF-II) and produce an enigmatic hypoglycemia. IGF-II-secreting sarcomas represent an extremely rare subset of soft tissue tumors, and reports are limited to a handful of cases.

PRESENTATION OF CASE: The authors present the case of hypoglycemia due to an IGF-II-secreting retroperitoneal sarcoma that was successfully treated by complete surgical resection. This report describes the diagnosis and management of this rare syndrome with 1-year follow-up and a review of the literature.

DISCUSSION: Steroid and growth hormone therapies also have efficacy to treat this hypoglycemia in some patients. However, outcomes appear better if combined with surgical resection.

CONCLUSIONS: The findings of this case report and review of the literature support a primary role for complete tumor resection to address tumor-induced hypoglycemia.

© 2014 Published by Elsevier Ltd. on behalf of Surgical Associates Ltd. This is an open access article under the CC BY-NC-ND license (<http://creativecommons.org/licenses/by-nc-nd/3.0/>).

1. Introduction

Hypoglycemia is a rare but potentially life-threatening presentation of soft tissue tumors the etiology of hypoglycemia may be difficult to diagnose. Retroperitoneal sarcomas have rarely been reported to secrete insulin-growth factor II (IGF-II) which can lead to low blood glucose levels. IGF-II-secreting sarcomas represent an extremely rare subset of soft tissue tumors, and there is no consensus on the ideal management of the hypoglycemia associated with this tumor-type. Here we present a case report of hypoglycemia with a large retroperitoneal mass and review of the literature.

2. Presentation of the case

A 38-year-old diabetic man presented with increasing episodes of hypoglycemia over the previous 8 months. As a consequent, his insulin had been discontinued 5 months prior, despite a long history of insulin-dependent diabetes. He also complained of increasing abdominal girth over the previous several months and 15 pound weight loss. A varicocele was discovered by ultrasound after complaints of worsening right testicular pain. Biochemical work-up revealed blood glucose level was very low at 32 mg/dL.

Total and free insulin levels were <1.2 and <1.5 μ IU/mL (normal: 0–22 μ IU/mL), respectively. Elevated Insulin-Like Growth Factor (IGF)-II level was 944 ng/mL (normal: 288–736 ng/mL). IGF-1 levels were reduced and C-peptide levels were undetectable (normal: 1.1–4.4 nL/mL). Computer tomography (CT) of abdomen demonstrated a large right retroperitoneal tumor involving the right kidney and displacing the IVC and liver (Fig. 1A).

The patient was admitted preoperatively for intravenous dextrose while unable to eat prior to surgery. He underwent an *en block* tumor resection via a chevron incision secondary to the size of the mass. After the celiotomy, a large mass arising from the retroperitoneum was encountered occupying the majority of the right hemi-abdomen (Fig. 1B). During tumor extirpation, a plane could not be developed between the mass and right kidney. Therefore, a right nephrectomy was included in the *en block* resection. The tumor weighed 3.25 kg and measured 19.5 cm \times 17.2 cm \times 13.5 cm (Fig. 1B, inset). Pathological examination using stains, immunohistochemistry, electron microscopy and molecular and cytogenetic studies showed a primitive, undifferentiated mesenchymal tumor (sarcoma).

After surgery, the patient was taken to the intensive care unit for blood sugar monitoring. The expected half-lives of free IGF-II and carrier protein-bound IGF-II in a healthy male are 10–12 min and 12–15 h, respectively.¹ However, immediately postoperatively, the patient's glucose levels elevated to the 200s mg/dL. He was started on an insulin drip with intravenous dextrose and then was transitioned to subcutaneous insulin with resumption of a diet. He was discharged home on postoperative day 6 with a serum glucose range 90–237 mg/dL. Within one month, the patient's IGF-II level returned to normal (317 ng/mL) with a serum glucose of 170 mg/dL.

Abbreviations: F, female; GH, recombinant human growth hormone; M, male; MO, months; NR, not reported; RP, Retroperitoneum; YR, years.

* Corresponding author at: Department of Surgery, Saint Louis University School of Medicine, 3rd Floor Desloge Tower, 3635 Vista at Grand Boulevard, St. Louis, MO 63110, United States. Tel.: +1 314 790 2758.

E-mail address: JPick@SLU.edu (J.A. Hawasli).

<http://dx.doi.org/10.1016/j.ijscr.2014.11.013>

2210-2612/© 2014 Published by Elsevier Ltd. on behalf of Surgical Associates Ltd. This is an open access article under the CC BY-NC-ND license (<http://creativecommons.org/licenses/by-nc-nd/3.0/>).

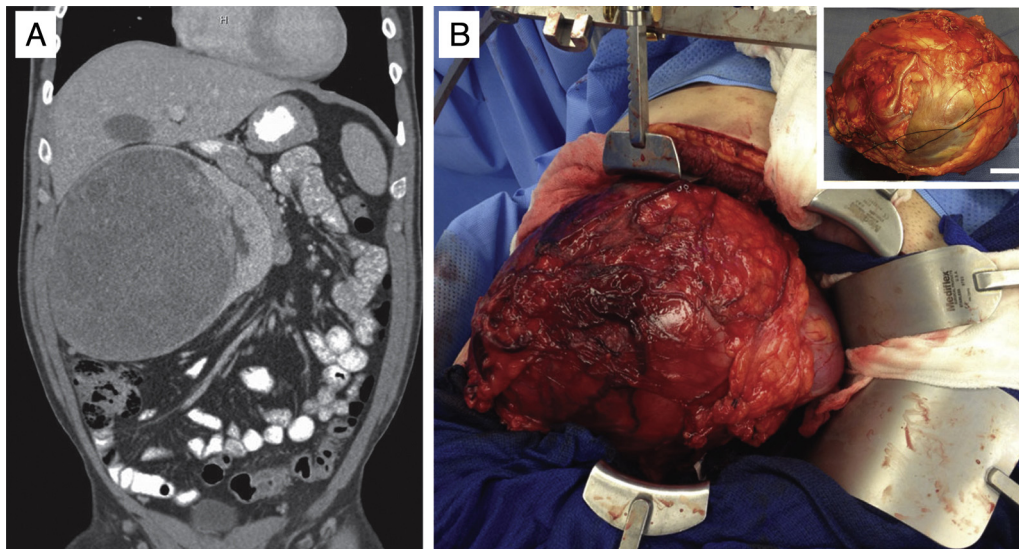


Fig. 1. Evaluation and resection of IGF-II-secreting retroperitoneal tumor. (A) Coronal computed tomography shows a retroperitoneal tumor involving the right kidney and displacing the inferior vena cava and liver. (B) A very large mass occupied the right hemiabdomen. Inset shows the gross pathology specimen, resected *en block*. Bar indicates 3 cm.

Table 1
Hypoglycemia associated with IGF-II secreting tumors – literature review.

Reference	Age, sex	Symptoms	Tumor pathology, location	Treatment	Hypoglycemia outcome	Oncologic outcome
Rose et al. ⁴	54, F	Fatigue Early satiety Weight loss	Mesenchymal solid fibrous tumor, Abdominal cavity	1. Intratumoral alcohol injections 2. Surgical debulking	Persistent hypoglycemia and death in 24 h	Not applicable
Teale and Wark ³ (8 cases: A–H)	34–81	Drowsiness Coma Otherwise NR	A. Carcinoma, lung B. Fibroma, thoracic C. Spindle-cell, NR D. Sarcoma, RP E. Sarcoma, NR F. Carcinoma, prostate G. Sarcoma, NR H. Fibroma, pleura	A. Steroids only B. Steroids only C. Debulking/Steroids D. Resection/chemo/steroids E. Steroids only F. Steroids/resection G. Resection H. Resection	A. Resolved, 5 MO B. Resolved, 8 MO C. Resolved, 9 MO D. Resolved, 6 MO E. Not resolved F. Resolved G. Resolved H. Resolved	A. NR B. Recur, 8 MO C. NR D. NR E. NR F. NR G. NR H. NR
Bourcigaux et al. ⁸	67, F	Acromegaly	Pleural fibroma, hemithorax	1. Chronic steroids 2. GH 3. Steroids and GH	Resolution of hypoglycemia with combined steroids and GH	NR
Chan et al. ⁷	70, M	Loss of consciousness	Fibrosarcoma, liver	1. Embolization 2. Complete resection	Resolved, 9 MO	Recurrence, 1 YR
De Groot et al. ⁶	83, M	Confusion	Solid fibrous tumor, kidney	Complete resection and nephrectomy <i>en block</i>	Resolution of hypoglycemia and normalization of glucose and IGF-II	NR
	48, F	Lethargy Coma	Metastatic hemangiopericytoma, liver	1. Chronic steroids 2. Chemotherapy	Free of hypoglycemic events through 1-YR follow up	Stable disease, 1 YR
Dutta et al. ⁵	77, M	Loss of consciousness	Sarcoma, retroperitoneum	1. Debulking 2. Chemotherapy 3. Radiotherapy 4. Chronic steroids	Free of hypoglycemic events through 6-YR follow up	Residual disease, 1 YR Asymptomatic, 6 YR Then lost to follow up

Table 1 (Continued)

Reference	Age, sex	Symptoms	Tumor pathology, location	Treatment	Hypoglycemia outcome	Oncologic outcome
	24, F	Hunger Sweating	Hemangiopericytoma, left upper abdomen	1. Chemotherapy 2. Complete resection with splenectomy, nephrectomy, partial pancreatectomy <i>en block</i>	Free of hypoglycemic events through 3-YR follow up	No recurrence, 3 YR
	32, F	Tremors Neuroglycopenia	Adrenocortical carcinoma, suprarenal	Complete resection with adrenalectomy <i>en block</i>	Free of hypoglycemic events through 1-YR follow up	No recurrence, 6 YR
	80, M	Cough	Pleural mesothelioma, internal chest wall	Chronic steroids (declined surgery and chemotherapy)	Immediate hypoglycemic episodes subsided but lost to follow-up	Lost to follow up
	48, M	Breathlessness Seizures Abdominal pain	Leiomyosarcoma, RP and abdomen	Complete resection	Free of hypoglycemic events through 6 MO	No recurrence, 6 MO
Hawasli et al. (2014)	38, M	Neuroglycopenia Testicular pain	Mesenchymal tumor, retroperitoneum	Complete resection with nephrectomy <i>en block</i>	Free of hypoglycemic events through 4 MO	No recurrence, 4 MO

F = female; GH = recombinant human growth hormone; M = male; MO = months; NR = not reported; RP = retroperitoneum; YR = years.

One-year post-operatively, he has returned to normal activities. He has had no further episodes of hypoglycemia, and his serum glucose level was elevated at 237 mg/dL, for which he is being evaluated for an insulin pump.

3. Discussion and literature review

Patients with non-islet cell tumors secreting IGF-II can have hypoglycemia because of increased glucose uptake into peripheral insulin target tissues and suppressed hepatic glucose production.² Therefore, tumor-induced hypoglycemia should be considered in a patient with low blood glucose, low C-peptide, low fasting insulin levels and weight loss.^{3–8}

Management of hypoglycemia in a patient with an IGF-II-secreting tumor remains under some deliberation. As shown in Table 1, Rose et al. reported on a 54 year old woman with an IGF-II secreting abdominal mesenchymal tumor leading to malignant hypoglycemia.⁴ Despite intratumoral alcohol injections and surgical debulking, this patient died 24 h after surgery due to persistent hypoglycemia. Teale et al. reported on 8 cases of hypoglycemia due to IGF-II-secreting tumors.³ They concluded that chronic steroid therapy may successfully treat hypoglycemia in some patients and complete surgical resection is recommended when possible. De Groot et al. reported on two adult patients with IGF-II-secreting tumors: one with a “solid fibrous tumor” of the kidney and another with a metastatic hemangiopericytoma.⁶ The first patient’s hypoglycemia immediately resolved after resection of the kidney mass. The second patient harbored several unresectable masses. With chronic corticosteroid therapy and chemotherapy, this patient remained free of hypoglycemic events for more than a year.⁶ Bourcigaux et al. reported resolution of hypoglycemia with combined chronic steroids and recombinant human growth hormone.⁸ Chan et al. reported resolution of hypoglycemia after steroids and complete resection.⁷ Dutta et al. reported 5 IGF-II-secreting tumors including a retroperitoneal sarcoma, hemangiopericytoma, adrenocortical carcinoma, pleural mesothelioma and a retroperitoneal leiomyosarcoma.⁵ Four patients underwent complete resections and all remained free from hypoglycemic events at follow up (6 months–6 years). One patient showed stable tumor disease while the other four showed no recurrence.

4. Conclusion

This case and review of the literature show that the most effective treatment for hypoglycemia due to an IGF-II-secreting sarcoma is complete surgical resection.^{4–6} If the tumor is not resectable and diet with glucose supplementation do not address the hypoglycemia, glucocorticoids and growth hormone may help in mildly symptomatic patients.^{4–6} Other treatments such as chemotherapy, radiotherapy, tumor embolization and alcohol injections into the tumor have been used but seem to have little effect on hypoglycemia induced by IGF-II secreting soft tissue masses.^{4–6} In summary, we report a case of a 38-year-old who presents with hypoglycemia due to an IGF-II-secreting retroperitoneal undifferentiated mesenchymal tumor that was successfully treated by surgical resection.

Disclosures

No relevant conflict of interests. This work was supported by the Department of Surgery, Saint Louis University School of Medicine. This case report is compliant with the CARE Guidelines (<http://www.care-statement.org/>).

Conflict of interest

The authors have no disclosures or conflicts of interest related to this manuscript.

Funding

This work was supported by the Department of Surgery, Saint Louis University School of Medicine.

Ethical approval

This is not a research study which requires ethical approval. So, there is no ethical approval.

Author contributions

Jennifer Hawasli drafted the manuscript, and was a resident involved in the surgical resection of the case. Eddy Hsueh was

the supervising attending physician of the presented patient. Both Eddy Hsueh and Jacob Hopping were involved in assisting with the review of the literature and editing the manuscript.

Consent

Written informed consent was obtained from the patient for publication of this case report and accompanying images. A copy of the written consent is available for review by the Editor-in-Chief of this journal on request.

Acknowledgements

The authors thank Drs. Ritoban Sen and Ammar Hawasli and the Departments of General Surgery and Surgical Oncology at Saint Louis University Hospital for their support of this project. We thank the patient for allowing us to present this case.

This case report is compliant with the CARE Guidelines (<http://www.care-statement.org/>).

References

1. Guler H-P, Zapf J, Schmid C, Froesch ER. Insulin-like growth factors I and II in healthy man. *Acta Endocrinol* 1989;**121**:753–8.
2. Livingstone C. IGF2 and cancer. *Endocr Relat Cancer* 2013;**20**:R321–R39.
3. Teale JD, Wark G. The effectiveness of different treatment options for non-islet cell tumour hypoglycaemia. *Clin Endocrinol* 2004;**60**:457–60.
4. Rose MGM, Tallini GMD, Pollak JMD, Murren JMD. Malignant hypoglycemia associated with a large mesenchymal tumor: case report and review of the literature. *Cancer J Sci Am* 1999;**5**:48–51.
5. Dutta P, Aggarwal A, Gogate Y, Nahar U, Shah VN, Singla M, et al. Non-islet cell tumor-induced hypoglycemia: a report of five cases and brief review of the literature. *Endocrinol Diabetes Metab Case Rep* 2013;**2013**:130046.
6. de Groot JW, Rikhof B, van Doorn J, Bilo HJ, Alleman MA, Honkoop AH, et al. Non-islet cell tumour-induced hypoglycaemia: a review of the literature including two new cases. *Endocr Relat Cancer* 2007;**14**:979–93.
7. Chan G, Horton PJ, Thyssen S, Lamarche M, Nahal A, Hill DJ, et al. Malignant transformation of a solitary fibrous tumor of the liver and intractable hypoglycemia. *J Hepatobiliary Pancreat Surg* 2007;**14**:595–9.
8. Bourcigaux N, Arnault-Ouayr G, Christol R, Perin L, Charbonnel B, Le Bouc Y. Treatment of hypoglycemia using combined glucocorticoid and recombinant human growth hormone in a patient with a metastatic non-islet cell tumor hypoglycemia. *Clin Ther* 2005;**27**:246–51.

Open Access

This article is published Open Access at sciendo.com. It is distributed under the [IJSCR Supplemental terms and conditions](#), which permits unrestricted non commercial use, distribution, and reproduction in any medium, provided the original authors and source are credited.