


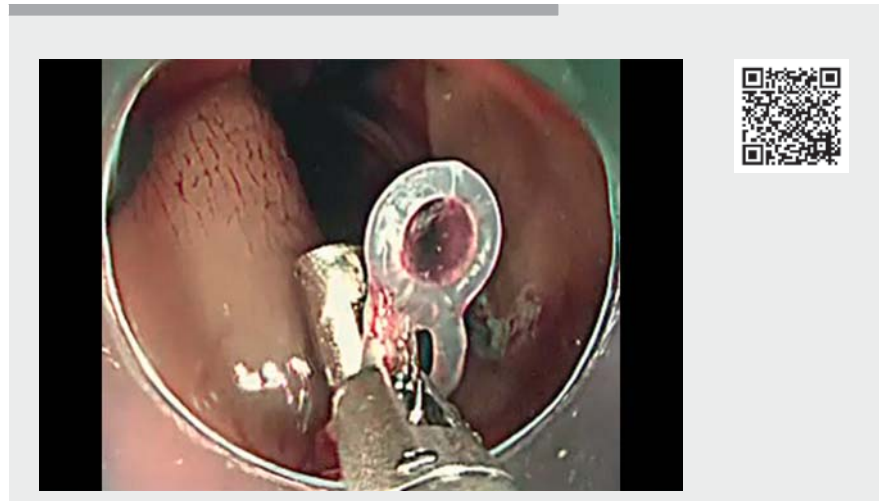
Complete closure of mucosal defect after colonic endoscopic submucosal dissection using clip with a silicone traction band

OPEN
ACCESS



► **Fig. 1** The clip with a silicone traction band (arrow).

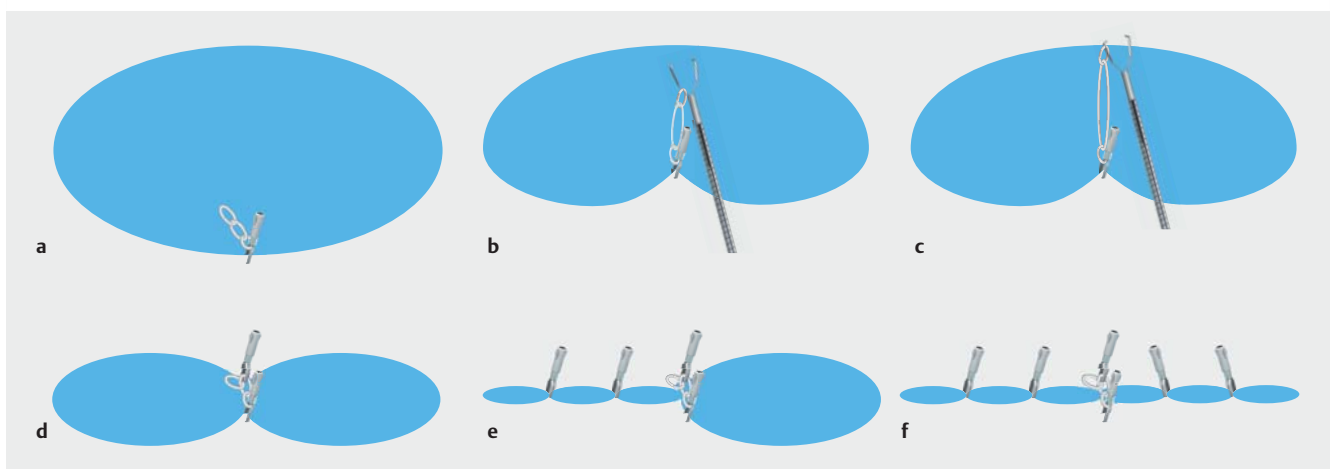
Endoscopic submucosal dissection (ESD) is a standard treatment for colorectal neoplasms, but the risk of severe post-operative complications persists even after successful ESD [1,2]. Therefore, complete closure of defects after ESD is essential to prevent such complications [3]. Although complete closure is a technically difficult procedure, several techniques have been developed to assist [4, 5]. Herein, we present a case of successful complete closure of a mucosal defect after colonic ESD using clips with a silicone traction band (► **Fig. 1**).



► **Video 1** Complete closure of a mucosal defect using clips with a silicone traction band after colonic endoscopic submucosal dissection.

ESD was performed to resect a 35-mm laterally spreading tumor located in the ascending colon; however, a 50-mm mucosal defect remained after lesion retrieval. Pulsating vessels and minor muscular injuries were observed in this

defect. Endoscopic closure using clips with a silicone traction band was performed on the lesion (► **Video 1**). The first clip with a band was placed at the proximal edge of the mucosal defect (► **Fig. 2a**). The second clip was placed at



► **Fig. 2** Schemata showing key steps of the endoscopic closure using clips with a silicone traction band. **a** The first clip with a silicone traction band was placed at the proximal margin of the mucosal defect after colonic endoscopic submucosal dissection. **b** The second clip hooked the silicone traction band attached to the base of the first clip. **c** The second clip was placed at the distal opposite margin of the mucosal defect. **d** Bridging the bilateral mucosal edges using clips with a silicone traction band changed the oval shape of the mucosal defect to a figure-of-eight shape. **e** Conventional clips were placed at the left side of the figure of eight. **f** Conventional clips were also placed on the right side of the figure of eight. Complete closure of the mucosal defect was then achieved.

the distal opposite edge, and it hooked the silicone traction band attached to the base of the first clip (► **Fig. 2 b, c**). Bridging the bilateral mucosal edges changed the shape from large oval to a figure of eight (► **Fig. 2 d**). Subsequently, complete closure of the mucosal defect was achieved by placing conventional clips on both sides (► **Fig. 2 e, f**). No complications occurred following the procedure.

The elastic energy of the silicone traction band attached to the base of the clip was sufficiently large to generate an appropriate traction force between the two clips. The advantage of this clip is that it is easily available and does not require preparation of any complicated device. Second, it is repositionable until the clips are placed at the right site. This method can be a good option for complete endoscopic closure of mucosal defects after colorectal ESD.

Endoscopy_UCTN_Code_TTT_1AQ_2AD

Competing interests

Eikichi Ihara participated in funded research for Takeda Pharmaceutical Co., Ltd. and belongs to the endowed course supported by the companies mentioned, including Ono Pharmaceutical Co., Ltd., Miyarisan Pharmaceutical Co. Ltd., Sanwa Kagaku Kenkyusho Co., Ltd., Otsuka Pharmaceutical Factory, Inc., Fujifilm Medical Co., Ltd., Terumo Corporation, FANCL Corporation, and Ohga Pharmacy. Eikichi Ihara also received a lecture fee from Takeda Pharmaceutical Co. The remaining authors declare that they have no conflict of interest.

The authors

Kosuke Maehara¹, Mitsuru Esaki^{1,2}, Yorinobu Sumida¹, Shin-ichiro Fukuda¹, Yosuke Minoda², Eikichi Ihara^{2,3}, Hirotada Akiho¹

Department of Gastroenterology, Kitakyushu Municipal Medical Center, Kitakyushu, Fukuoka, Japan

Department of Medicine and Bioregulatory Science, Graduate School of Medical Sciences, Kyushu University, Fukuoka, Fukuoka, Japan

Department of Gastroenterology and Metabolism, Graduate School of Medical Sciences, Kyushu University, Fukuoka, Fukuoka, Japan

Corresponding author

Mitsuru Esaki, MD

Department of Medicine and Bioregulatory Science, Graduate School of Medical Sciences, Kyushu University, 3-1-1, Maidashi, Higashi-ku, 812-8582, Fukuoka, Japan
esaki_saiseikai@yahoo.co.jp

References

- [1] Santos JB, Nobre MRC, Oliveira CZ et al. Risk factors for adverse events of colorectal endoscopic submucosal dissection: a systematic review and meta-analysis. *Eur J Gastroenterol Hepatol* 2021; 33: e33–e41
- [2] Arezzo A, Passera R, Marchese N et al. Systematic review and meta-analysis of endoscopic submucosal dissection vs endoscopic mucosal resection for colorectal lesions. *United European Gastroenterol J* 2016; 4: 18–29
- [3] Liu M, Zhang Y, Wang Y et al. Effect of prophylactic closure on adverse events after colorectal endoscopic submucosal dissection: a meta-analysis. *J Gastroenterol Hepatol* 2020; 35: 1869–1877
- [4] Ogiyama H, Tsutsui S, Murayama Y et al. Prophylactic clip closure may reduce the risk of delayed bleeding after colorectal endo-

scopic submucosal dissection. *Endosc Int Open* 2018; 6: E582–E588

- [5] Minoda Y, Ihara E, Ogino H et al. The efficacy and safety of a promising single-channel endoscopic closure technique for endoscopic treatment-related artificial ulcers: a pilot study. *Gastrointest Tumors* 2020; 7: 21–29

Bibliography

Endoscopy 2022; 54: E1005–E1006

DOI 10.1055/a-1889-4838

ISSN 0013-726X

published online 4.8.2022

© 2022. The Author(s).

This is an open access article published by Thieme under the terms of the Creative Commons Attribution-NonDerivative-NonCommercial License, permitting copying and reproduction so long as the original work is given appropriate credit. Contents may not be used for commercial purposes, or adapted, remixed, transformed or built upon. (<https://creativecommons.org/licenses/by-nc-nd/4.0/>)

Georg Thieme Verlag KG, Rüdigerstraße 14, 70469 Stuttgart, Germany



ENDOSCOPY E-VIDEOS

<https://eref.thieme.de/e-videos>



Endoscopy E-Videos is an open access online section, reporting on interesting cases and new techniques in gastroenterological endoscopy. All papers include a high quality video and all contributions are freely accessible online. Processing charges apply (currently EUR 375), discounts and waivers acc. to HINARI are available.

This section has its own submission website at <https://mc.manuscriptcentral.com/e-videos>