

CASE REPORT



A rare case of late onset saphenous vein graft spasm

Nirmal Guragai^a, Upamanyu Rampal^b, Rahul Vasudev^c, Hiten Patel^b, Meherwan B Joshi^a and Fayez Shamoon^b

^aDepartment of Internal Medicine, Trinitas Regional Medical Center, Seton Hall University, Elizabeth, NJ, USA; ^bDepartment of Cardiology, New York Medical College at St Joseph's Regional Medical Center, Paterson, NJ, USA; ^cDepartment of Internal Medicine, New York Medical College at St Joseph's Regional Medical Center, Paterson, NJ, USA

ABSTRACT

Spasm following coronary artery bypass graft surgery has been well established in arterial grafts, especially in grafts utilizing the internal mammary. Venous graft spasms are uncommon and are only observed in vein grafts during or soon after the coronary artery bypass surgery. It is exceedingly rare to see spasm of venous graft beyond one year of surgery. We report a 72-year-old female who had coronary artery bypass graft three years ago and presented with new onset chest pain for one month. The coronary angiogram revealed severe spasm of the proximal aspect of a patent saphenous venous graft which was relieved by intracoronary nitroglycerine. Patient was successfully managed using combination of anti-spasmodic medications (nitrates and calcium channel blockers) leading to long-term resolution of her anginal symptoms.

ARTICLE HISTORY

Received 10 June 2017
Accepted 7 September 2017

KEYWORDS

Saphenous vein graft spasm; arterial graft spasm; percutaneous coronary angiogram; angina symptoms; coronary artery bypass grafting

1. Introduction

Coronary artery bypass grafting (CABG) surgery remains the standard treatment for patients with multi-vessel coronary artery disease (CAD) and significant lesion affecting proximal left anterior descending (LAD) artery. Autologous arteries rather than vein bypass grafts are preferred due to overall better long term benefits. However aortocoronary bypass using saphenous vein grafts have also been extremely successful in relieving angina pectoris in most patients who undergo this procedure. Spasm of arterial grafts in coronary artery bypass grafting surgery has well been described in literature. However spasm involving venous grafts is a very rare phenomena. The usual causes of angina following CABG surgery in cases of venous grafts include occlusion of graft, incomplete vascularization, progression of the disease in grafted vessels, atherosclerotic narrowing of saphenous vein graft, technical problems in either proximal or distal anastomotic site, and kinking of the vein graft. In this report we present an unusual cause of recurrent angina many years after the initial CABG surgery resulting from spontaneous severe spasm of a venous graft.

2. Case report

A 72-year-old female presented with exertional chest pain for one month. Chest pain was retrosternal and occasionally radiated to left arm. Patient had history of

significant coronary artery disease with a critical lesion of the left main coronary artery ostium, posterior descending artery (PDA), first diagonal artery, and therefore underwent coronary artery bypass surgery three years ago prior to current presentation. She had left internal mammary artery (LIMA) graft from left subclavian to distal left anterior descending (LAD) artery, which bypassed the proximal LAD lesion. She also had two aortocoronary saphenous vein bypass grafts on to the PDA artery and another to the diagonal. A prior catheterization for abnormal stress test (moderate inferior ischemia) revealed an atretic LIMA graft, however patent SVG graft to diagonal artery maintained TIMI-3 flow to LAD via the diagonal artery. The SVG graft to PDA was occluded with significant disease in right coronary artery. This correlated with the area of ischemia on the nuclear stress test and was thus treated with percutaneous coronary angioplasty. On this presentation her vitals were stable and remaining physical examination was grossly unremarkable. EKG showed normal sinus rhythm without evidence of ischemia. Cardiac enzymes were also normal. Given the nature of pain and her prior history of significant CAD, further risk stratification was done by performance of a vasodilatory nuclear stress test. The myocardial perfusion study revealed uniform perfusion, however transient ischemic dilation (1.39) was observed which was indicative of possible balanced ischemia due to presence of multi-vessel disease. Therefore the patient underwent cardiac catheterization which

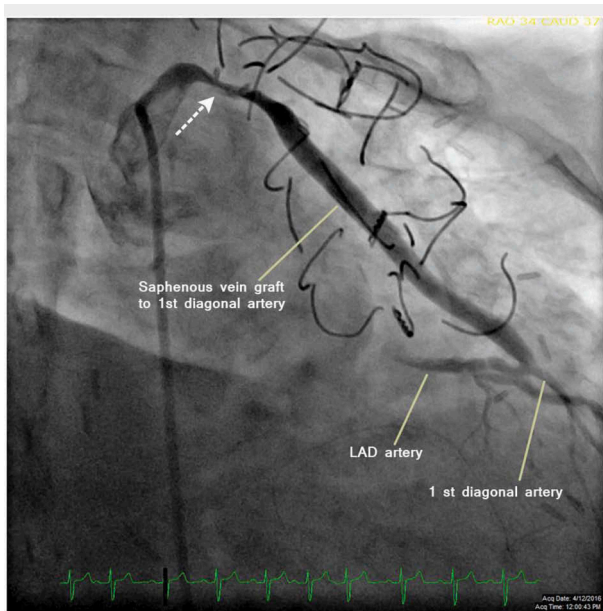


Figure 1. Angiogram with right anterior oblique (RAO)-caudal projection of the saphenous vein graft bypassing the first diagonal artery revealing severe spasm (dashed arrow) of the proximal portion of the graft.

showed an eccentric 70% lesion at ostium of the left main. The first vein graft to right coronary artery was totally occluded with patent stents in the RCA. The second venous graft to the diagonal vessel was widely patent and was providing TIMI-3 flow to the LAD as well. In the proximal aspect of this vein graft severe spasm was noted in multiple fluoroscopic projections and was associated with chest pain (Figure 1). The patient's symptoms and spasm resolved after administration of intracoronary (IC) nitroglycerine (Figure 2).

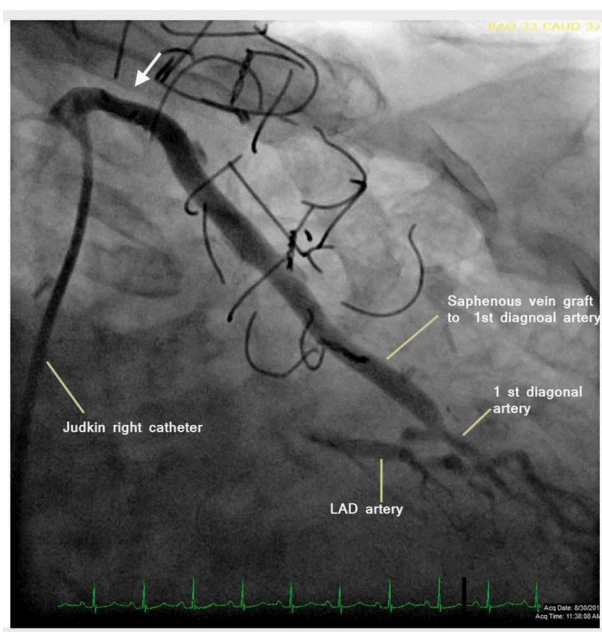


Figure 2. Angiogram with RAO-caudal projection depicting resolution of saphenous vein graft spasm (solid arrow) after intracoronary (IC) administration of nitroglycerin.

The angina symptoms in our patient were therefore attributed to spasm of the saphenous vein graft. Patient was subsequently started on amlodipine and isosorbide mononitrate which resulted in long-term resolution of her symptoms.

3. Discussion

Coronary artery bypass grafting (CABG) surgery remains the standard treatment for patients with multivessel coronary artery disease. During the past decade, percutaneous coronary intervention has been increasingly used for revascularization in patients with multivessel disease and low syntax score and in the presence of medically refractory angina in the setting of one/two-vessel disease (especially if not involving the proximal left anterior descending coronary artery) [1,2]. Autologous arteries are preferred over veins for bypass grafts due to better long-term outcomes stemming largely from the superior patency rate of the internal mammary grafts [3,4]. This has led to the use of the left internal mammary artery to graft for the bypass of the diseased LAD becoming the standard method for almost all CABG surgeries. The existence and incidence of vasospasm in CABG surgery using arterial grafts and its pathophysiologic mechanisms have been studied and discussed in the literature. Refractory vascular spasm has been reported to occur in between 0.8% and 1.3% of CABG procedures, although transient coronary or graft spasm has been shown to affect up to 11% of operated patients [5–7].

Meanwhile aortocoronary surgery with saphenous vein bypass grafting has been performed since 1968 for the treatment of atherosclerotic coronary artery disease [8]. As compared to LIMA grafts the SVG grafts have higher closure rates of 61% in 10 years for SVGs compared with 85% for IMA grafts resulting frequently in angina, myocardial infarction, and heart failure [9]. There are various mechanisms for SVG disease including thrombotic closure, neointimal hyperplasia causing intimal damage, fibrosis, platelet aggregation, release of growth factors, and smooth muscle cell proliferation. Technical factors, such as poor distal runoff, graft kinking, and small target vessel diameter also predispose grafts to occlusion. After the first year aggressive atherosclerotic narrowing occurring over the already abnormal endothelium is the main mechanism for graft failure [10]. Atherosclerotic plaques in SVGs are more diffuse, friable, contain more foam and inflammatory cells, have absent or small fibrous caps, and little or no calcification in comparison to native coronary atherosclerosis. However only a few case reports describe the presence and mechanism of spasm of a venous graft after CABG surgery. Spasm of saphenous veins used as aorto-coronary bypass grafts was first

described by Victor et al. [11,12], however its presence remains contentious until today. Moreover it is quite unusual to find it in venous segments used as arterial grafts beyond one year of surgery. The suggested explanation for this is that by this time the hyperplastic process of the venous wall is completed, resulting in gradual loss of viable smooth muscle cells and conversion of the vein into an anelastic, rigid tube with little tendency for vasomotion [13]. Therefore it is very rare to see spasm of venous graft especially after one year of CABG surgery. Our literature review found that there are six reported cases of SVG spasm and all of them presented early (<2 year) in relation to CABG surgery (Table 1). Our case is unique in demonstrating that the phenomenon of SVG spasm can occur even many years after surgery and can be responsible for anginal symptoms which can be managed with anti-spasmodic medications. The occurrence of this very late SVG spasm (>3 years) has never been reported in literature.

Even though the exact mechanism has not been established several theories have been postulated for spasm of vascular grafts. These possible mechanisms have been almost exclusively studied on arterial rather than venous grafts. In general, vasoconstriction may be evoked by a number of stimulants including mechanical and/or nerve stimulation and platelet dysfunction as well as vasoconstrictor substances called spasmogens [11,17]. Common spasmogens include endothelin -1, thromboxane A2, prostaglandins, α -adrenoceptor agonists, and platelet-derived substances (eg, 5-hydroxytryptamine) as well as mast cells and histamine. Activation of platelets also release thromboxane, which is a very powerful vasoconstrictor, meanwhile endothelial cells release prostacyclin, which is a vasodilator. The imbalance between vasoregulatory effects of thromboxane and prostacyclin leads to alteration in caliber of the vessel resulting in spasm. Vasospasm could also be related to endothelial dysfunction due to decreased production of prostacyclin. The intact endothelium may prevent spasm of the vessel by releasing a number of endothelium-derived relaxing factors such as nitric oxide, endothelium derived hyperpolarizing factor, and PGI2 which help balance

vasoconstriction and relaxation in the grafts. More recently the role of adipocytes producing large numbers of metabolically active substances with both endocrine and paracrine actions and the role of hypothermia have also been implicated in graft spasm [18,19]. Melville et al. suggested that coronary spasm is caused by neural impulses from the central nervous system or autonomic nervous system; however, this mechanism was challenged by the results of auto transplantation reported by Clark et al. who described severe refractory coronary arterial spasm in a patient with a cardiac transplant [20,21].

We believe in our case the most likely cause of graft spasm was due to chemical autoregulatory imbalance chemical mediators including thromboxane causing vasospasm. However, the definitive mechanism of spasm of venous graft still remains challenging and further studies are needed. The demonstration of spasm of the venous graft and favourable response of the angina to therapy with calcium channel blockers and nitrate suggest that the spasm of the venous graft must have played a significant role in our patient with angina even many years after surgery. Cardiac catheterization plays a central role in diagnosis by visualization of spasm in multiple angiographic projections and resolution of spasm/symptoms after administration of IC coronary vasodilators. However the diagnosis can be difficult due to the transient nature of vasospasm and the role of sophisticated provocative strategies for identification of SVG spasms is not well defined [22].

4. Conclusion

Contrary to prior reports in the medical literature, spasm of venous graft can even occur several years after CABG surgery. The diagnosis of this very late SVG spasm is challenging due to its transient nature with coronary angiography playing a central role. Careful provocative testing for SVG spasm may prove to be useful; however its role is not well defined. Once diagnosed, patients can be effectively managed with calcium channel blockers and nitrates with excellent outcomes.

Table 1. Reported cases of saphenous vein graft spasms along with age and gender of the patient, presenting symptoms and time of onset after coronary artery bypass graft surgery (CABG).

No.	Case reports	Age	Symptoms of spasm	Time of onset after CABG
1.	Sarandriaa et al. [8]	77 male	Low cardiac output	Day 1
2.	Victor et al. [11]	68 male	Angina	2 months
3.	Walinsky et al. [12]	66 male	Recurrent angina	6 months
4.	Maleki, M et al. [14]	54 male	Angina	14 months
5.	Takatsu et al. [15]	57 male	Exertional chest pain	20 months
6.	Porto et al. [16]	60 male	Severe rest angina	3 months
7.	Our case	72 female	Recurrent angina	3 years

Disclosure statement

No potential conflict of interest was reported by the authors.

ORCID

Nirmal Guragai  <http://orcid.org/0000-0002-6477-7789>

References

- [1] Taggart DP. CABG or stents in coronary artery disease: end of the debate? *Lancet*. 2013;381:605–607.
- [2] He G-W, David P. Taggart spasm in arterial grafts in coronary artery bypass grafting surgery. *Ann Thorac Surg*. 2016;101(3):1222–1229.
- [3] Sabik JF 3rd, Stockins A, Nowicki ER, et al. Does location of the second internal thoracic artery graft influence outcome of coronary artery bypass grafting? *Circulation*. 2008;118(14 Suppl):S210–S215.
- [4] Yi G, Shine B, Rehman SM, et al. Effect of bilateral internal mammary artery on long-term survival: a meta-analysis approach. *Circulation*. 2014;130:539–545.
- [5] Lorusso R, Crudeli E, Lucà F, et al. Refractory spasm of coronary arteries and grafted conduits after isolated coronary artery bypass surgery. *Ann Thorac Surg*. 2012;93:545–551.
- [6] Buxton AE, Goldberg S, Harken A, et al. Coronary artery spasm after myocardial revascularization. *N Engl J Med*. 1981;304:1249–53. 3.
- [7] Lemmer JH Jr, Kirsh MM. Coronary artery spasm following coronary artery surgery. *Ann Thorac Surg*. 1988;46:108–115.
- [8] Sarandria D, Benassi F, Massarenti L, et al. Intractable spasm of saphenous vein conduits after coronary artery bypass grafts. *J Cardiovasc Med*. 2011;12:893–895.
- [9] Goldman S, Zadina K, Moritz T1, et al. Long-term patency of saphenous vein and left internal mammary artery grafts after coronary artery bypass surgery. *J Am Coll Cardiol*. 2004;44(11):2149–2156.
- [10] Hindnavis V, Cho SH, Goldberg S1. Saphenous vein graft intervention: a review. *J Invasive Cardiol*. 2012;24(2):64–71.
- [11] Victor MF, Kimbiris D, Iskandrian AS, et al. Spasm of a saphenous vein bypass graft: a possible, mechanism for occlusion of the venous graft. *Chest*. 1981;80:413–415.
- [12] Walinsky P. Angiographic documentation of spontaneous spasm of saphenous vein coronary artery bypass graft. *Am Heart J*. 1982;103:290–292.
- [13] Manfrini O, Pizzi C, Viecca M, et al. Abnormalities of cardiac autonomic nervous activity correlate with expansive coronary artery remodeling. *Atherosclerosis*. 2008;197:183–189.
- [14] Maleki M, Manley JC. Venospastic phenomena of saphenous vein bypass grafts: possible causes for unexplained postoperative recurrence of angina or early or late occlusion of vein bypass grafts. *Heart*. 1989;62:57–60.
- [15] Takatsu F, Ishikawa H, Nagaya T. A case with spasm of a saphenous vein graft. *Jpn Heart J*. 1987;28:947–953.
- [16] Porto I, Burzotta F, Mongiardo R, et al. Left main and saphenous vein graft spasm: an unusual association. *Int J Cardiol*. 2005;99:133–134.
- [17] He GW, Rosenfeldt FL, Buxton BF, et al. Reactivity of human isolated internal mammary artery to constrictor and dilator agents. Implications for treatment of internal mammary artery spasm. *Circulation*. 1989;80 (3 Pt 1):I141–50.
- [18] Aghamohammadzadeh R, Withers S, Lynch F, et al. Perivascular adipose tissue from human systemic and coronary vessels: the emergence of a new pharmacotherapeutic target. *Br J Pharmacol*. 2012;165:670–82. 72.
- [19] Bodelsson M, Arneklo-Nobin B, Chester AH, et al. Differential effect of hypothermia on the vascular tone and reactivity of the human coronary artery and graft vessels. *J Cardiovasc Surg (Torino)*. 1991;32:288–294.
- [20] Melville K, Garvey H, Shister E, et al. Central nervous system stimulation and cardiac ischemic changes in monkeys. *Ann NY Acad Sci*. 1969;156:241–260.
- [21] Clark DA, Quint RA, Mitchell RL, et al. Coronary artery spasm. Medical management, surgical denervation, and autotransplantation. *J Thorac Cardiovasc Surg*. 1977;73:332–339.
- [22] Zaya M 1, Mehta PK 1, Merz CN 2. Provocative testing for coronary reactivity and spasm. *J Am Coll Cardiol*. 2014;63:103–109.