

Available online at [www.sciencedirect.com](http://www.sciencedirect.com)

ScienceDirect

journal homepage: [www.elsevier.com/locate/radcr](http://www.elsevier.com/locate/radcr)

## Case Report

# Insufficiency fractures: A rare cause of foot and ankle pain in three patients with rheumatoid arthritis☆☆☆

Katherine C.L. Hillyard\*, Shabnam Shabbir, Udawattage Nadeeka Sirisena, Maxine Hogarth, Ajay Sahu

Radiology Department, Ealing Hospital, Uxbridge Rd, Southall, London UB1 3HW, UK

## ARTICLE INFO

## Article history:

Received 16 February 2018

Revised 24 May 2018

Accepted 26 May 2018

## Keywords:

Insufficiency

Fracture

Fragility

Rheumatoid

Foot

Ankle

## ABSTRACT

Insufficiency fractures are recognized but rare complications in patients with longstanding rheumatoid arthritis. Such fractures are typically solitary and are rarely seen to affect the foot and ankle. We describe 3 women with longstanding rheumatoid arthritis, treated with one, or a combination of, corticosteroids, DMARDs and anti-TNF, presenting with foot and ankle pain with no prior history of trauma. MRIs showed rare multiple florid insufficiency fractures of the foot and ankle, in 2 cases bilaterally, which were managed conservatively. These cases highlight the importance of considering insufficiency fractures in similar patients presenting with foot and ankle pain. Radiographs may fail to demonstrate these lesions, delaying diagnosis, and worsening patient outcome, therefore in such cases MRI is a valuable modality.

© 2018 The Authors. Published by Elsevier Inc. on behalf of University of Washington.

This is an open access article under the CC BY-NC-ND license.

(<http://creativecommons.org/licenses/by-nc-nd/4.0/>)

## Introduction

Rheumatoid arthritis predisposes patients to insufficiency fractures secondary to osteoporosis, this is in part due to the disease process, but also due to environmental factors such as reduced weight bearing and as a side effect of medications used to treat the disease. In the medical literature, single insufficiency fractures of the hip and pelvic girdle are more commonly reported. This case series presents 3 cases of insuffi-

ciency fractures that are unusual in a number of ways. First, the site of the fractures is unusual in affecting the foot and ankle, in 2 cases bilaterally. Second, the fractures are also florid rather than solitary in nature. Third, clinical suspicion of fracture was low with few signs of inflammation. And finally, in 1 case plain films of the extremities failed to detect any fracture, with MRI providing the final diagnosis. This paper highlights the importance of including insufficiency fracture in one's differential, in patients with longterm RA presenting with pain.

\* Acknowledgments: This case report had no source of funding or relevant financial interest.

☆☆ Conflict of interests: The authors have declared there is no known potential conflict of interest.

\* Corresponding author.

E-mail addresses: [katehillyard@hotmail.co.uk](mailto:katehillyard@hotmail.co.uk) (K.C.L. Hillyard), [shabnam.shabbir@nhs.net](mailto:shabnam.shabbir@nhs.net) (S. Shabbir), [n.sirisena@gmail.com](mailto:n.sirisena@gmail.com) (U.N. Sirisena), [maxine.hogarth@nhs.net](mailto:maxine.hogarth@nhs.net) (M. Hogarth), [asahu@nhs.net](mailto:asahu@nhs.net) (A. Sahu).

<https://doi.org/10.1016/j.radcr.2018.05.016>

1930-0433/© 2018 The Authors. Published by Elsevier Inc. on behalf of University of Washington. This is an open access article under the CC BY-NC-ND license. (<http://creativecommons.org/licenses/by-nc-nd/4.0/>)

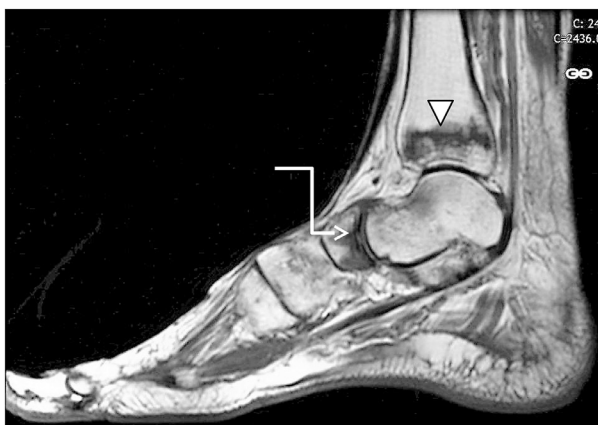## Case 1

### Presentation

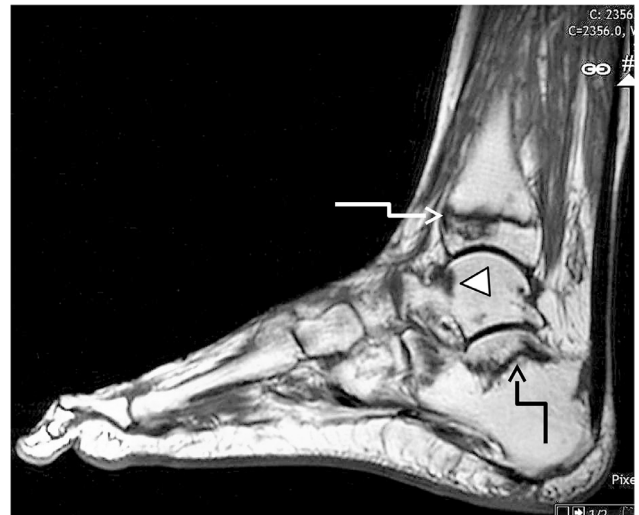
Case 1 is a 66-year-old lady with seropositive RA treated with methotrexate for over 20 years. In September 2015, her arthritis became active and she had synovitis affecting her ankles and feet. She received a steroid injection and the methotrexate was increased. She was also commenced on alendronate, as she had osteoporosis with a T score of  $-2.6$  in the femoral neck and  $-2.7$  in the spine, with a 16% 10 year probability of major fracture using fracture risk assessment tool assessment. Calcium and vitamin D levels were normal. The inflammation improved, but the pain in the ankles and feet increased. X-rays of the right foot in February 2016 showed osteopenia and 4th and 5th metatarsophalangeal (MTP) subluxation and degenerative change and she was referred for podiatry assessment for presumed mechanical foot pain. In March 2016, she was complaining of severe pain in the feet, worse on the right with difficulty weight bearing and was seen by an orthopaedic consultant in April. On examination, she had tenderness particularly over the ankle and subtalar joints and Achilles tendons but the joints were not hot, red, or swollen.

### Investigation

She was referred to radiology for MRI of both feet and/or ultrasound guided steroid injections. An MRI of both feet was performed. MRI of the right foot showed multiple fractures in the ankle and foot with extensive high signal change noted within the distal tibia, posterior talus, cuboid, and calcaneus with corresponding serpentine low signal lines noted in these respective bones (Figs. 1a,2,3). MRI of the left foot showed extensive marrow oedema in the distal tibia, calcaneus, talar neck, navicular, and proximal phalanx of the great toe with corresponding low signal lines in the distal tibia, calcaneus, and navicular (Fig. 2). Further high signal changes were noted within the lateral cuneiform. In short, she had florid bilateral insufficiency fractures of the foot and ankle (Fig. 1b).



**Fig. 1a – Case 1—Sagittal T1 image of right foot and ankle. Serpentine low signal changes within the distal tibial metaphysis (white arrowhead) and navicular (white arrow).**



**Fig. 1b – Case 1—Sagittal T1 images of left foot and ankle showing low signal serpentine line in keeping with fractures in the distal tibial metaphysis (white arrow), posterior calcaneus (black arrow), and talar neck (white arrowhead).**

### Treatment

From an orthopaedic perspective, she was managed conservatively using an air-cast boot for 3 months. Repeat MRI at 3 months showed healing fractures, following which she was discharged by orthopaedics. She remains under regular rheumatology follow up.

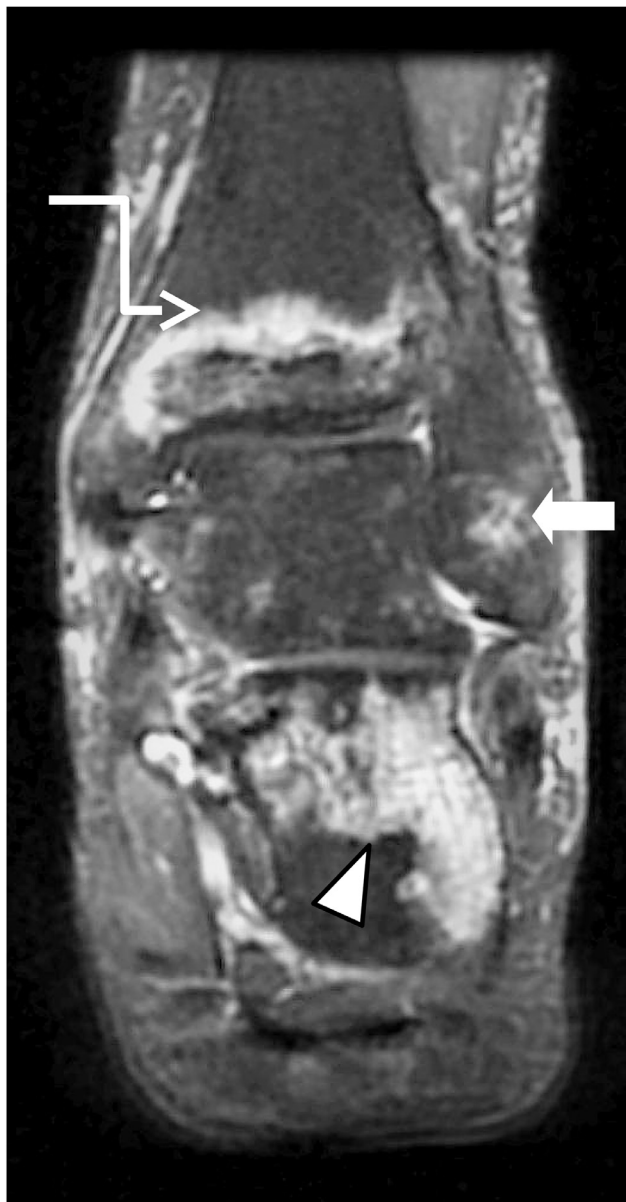## Case 2

### Presentation

Case 2 is a 75-year-old lady who was diagnosed with seronegative rheumatoid arthritis in 2003 at a center elsewhere and was seen in our department in March 2017. She was taking methotrexate 20 mg once weekly and had not received any corticosteroid treatment to our knowledge (previous clinical records were unavailable). Two months previously she had developed increased right ankle pain and swelling, and had received a course of antibiotics from the GP for an associated infection and had recently been started on furosemide for ongoing swelling. On examination she had pitting oedema at the ankle with reduced movement and mild tenderness but there was no erythema. The furosemide was discontinued and an ankle MRI was requested.

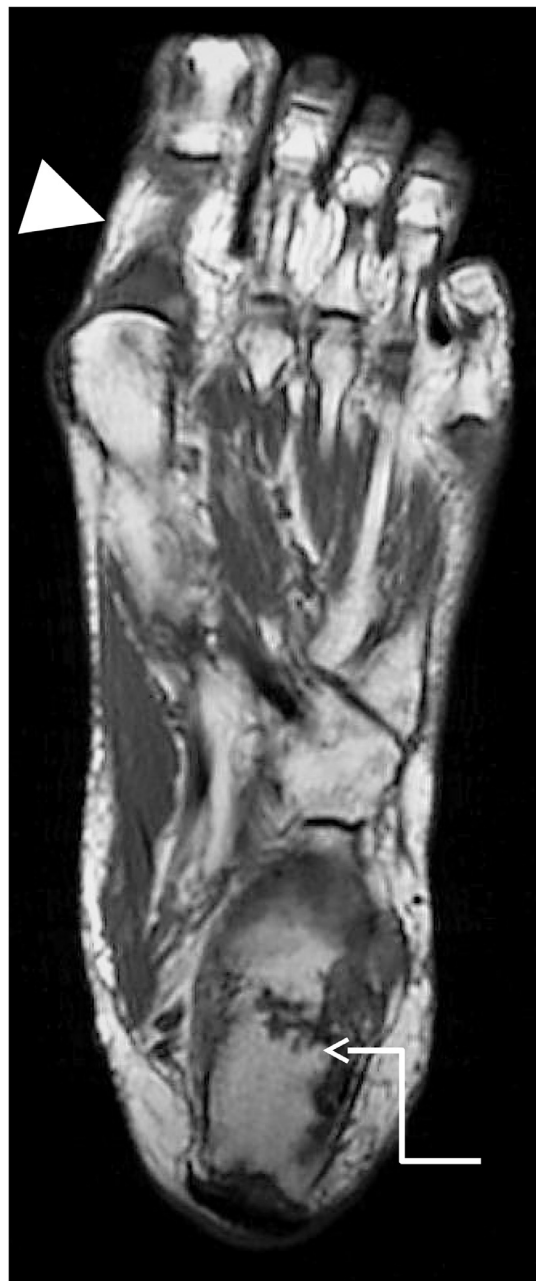
### Investigation

MRI showed a complete healing insufficiency fracture in the lower one-third of the tibia as evidenced by high signal change, periosteal reaction, callus formation, and subtle val-



**Fig. 2 – Case 1—Coronal STIR image of the right ankle showing high signal changes within the distal tibial metaphysis (thin arrow), lateral malleolus (thick arrow), and florid oedematous changes within the calcaneus (arrowhead) in keeping with the acute insufficiency fractures.**

gus angulation (Fig. 4). In addition, there were multilevel insufficiency fractures of the lower third of the distal tibia, fibula and posterior talus, and the upper calcaneus (Fig. 5). Several days later she went on to have an ultrasound and a plain radiograph of the right foot. Ultrasound noted ankle joint effusion or the appearance of synovitis as well as gross subcutaneous oedematous changes. X-ray showed healing insufficiency fracture of the right lower one-third of the distal tibia with some callus formation on the lateral aspect as well as healing fractures of the distal one-third of the fibula and subchondral bone of the right distal tibia. While generalized os-

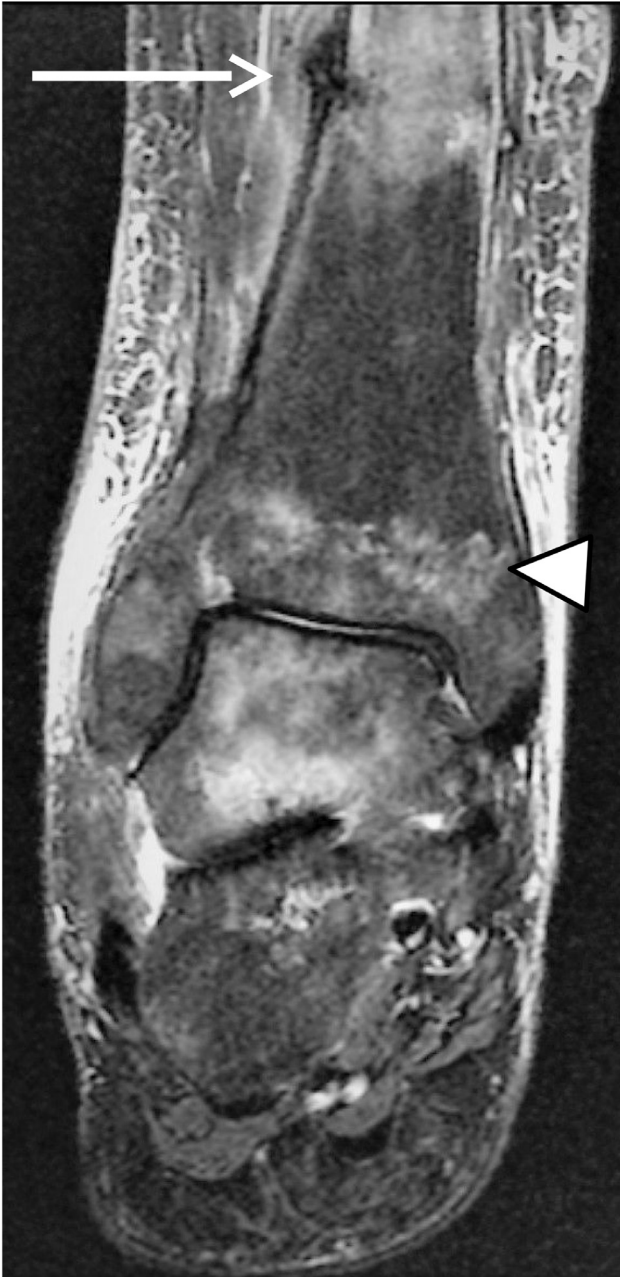

**Fig. 3 – Case 1—Long axis axial T1 image showing low signal changes within the right calcaneus (white arrow), and proximal phalanx of the great toe showing multiple fractures (arrowhead) in keeping with oedematous change associated with serpentine fracture lines.**

teopenia of the bones was noted, the florid insufficiency fractures of the hindfoot were not identifiable (Fig. 6).

#### Treatment

She was commenced on oral bisphosphonate treatment at diagnosis of her insufficiency fractures. She was treated conservatively in an air-cast boot. She has been discharged by orthopaedics and remains under rheumatology follow up.

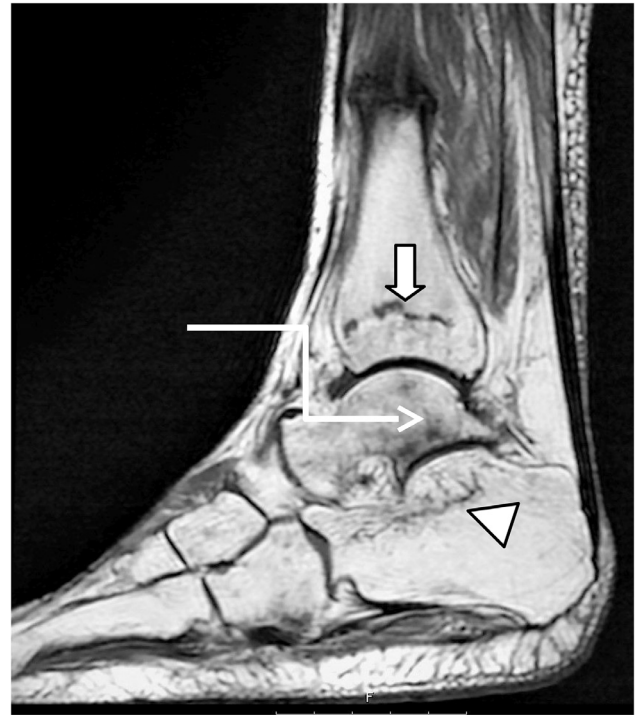


**Fig. 4 – Case 2—Coronal STIR image of right foot and ankle showing a complete healing insufficiency fracture in the lower one-third of the tibia as evident by high signal change, periosteal reaction, callus formation, and subtle valgus angulation (white arrow). Insufficiency type fracture within the distal tibia as evident by serpentine high signal line (arrowhead).**

### Case 3

#### Presentation

Case 3 is a 74-year-old woman diagnosed with seropositive rheumatoid arthritis in 2009. She also had bilateral knee re-

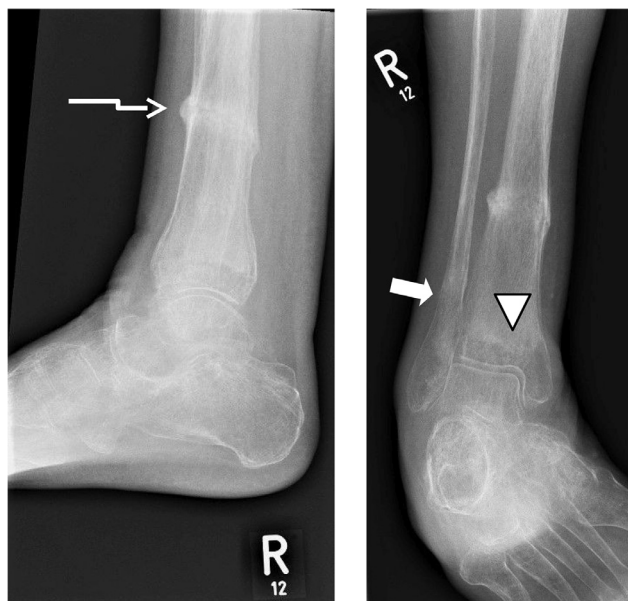

**Fig. 5 – Case 2—Sagittal T1 image of right foot showing serpentine low signal line in the inferior talus to the subtalar joint (thin arrow) with a similar line in the posterosuperior aspect of the calcaneus (arrowhead), and distal tibia (thick arrow) suggestive of further pathological fractures.**

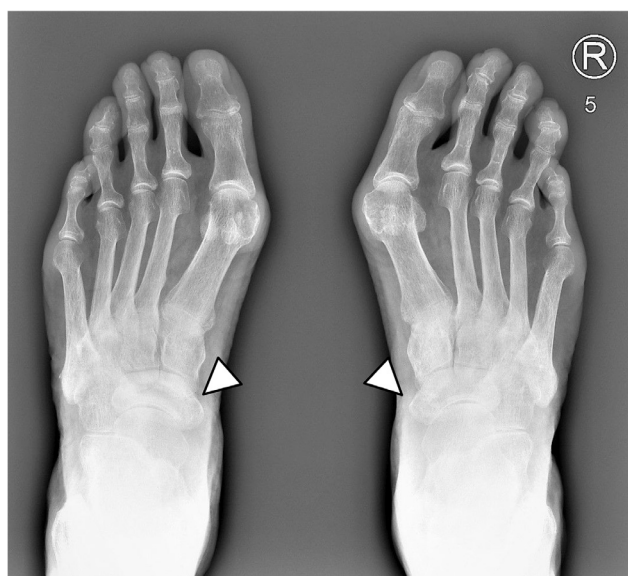
placements for degenerative joint disease and a history of mechanical foot pain for which she had seen a podiatrist. Her arthritis was controlled on methotrexate 15 mg once weekly but in 2016 she started to have flares affecting the ankles and feet, the methotrexate was increased, hydroxychloroquine and sulfasalazine added and she received several steroid injections and a course of oral steroids. In March 2017, her disease activity had improved but she was still complaining of pain in the feet with synovitis at 2 metacarpal phalangeal joints and the ankles were noted to be warm. X-rays and an MRI of the feet were requested.

#### Investigation

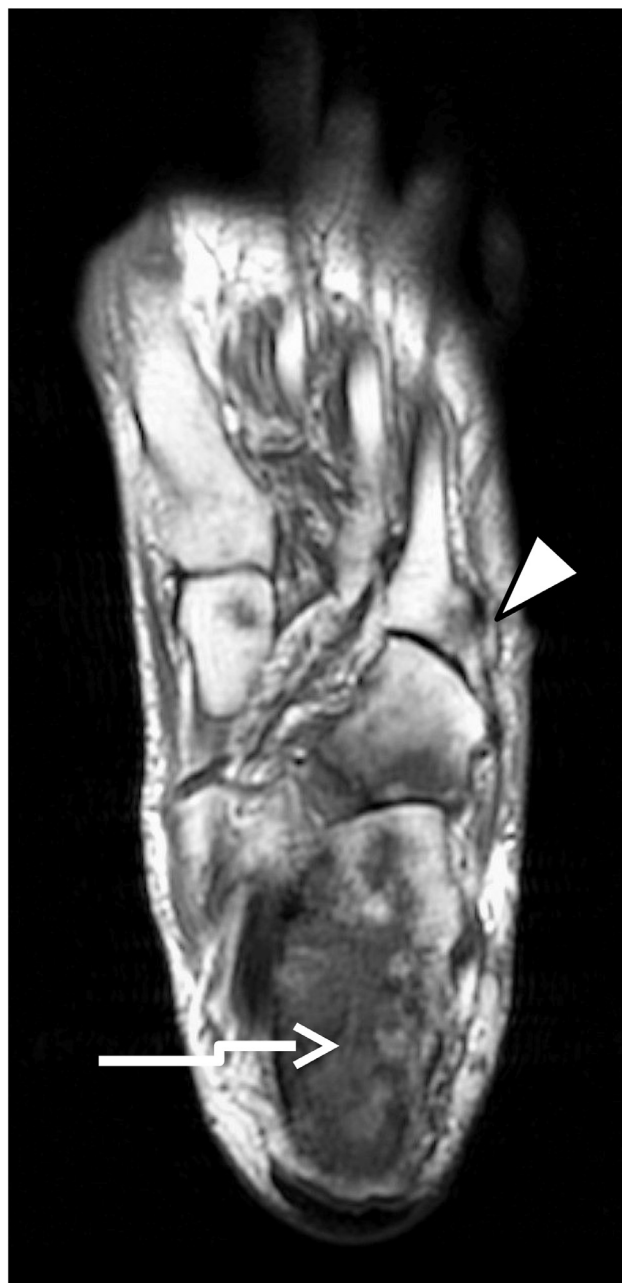She went on to have plain radiographs of both feet. While generalized osteopenia and mild-to-moderate degenerative changes in the bilateral first MTPJs and mid foot joints were noted there was no sign of fracture (Fig. 7). She went on to have an MRI. Left foot MRI showed extensive high signal changes within the posterior aspect of the calcaneus, with subchondral collapse and corresponding low signal line on T1 imaging in keeping with pathological fracture of the calcaneus (Fig. 8). Less florid high signal changes were noted within the navicular, accompanied by a low signal line noted on T1 imaging in keeping with a second insufficiency fracture. Further oedematous changes were noted within the proximal aspect of the cuboid in keeping with microtrabecular fracture. Fur-



**Fig. 6 – Case 2—Anteroposterior and lateral plain radiographs of right ankle showing healing insufficiency fracture of the right lower one-third of the distal tibia with some callus formation on the lateral aspect (thin arrow). Alongside healing fractures of the distal one-third of the fibula (thick arrow) and subchondral bone of the right distal tibia (arrowhead). Generalized osteopenia of the bones noted. Multiple fractures of the hindfoot bones are unidentifiable.**



**Fig. 7 – Case 3—plain radiographs of both feet showing generalized osteopenia and no erosive arthropathy. There is increased sclerosis of bilateral navicular bones (arrowheads).**



**Fig. 8 – Case 3—left foot long axis axial T1 image showing low signal line in keeping with pathological fracture of the calcaneus (white arrow). Oedematous changes noted within the proximal aspect of the cuboid in keeping with microtrabecular fracture and proximal aspect of the fifth metatarsal base (arrowhead).**

ther areas of patchy oedematous changes in the bone marrow were noted within the distal tibia, lateral malleolus, proximal aspect of the fifth metatarsal base, and in the intermediate cuneiform.

#### Treatment

She went on to have a dual energy X-ray absorptiometry scan that surprisingly showed a T score of  $-1.3$  at the hip (os-

teopenia) and T score of  $-0.7$  at the spine (normal). Vitamin D was borderline low at 54 with normal calcium levels. Vitamin D was replaced and alendronic acid commenced. She was managed conservatively in an air-cast boot following which she was discharged from orthopaedics. She remains under rheumatology follow up.

---

## Discussion

Rheumatoid arthritis is a chronic autoimmune inflammatory condition of unclear aetiology. It is thought to be a product of genetic susceptibility and environmental triggers [1,2]. A conservative estimate for RA prevalence in the UK is 1.16% in women and 0.44% in men [3]. RA primarily affects the joints. Synovitis causes a symmetrical destruction of the articular cartilage leading to pain and loss of movement. Chronic joint inflammation associated with RA is known to cause local osteoporosis in subchondral bone. However RA sufferers are at increased risk of osteoporosis at sites distant to joint inflammation. The reason behind this is thought to be due to the systemic nature of inflammation present in RA. In healthy bones there is a balance between bone resorption and formation. The inflammatory changes associated with RA decouple these forces, leading to an overall bone loss with cancellous bone being most affected [4–6]. Inflammatory cytokines including  $\text{TNF}\alpha$  and interleukins 1, 7, 11, and 17 have been implicated in this pathophysiology [4]. These cytokines increase expression of receptor activator of nuclear factor kappa-B ligand which binds to RANK initiating bone resorption [7]. The rate of bone formation cannot keep pace with the rate of bone resorption leading to generalized weakening of the bone, predisposing RA patients to insufficiency fractures secondary to osteoporosis [8]. In addition pain, reduced range of movement and the increased basal metabolic rate associated with RA contribute to reduced loading of the bone and muscle atrophy further predisposing patients to osteoporosis [7]. Treatments for RA also increase bone loss. Glucocorticoids which are used long-term to suppress immune mediated inflammation reduce bone strength and stiffness [4,9]. While high level evidence is lacking, methotrexate osteopathy has also been implicated in increasing susceptibility to insufficiency fractures in RA patients via osteoblast inhibition [10].

Insufficiency fractures are a type of stress fracture caused by subthreshold trauma to diseased bone. Loss of trabecular bone reduces the elastic resistance of the bone, predisposing it to fracture [11]. Insufficiency fractures are commonly seen in bones with a high proportion of trabecular bone such as the vertebrae, femur, pelvis, and irregular bones of the foot [5,12]. This type of fracture of the foot and ankle usually involves the second metatarsal and the calcaneus, with the navicular and talus less commonly involved [13]. If early insufficiency fractures are suspected, MRI and bone scans are preferable imaging modalities. On plain radiograph insufficiency fractures may show as radiolucent lines in osteopenic bone, but in cases of recent fracture appearances may be normal. MRI has equal sensitivity to bone scans but higher specificity for locating the exact site and aetiology of the abnormality [14]. MRI is adept at identifying soft tissue abnormalities, for ex-

ample in the bone marrow [15]. Features suggestive of insufficiency fracture on MRI include ill-defined low bone marrow signal on T1-weighted images with a hypointense serpentine intramedullary fracture line which may extend to the cortex [11,16]. T2-weighted images show high bone marrow signal and may be accompanied by a hypointense periosteal callus [13]. Changes in bone marrow signal are caused by oedema or haemorrhage, in either case the borders are poorly defined [13]. The fracture line and surrounding oedema become more apparent several weeks after injury [13]. Contrast enhancement, typically with gadolinium, can help delineate lesions.

There are case reports documenting single insufficiency fractures, for example, Straaton et al.'s case series reported 3 patients with RA and distal tibial fracture. Similarly, atypical fractures have been identified at the subtrochanteric and/or femoral diaphysis in patient with RA, taking glucocorticoids, methotrexate, and alendronate. Multiple fractures of the pelvis and lumbosacral region were reported by Fukunishi et al. [17]. There are infrequent case reports in the medical literature describing insufficiency foot fractures in more than 1 bone in patients with RA. Spina et al. report 1 case of talar and calcaneal insufficiency fracture in a patient with RA [13]. Plain radiograph suggested a fracture in the foot, which was confirmed by MRI and bone scintigraphy. The cases we present are unusual in that they show multiple fractures in numerous bones in the foot and ankle, in 2 cases bilaterally. As far as the authors are aware, no other case series has reported similar presentations. A further salient feature is that plain film did not detect any fracture, despite MRI findings showing florid and multiple insufficiency fractures. From this we can appreciate the importance of investigating patients with MRI, which is superior at identifying early changes associated with fracture, such as bone marrow oedema.

---

## Informed consent statement

Written informed consent was obtained from all 3 patients for publication of this case report, including accompanying images.

---

## Learning points

- Clinicians need to consider insufficiency fractures in their differential diagnosis when patients present with reduced functional status or joint or bone pain, with a background of RA and corticosteroid use.
- Complaints of new or worsening symptoms need to be investigated as symptoms of insufficiency fracture are difficult to differentiate from an exacerbation of RA. Delay in diagnosis can lead to worse outcomes.
- Plain radiograph may fail to elucidated pathology, so consideration of MRI is strongly advised for patients with RA complaining of pain or loss of functional status without a history of trauma.

## REFERENCES

- [1] Gibofsky A. Overview of epidemiology, pathophysiology, and diagnosis of rheumatoid arthritis. *Am J Manag Care* 2012;18((December) 13 Suppl):S295–302.
- [2] MacGregor AJ, Snieder H, Rigby AS, Koskenvuo M, Kaprio J, Aho K, et al. Characterizing the quantitative genetic contribution to rheumatoid arthritis using data from twins. *Arthritis Rheum* 2000;43((January) 1):30–7.
- [3] Symmons D, Turner G, Webb R, Asten P, Barrett E, Lunt M, et al. The prevalence of rheumatoid arthritis in the United Kingdom: new estimates for a new century. *Rheumatology* 2002;41((July) 7):793–800.
- [4] Takahata M, Maher JR, Juneja SC, Inzana J, Xing L, Schwarz EM, et al. Mechanisms of bone fragility in a glucocorticoid-treated mouse model of rheumatoid arthritis – implications for insufficiency fracture risk. *Arthritis Rheum* 2012;64((October) 11):3649–59.
- [5] Pathria MN, Chung CB, Resnick DL. Acute and stress-related injuries of bone and cartilage: pertinent anatomy, basic biomechanics, and imaging perspective. *Radiology* 2016;280((July) 1):21–38.
- [6] Walsh NC, Reinwald S, Manning CA, Condon KW, Iwata K, Burr DB, et al. Osteoblast function is compromised at sites of focal bone erosion in inflammatory arthritis. *J Bone Miner Res* 2009;24((September):1572–85.
- [7] Maruotti N, Corrado A, Cantatore FP. Osteoporosis and rheumatic diseases. *Reumatismo* 2014;66((June) 2):125–35.
- [8] Kim SY, Schneeweiss S, Liu J, Daniel GW, Chang CL, Gameau K, et al. Risk of osteoporotic fracture in a large population-based cohort of patients with rheumatoid arthritis. *Arthritis Res Ther* 2010;12(4):R154.
- [9] Kanis JA, Johansson H, Oden A, Johnell O, de Laet C, Melton LJ III, et al. A meta-analysis of prior corticosteroid use and fracture risk. *J Bone Miner Res* 2004;19((June) 6):893–9.
- [10] Preston SJ, Diamond T, Scott A, Laurent MR. Methotrexate osteopathy in rheumatic disease. *Ann Rheum Dis* 1993;52:582–5.
- [11] Krestan CR, Nemeč U, Nemeč S. Imaging of insufficiency fractures. *Semin Musculoskelet Radiol* 2011;15((July) 3):198–207.
- [12] van Staa TP, Geusens P, Bijlsma JW, Leufkens HG, Cooper C. Clinical assessment of the long-term risk of fracture in patients with rheumatoid arthritis. *Arthritis Rheum* 2006;54((October) 10):3104–12.
- [13] Spina A, Clemente A, Vancini C, Fejzo M, Campioni P. Spontaneous talar and calcaneal fracture in rheumatoid arthritis: a case report. *J Radiol Case Rep* 2011;5(7):15–23.
- [14] Berger FH, de Jonge MC, Maas M. Stress fractures in the lower extremity. The importance of increasing awareness amongst radiologists. *Eur J Radiol*. 2007;62((April) 1):16–26.
- [15] Rosenberg ZS, Beltran J, Bencardino JT. From the RSNA refresher courses. Radiological Society of North America. MR imaging of the ankle and foot. *Radiographics* 2000;20((October):S153–79.
- [16] Fayad LM, Kawamoto S, Kamel IR, Bluemke DA, Eng J, Frassica FJ, et al. Distinction of long bone stress fractures from pathologic fractures on cross-sectional imaging: how successful are we? *AJR Am J Roentgenol* 2005;185((October) 4):915–24.
- [17] Fukunishi S, Fukui T, Nishio S, Imamura F, Yoshiya S. Multiple pelvic insufficiency fractures in rheumatoid patients with mutilating changes. *Orthop Rev* 2009;1((October) 2):e23.