



Contents lists available at ScienceDirect

International Journal of Surgery Case Reports

journal homepage: www.casereports.com

Perforation of intestinal leiomyosarcoma: A case report

Shota Fukai^{a,*}, Alan Kawarai Lefor^b, Kazuhiro Nishida^a^a Department of Surgery, Tokyo Bay Medical Center, 3-4-32 Todajima, Urayasu, Chiba, 279-0001, Japan^b Department of Surgery, Jichi Medical University, 3311-1 Yakushiji, Shimotsuke-shi, Tochigi, 329-0498, Japan

ARTICLE INFO

Article history:

Received 12 January 2021

Received in revised form 15 January 2021

Accepted 15 January 2021

Available online 19 January 2021

Keywords:

Leiomyosarcoma

Perforation

Small intestine

ABSTRACT

INTRODUCTION AND IMPORTANCE: The majority of gastrointestinal sarcoma is gastrointestinal stromal tumors and intestinal leiomyosarcoma is rare. Small intestinal mesenchymal tumors are often large at diagnosis, and they commonly present with bleeding or intussusception. We report a perforation associated with intestinal leiomyosarcoma.

CASE PRESENTATION: A 66-year-old man presented with severe epigastric pain. A physical examination showed tachycardia and a diffusely tender and rigid abdomen. Computed tomography showed a massive tumor and free air. A laparotomy was performed to treat lower digestive perforation. Massive tumor, which invaded surrounding intestine, was 20 cm in size at the ileum. The involved intestine was perforated. We confirmed that feeding artery was superior mesenteric artery and performed partial intestinal resection. His clinical course was uneventful and discharged 10 days postoperatively. The pathological findings showed spindle shaped and the tumor invaded the mucosa at the perforated site. Immunohistochemical spectrum resulted c-kit negative, S-100 negative, Desmin positive, alpha smooth muscle actin(α SMA) positive and Ki-67 30–40%. The pathological findings were leiomyosarcoma.

DISCUSSION: Gastrointestinal sarcoma is sometimes found by bleeding. In our patient, leiomyosarcoma invaded surrounding intestine, it made the intestine wall frail and caused perforation. The intestinal perforation which was involved by leiomyosarcoma has been rarely reported to the best of our knowledge since WHO refined leiomyosarcoma.

CONCLUSIONS: Although intestinal leiomyosarcoma is rare, we should know that it can involve surrounding intestines and make them perforated.

© 2021 The Author(s). Published by Elsevier Ltd on behalf of IJS Publishing Group Ltd. This is an open access article under the CC BY-NC-ND license (<http://creativecommons.org/licenses/by-nc-nd/4.0/>).

1. Introduction and importance

The most common type of intestinal sarcoma is a gastrointestinal stromal tumors (GIST), accounting for 83–86 percent of cases [1,2]. A leiomyosarcoma is a rare smooth muscle malignant neoplasm which appears mostly in the retroperitoneal space, vascular wall and soft tissues of the lower extremities. It is an exceptionally rare tumor of gastrointestinal tract [3]. Although the clinical presentation was unpecific as in other small bowel tumors, it commonly present with bleeding and intussusception [4]. We report a perforation associated with intestinal leiomyosarcoma. This work is reported in accordance with the SCARE criteria [5].

2. Case presentation

A 66-year-old man presented with severe epigastric pain. He revealed a four-month history of abdominal distention that had

gradually worsened and was associated with sudden epigastric pain a few hours prior to presentation. He was otherwise healthy and denied the regular use of any medications. A physical examination showed a blood pressure of 170/90 mmHg, heart rate of 100 beats/min, respiratory rate of 20 breaths/min, and normal body temperature. An abdominal examination showed a diffusely rigid abdomen with rebound tenderness over the entire abdomen and reduced bowel sounds. We could touch massive mass on the upper abdomen. Contrast-enhanced abdominal computed tomography showed free air, amount of ascites and a massive tumor which was 15 × 11 × 20 cm in size and with mixed by hypodensity and hyperdensity (Fig. 1). The patient developed gastrointestinal perforation-induced peritonitis. An emergency laparotomy was performed and we observed a massive tumor, which invaded 50 cm surrounding intestine and looked like a lump of small intestine, was 20 cm in size and 200 cm from Treitz ligament. The tumor invaded not a remote intestine but a consecutive intestine. The anal edge of involved intestine was 100 cm from Bauhin's valve. The involved intestine was perforated. The perforated site was a few millimeters and invaded by tumor. We confirmed that feeding artery was superior mesenteric artery. We resected the massive tumor along with the involved intestines and performed primary anastomosis. The

* Corresponding author.

E-mail addresses: shoutaf@jadecom.jp (S. Fukai), alefor@jichi.ac.jp (A.K. Lefor), pandadebanda4@gmail.com (K. Nishida).

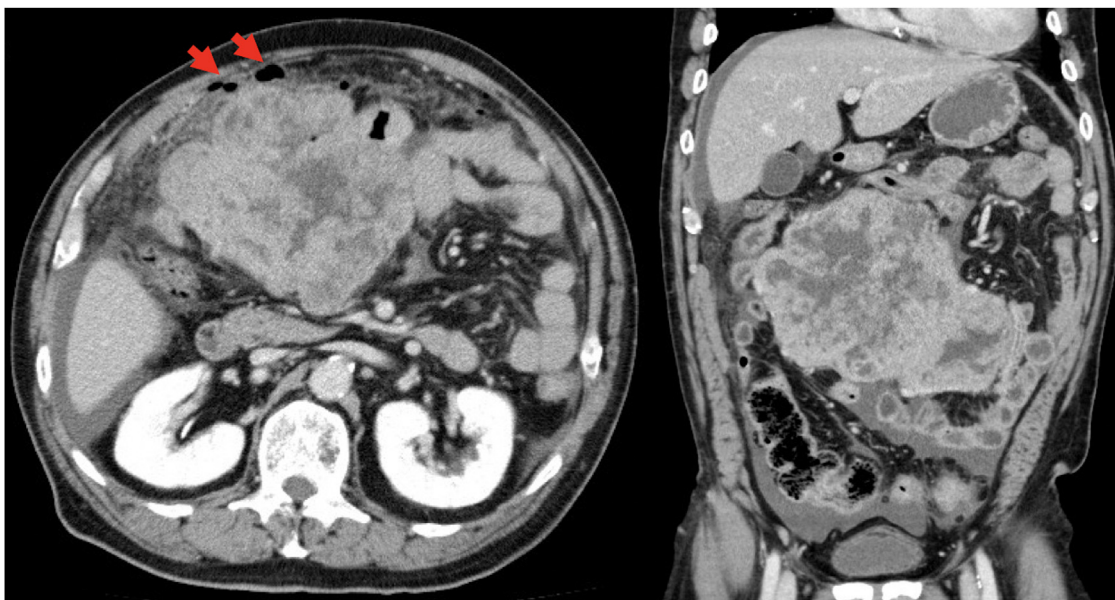


Fig. 1. Contrast-enhanced abdominal computed tomography showed free air (the red arrow), amount of ascites and a massive tumor which was 15 × 11 × 20 cm in size and with mixed by hypodensity and hyperdensity.

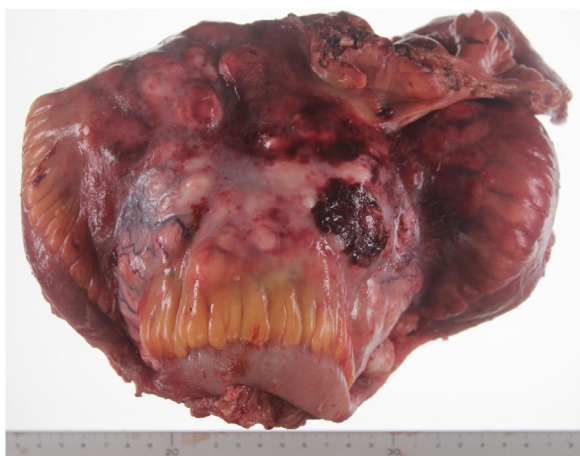

Fig. 2. Specimens from a partial intestinal resection. Normal intestine which was invaded by the tumor was perforated. The size was 14 × 13 × 20 cm. the tumor was soft, white and had myxoid change. The site of perforation was very small, but fibrins and clots attached around it.

resected specimen showed normal intestine which was invaded by the tumor was perforated. The tumor was soft, white and had myxoid change (Fig. 2). His postoperative clinical course was uneventful and discharged 10 days postoperatively. The pathological findings showed spindle shaped. The perforated site was invaded by tumor and the pathological findings at the perforated site showed it invaded the mucosa. Immunohistochemical spectrum resulted c-kit negative, DOG-1 negative, CD34 negative, S-100 negative, desmin positive, alpha smooth muscle actin(α SMA) positive and Ki-67 30–40% (Fig. 3). We diagnosed intestinal leiomyosarcoma.

3. Discussion

Since the pathological diagnosis of GIST using immunostaining of KIT protein was established by Hirota in 1998 [6]. WHO redefined small bowel leiomyosarcoma in 1999. The majority of previously classified leiomyosarcomas in order studies are fact GIST tumors [2]. It implies that sarcoma except for GIST would be very rare as a possibility. Symptoms are poor at an early stage, and it is

difficult to diagnose until the condition progressed and the symptoms appear prominently. The diagnosis of leiomyosarcoma is often intussusception and anemia due to tumor bleeding [4]. There are few case reports of perforation. Matsuda et al. analyzed case reports of leiomyosarcoma in the Japanese literature from 1989 through 1989 and reported the frequency of perforation was found to be 8.6% [7]. But, the literature was reported before the redefinition and we think that the frequency of perforation is actually rare.

We searched literatures about a perforation of intestinal leiomyosarcoma in the PubMed, which used WHO redefinition, from 1999 to now. We could find one literature which reported the perforation of small intestine by leiomyosarcoma as a metastasis of uterine leiomyosarcoma [8]. The same point between the case and our patient was that leiomyosarcoma invaded normal ileum all through the intestine wall from serosa into the mucosa regardless of the primary lesion and the size.

The mechanism of perforation is mainly divided into two; tumors themselves or tumor invasion. The former was sometimes reported before the redefinition, but we couldn't search the mechanism after the redefinition. We assumed that it is difficult to perforate at the primary lesion because intestinal leiomyosarcoma was often detected by mucosal symptoms as bleeding and intussusception before full layer infiltration. The latter involves directly invasion and development of dissemination lesion. As our patient, leiomyosarcoma invaded surrounding intestine. It made the intestine wall frail and caused perforation before mucosal symptoms. The intestinal perforation which was involved by leiomyosarcoma is the second case report to the best of our knowledge since WHO refined leiomyosarcoma.

Local recurrence rate of leiomyosarcoma is 38.5% and secondary metastasis rate was 70.6% [9]. The bad prognosis would be expected in case of the perforation although we don't know the concrete rate, because leiomyosarcoma would get larger, invade other organs and disseminate peritoneum at the time of perforation.

4. Conclusion

Although intestinal leiomyosarcoma is rare and the majority of symptoms are bleeding, we should know that it can involve

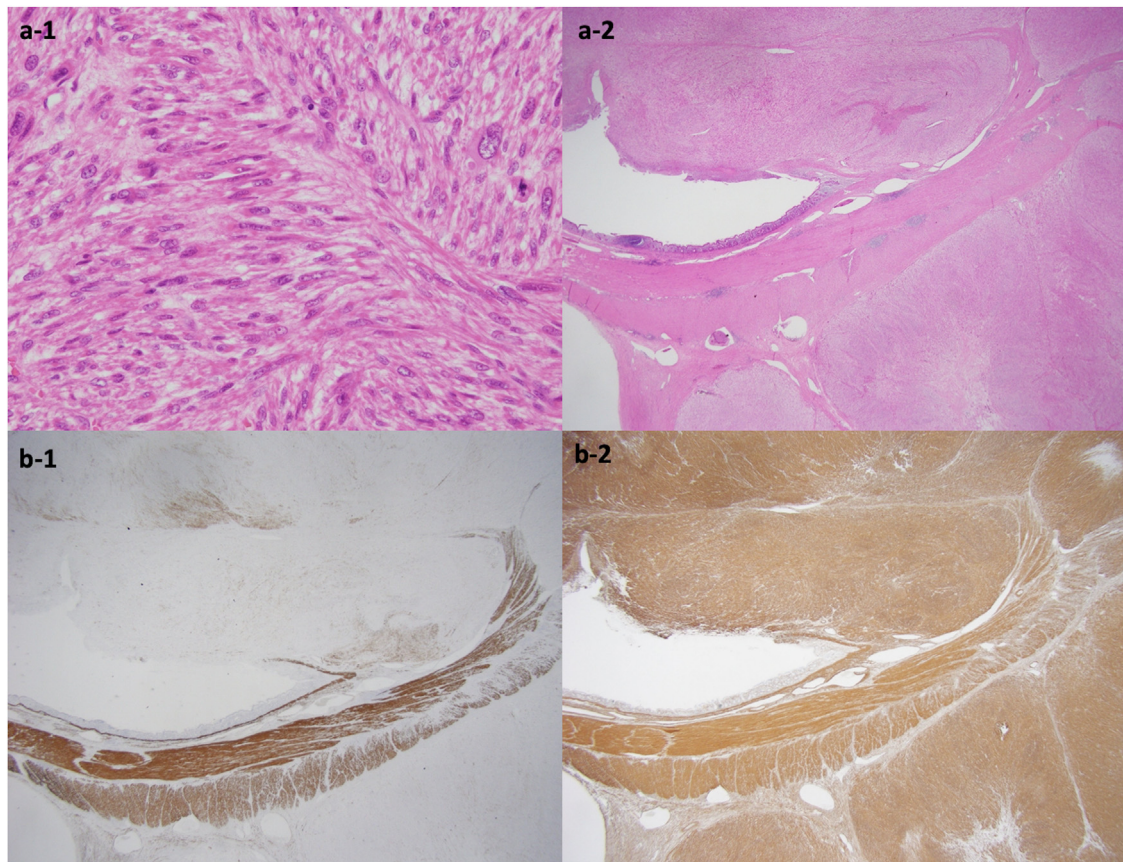


Fig. 3. Photomicrograph of the center of the excised specimen at low magnification (a-1: $\times 1.25$, a-2: $\times 400$) showing spindle shaped and invasion to the mucosa at the perforated site. Immunohistochemical photomicrograph of the center of the excised specimen at low magnification (b-1: $\times 1.25$, b-2: $\times 1.25$) showing desmin positive and alpha smooth muscle actin positive.

surrounding intestines and make them perforated. Further accumulation of perforated intestinal leiomyosarcoma is expected.

Declaration of Competing Interest

There are no conflicts of interest to be declared.

Funding

This research did not receive any specific grant from funding agencies in the public, commercial, or not-for-profit sectors.

Ethical approval

Not applicable.

Consent

Informed consent for the publication of this work was given by the patient. Written informed consent was obtained from the patient for publication of this case report and accompanying images. A copy of the written consent is available for review by the Editor-in-Chief of this journal on request.

Author contribution

SF and KN gathered the patient's data and wrote the manuscript. KN was responsible for the in-patient optimization. KN and AKL reviewed manuscript. All authors approved the final manuscript.

Registration of research studies

Not applicable.

Guarantor

Shota Fukai MD.

Provenance and peer review

Not commissioned, externally peer-reviewed.

Acknowledgements

None.

References

- [1] K.Y. Bilimoria, D.J. Bentrem, J.D. Wayne, C.Y. Ko, C.L. Bennett, M.S. Talamonti, Small bowel cancer in the United States: changes in epidemiology, treatment, and survival over the last 20 years, *Ann. Surg.* 249 (1) (2009) 63.
- [2] M. Miettinen, J. Kopczynski, H.R. Makhlof, M. Sarlomo-Rikala, H. Gyorffy, A. Burke, et al., Gastrointestinal stromal tumors, intramural leiomyomas, and leiomyosarcomas in the duodenum: a clinicopathologic, immunohistochemical, and molecular genetic study of 167 cases, *Am. J. Surg. Pathol.* 27 (5) (2003) 625.
- [3] T. Guzel, K. Mech, M. Mazurkiewicz, B. Dabrowski, G. Lech, A. Chaber, et al., A very rare case of a small bowel leiomyosarcoma leading to ileocecal intussusception treated with a laparoscopic resection: a case report and literature review, *World J. Surg. Oncol.* 14 (2016) 48.
- [4] E. Masaya, T. Shingo, K. Eiko, N. Yuichi, K. Kenji, T. Akihiko, A case of leiomyosarcoma of the small intestine with high Ki-67 repeated early recurrence after surgery, *Nihon Rinsho Geka Gakkai Zasshi* 80 (12) (2019) 2207–2212.

- [5] R.A. Agha, T. Franchi, C. Sohrabi, G. Mathew, for the SCARE Group, The SCARE 2020 guideline: updating consensus surgical Case Report(SCARE) guidelines, *Int. J. Surg.* 84 (2020) 226–230.
- [6] H. Seiichi, I. Koji, M. Yasuhiro, H. Koji, N. Toshirou, I. Shingo, et al., Gain-of-function mutations of c-kit in human gastrointestinal stromal tumors, *Science* 279 (5350) (1998) 577–580.
- [7] M. Kazuo, H. Osamu, K. Yasuharu, T. Yoshihiro, K. Yoshiro, M. Hirotaka, et al., Clinicopathological analysis of leiomyosarcomas of the small intestine and a review of the Japanese literature, *Gan No Rinsho* 36 (11) (1990) 2079–2085.
- [8] S. Baris, V.O. Omer, P.D. Arife, K. Bahadir, H. Ozge, C. Faruk, Perforated intestinal leiomyosarcoma as a metastasis of uterine leiomyosarcoma: a case report, *Cases J.* 2 (2009) 9288.
- [9] L. Hilal, K. Barada, D. Mukherji, S. Temraz, A. Shamseddine, Gastrointestinal leiomyosarcoma case series and review on diagnosis, management, and prognosis, *Med. Oncol.* 33 (2) (2016) 20.

Open Access

This article is published Open Access at [sciencedirect.com](https://www.sciencedirect.com). It is distributed under the [IJSCR Supplemental terms and conditions](#), which permits unrestricted non commercial use, distribution, and reproduction in any medium, provided the original authors and source are credited.