



Surgical technique

Removing a well-fixed femoral sleeve during revision total knee arthroplasty

J. Ryan Martin, MD^{*}, Tyler S. Watters, MD, Daniel L. Levy, BS, Jason M. Jennings, MD, Douglas A. Dennis, MD

Colorado Joint Replacement, Denver, CO, USA

ARTICLE INFO

Article history:

Received 4 May 2016

Received in revised form

26 May 2016

Accepted 26 May 2016

Available online 2 July 2016

Keywords:

Revision total knee arthroplasty

Femoral sleeve

Infection

Removal techniques

ABSTRACT

The following surgical technique describes a case of a 51-year-old man with severe juvenile rheumatoid arthritis that required a 2-stage revision of an infected revision total knee implant. The patient had previously been implanted with a revision rotating platform, constrained condylar device which gained excellent fixation through the use of diaphyseal-engaging stems, and a well-ingrown, fully porous-coated femoral metaphyseal sleeve. To avoid intraoperative complications while removing the femoral sleeve, a novel technique for femoral sleeve extraction was used. Using this technique, the femoral sleeve was successfully removed without intraoperative fracture or substantial bone loss.

© 2016 The Authors. Published by Elsevier Inc. on behalf of The American Association of Hip and Knee Surgeons. This is an open access article under the CC BY-NC-ND license (<http://creativecommons.org/licenses/by-nc-nd/4.0/>).

Introduction

Removal of well-fixed implants during revision total knee arthroplasty (TKA) can be challenging and associated with complications such as periprosthetic fracture and substantial bone loss [1–3]. Numerous techniques have been described to facilitate safe removal of well-fixed implants [4,5]. During revision surgery, the epiphyseal bone is often damaged or absent, requiring the need to obtain further fixation in the metaphysis and diaphysis [6]. This can be accomplished by using modular metaphyseal sleeves or cones and cemented or uncemented stems [7–9]. These additional implant fixation devices have significantly reduced failure rates of revision TKA due to prosthetic loosening [7,10,11] but unfortunately may be very difficult to remove at the time of revision surgery since the surgeon has limited access to intramedullary metaphyseal fixation. To date, we are unaware of any formal technique for removing a fully porous-coated femoral metaphyseal sleeve which

has excellent osseous ingrowth in the setting of an infected revision TKA. The following surgical technique was developed to provide a strategy of safely and effectively removing a well-fixed femoral metaphyseal sleeve while preserving bone stock and avoiding intraoperative fracture.

Surgical technique

Case example

A 51-year-old man with a long-standing history of juvenile rheumatoid arthritis was revised with a constrained rotating platform device which also incorporated diaphyseal-engaging stems and a fully porous-coated femoral metaphyseal sleeve (PFC Sigma Rotating Platform Total Condylar 3; Depuy, Inc., Warsaw, IN) secondary to instability. Excellent fixation was obtained, and the patient functioned well for the first 2 postoperative years. Thereafter, he developed progressive, recurrent instability including a dislocation which was treated at an out-of-state medical center with 2 additional revision operative procedures for liner exchange to a thicker polyethylene insert. Unfortunately, his knee became infected with methicillin-resistant *Staphylococcus epidermidis* which was treated with serial debridements, 6 weeks of parenteral vancomycin, and subsequent oral minocycline for suppression. This failed to control the infection and instability persisted resulting in the plan of a 2-stage revision TKA to attempt to eradicate the

One or more of the authors of this paper have disclosed potential or pertinent conflicts of interest, which may include receipt of payment, either direct or indirect, institutional support, or association with an entity in the biomedical field which may be perceived to have potential conflict of interest with this work. For full disclosure statements refer to <http://dx.doi.org/10.1016/j.artd.2016.05.005>.

^{*} Corresponding author. 2535 S. Downing St., Denver, CO 80209, USA. Tel.: 574-361-8647.

E-mail address: johrmart@gmail.com

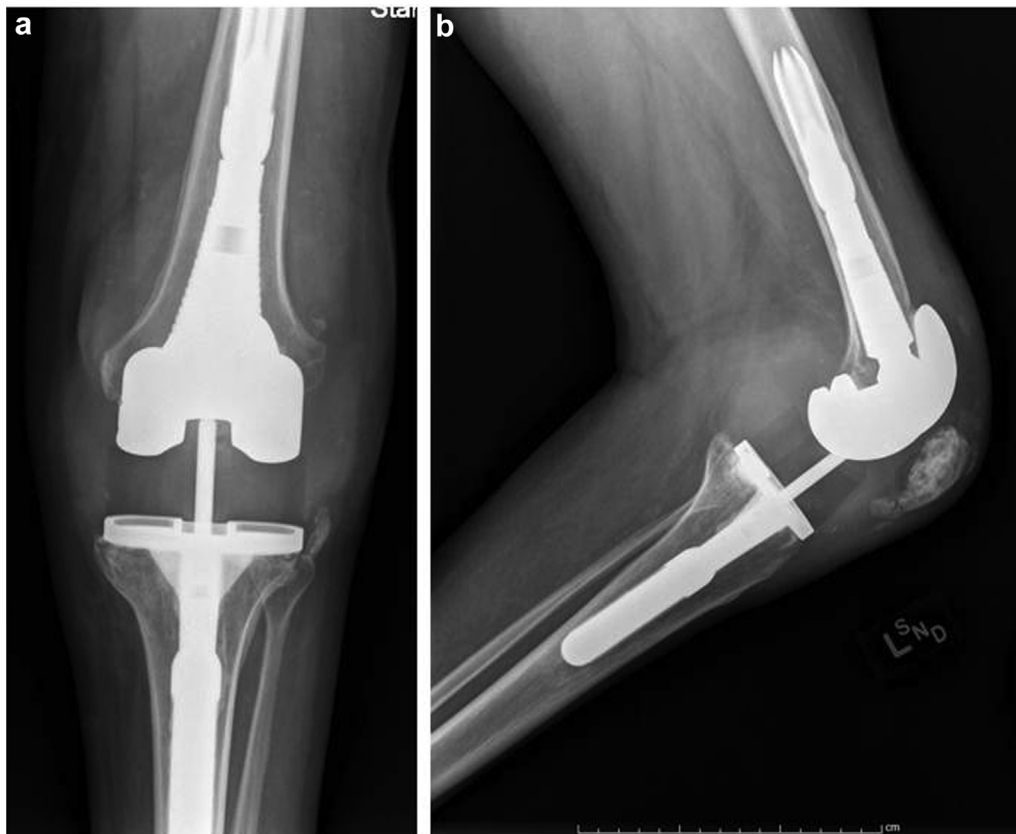

Figure 1. Preoperative anteroposterior (AP) (a) and lateral (b) radiographs demonstrating well-fixed implants with good bonding to the porous-coated femoral metaphyseal sleeve.

infection with eventual replantation of a hinged prosthesis. Radiographs at this point suggested maintenance of fixation with excellent osseous ingrowth of the femoral metaphyseal sleeve (Fig. 1). A detailed discussion with the patient preoperatively was completed to educate him on the potential risks of removing a well-fixed femoral sleeve, specifically addressing the possibility of intraoperative fracture.

Surgical technique

Before proceeding with the operative procedure, the surgeon must be familiar with the various modular connections that exist in this implant design (Fig. 2). Using a midline medial parapatellar approach, the patient's left knee was exposed. A thorough debridement of infected soft tissues was performed. The femoral and the tibial components were assessed for stability, and both were found to be well fixed. Focus was then shifted to removal of the femoral component. The first step in removal of a well-fixed femoral sleeve is to disrupt the femoral component–cement interface with a mini oscillating saw and a series of thin osteotomes. Next, the condylar portion of the femoral component must be disengaged from the femoral adapter bolt which attaches the femoral component to the femoral adapter (which connects to the femoral sleeve via a Morse Taper). This step enables access to the femoral sleeve–bone fixation interface. This was achieved by using a carbide drill bit(s) to debulk the head of the femoral adapter bolt (Fig. 3a and b). The femoral adapter bolt head diameter must be reduced to a lesser diameter than the width of the hole in the intercondylar box of the femoral component to enable the femoral component to be completely disengaged and removed from the metaphyseal sleeve. It is imperative to cover the adjacent soft

tissues when the carbide drill is used to prevent access of third-body metallic debris into the wound (Fig. 4a and b).

After removal of the condylar portion of the femoral component, the femoral sleeve will be visible and the bone–sleeve interface can be easily accessed. The femoral adapter bolt was then unscrewed and removed from the femoral adapter. The femoral adapter was then disimpacted from the metaphyseal sleeve and removed (the Morse Taper must be broken to remove). Using a high-speed pencil-tipped drill, the distal aspect of the sleeve–bone interface was interrupted. A straight 0.25-inch osteotome was then passed circumferentially around the sleeve to further disrupt the sleeve–bone interface, particularly at the proximal aspect of the sleeve (Fig. 5a and b). After the femoral adapter is removed, the threads on the femoral sleeve will now be visible. Finally, an HP Extraction Stem Trial Extractor Adapter (Part # 2011-03-047, DePuy, Inc., Warsaw, IN) was threaded into the sleeve. A Small Slap Hammer (Part # 2709-04-002, DePuy, Inc., Warsaw, IN) was then attached to the threaded extraction adapter, and the sleeve was removed by applying multiple disimpaction forces (Fig. 6a-c). The femoral component was easily removed while retaining femoral bone stock and avoiding intraoperative fracture (Fig. 7). The tibial and patellar components were subsequently removed. The entire surgical site was irrigated with 9 L of antibiotic-containing irrigant solution. Finally, an antibiotic-impregnated static cement spacer was inserted, and the patient's incision was closed.

Discussion

Removal of well-fixed implants at the time of revision TKA surgery can be challenging and associated with intraoperative

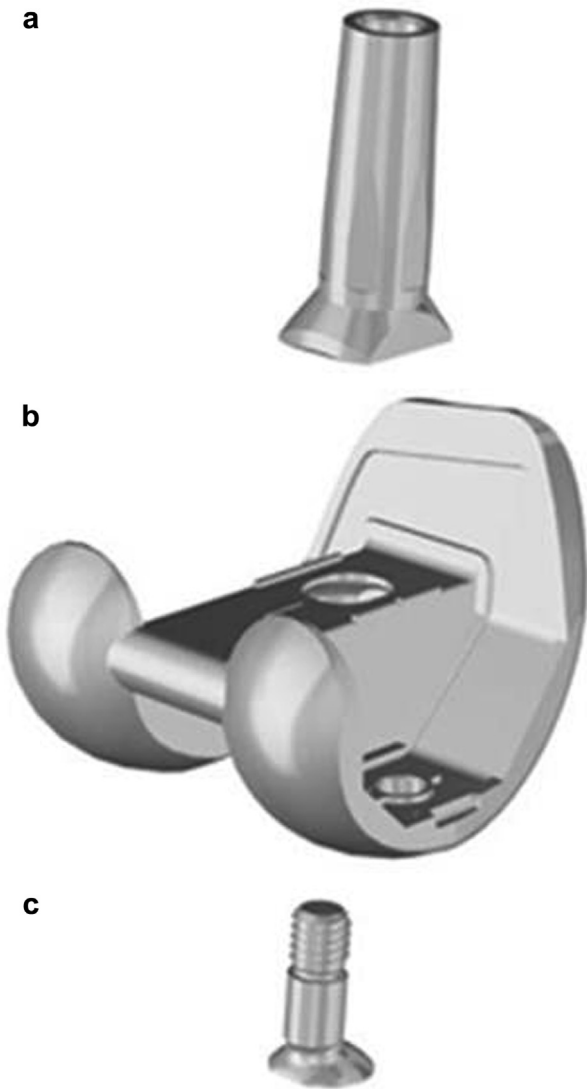


Figure 2. Photograph demonstrating the various modular components and connections of the current femoral component; (a) the femoral adapter (which connects to the sleeve via a Morse Taper), (b) the femoral component, and (c) the femoral adapter bolt.

complications [1–3]. Revision implants can be more challenging to remove than primary devices since implant fixation often extends into the metaphysis and diaphysis [10]. Fixation extending into these regions creates increased difficulties in component removal since surgeon access to the fixation interface is limited without using techniques that increase the risk of bone destruction. Metaphyseal fixation can be achieved with the use of metaphyseal sleeves or cones [12]. These implants increase the surface area of implant fixation and therefore improve implant stability but require advanced techniques of implant removal should it become necessary.

We are unaware of any detailed technique that describes the removal of a stable, porous-coated femoral metaphyseal sleeve in the setting of revision TKA. Removal of a stable femoral sleeve poses a unique challenge to safe extraction because the sleeve–bone interface is obscured by the condylar portion of the femoral component. Therefore the femoral component must be initially removed to gain access to the sleeve–bone interface. Removal of the femoral component requires 2 phases. Phase 1 entails disrupting the condylar femoral component fixation interface. This can be accomplished as previously described in the surgical technique utilizing a thin saw and osteotome to disrupt the fixation interface. Phase 2 requires separating the condylar aspect of the femoral component from the femoral sleeve. The femoral component is connected to the sleeve through the femoral adapter which is press fit to the femoral sleeve via a Morse Taper. The femoral adapter is connected to the femoral component by the femoral adapter bolt placed through the intercondylar box into the femoral adapter (Fig. 2). Therefore, the femoral component and the sleeve can be separated by breaking the taper between the femoral adapter and the sleeve or by disrupting the connection between the femoral adapter and the intercondylar box.

Disengaging the taper between the femoral adapter and the sleeve is difficult. The taper is not visible and is therefore not accessible without removing femoral bone. In addition, the amount of force required to break the taper to the femoral component could potentially increase the risk of fracture. Therefore, to limit the risk of intraoperative fracture, this technique focused on reducing the dimension of the head of the femoral adapter bolt that connects the femoral component and femoral adapter by using a carbide drill. As soon as the diameter of the head of the femoral adapter bolt is reduced to a dimension less than that of the hole in the

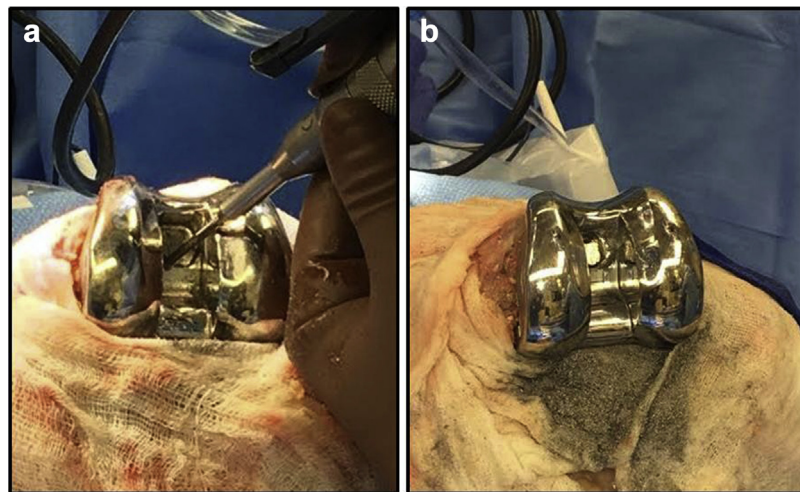


Figure 3. Intraoperative photograph demonstrating the use of a carbide drill to reduce the head diameter of the femoral adapter bolt (a). The soft tissues are completely covered to lessen passage of metal debris particulate into the wound (b).

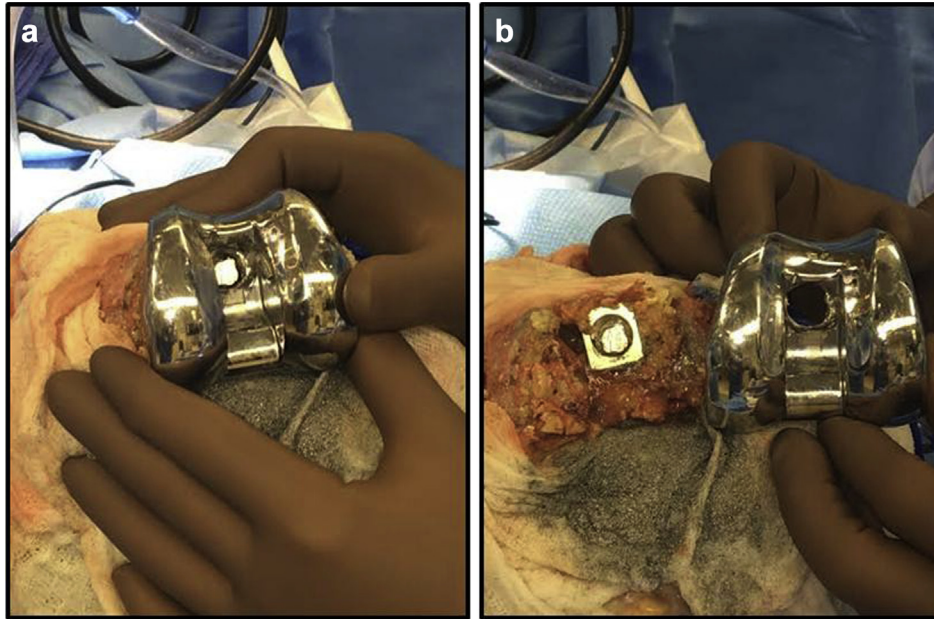


Figure 4. Intraoperative photographs demonstrating removal of the femoral component from the distal femur (a and b).

intercondylar box, the femoral component can be gently removed without requiring excessive disimpaction forces. One potential downside of this technique is creation of metallic debris generated by the carbide burr on the femoral adapter bolt. To contain and limit the amount of metallic debris, wet lap sponges were placed around the operative area and sterile ultrasonic gel was applied circumferentially around the screw head to trap the particles. After the burring was completed, the metallic debris trapped in the gel

was discarded through the suction, the lap sponges were removed from the operative field, and the entire surgical site was thoroughly irrigated with sterile saline.

In the following surgical technique, a femoral sleeve was successfully removed from our patient without any intraoperative complication. However, there are several limitations to this surgical technique. First, all femoral sleeves are different, and there may be subtle nuances to each system. However, the salient point of this

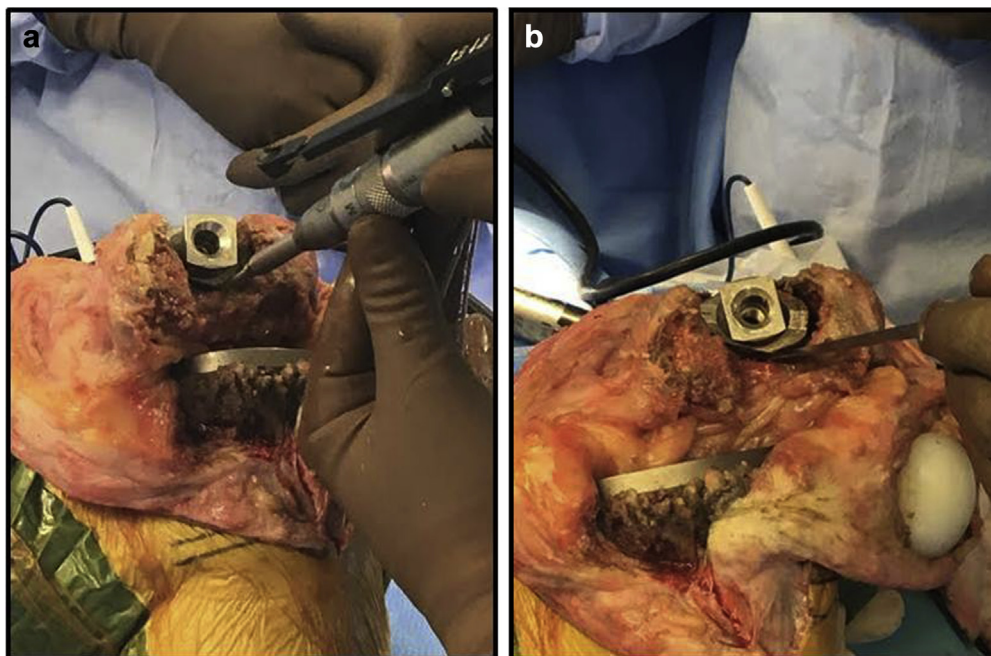


Figure 5. Intraoperative photographs demonstrating disruption of the fixation interface of the metaphyseal sleeve, initially with a high-speed pencil tip drill (a) and completed with a straight 0.25-inch osteotome (b).

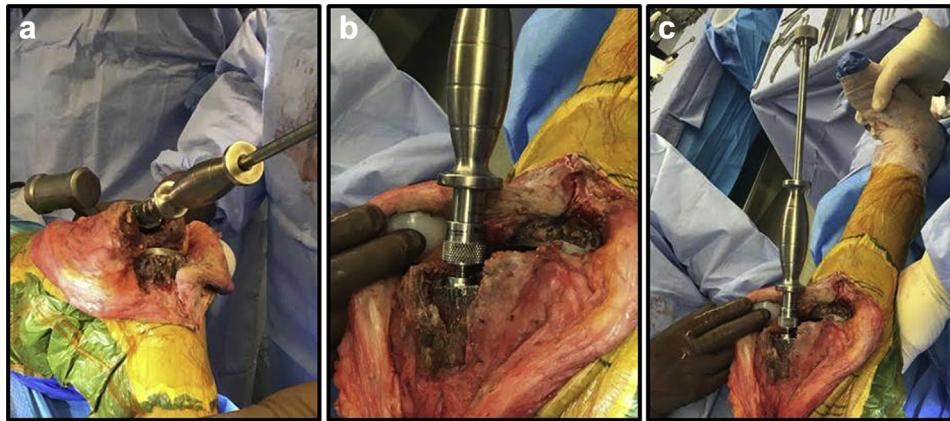


Figure 6. Intraoperative photographs demonstrating attachment of the HP Extraction Stem Trial Extractor Adapter and Small Slap Hammer to the femoral sleeve to allow for sleeve removal (a-c).

technique involves separating the femoral component from the femoral sleeve to visualize the sleeve–bone interface for safe sleeve extraction, which appears to be generalizable to most systems. In addition, there may be other methods than the one described to achieve safe removal of well-fixed femoral sleeves. Second, this technique includes only 1 patient, and it is possible that subsequent procedures could result in an intraoperative fracture or excessive removal of bone if patience is not displayed to ensure the fixation interface is completely disrupted before sleeve removal. Finally, this technique is not applicable to metaphyseal cones. Metaphyseal cones pose a different set of challenges because the cone is “united”

with the femoral component and stem by cement rather than a taper. Therefore, metaphyseal cones likely require alternative methods of removal.

Summary

The following surgical technique provides a method for removing a well-fixed TKA implant with a fully porous-coated femoral sleeve. The procedure involves disrupting the connection between the femoral component and the femoral sleeve. By removing the condylar aspect of the femoral component, the femoral sleeve–bone interface is easily accessible. After disrupting the femoral sleeve–bone interface, the implant can be safely extracted. However, caution should still be used on these complex cases, as intraoperative fracture remains a major concern with removal of this type of revision implant.

References

- [1] Mason JB, Fehring TK. Removing well-fixed total knee arthroplasty implants. *Clin Orthop Relat Res* 2006;446:76.
- [2] Masri BA, Mitchell PA, Duncan CP. Removal of solidly fixed implants during revision hip and knee arthroplasty. *J Am Acad Orthop Surg* 2005;13(1):18.
- [3] Klein GR, Levine HB, Hartzband MA. Removal of a well-fixed trabecular metal monoblock tibial component. *J Arthroplasty* 2008;23(4):619.
- [4] Jacofsky DJ, Della Valle CJ, Meneghini RM, Sporer SM, Cerceke RM. Revision total knee arthroplasty: what the practicing orthopaedic surgeon needs to know. *Instr Course Lect* 2011;60:269.
- [5] Sun Z, Patil A, Song EK, Kim H-T, Seon J-K. Comparison of quadriceps snip and tibial tubercle osteotomy in revision for infected total knee arthroplasty. *Int Orthop* 2015;39(5):879.
- [6] Lombardi AV, Berend KR, Adams JB. Management of bone loss in revision TKA: it's a changing world. *Orthopedics* 2010;33(9):662.
- [7] Huang R, Barrazaeta G, Ong A, et al. Revision total knee arthroplasty using metaphyseal sleeves at short-term follow-up. *Orthopedics* 2014;37(9):e804.
- [8] Bugler KE, Maheshwari R, Ahmed I, Brenkel IJ, Walmsley PJ. Metaphyseal sleeves for revision total knee arthroplasty: good short-term outcomes. *J Arthroplasty* 2015;30(11):1990.
- [9] Graichen H, Scior W, Strauch M. Direct, cementless, metaphyseal fixation in knee revision arthroplasty with sleeves-short-term results. *J Arthroplasty* 2015;30(12):2256.
- [10] Meneghini RM, Lewallen DG, Hanssen AD. Use of porous tantalum metaphyseal cones for severe tibial bone loss during revision total knee replacement. *J Bone Joint Surg Am* 2008;90(1):78.
- [11] Barnett SL, Mayer RR, Gondusky JS, et al. Use of stepped porous titanium metaphyseal sleeves for tibial defects in revision total knee arthroplasty: short term results. *J Arthroplasty* 2014;29(6):1219.
- [12] Howard JL, Kudera J, Lewallen DG, Hanssen AD. Early results of the use of tantalum femoral cones for revision total knee arthroplasty. *J Bone Joint Surg Am* 2011;93(5):478.

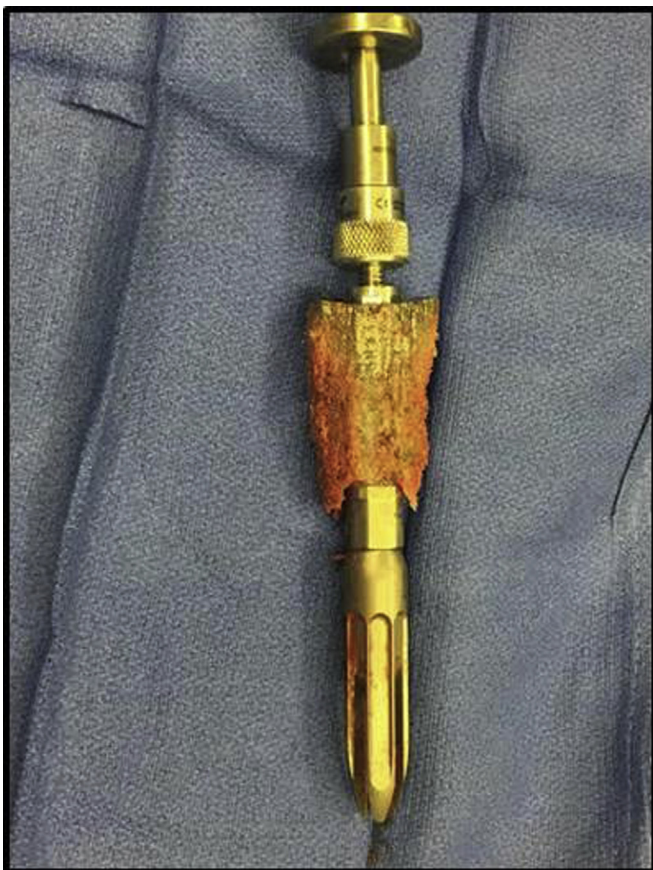

Figure 7. Photograph of the femoral metaphyseal sleeve after removal.