

# Successful treatment of locally advanced urachal adenocarcinoma with peri-operative gemcitabine – cisplatin combination therapy: a case report and perspective on targeted therapies

Ioannis A. Voutsadakis

*Algoma District Cancer Program, Sault Area Hospital, Sault Ste. Marie, Ontario, Canada, and Section of Internal Medicine, Division of Clinical Sciences, Northern Ontario School of Medicine, Sudbury, Ontario, Canada*

**Citation:** Voutsadakis IA. Successful treatment of locally advanced urachal adenocarcinoma with peri-operative gemcitabine – cisplatin combination therapy: a case report and perspective on targeted therapies. *Cent European J Urol.* 2020; 73: 476-481.

## Article history

Submitted: June 15, 2020

Accepted: Nov. 5, 2020

Published online: Nov. 20, 2020

## Corresponding author

Ioannis A. Voutsadakis  
Algoma District  
Cancer Program  
Sault Area Hospital  
750 Great Northern Road  
Sault Ste Marie,  
ON P6B 0A8, Canada  
ivoutsadakis@nosm.ca

Urachal adenocarcinoma is a rare cancer and is treated based on the experience from case series and expert opinion as no randomized studies have been performed. This report adds to the current literature the experience of a patient with locally advanced urachal adenocarcinoma who was treated with combination of neoadjuvant gemcitabine/ cisplatin chemotherapy, surgery and adjuvant chemotherapy and has obtained a long recurrence free survival currently for more than 5 years. Although 5-FU-based chemotherapy is favored by many experts in the treatment of metastatic urachal adenocarcinoma, gemcitabine-based regimens have produced partial responses in metastatic disease and have been used in peri-operative treatment with a manageable adverse effect profile. A brief discussion of molecular lesions in urachal carcinomas and of the emerging role of targeted therapies is included in the current report.

**Key Words:** urachal adenocarcinoma ◊ adjuvant ◊ chemotherapy ◊ recurrence-free survival ◊ gemcitabine ◊ targeted therapies

## INTRODUCTION

Urachal adenocarcinoma is a rare disease arising from the dome of the urinary bladder. It represents only 0.5% of bladder cancers and has a different pathogenesis from the most common transitional carcinoma of the urothelium [1, 2]. The optimal therapy of urachal adenocarcinoma is not as well defined as the common transitional urothelial cancer. Due to lack of higher level evidence, recommendations for urachal carcinoma treatment are based on the experience from case reports and small case series and expert guidelines [2, 3]. The value of adjuvant therapy in urachal carcinoma is also not well-

established. However, it may be considered in cases with higher probabilities of relapse [2]. The optimal regimen remains to be determined.

Recently, case series evaluating the molecular landscape of urachal adenocarcinomas have been published and the most common molecular defects in the disease have been outlined [4, 5]. These reports provide evidence for similarities between urachal and colorectal adenocarcinomas and may pave the way for rational and effective targeted treatments.

Sheldon stage, the most commonly used staging system for urachal adenocarcinoma, classifies patients with disease confined to the mucosa as stage I. Disease invading beyond the mucosa but confined

to the urachus is classified as stage II and disease extending to the bladder, abdominal wall, peritoneum or other visceral organs is classified as stage III. Sheldon stage IV urachal adenocarcinomas are divided in two sub-stages, stage IVA comprises cases with regional lymph node extension and Sheldon stage IVB is disease with distant metastases [1]. The current case study presents a successful combined modality treatment of a Sheldon stage IVA patient with a long-term recurrence-free outcome.

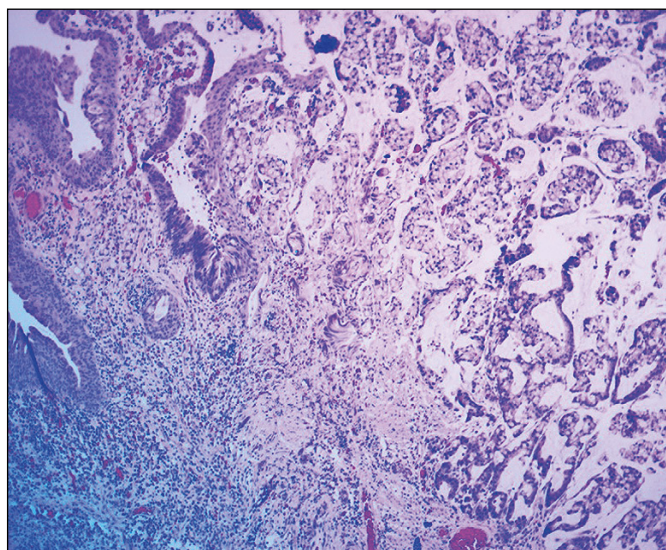
## CASE REPORT

A 49-year old man with history of psoriasis, on methotrexate for 3 years, presented with microscopic hematuria. The patient was asymptomatic otherwise (ECOG Performance status 0). His methotrexate treatment was held and an ultrasound of the abdomen and pelvis showed a urinary bladder mass. Further evaluation with a cystoscopy disclosed a tumor in the dome of the bladder, but no other mucosal abnormalities on inspection. Pathologic evaluation of a biopsy specimen of the tumor was consistent with mucinous adenocarcinoma (Figure 1). Immunohistochemistry (IHC) was positive for cytokeratin 20 (CK20) and CDX2 and negative for CK7 and GATA3. No urothelial carcinoma in situ was observed. Staging with a CT scan of chest abdomen and pelvis showed an exophytic lobulated tumor mass with coarse calcifications in the dome of the bladder extending superiorly. The mass measured 3.6 cm by 2.8 cm by 6.2 cm in diameter (Figure 2A). A right enlarged pelvic lymph node with a diameter of 2 cm was also present (Figure 2B) but no extension of the disease beyond the pelvis was observed. No evidence of any other primary was seen in the CT scans. A colonoscopy was negative. After multidisciplinary consultation and given the local extent of the disease, a decision was made to proceed with neo-adjuvant chemotherapy. The patient received three cycles of gemcitabine 1250 mg/m<sup>2</sup> on day 1 and 8 and cisplatin 75 mg/m<sup>2</sup> of a 21-day cycle which he tolerated well, with only grade 1 fatigue. Six weeks after completion of neo-adjuvant chemotherapy, he underwent a partial cystectomy with en bloc resection of the umbilicus and pelvic lymph node dissection. The surgical approach was suprapubic with dissection of the umbilicus, medial rectus muscle fibers, urachus and mobilization of the bladder circumferentially. The tumor was felt in the dome and dissected with large margins through a suprapubic cystostomy, together with the urachus and umbilicus in one specimen. The lymph node dissection started from the node of Cloquet and carried proximally to the bifurcation of the common iliac vessels. Ex-

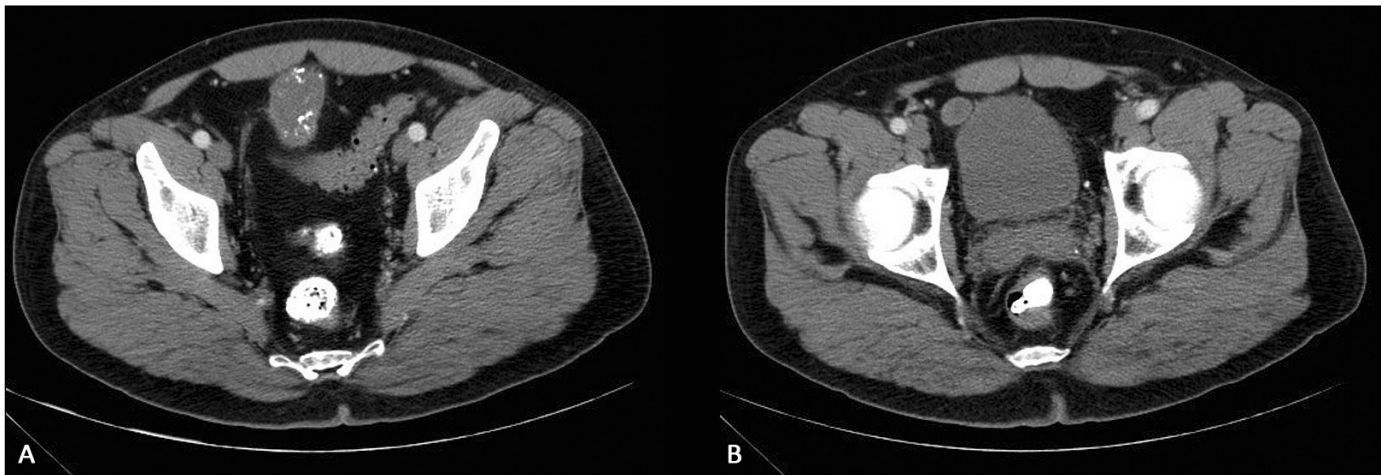
ternal iliac nodes were dissected en bloc with internal iliac nodes and the nodes of the obturator fossa. Surgical pathology disclosed a well-differentiated urachal adenocarcinoma invading perivesical tissue. The enlarged lymph node, measuring still 2 cm in gross pathology, was positive for metastatic adenocarcinoma but 10 additional lymph nodes resected were negative. Thus, the overall TNM stage was ypT3ypN1cM0. Margins of resection were all negative. A post-operative CT scan showed no abnormal findings. Post-operatively the patient received three additional cycles of the same gemcitabine and cisplatin regimen, starting 10 weeks post-operatively, with excellent tolerance. He is followed expectantly since, with cystoscopies and yearly scans and remains free of recurrence more than five years from his diagnosis. He has resumed methotrexate therapy with good control of psoriasis.

## DISCUSSION

Urachal adenocarcinoma is a rare cancer of the urinary bladder arising from the dome and is believed to be associated with embryonic remnants of the allantois which becomes the urachal ligament. The urachal ligament is a fibromuscular band that extends from the dome of the bladder to the umbilicus in adults after the allantois lumen collapses. In up to a third of the population, remnants of the lumen persist as a cyst communicating with the anterosuperior bladder wall in the middle line [6]. Urachal carcinomas arise from these embryonic remnants. However malignant transformation is rare and no prophylactic treatment is advocated [7]. Criteria for diagnosis



**Figure 1.** Pathologic microphotograph of the biopsy of the tumor. On the left, transition to normal epithelium is seen.



**Figure 2.** Computed tomography scan at the level of the tumor (A) and at the level of the right pelvic lymph node (B).

of urachal adenocarcinomas have been established and include a midline location of the tumor, clear demarcation from the surrounding urothelial epithelium and absence of urothelial dysplasia or cystitis cystica or glandularis histologically [2]. The histology of the carcinoma should resemble enteric-type and other primaries should also be excluded before an urachal primary is diagnosed [2]. All these criteria were fulfilled in the presented case.

The most commonly used staging system for urachal adenocarcinoma is that according to Sheldon where direct extension to bladder, abdominal wall, peritoneum or other viscera is classified as stage III disease, while regional lymph node metastases are classified as stage IVA disease and distant metastases are classified as stage IVB disease [8]. Prognosis depends on the Sheldon stage and 5 year cancer specific survival varies from 63% in stage I to 19% and 8% in stage III and IV respectively. An alternative staging system proposed by investigators in the Mayo clinic classifies locally extensive disease as stage II and regional lymph node infiltration as stage III disease [9]. The Mayo staging system was equally effective with the Sheldon classification in predicting outcomes and simpler. The classic TNM staging system is also used and has been found to predict mortality rate [10].

Disease recurrence is more common with advancing local stage [11]. The outcomes of locally advanced disease are poor and long-term survival of patients with lymph node positive disease remains as low as about 20% at 5 years [9]. The value of adjuvant treatment for locally advanced disease is not well-described due to the rarity of this cancer that precludes performance of randomized trials even under the auspices of collaborative groups [8]. As there is a paucity of randomized data on adjuvant therapy in urachal cancer, the indication for offering (neo)-adju-

vant chemotherapy in these circumstances is based only on expert opinion and consensus.

This report presents a case of a patient with locally extensive Sheldon IVA disease with pelvic lymphadenopathy successfully treated with a combination of neo-adjuvant chemotherapy followed by surgery and adjuvant chemotherapy. Partial cystectomy has been proposed as an alternative to radical cystectomy and has been used successfully in the current case. In a series of 66 patients, 46 of whom were treated with partial cystectomy, this procedure was found to produce similar cancer-specific survival outcomes with radical cystectomy [9]. In contrast, patients with positive margins had worse outcomes than counterparts with negative margins. Similarly, patients in whom no umbilectomy was performed had worse cancer-specific survival. Thus, it appears from the available data that partial cystectomy could be a preferred alternative to radical cystectomy for urachal carcinomas, as long as negative margins are obtained and en bloc resection of the umbilicus is performed. Regarding lymph node dissection in urachal carcinomas, there is no formal demonstration of survival benefit [8, 9]. However, it is noted that in the absence of randomized data and given the small number of patients in the studies available, such a benefit may exist. The adverse prognostic implications of positive lymph nodes in urachal carcinoma may add value in performing a lymph node dissection for improving prognostication and guiding therapeutic decisions [8].

Neo-adjuvant chemotherapy is not indicated for node negative disease but it has been suggested to be worth considering in node positive disease [2]. The choice of chemotherapy in the described case was based on previous case reports of the use of the combination of gemcitabine and cisplatin in this disease

**Table 1.** Studies of molecular abnormalities in urachal adenocarcinoma

Study	Number of patients	KRAS	NRAS	BRAF	PI3CA	GNAS	NF1	SMAD4	TP53	MSI
Reis et al. [5]	70	15	1	3	3	NA	NA	NA	46	0/61
Módos et al. [4]	22	6	1	4	0	NA	NA	NA	NA	NA
Cornejo et al. [21]	32	15	1	1	0	4	NA	3	18	NA
Sirintrapun et al. [22]	7	3	NA	0	NA	NA	NA	NA	NA	3
Singh et al. [23]	7	1	NA	NA	NA	NA	3	2	4	NA
Riva et al. [28]	7	4	0	0	1	NA	NA	NA	NA	NA
Loh et al. [24]	2	1	0	0	0	1	0	0	2	NA
Total	147	45/147	3/133	8/140	4/133	5/34	3/9	5/41	70/111	3/64

NA – not available; MSI – microsatellite instability

as well as the experience of the feasibility of this regimen in the neo-adjuvant setting before cystectomy for urothelial cancers [12]. Other regimens that have been used for urachal carcinoma in the metastatic setting and could be used peri-operatively include MVAC (methotrexate, vinblastine, Adriamycin and cisplatin), CMV (cisplatin methotrexate and cisplatin), Gem-FLP (gemcitabine, 5-FU, leucovorin and cisplatin), FOLFIRI (5-FU, leucovorin and irinotecan) and FOLFOX (5-FU, leucovorin and oxaliplatin) [13–16]. This last regimen is suggested as the preferred choice in a recently published Canadian guideline based on the similarities of urachal adenocarcinomas with those of colonic origin [3]. Due to the anecdotal nature of these experiences a more definitive advice on the most efficacious regimen cannot be based in higher degree evidence. However based on our experience and that of others [17–20], gemcitabine and cisplatin-based regimens remain a viable option, although 5-FU-based regimens seem to be at least equally effective.

Further progress on treatment of urachal adenocarcinomas may be derived from the molecular characterization of the disease that has disclosed common molecular lesions in the EGFR/ KRAS/ BRAF/ MAPK pathway (Table 1). One study of 70 urachal cancers examined by targeted next generation sequencing (NGS) disclosed KRAS mutations in 21% of cases, NRAS mutations in 1%, BRAF mutations in 4% and PIK3CA mutations in 4% of cases [5]. In addition, amplifications of EGFR and ERBB2 were discovered in 5% and 2% of samples respectively. Another study of 22 urachal carcinomas examined 5 genes of the pathway by pyrosequencing and found KRAS mutations in 6 patients (27%), BRAF mutations in 4 patients (18%) and NRAS mutations in 1 patient (5%) but no mutations in EGFR or PIK3CA genes in any of the samples [4]. A third study included 32 urachal adenocarcinomas and examined them by targeted NGS in a platform of 50 genes [21]. KRAS was mu-

tated in 15 cases and an additional case had NRAS mutation. Two additional genes of the pathway that were found to be mutated were GNAS in 4 cases and BRAF in one case. Another report found KRAS mutations in 3 of 7 urachal carcinoma patients but no mutations in BRAF [22]. A series of 7 patients showed a KRAS mutation in one and NF1 mutations in 3 patients, including the one that had KRAS mutation [23]. Interestingly 3 of the 7 cases in this study had amplifications of the 12p chromosome, a lesion commonly seen in germ cell tumors. A case report of 2 patients found a KRAS mutation in one of them who also had a GNAS mutation [24]. The other patient had mutation of the MAP2K1 kinase which functions downstream of KRAS/ BRAF as well as amplification of the receptor tyrosine kinase FLT3. Two of the above studies examined TP53 and found mutations in 56% and 66% of specimens [5, 21]. Two studies examined mismatch repair (MMR) proteins (MSH2, MSH6, MLH1 and PMS2) by immunohistochemistry (IHC) with differing results. In the one three of seven patients had loss of expression of one or more of these proteins suggesting microsatellite instability while in the other study none of 70 patients had loss of MMR proteins expression [5, 22]. Currently there are sparse reports of targeted treatments based on molecular lesions in urachal carcinomas. A patient with KRAS and GNAS mutations treated with the MEK inhibitor trametinib was not evaluable for response to therapy due to early discontinuation of therapy for intolerance [24]. A second patient in the same report who had a MAP2K1 mutated and FLT3-amplified tumor obtained a 10 month stability of her disease with trametinib after a trial of sorafenib that she could not tolerate because of a cutaneous rash. Another report of a patient with urachal carcinoma treated empirically, without molecular characterization, with sunitinib showed stability of disease for 3 months [25]. Lastly, another patient with metastatic urachal adenocarcinoma

in a genetic background of BRCA1 deletion was treated with the PARP inhibitor rucaparib and obtained a complete response [26].

In conclusion, the current report describes a successful combination therapy for locally advanced urachal adenocarcinoma. Neo-adjuvant chemotherapy has only rarely been described in this disease previously and it may be worth of further investigation in lymph node positive disease. The role of targeted treatments for localized and metastatic disease is an area carrying significant promise for improving outcomes. A way to circumvent the practical difficulties encountered for performing clinical trials in orphan cancers could be with the use of a basket design which would include genetically characterized cancers irrespective of primary origin. In these trials urachal cancers with mutations in KRAS, BRAF or other characterized lesions would be included together with cancers of other origins but with the same molecular lesions and treated with inhibitors of these lesions. Given the common occurrence of EGFR/ KRAS/ BRAF/ MAPK pathway lesions in urachal adenocarcinoma, inhibitors of the pathway may be of particular interest for development as therapies of the disease [21–24, 28]. However, in view of the experience in colorectal adenocarcinomas, which commonly harbor mutations

in the same pathway, combination treatment with targeted drugs of multiple nodes in the pathway may be more effective than monotherapies. Concomitant inhibition of several proteins of the pathway has been found to be effective in colorectal cancer by prevention of development of feed-forward loops that bypass single inhibition. This is exemplified by the recent results of the triple combination therapy comprised by the EGFR inhibitor cetuximab, BRAF inhibitor encorafenib and MAPK inhibitor binimetinib in metastatic colorectal cancer with V600E BRAF mutations [27]. This study showed an improvement of overall survival (OS) with the triple targeted therapy compared with standard chemotherapy. Thus similar combination treatments could be the preferred candidates for development in urachal adenocarcinoma.

#### STATEMENT OF ETHICS

Written informed consent has been obtained by the patient to publish this case.

#### DISCLOSURE STATEMENT

The author has no conflicts of interest to declare.

#### FUNDING SOURCES

No external funding has been received to perform this case study.

## References

- Paner GP, Lopez-Beltran A, Sirohi D, Amin MB. Updates in the pathologic diagnosis and classification of epithelial neoplasms of urachal origin. *Adv Anat Pathol*. 2016; 23: 71-83.
- Siefker-Radtke A. Urachal adenocarcinoma: A clinician's guide for treatment. *Semin Oncol*. 2012; 39: 619-624.
- Hamilou Z, North S, Canil C, et al. Management of urachal cancer: A review by the Canadian Urological Association and Genitourinary Medical Oncologists of Canada. *Can Urol Assoc J*. 2020; 14: E57-64.
- Módos O, Reis H, Niedworok C, et al. Mutations of KRAS, NRAS, BRAF, EGFR, and PIK3CA genes in urachal carcinoma: Occurrence and prognostic significance. *Oncotarget*. 2016; 7: 39293-39301.
- Reis H, van der Vos KE, Niedworok C, et al. Pathogenic and targetable genetic alterations in 70 urachal adenocarcinomas. *Int J Cancer*. 2018; 143: 1764-1773.
- Schubert GE, Pavkovic MB, Bethke-Bedurftig BA. Tubular urachal remnants in adult bladders. *J Urol*. 1982; 127: 40-42.
- Gleason JM, Bowlin PR, Bagli DJ, et al. A comprehensive review of pediatric urachal anomalies and predictive analysis for adult urachal adenocarcinoma. *J Urol*. 2015; 193: 632-636.
- Szarvas T, Módos O, Niedworok C, et al. Clinical, prognostic, and therapeutic aspects of urachal carcinoma—A comprehensive review with meta-analysis of 1,010 cases. *Urol Oncol*. 2016; 34: 388-398.
- Ashley RA, Inman BA, Sebo TJ, et al. Urachal carcinoma: clinicopathologic features and long-term outcomes of an aggressive malignancy. *Cancer*. 2006; 107: 712-720.
- Dhillon J, Liang Y, Kamat AM, et al. Urachal carcinoma: a pathologic and clinical study of 46 cases. *Hum Pathol*. 2015; 46: 1808-1814.
- Herr HW, Bochner BH, Sharp D, Dalbagni G, Reutern VE. Urachal carcinoma: Contemporary surgical outcomes. 2007; 178: 74-78.
- Dash A, Pettus JA 4th, Herr HW, et al. A role for neoadjuvant gemcitabine plus cisplatin in muscle-invasive urothelial carcinoma of the bladder: a retrospective experience. *Cancer*. 2008; 113: 2471-2477.
- Siefker-Radtke AO, Gee J, Shen Y, et al. Multimodality management of urachal carcinoma: the M.D. Anderson Cancer Center experience. *J Urol*. 2003; 169: 1295-1298.
- Hong JY, Choi MK, Uhm JE, et al. Palliative chemotherapy for non-transitional cell carcinomas of the urothelial tract. *Med Oncol*. 2009; 26: 186-192.
- Yanagihara Y, Tanji N, Miura N, et al. Modified FOLFOX6 chemotherapy in patients with metastatic urachal cancer. *Chemotherapy*. 2013; 59: 402-406.
- Tran B, McKendrick J. Metastatic urachal cancer responding to FOLFOX chemotherapy. *Can J Urol*. 2010; 17: 5120-5123.
- Yaegashi H, Kadomoto S, Naito R, et al. Metastatic urachal cancer treated effectively with gemcitabine/ cisplatin combination chemotherapy and radiotherapy: A case report. *Mol Clin Oncol*. 2019; 11: 139-142.

18. García Alvarez C, González Alvarez RJ, Plata Bello AC, et al. Multimodal therapy in urachal carcinoma with oligometastatic bone disease. *Urol Case Rep.* 2019; 26: 100936.
19. Kim MJ, Kim YS, Oh SY, et al. Retrospective analysis of palliative chemotherapy for the patients with bladder adenocarcinoma: Korean Cancer Study Group Genitourinary and Gynecology Cancer Committee. *Korean J Intern Med.* 2018; 33: 383-390.
20. Yu B, Zhou J, Cai H, et al. Neoadjuvant chemotherapy for primary adenocarcinomas of the urinary bladder: a single-site experience. *BMC Urol.* 2015; 15: 3.
21. Cornejo KM, Cosar EF, Paner GP, et al. Mutational profile using next-generation sequencing may aid in the diagnosis and treatment of urachal adenocarcinoma. *Int J Surg Pathol.* 2020; 28: 51-59.
22. Sirintrapun SJ, Ward M, Woo J, Cimic A. High-stage urachal adenocarcinoma can be associated with microsatellite instability and KRAS mutations. *Hum Pathol.* 2014; 45: 327-330.
23. Singh H, Liu Y, Xiao X, et al. Whole exome sequencing of urachal adenocarcinoma reveals recurrent NF1 mutations. *Oncotarget.* 2016; 7: 29211-29215.
24. Loh KP, Mondo E, Hansen EA, et al. Targeted therapy based on tumor genomic analyses in metastatic urachal carcinoma. *Clin Genitourinary Cancer* 2016; 14: e449-452.
25. Testa I, Verzoni E, Grassi P, Colecchia M, Panzone F, Procopio G. Response to targeted therapy in urachal adenocarcinoma. *Rare Tumors.* 2014; 6: 5529.
26. Seto T, Pujare D, Song M-N, et al. Germline BRCA1 deletion as driver mutation for metastatic urachal adenocarcinoma in patient who achieved complete response to rucaparib. *J Oncol Pract.* 2019; 15: 293-295.
27. Kopetz S, Grothey A, Yaeger R, et al. Encorafenib, Binimetinib, and Cetuximab in BRAF V600E-Mutated Colorectal Cancer. *N Engl J Med.* 2019; 381: 1632-1643.
28. Riva G, Mian C, Luchini C, et al. Urachal carcinoma: from gross specimen to morphologic, immunohistochemical, and molecular analysis. *Virchows Arch.* 2019; 474: 13-20. ■