

Gluteal Black Market Silicone–induced Renal Failure: A Case Report and Literature Review

Andrea Matson, DO, PGY-2
Burt Faibisoff, MD, FRCSC

Summary: Very few cases of successful surgical treatment for renal failure due to gluteal silicone injections have been reported in the literature. The silicone toxicity and subsequent renal failure seem to follow repetitive silicone injections and silicone injections in large quantities. This is a case of a 31-year-old woman who developed renal failure after 6 years of gluteal silicone injections who underwent radical resection of bilateral gluteal regions in an attempt to mitigate her impending complete renal failure. A systematic review of the literature was conducted using PubMed database and with assistance from medical library staff to conduct keyword searches for “Silicone,” “Renal failure,” “Silicone emboli syndrome,” “Silicone granuloma,” and “Silicone end organ toxicity.” The search results were reviewed by the authors and selected based on the relevance to the case report presented. Extensive literature relating to silicone granulomas and their systemic effects supports the use of steroids for immediate treatment and eventual surgical resection for cure of the various silicone-related end-organ toxicities including renal failure. (*Plast Reconstr Surg Glob Open* 2017;5:e1578; doi: 10.1097/GOX.0000000000001578; Published online 20 November 2017.)

Silicone, once thought to be safe for cosmetic use because of its thermal stability, now has been described as a catalyst to end-organ toxicity and multi-organ dysfunction.¹

Silicone was first introduced for cosmetic surgery during the World War II era and was initially thought to be inert with no immediately recognized local or systemic response. It was not until months to years later that side effects such as migration, granuloma formation, embolic phenomena, hypercalcemia, and renal failure became evident.^{2–6} The current literature suggests that likelihood of silicone embolic reactions is in direct correlation with the quantities of silicone injections used. These emboli are met with a stress response by the body and result in direct toxicity to the organs.¹

More research is necessary to identify the pathophysiology of silicone-induced renal failure. There have only been 5 cases reported in the literature of silicone-related renal failure and only one case report of renal failure after gluteal silicone injections.^{2–5} This

is a literature review and case report of a 31-year-old woman with successful surgical therapy for silicone-induced renal failure.

CASE REPORT

This is a 31-year-old white woman who presented with stage 3 kidney disease (estimated glomerular filtration rate 30–59), bilateral gluteal silicone granulomas, hypercalcemia, hypertension, adrenal insufficiency, and elevated blood glucose. She began to notice a gradual decline in her health over a 6-year period while receiving gluteal silicone injections from an unlicensed individual impersonating a medical specialist. A 2-year course of prednisone (Table 1) treatments and vacuum-assisted wound care had failed to improve her left gluteal wound, and her renal function continued to decline. The patient had elevation of renal enzymes suggestive of renal damage. Review of the patient’s condition with her nephrologist leads to the hypothesis that this was due to granuloma formation in the kidneys.

The patient history included a prior attempt at granuloma resection using sharp debridement to remove fat necrosis and retained silicone around 1 site on her left buttock that was left open and draining. This surgical wound never healed, and she was being treated with vacuum-assisted wound closure therapy with the sponge being changed every third day (Table 1).

From the Department of Surgery, Mountain Vista Medical Center, Mesa, Ariz.

Received for publication June 29, 2017; accepted September 29, 2017.

Copyright © 2017 The Authors. Published by Wolters Kluwer Health, Inc. on behalf of The American Society of Plastic Surgeons. This is an open-access article distributed under the terms of the Creative Commons Attribution-Non Commercial-No Derivatives License 4.0 (CCBY-NC-ND), where it is permissible to download and share the work provided it is properly cited. The work cannot be changed in any way or used commercially without permission from the journal.

DOI: 10.1097/GOX.0000000000001578

Disclosure: The authors have no financial interest to declare in relation to the content of this article. The Article Processing Charge was paid for by the authors.

Table 1. A List of Medications the Patient Had Been on for the Past 2 Years

Medications	Dose	Frequency
Amlodipine	5 mg	1/d
Prednisone	2.5 mg	1/d for 2 y
Wellbutrin	200 mg	1/d
Albuterol	2.5 mg	Every 4 h as needed

Physical examination revealed bilateral nodularity in the skin and deep tissues of both buttocks and an open draining wound of the left mid-gluteal region. One culture was taken at our facility during the surgical excision, and it was tested for aerobic and anaerobic organisms. She had no growth on culture results of her chronic left buttock wound with no organisms seen on gram stain (Fig. 1).

She was taken to the operating room and underwent radical excision of silicone granulomas bilaterally with flap advancements and closures (Fig. 2). During her operation, large areas of infiltrating granulomatous material and hyperfirm scarring were evident throughout her tissues extending into her gluteal muscles obscuring normal anatomical planes of dissection. The dissection was taken to the level of the gluteus fascia using the pulsed radiofrequency energy device. The resected skin ellipses were measured at 26 × 11 cm with a total of 2–3 L of tissue and silicone resected (Fig. 3). During the course of the 4-hour procedure, the patient required 2 units of blood, several units of hetastarch in sodium chloride, and 100 mg of albumin and lost an estimated 2.5 L of blood. She was admitted to the intensive care unit and went on to make a full recovery.

Interestingly on 2-month follow-up, her renal function had improved with creatinine at 1.35 mg/dL and blood urea nitrogen of 22 mg/dL, and her hypercalcemia had resolved. As expected, her pathology report showed foreign-body granulomatous reactions with cysts containing a mucous-like clear fluid.

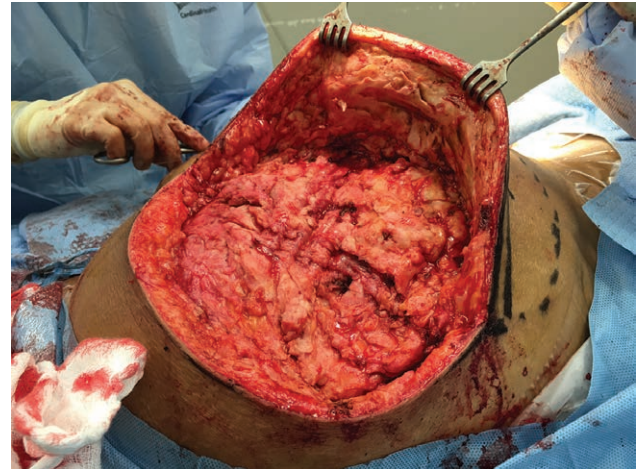


Fig. 2. Right buttock; intraoperative view of removal of silicone-impregnated tissues of the gluteal region.

DISCUSSION

Historically, migration of liquid silicone has been a concern within the plastic surgery specialty, and there are well-documented reports of hepatic and pulmonary embolization.^{7,8} Although no renal biopsy was conducted on our patient, we postulate this as a possible cause of her renal insufficiency.

It has long been known that silicone injection leads to development of a foreign-body reaction in the form of chronic granulomatous inflammation. This reaction starts with active inflammation followed by chronic inflammation taking months to years to mature. Many who present with severe granulomatous reactions develop calcitriol-related hypercalcemia along with renal failure.² Steroids such as dexamethasone have been observed to downregulate synthesis of 1,25 dihydroxy-vitamin D in macrophages, leading to decreased calcium reabsorption. Steroid injections seem to provide a temporary solution.

In addition to local inflammatory reactions described above leading to hypercalcemia and subcutaneous nodular disfigurement, silicone injections in various body regions have the ability to migrate to various organs in the body including

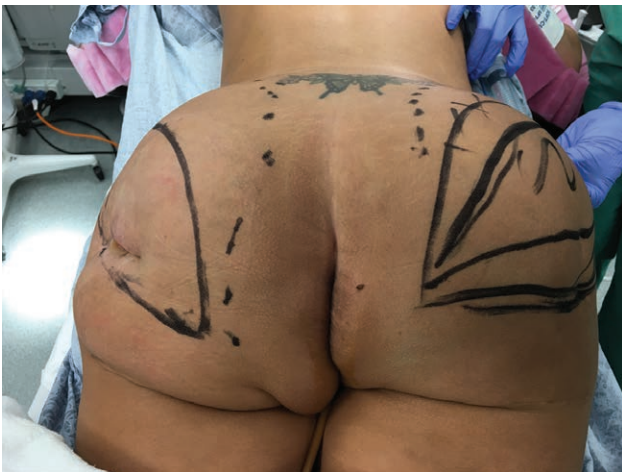

Fig. 1. Preoperative picture before resection. Note bilateral indurated gluteal granulomas and the chronic draining wound on her left buttock.

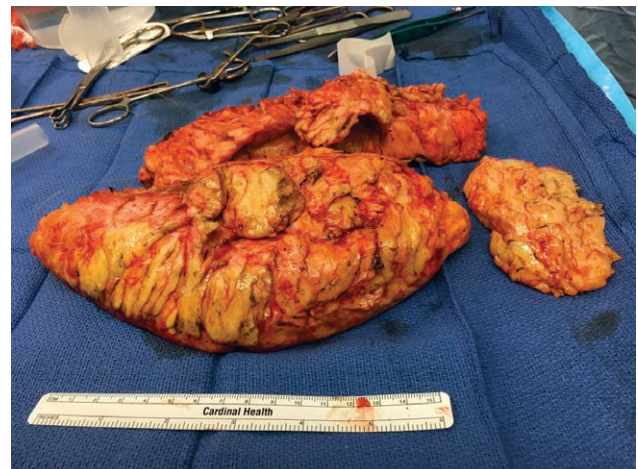

Fig. 3. A total of 2–3 L of tissue were removed from bilateral glutei.

Table 2. A Summary of the Literature Reviewed for This Case Report and Treatment Outcomes

Case Reports	Type(s) of Silicone Exposure	Renal Effects	Method(s) of Treatment	Outcome
Khan and Sim ¹	Silicone injections to bilateral hips	Chronic renal failure a decade later	Low-dose steroids (prednisone 2.5 mg daily)	Responded well, renal indices improved, hypercalcemia resolved
Visnyei et al. ²	Silicone injections for body contouring	Acute kidney injury a decade later	IV hydration, pamidronate, Methylprednisolone	Renal function normalized
Tan et al. ³	Bilateral breast implant with silicone shell	Focal segmental necrotizing and crescentic glomerulonephritis	Pulse dose of methylprednisolone, cyclophosphamide, and plasmapheresis	Good clinical response
Figueres et al. ⁴	Silicone breast implants	Chronic renal failure with IgG <i>k</i> associated with free monoclonal <i>k</i> light chains	This study reported no treatments but highlighted other literature recommending removal of implants resulting in disappearance of monoclonal immunoglobulins	Not reported in this article
Hitoshi et al. ⁵	Augmented mammoplasty with silicone injections directly into bilateral breasts	Severe hypertension (220/160), ANA + renal failure Cr 2.6, BUN 44	ACE-I: enalapril 20 mg/d, nifedipine 60 mg/d, prazosin 1 mg/d	Blood pressure responded and decreased to acceptable levels on day 12
Uretsky et al. ⁹	—	Clinical findings consistent with PSS/scleroderma renal crisis	—	Creatinine declined after day 16 of treatment
D'Ythurbide et al. ¹⁰	Bilateral augmented mammoplasty	Developed peritoneal signs and enlarged kidneys, BUN 62 mg/dL, Cr 2 mg/dL	Both breast implants removed POD 11	Over the next 6 days, renal failure resolved with complete resolution at 7 wk
	Gluteal liquid silicone injections to bilateral glutei	Chronic renal failure (Cr 13.3 mg/dL), massive proteinuria, AA-amyloidosis on biopsy	Authors stated excision of exogenous material was "technically impossible"	After 6 mo, SAA was undetectable but patient still required hemodialysis
	—	—	Interleukin-1 receptor antagonist was used	—

ACE-I, angiotensin-converting enzyme inhibitor; ANA, antinuclear antibody; IV, intravenous; POD, postoperative day; PSS, progressive systemic sclerosis; SAA, serum amyloid A.

the kidneys.⁹ How exactly silicone leads to renal failure seems to be multifactorial. There is some evidence that silicone may cause renal failure by direct toxicity, granulomatous inflammation in tubulointerstitial compartment, monoclonal gammopathy, osmotic nephrosis, microscopic polyangiitis, and focal segmental necrotizing glomerulonephritis.^{2,3}

In our review of the literature, there are only 5 reports of renal failure after silicone injections and 1 report of gluteal injections with very similar presentation to our patient.² Before this case presentation, surgical resection was thought to be technically impossible because of the excessive and infiltrating nature of the disease.^{2,10}

To our knowledge, this is the first instance where surgical treatment in the form of radical excision of gluteal silicone granulomas has been successfully completed to stabilize and restore renal function in a patient with silicone-induced renal failure (Table 2).

It is most likely that the cause of the nephrotoxicity and renal failure was due to direct silicone toxicity as the renal function remained stable and even slightly improved with removal of the offending foreign substance from the body.

Andrea Matson, DO, PGY2

Department of Surgery
Mountain Vista Medical Center
10238 East Hampton Avenue Suite 301C
Mesa, AZ 85209

E-mail: Andrea_Matson@iasishealthcare.com

REFERENCES

1. Khan O, Sim JJ. Silicone-induced granulomas and renal failure. *Dial Transplant*. 2010;39:254–259.
2. Visnyei K, Samuel M, Heacock L, et al. Hypercalcemia in a male-to-female transgender patient after body contouring injections: a case report. *J Med Case Rep*. 2014;71:1–6.
3. Tan J, Spath F, Malhotra R, et al. Microscopic polyangiitis following silicone exposure from breast implantation. *Case Rep Nephrol*. 2014;2014:902089.
4. Figueres ML, Beaume J, Vuiblet V, et al. Crystalline light chain proximal tubulopathy with chronic renal failure and silicone gel breast implants: 1 case report. *Hum Pathol*. 2015;46:165–168.
5. Hitoshi S, Ito Y, Takehara K, et al. A case of malignant hypertension and scleroderma after cosmetic surgery. *Jpn J Med*. 1991;30:97–100.
6. Purdy-Payne EK, Green J, Zenoni S, et al. A serious complication of illicit silicone injections: latent silicone embolization syndrome after incision and drainage of local injection site. *Surg Infect*. 2015;16:473–477.
7. Bartsich S, Wu JK. Silicon emboli syndrome: a sequela of clandestine liquid silicone injections. A case report and review of the literature. *J Plast Reconstr Aesthet Surg*. 2010;63:e1–e3.
8. Ellenbogen R, Rubin L. Injectable fluid silicone therapy. Human morbidity and mortality. *JAMA* 1975;234:308–309.
9. Uretsky BF, O'Brien JJ, Courtiss EH, et al. Augmentation mammoplasty associated with a severe systemic illness. *Ann Plast Surg*. 1979;3:445–447.
10. d'Ythurbide G, Kerrou K, Brocheriou I, et al. Reactive amyloidosis complicated by end-stage renal disease 28 years after liquid silicone injection in the buttocks. *BMJ Case Rep*. 2012;2012:1–3.