



Contents lists available at ScienceDirect

## International Journal of Surgery Case Reports

journal homepage: [www.casereports.com](http://www.casereports.com)

## Volvulus of ileal S-pouch: A rare complication of ileal pouch anal anastomoses



Gaurav Tyagi\*, Utsav Gupta, Ankit Verma, Dhananjay Saxena, Atul Mittal, Amit Goyal, Jeevan Kankaria, R.K. Jenaw

Department of General Surgery, S.M.S. Medical College, JLN Marg, Jaipur 302004, Rajasthan, India

### ARTICLE INFO

#### Article history:

Received 26 October 2013

Received in revised form 16 June 2014

Accepted 5 July 2014

Available online 23 August 2014

#### Keywords:

Ileal pouch volvulus

Ileal S-pouch

Volvulus

IPAA

Pouchpepy

### ABSTRACT

**INTRODUCTION:** Ileal pouch anal anastomosis (IPAA) after total proctocolectomy is a frequently performed surgery for medically refractory ulcerative colitis (UC). Volvulus of the ileal pouch as a complication of IPAA is extremely rare. We present a case of volvulus of S-type ileal pouch.

**PRESENTATION OF CASE:** A 28 year old male, with history of total proctocolectomy with IPAA for severe UC in 2009 presented with signs of bowel obstruction. Emergency laparotomy was done and a volvulus of the S-type ileal pouch was derotated and pouchpepy done.

**DISCUSSION:** The IPAA has a wide spectrum of complications, with obstruction of proximal small bowel occurring frequently. Volvulus of the ileal pouch is extremely rare with only 3 reported cases. Early diagnosis and intervention is important to salvage the pouch. Computed tomography (CT) may aid the diagnosis in stable patients.

**CONCLUSION:** The diagnosis of ileal pouch volvulus although rare, should be kept in mind when dealing with patients complaining of recurrent obstruction following IPAA.

© 2014 The Authors. Published by Elsevier Ltd. on behalf of Surgical Associates Ltd. This is an open access article under the CC BY-NC-SA license (<http://creativecommons.org/licenses/by-nc-sa/3.0/>).

### 1. Introduction

Ileal pouch anal anastomosis (IPAA) after total proctocolectomy, first popularized by Parks AG et al., in the early 1980s<sup>1,2</sup> is now the surgical procedure of choice in ulcerative colitis. Recurrent postoperative obstruction is a common complication after IPAA. Volvulus of the ileal pouch itself is extremely rare with only three cases reported in literature. We here report a case of volvulus of S-type ileal pouch, which is the first documentation of its type.

### 2. Case report

A 28 year old male presented to the emergency with colicky pain abdomen, distension and bilious vomiting for 3 days, and not passing flatus, motion for last 2 days.

On examination patient had tachycardia, hypotension and features of dehydration.

Abdomen showed the midline scar of previous surgery, was distended and tender.

Patient had a history of total proctocolectomy with ileal pouch anal anastomosis for refractory ulcerative colitis in 2009. There was no history of any other surgical procedure or any known medical comorbidity.

He had several episodes of constipation following the surgery but all were self-relieving.

Abdominal X-ray was suggestive of dilated bowel loops with multiple air fluid levels and a large loop of small bowel reaching up to left dome of diaphragm (Fig. 1).

Laboratory examinations revealed hemoglobin of 11.5 gm/dL, total leucocyte count 7200/cu mm. Blood sugar levels, serum urea/creatinine and liver function tests were within normal limits.

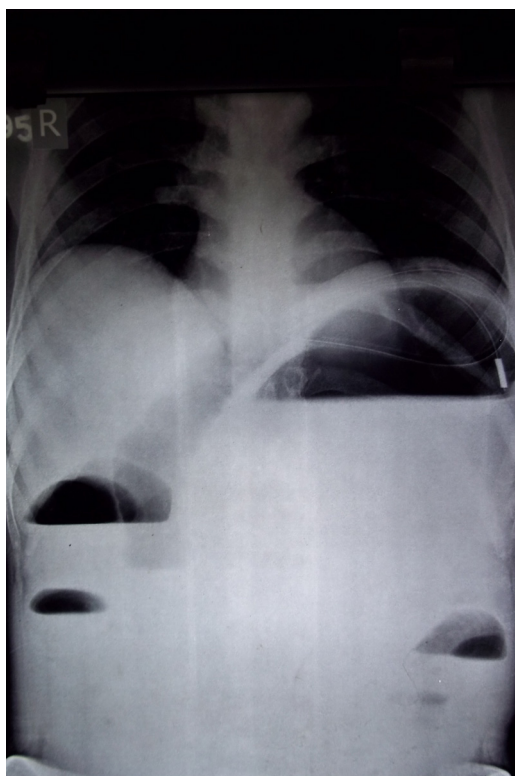
A diagnosis of acute post operative obstruction was made. Patient was resuscitated with intravenous fluids and nasogastric aspiration was done. Due to the deteriorating vital parameters of the patient an emergency laparotomy was planned.

Exploratory laparotomy with derotation of volvulus of ileal S-pouch with pouchpepy (anchoring the ascending and descending limbs of the S-pouch by seromuscular non absorbable polypropylene 2-0 sutures to the posterior pelvic wall/presacral fascia) and proximal loop ileostomy was done.

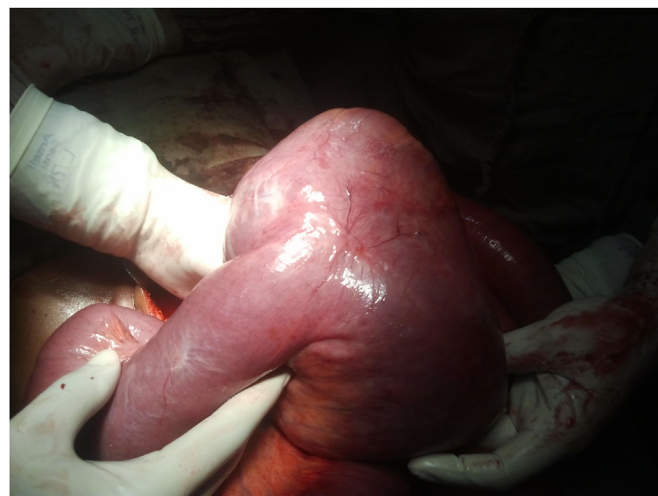Intraoperative findings were that of massively dilated S-type ileal pouch rotated upon its axis with proximal bowel dilatation, with multiple inter loop and peritoneal adhesions (Figs. 2–4). Upon derotation the pouch was healthy with no signs of ischemia, thus pouch fixation to pelvic side wall was done. Proximal diversion ileostomy for decompression was made.

\* Corresponding author. Tel.: +91 9660239454.

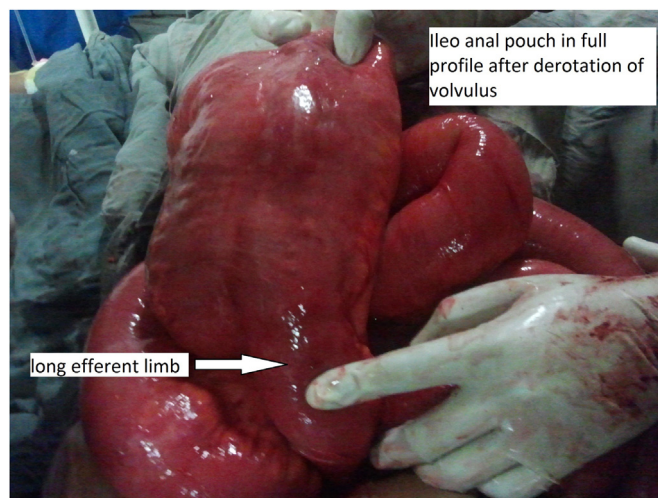
E-mail addresses: [gauravytyagi6886@gmail.com](mailto:gauravytyagi6886@gmail.com) (G. Tyagi), [drutsav86@gmail.com](mailto:drutsav86@gmail.com) (U. Gupta), [ankit.doc2004@gmail.com](mailto:ankit.doc2004@gmail.com) (A. Verma), [dr.dhananjaysaxena@gmail.com](mailto:dr.dhananjaysaxena@gmail.com) (D. Saxena), [a.mittal007@gmail.com](mailto:a.mittal007@gmail.com) (A. Mittal), [amitgoyal0304@gmail.com](mailto:amitgoyal0304@gmail.com) (A. Goyal), [jeevan.kankaria@gmail.com](mailto:jeevan.kankaria@gmail.com) (J. Kankaria), [jenawrk@yahoo.com](mailto:jenawrk@yahoo.com) (R.K. Jenaw).



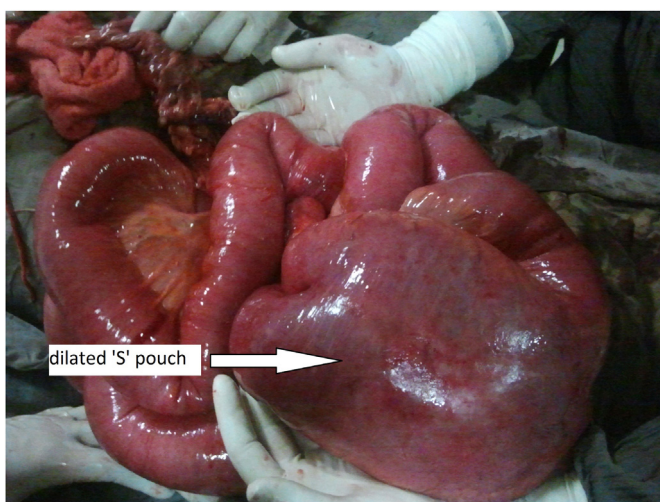
**Fig. 1.** Abdominal radiograph showing multiple air fluid levels and a large dilated small bowel loop reaching up to the left dome of diaphragm.



**Fig. 3.** Ileoanal pouch during derotation.



**Fig. 4.** Ileoanal pouch after complete derotation, showing the “S” shaped anastomosis.



**Fig. 2.** Intraoperative image of twisted S-type ileoanal pouch with proximal small bowel dilatation.

Patient became normotensive on post-operative day 2 and was discharged on post operative day 8. Gut continuity was restored with ileostomy closure after 2 months. The patient is in regular follow up and is asymptomatic for last 6 months since surgery.

### 3. Discussion

For patients with ulcerative colitis refractory to medical treatment, restorative proctocolectomy with ileal pouch anal anastomosis is the gold standard.<sup>3</sup> Ileal pouch provides the benefit of improved continence by maintaining the anal sphincter function thereby decreasing the stool frequency.<sup>4</sup>

Ileal pouch formation can have several variations including: the triple loop “S” pouch, double loop “J” pouch or quadruple loop “W” pouch. The type of pouch totally depends upon the surgeon expertise with the J-pouch being the most commonly performed.<sup>5</sup>

Complications of IPAA are varied ranging from pouch leak, pelvic abscess/sepsis, and pouch bleeding, occurring in the early post operative period (30 days) to the delayed manifestations of obstruction, pouchitis, fistula formation, anastomotic stricture, urinary and sexual dysfunction.

Obstruction of the small bowel is one of the most common complications and is generally due to post operative adhesions.<sup>6</sup>

Volvulus of the small bowel following IPAA is rare and to our knowledge only 6 cases have been reported in the literature with only 3 of them involving the ileal pouch itself<sup>7–13</sup> (Table 1). Our case being the first documentation on volvulus of an S-type ileal pouch.

Patel et al. have described a case of ileal pouch necrosis due to volvulus of small bowel,<sup>9</sup> thereby emphasizing the importance of early diagnosis and management in pouch salvage.

The CT findings of small bowel volvulus in a case of IPAA have been described by Catalano. He described signs of obstruction with a radial disposition of small bowel loops around the mesenteric root

**Table 1**

Cases of ileal pouch volvulus reported in literature.

Reference	Type of pouch	Stapled/hand-sewn	Site of volvulus	Operative procedure done
Ullah et al. [10]	W pouch	Stapled	Pouch	Redo of pouch
Patel et al. [9]	??	??	Small bowel	Pouch take down with end ileostomy
Jain and Abbas et al. [8]	J pouch	Stapled	Pouch	Redo of pouch
Arima et al. [11]	J pouch	Stapled	Pouch	Pouchpexy

and an abnormal right sided position of the superior mesenteric artery and vein in an abdominal CT.<sup>7</sup>

The usefulness of endoscopy in diagnosis or reduction of volvulus is doubtful with cases of unsuccessful attempts<sup>11</sup> and even a perforation<sup>8</sup> had been reported.

When the diagnosis is in doubt and patient still in obstruction, exploration should not be delayed; failing to do so can lead to necrosis and pouch loss. Upon exploration, if the pouch is viable after de-rotation and anastomotic site healthy, simple pouchpexy is all that is required. Presence of gangrene in the pouch or proximal bowel should warrant a redo of the pouch anastomosis with preferable proximal diversion ileostomy.

Role of post-operative follow-up endoscopy is not yet proven.

As in our case the patient's deteriorating general condition mandated early operative intervention, a CT or endoscopic evaluation/intervention could not be performed.

There were no technical issues with the pouch formation and ileoanal anastomosis during the original operation.

During the current surgery distal limb of the "S" type pouch containing the ileoanal anastomosis was found to be abnormally elongated. The elongation could have been the result of chronic repeated obstruction which might have led to the volvulus. But this conclusion cannot be definitively drawn due to the rarity of this complication. Also the occurrence of a pouch volvulus cannot attributed to a specific pouch type.

#### 4. Conclusion

Volvulus of the ileal pouch is a very rare occurrence following IPAA for ulcerative colitis. It should always be included in the differential diagnosis of patients presenting with recurrent post operative obstruction due to its serious complications. In our case timely exploration and correction of the volvulus lead to the pouch salvage, hence preventing the patient from undergoing another major procedure and morbidity, thus emphasizing on the importance of early diagnosis and management of ileal pouch volvulus.

#### Conflicts of interest

The authors report that there are no conflicts of interest.

#### Funding

None.

#### Ethical approval

Written informed consents were obtained from the patient for publication of the case and accompanying images. A copy of the written consent is available for review by Editor-in-Chief of the journal on request.

#### Author contributions

Dr. Gaurav Tyagi—Study design, data acquisition, writing, article revision and data analysis.

Dr. Utsav Gupta—Study design, data analysis.

Dr. Ankit Verma—Article revision and writing.

Dr. Dhananjay Saxena—Writing.

Dr. Atul Mittal—Data acquisition.

Dr. Amit Goyal—Article revision.

Dr. Jeevan Kankaria—Design, article revision.

Dr. R.K. Jenaw—Data analysis, article revision and approval

#### References

1. Parks AG, Nicholls RJ, Belliveau P. Proctocolectomy with ileal reservoir and anal anastomosis. *Br J Surg* 1980;**67**:533–8.
2. Martin LW, Fischer JOSEFE. Preservation of anorectal continence following total colectomy. *Ann Surg* 1982;**196**:6:700.
3. Fazio VW, et al. Ileal pouch-anal anastomoses complications and function in 1005 patients. *Ann Surg* 1995;**222**:2:120.
4. Pemberton JH, Kelley KA, Beart Jr RW, Dorzois RR, Wolff BG, Ilstrup DM. Ileal pouch-anal anastomosis for chronic ulcerative colitis: long-term results. *Ann Surg* 1987;**206**:504–11.
5. Sagar PM, Taylor BA. Pelvic ileal reservoirs: the options. *Br J Surg* 1994;**81**:325–32.
6. Francois Y, Dozois RR, Kelly KA, et al. Small intestinal obstruction complicating ileal pouch-anal anastomosis. *Ann Surg* 1989;**209**:46–50.
7. Catalano O. Small bowel volvulus following ileal pouch-anal anastomosis: CT demonstration. *Euro J Radiol* 1996;**23**:115–7.
8. Jain A, Abbas MA, Sekhon HK, Rayhanabad JA. Volvulus of an ileal J-pouch. *Inflamm Bowel Dis* 2010;**16**:3–4.
9. Patel S, Salotera G, Gurjar S, Hewes J, Ahmed I, Andrews B. Ileo-anal pouch necrosis secondary to small bowel volvulus: a case report. *World J Emerg Surg* 2008;**3**:18.
10. Ullah MZ, Fajobi OA, Bhargava AM. Long-axis rotational volvulus in a W ileo-anal pouch: an unusual but potentially preventable problem. *Dis Colon Rectum* 2007;**50**:540–3.
11. Arima K, Wantanabe M, Iwatsuki M, et al. Volvulus of an ileal pouch-rectal anastomosis after subtotal colectomy for ulcerative colitis: report of a case. *Surg Today* 2013. PMID: 24048765 (Epub ahead of print).
12. Warren C, O'Donnell ME, Gardiner KR, Irwin T. Successful management of ileo-anal pouch volvulus. *Colorectal Dis* 2011;**13**:1:106–7.
13. Choughari L, Sohawon S, Noordally SO. Volvulus of an ileoanal J pouch. *Int J Colorectal Dis* 2010;**25**(8):1021–2.

#### Open Access

This article is published Open Access at [scimedirect.com](http://scimedirect.com). It is distributed under the [IJSCR Supplemental terms and conditions](#), which permits unrestricted non commercial use, distribution, and reproduction in any medium, provided the original authors and source are credited.