

Effects of inferior alveolar nerve rupture on bone remodeling of the mandible

A preliminary study

Hongzhou Shen, DDS, PhD, Shuze Wang, DDS, Yin Zhi, DDS, Jiawen Si, DDS, PhD*, Jun Shi, MD, PhD*

Abstract

Although various animal studies have indicated that sensory nerves played an important role in bone metabolism and nerve injury could impair the process of bone remodeling, the actual effect of sensory nerve rupture on human bones remains unclear. The aim of this preliminary study was to investigate the effect of inferior alveolar nerve (IAN) rupture on mandibular bone remodeling of patients underwent bilateral sagittal split ramus osteotomy (BSSRO).

Ten patients with unilateral IAN rupture during BSSRO were involved in this study. Neurosensory examinations were employed to assess the sensory function of bilateral IAN. The remodeling process of the post-operational mandible was evaluated by panoramic radiographs and computed tomography (CT) scans.

Neurosensory examinations indicated that nerve rupture resulted in significant hypoesthesia at the IAN-rupture side. Assessment of panoramic radiographs showed no evident alterations of bone structure at the IAN-rupture side of mandible. Evaluation of CT images also indicated no statistical difference in bone density and thickness between IAN-rupture side and contralateral side.

Accordingly, our study indicated that IAN rupture may not significantly impair the short-term bone remodeling process of human mandible.

Abbreviations: 3M = 3-month, 6M = 6-month, BSSRO = bilateral sagittal split ramus osteotomy, CGRP = calcitonin gene-related peptide, IAN = inferior alveolar nerve, LCT = lingual cortical thickness, MTD = mean trabecular density, SP = substance P.

Keywords: bone remodeling, mandible, nerve injury, sagittal split osteotomy

1. Introduction

Human bones are constantly remodeled by targeted and untargeted remodeling.^[1,2] The untargeted remodeling is a stochastic process which participates in maintaining the balance of essential mineral, while the targeted remodeling is aimed at specific sites, providing a mechanism for the bone tissue to repair

damage and adapt itself to the mechanical environment.^[1] Numerous factors, including mechanical loading, aging, endocrine system, and neural system, have been shown to participate in both targeted and untargeted remodeling.^[3–8] Among these factors, nerve system, as was recently suggested by in vitro and in vivo studies, may play an equally important role in the targeted bone remodeling with the others.^[6,7,9–17] The in vivo evidence derived from murine and rabbit inferior alveolar nerve (IAN) transection models indicated that IAN injury could lead to a delayed process of bone healing and significant periodontal bone damage in the mandible.^[7,9,10,12,14,16,17] The related results of immunohistochemical analysis revealed that IAN injury altered the expression level of several IAN-secreted neuropeptides, such as calcitonin gene-related peptide (CGRP) and substance P (SP), and subsequently impaired bone remodeling by affecting osteoclast and osteoblast activities.^[6,9,10,13,17]

Notably, the IAN transection model is very similar to the situation of IAN rupture during bilateral sagittal split ramus osteotomy (BSSRO), a prevalent surgical method for the correction of maxillofacial deformities. As the most frequently-adopted surgical procedure in orthognathic surgery, neurosensory disturbance remains one of the most common complications of BSSRO despite of its advantages.^[7,9,17,18] Previous studies reported that persistent post-operational hypoesthesia of IAN due to nerve rupture during operation might occur in 1.3% to 7% of BSSRO cases.^[18–23] Though the incidence rate is low, if it did happen, however, the subsequent effect of IAN rupture on remodeling of human mandible is still unclear. Therefore, this study was designed to investigate the bone remodeling process of the unilaterally IAN-rupture mandible by assessing nerve function and radiograph data, through which, we hope to, provide a guidance for clinical practice.

Editor: Xu Qian.

HS and SW contributed equally to this work.

This work was supported by the National Natural Science Foundation of China (No: 81600827).

The authors have no conflicts of interest to disclose.

Supplemental Digital Content is available for this article.

Department of Oral and Craniomaxillofacial Surgery, Shanghai Ninth People's Hospital, College of Stomatology, Shanghai Jiao Tong University School of Medicine, National Clinical Research Center for Oral Diseases, Shanghai Key Laboratory of Stomatology, Shanghai Research Institute of Stomatology, Shanghai, People's Republic of China.

* Correspondence: Jiawen Si, Jun Shi, Department of Oral and Craniomaxillofacial Surgery, Shanghai Ninth People's Hospital, College of Stomatology, Shanghai Jiao Tong University School of Medicine, No. 639, Zhizaoju Road, Shanghai, 200011, People's Republic of China (e-mail: sjwly@163.com).

Copyright © 2019 the Author(s). Published by Wolters Kluwer Health, Inc. This is an open access article distributed under the terms of the Creative Commons Attribution-Non Commercial-No Derivatives License 4.0 (CCBY-NC-ND), where it is permissible to download and share the work provided it is properly cited. The work cannot be changed in any way or used commercially without permission from the journal.

Medicine (2019) 98:35(e16897)

Received: 19 October 2018 / Received in final form: 20 July 2019 / Accepted: 27 July 2019

<http://dx.doi.org/10.1097/MD.00000000000016897>

2. Patients and methods

2.1. Patients

This retrospective research was approved by the Independent Ethics Committee of Shanghai Ninth People's Hospital affiliated to Shanghai JiaoTong University, School of Medicine (SH9H-2018-T19-1). All medical records of patients who received BSSRO in our department from 2013 to 2018 were retrieved to screen out the unilaterally IAN-rupture cases. Patients with a history of alcohol abuse, smoking, medications, or pathology that could influence bone metabolism were excluded from this study. Finally, a total of 10 eligible cases (4 males and 6 females) were included in this study.

2.2. Neurosensory examinations

The IAN-distributed area was divided into 4 sites in each patient: site 1-right lower lip; site 2-left lower lip; site 3-left chin skin; site 4-right chin skin (Supplemental digital content.1, <http://links.lww.com/MD/D187>).^[19] The IAN neurosensory disturbance was evaluated by a self-assessment (Westermarck) test and a light-touch sensation examination. According to Westermarck's study, patients were asked to select a score for each site on basis of a 5-point assessment system: 1-completely numb; 2-almost no sensation; 3-reduced sensitivity; 4-almost normal sensitivity; 5-completely normal sensitivity.^[24] The light-touch sensation examination was carried out by a doctor.^[18] The criteria of

light-touch sensation were: 0-no responding to stimuli; 1-serious perception loss; 2-hardly perceiving mild stimuli with sensory change; 3-perceiving mild stimuli with sensory change; 4-perceiving mild stimuli with no sensory change. Both examinations were repeated 3 times by the same examiner.^[18]

2.3. Assessment of panoramic radiograph

The preoperational and postoperational (3 months and 6 months) panoramic radiographs of selected patients were obtained to assess the bilateral mandibular cortex and trabeculae at the premolar region.

- (1) The mandibular cortex was categorized according to Klemetti Index.^[25,26]
 - (i) Normal cortex: The endosteal margin of the cortex is even and sharp on both sides;
 - (ii) Moderately eroded cortex: The endosteal margin shows lacunar resorption or endosteal cortical residues;
 - (iii) Severely eroded cortex: The cortex forms heavy endosteal cortical residues and is unequivocal porosity;
- (2) The mandibular trabeculae was categorized according to a 3-step visual index.^[27-29]
 - (i) Dense: Small intertrabecular spaces;
 - (ii) Mixed dense: Small intertrabecular spaces cervically and large spaces apically;
 - (iii) Sparse: Large intertrabecular spaces

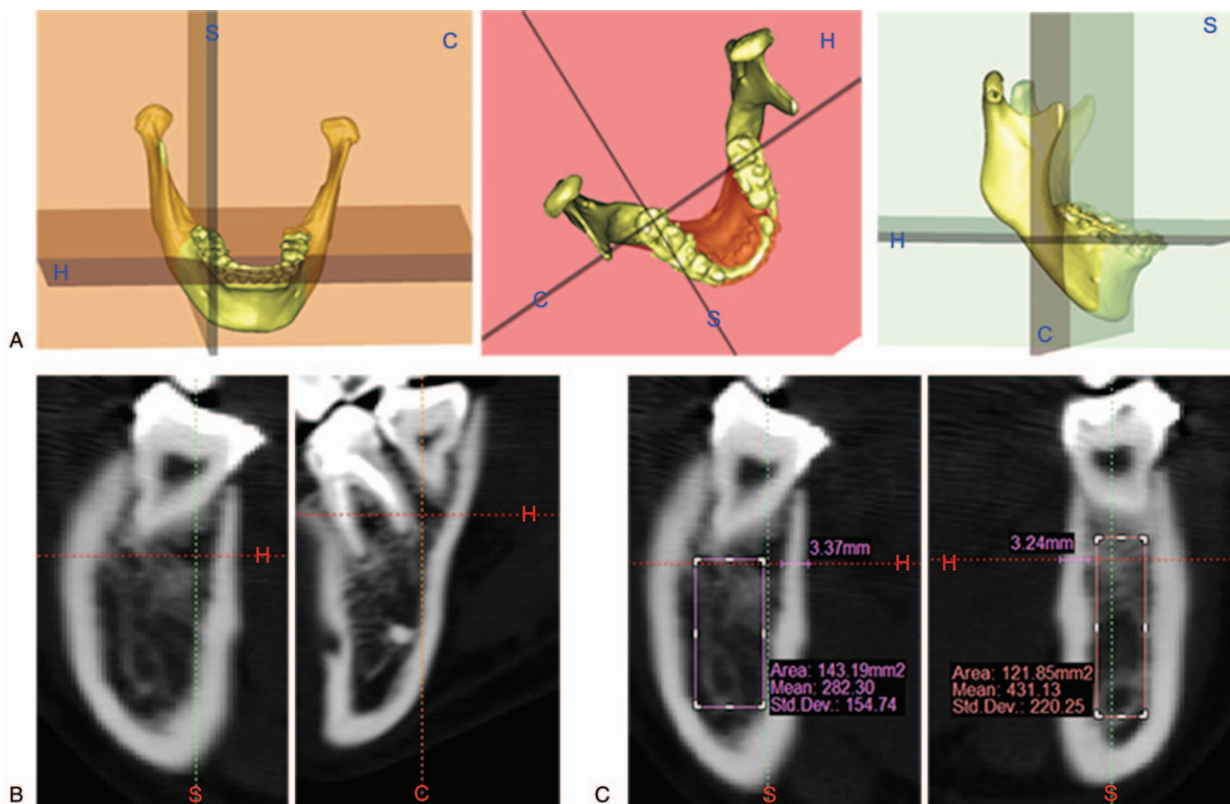


Figure 1. (A) Three-dimensional location of ROI, C means coronal plane, S means sagittal plane, H means horizontal plane, the coronal and sagittal plane cross on the central fossa of lower 7; (B) 2-dimensional location of ROI, the coronal and sagittal plane pass the central fossa of lower 7, the horizontal plane passes the midpoint of the mesial apex of lower 7 and the distal apex of lower 6; (C) LCT was measured at the level of horizontal plane, MTD of the selected region was calculated by the software. LCT = lingual cortical thickness, MTD = mean trabecular density, ROI = region of interest.

Table 1
Difference values of LCT and MTD.

	LCT	MTD
3-mo	$LCT_3 - LCT_p$	$MTD_3 - MTD_p$
6-mo	$LCT_6 - LCT_p$	$MTD_6 - MTD_p$

LCT_3 = 3-month lingual cortical thickness, LCT_6 = 6-month lingual cortical thickness, LCT_p = pre-operational lingual cortical thickness, MTD_3 = 3-month mean trabecular density, MTD_6 = 6-month mean trabecular density, MTD_p = pre-operational mean trabecular density.

2.4. Evaluation of computed tomography images

Computed tomography (CT) scans (Philips Brilliance 64, 120 kv, 1.0 mm-thickness) were performed before and 3 months, 6 months after surgery. Related CT data were imported into Simplant (Materialise Dental, Leuven, Belgium) to reconstruct the 3-dimensional models of mandible (Threshold: 350–2976 HU). The location of regions of interest was demonstrated in Figure 1A and B. The bilateral lingual cortical thickness (LCT) and mean trabecular density (MTD) were measured on the 2-

dimensional CT images and calculated by the software (Fig. 1C). The difference values of LCT and MTD on each side was calculated by the formulas listed in Table 1.

2.5. Statistics

All data were presented as mean value and analyzed by IBM SPSS statistics software (version 22.0; IBM, Armonk, NY). Wilcoxon signed-ranked test was applied to assess the differences between the IAN-rupture side and contralateral one. The level of statistical significance was set at $P < .05$.

3. Results

All these 10 patients (25.3 ± 3.95 years old) were healthy with normal sensation function of IAN before surgery. As was shown in Figure 2, the vertical osteotomy cut was extended from the distal of the first molar to the posterior border of mandible. IAN rupture might occur during the cutting, splitting or moving the mandible (Fig. 2C). Each case of unilateral IAN rupture was observed and confirmed by the surgeon during surgery (Fig. 2D).

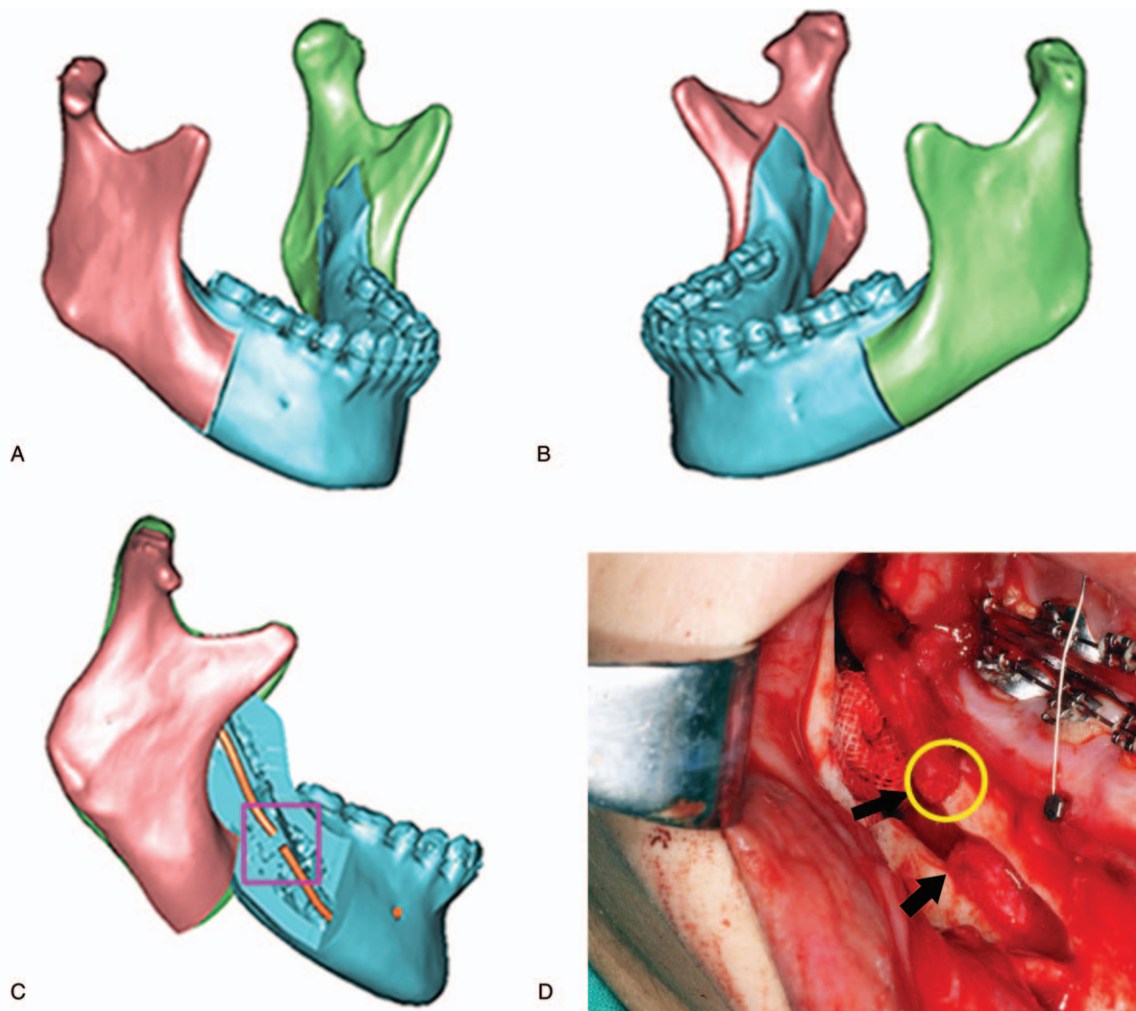


Figure 2. (A and B) The osteotomy line of BSSRO, the vertical osteotomy cut was extended from the distal of the first molar to the posterior border of mandible; (C) the model of IAN-rupture side, the rupture site of IAN was highlighted by the box; (D) IAN rupture during BSSRO surgery, the broken ends of IAN were marked by the black arrow, the broken surface of IAN was highlighted by the yellow circle. BSSRO = bilateral sagittal split ramus osteotomy, IAN = inferior alveolar nerve.

Table 3
Light sensation examination.

	Injured side	Site 1 (3M)	Site 2 (3M)	Site 3 (3M)	Site 4 (3M)	Site 1 (6M)	Site 2 (6M)	Site 3 (6M)	Site 4 (6M)
Patient 1	Right	1.7	3.7	3.3	2.0	2.3	4.0	3.3	2.7
Patient 2	Right	0.0	3.3	4.0	0.0	0.3	3.7	4.0	0.3
Patient 3	Left	3.7	1.7	2.0	3.0	4.0	2.0	2.3	4.0
Patient 4	Left	3.3	0.7	1.3	4.0	4.0	1.0	1.0	4.0
Patient 5	Left	4.0	1.7	1.7	3.3	4.0	2.0	1.7	3.7
Patient 6	Right	2.0	4.0	4.0	2.3	2.7	4.0	4.0	2.7
Patient 7	Right	0.7	3.7	3.7	1.3	1.7	4.0	4.0	2.0
Patient 8	Left	3.7	1.0	1.3	3.3	3.7	1.7	1.7	3.7
Patient 9	Right	1.3	3.3	3.3	1.7	2.3	3.7	4.0	2.0
Patient 10	Right	0.7	3.3	3.3	1.0	1.7	3.7	3.7	1.7

3M = 3-month, 6M = 6-month.

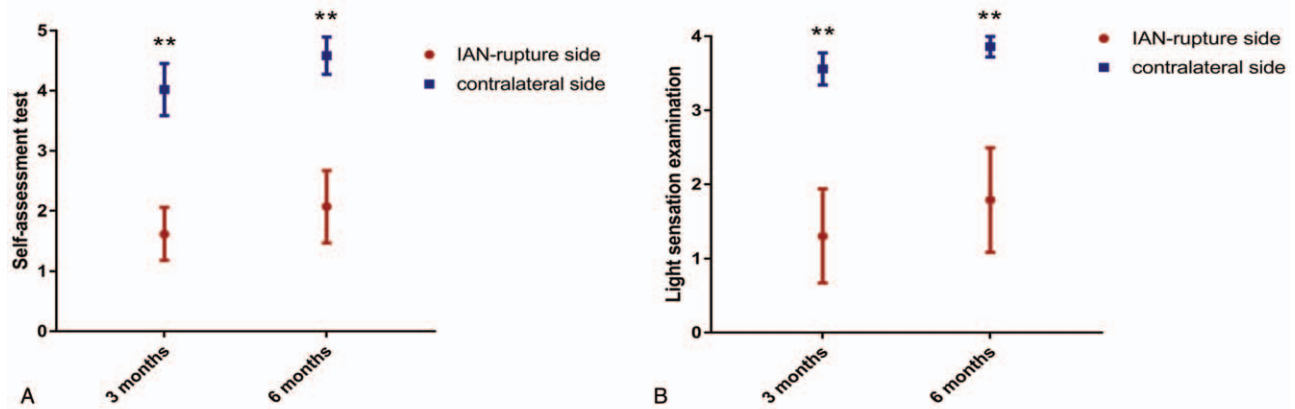


Figure 3. The sensation scores of self-assessment test and light sensation examination. (A) Self-assessment test, $p_{3\text{-month}} = .005$, $p_{6\text{-month}} = .005$; (B) light sensation examination, $p_{3\text{-month}} = .005$, $p_{6\text{-month}} = .005$.

3.1. Neurosensory examinations

All patients were free of neurosensory disturbance before surgery. The postoperational sensation scores of all patients were listed in Tables 2 and 3. The average sensation scores of IAN-rupture side and contralateral one were presented in Figure 3. Figure 3 indicated that BSSRO surgery led to an impaired sensation function of bilateral IAN with a significantly lower sensation score at the IAN-rupture side. Although the sensation function of

IAN might slightly restore over 6 months after surgery, patients still felt numb on the skin of IAN-rupture side, indicating that the sensation function of ruptured IAN had no apparent improvement.

3.2. Panoramic radiograph

The patients' preoperational panoramic radiographs depicted normal cortical and trabecular bone in both sides (Fig. 4A). No evident alteration of bone structure was found on postopera-

Table 2
Self-assessment test.

	Injured side	Site 1 (3M)	Site 2 (3M)	Site 3 (3M)	Site 4 (3M)	Site 1 (6M)	Site 2 (6M)	Site 3 (6M)	Site 4 (6M)
Patient 1	Right	1.7	4.3	4.0	2.0	3.3	5.0	5.0	3.3
Patient 2	Right	1.0	3.6	3.3	1.0	1.3	4.0	4.3	2.7
Patient 3	Left	4.0	2.3	2.3	4.0	4.3	2.7	3.0	4.7
Patient 4	Left	3.3	1.3	1.7	3.0	4.0	1.3	2.0	4.3
Patient 5	Left	4.3	1.7	2.0	4.0	4.7	2.0	2.0	5.0
Patient 6	Right	1.7	4.0	5.0	2.7	2.0	4.7	5.0	2.7
Patient 7	Right	1.3	4.0	4.3	1.7	1.3	4.7	4.3	1.7
Patient 8	Left	4.3	1.7	1.3	4.3	4.7	1.7	1.3	4.7
Patient 9	Right	1.3	4.7	4.3	1.7	2.0	5.0	4.7	1.7
Patient 10	Right	1.0	4.0	3.7	1.0	1.7	4.3	4.3	1.7

3M = 3-month, 6M = 6-month.

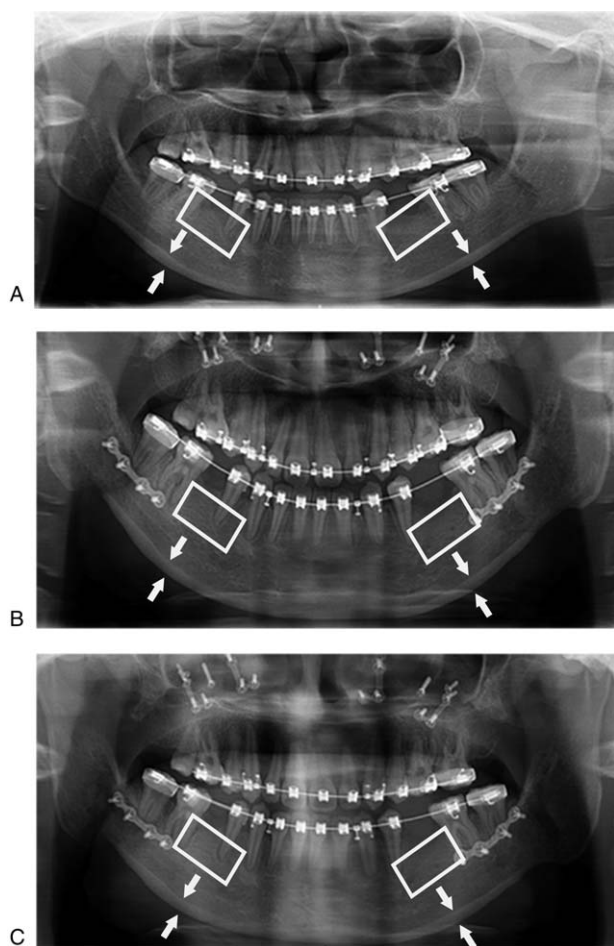


Figure 4. Cortical bone in the premolar mandibular region (white arrow), trabeculae bone in the premolar region (white box). (A) Preoperational panoramic radiograph; (B) panoramic radiograph (3 months after BSSRO); (C) panoramic radiograph (6 months after BSSRO). BSSRO = bilateral sagittal split ramus osteotomy.

tional panoramic radiographs (Fig. 4B and C). The trabecular bone in bilateral premolar region of all patients exhibited dense bone pattern with small intertrabecular spaces on the pre- and postoperational radiographs (Fig. 4).

3.3. CT images

Minor alterations of bone structure were then further verified on CT images. For all patients, bone regeneration occurred at the bilateral osteotomy region (Fig. 5C and E). Compared with the preoperational images, bone structure was normal bilaterally and no abnormal alteration was found in the mandibular osteotomy region (Fig. 5B, D, and F). The detailed data of LCT and MTD were presented in Tables 4 and 5. Figure 6 depicted the difference values of LCT and MTD of the IAN-rupture side and contralateral side. Analysis of the difference values demonstrated no significant difference between the IAN-rupture side and contralateral one ($P > .05$).

4. Discussion

Bone metabolism is complicatedly regulated by systemic and local factors. In the last 2 decades, an increasing number of

studies have concentrated on the origin, distribution, and function of neural system in bone.^[6,10,13,15,17] Previous immunohistochemical evidence confirmed that sensory nerve fibers distributed in periosteum, trabecular bone, and cortical bone.^[6,7,9] Recent animal studies of experimental denervation have indicated that sensory neural systems are closely involved in bone remodeling.^[8,11,15,30] A complex of cellular and molecular signal alterations may be immediately initiated following a sensory nerve injury. If had not been promptly treated, neural injury could cause a significant reduction in the release of neuropeptides, thus affecting the balance of bone metabolism.^[6] However, intriguing paradox still exists in the facts that isolated bone cells and tissue-engineered bones with no innervation can still be used to restore bone defects and fractures. Moreover, no strong clinical evidence has supported the close correlation of sensory nerve injury and attenuation of bone healing so far. Notably, Hert et al have indeed demonstrated that innervated and denervated limbs react to intermittent loading in the same way.^[31] Through assessing the pre- and postoperational radiological images of 10 patients with unilateral IAN rupture during BSSRO, we also found no significant alterations of bone structure, density and healing quality at the IAN-rupture side.

IAN, a branch of the mandibular nerve, travels beneath the lateral pterygoid muscle before entering mandibular canal through the mandibular foramen. The IAN inside the mandibular canal is a sensory nerve surrounded by mandibular cortex and trabeculae, which makes IAN an ideal model for investigating the influence of peripheral sensory nerves on bone remodeling.^[9] Previous in vivo studies have well established that IAN transection would significantly impede the healing process of mandibular bone and aggravate periodontal tissue destruction by inhibiting osteoblast function, promoting osteoclast formation, and changing the secretion of several neuropeptides such as CGRP, SP, and nerve growth factor- β (NGF- β).^[9,30,32] Moreover, the neuropeptides released from sensory nerve fibers are also able to regulate the in vitro differentiation of osteoblast lineage cells, and promote in vivo bone formation and remodeling.^[10,12,13]

Thus, according to the aforementioned findings, patients with IAN rupture might suffer from not only paresthesia but also impaired bone remodeling theoretically.^[14] However, the present results of our study failed to support such hypothesis. Although the neurosensory examinations indicated a severe impairment of sensation function at the IAN-rupture side up to 6 months after the surgery, no obvious sign of abnormal bone resorption was found at the rupture side. Evaluation of panoramic radiographs and CT images revealed that bone remodeling at the rupture side was similar to the contralateral side. Actually, animal study is a relatively simple experimental model which is unable to reproduce the complicated conditions in human body. Therefore, 3 possible factors might explain the inconsistency between our results and previous findings. First, the surgical method of animal study is different with BSSRO surgery. The IAN transection model of animal study was established by transecting IAN at the site of mandibular foramen, while IAN rupture mainly occurred inside the mandibular canal during BSSRO.^[9,18] Second, different examination methods between clinical study and animal study might contribute to the inconsistent results. Micro-CT and histological examination, 2 common examination methods of animal study, were capable of discovering the microscopic alterations of bone structure.^[9-11,17,33] However, panoramic radiograph and CT scan could hardly achieve the same accuracy.

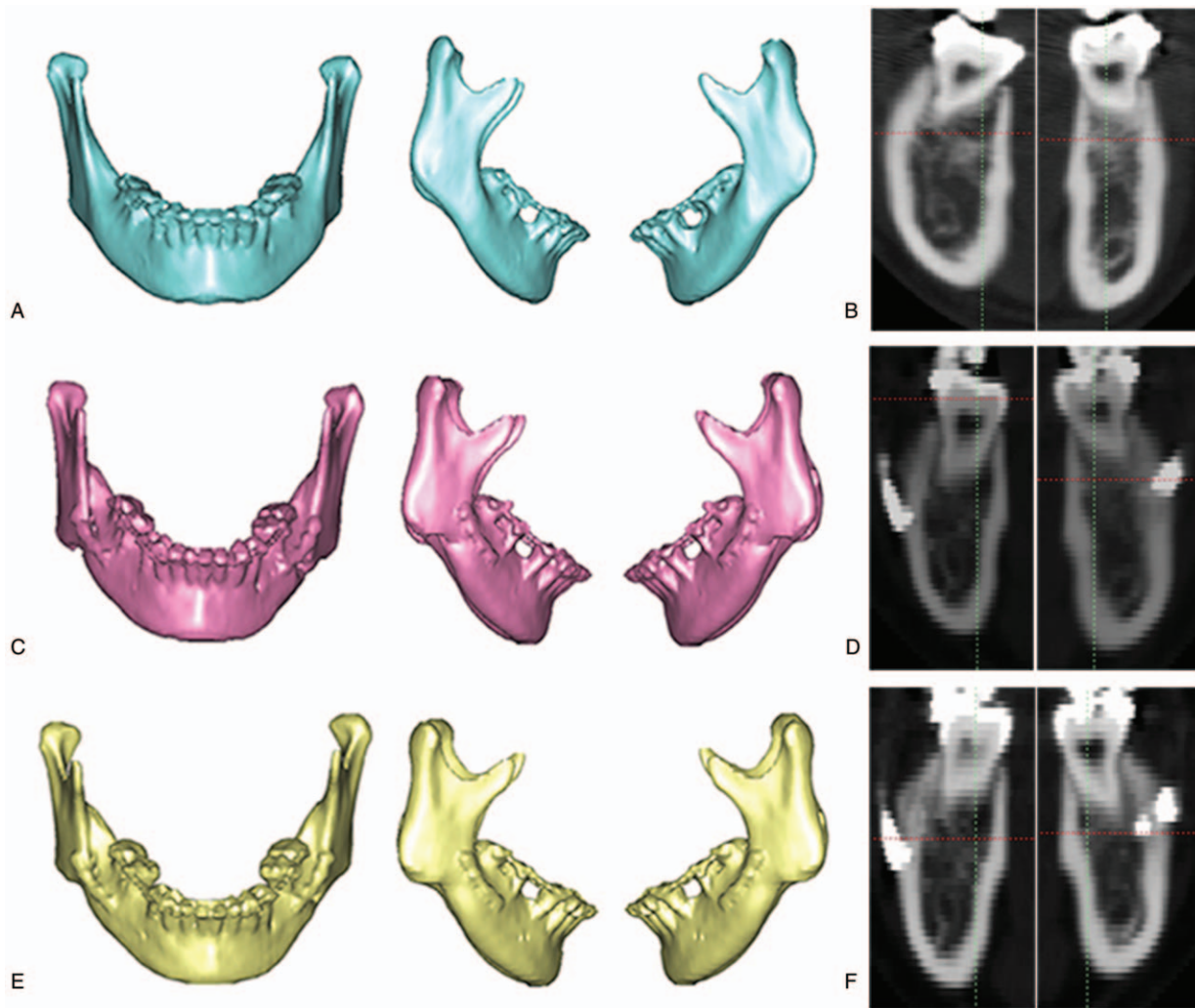


Figure 5. The 3-dimensional models of mandible, (A) preoperational; (C) 3 months after BSSRO; (E) 6 months after BSSRO. Bone regeneration occurred at the bilateral osteotomy region; The 2-dimensional bone structures of ROI. (B) Preoperational; (D) 3 months after BSSRO; (F) 6 months after BSSRO. Compared with the preoperational images (B), the postoperational bone structure (D and F) was normal bilaterally and no abnormal alteration was found. BSSRO = bilateral sagittal split ramus osteotomy, ROI = region of interest.

Still, CT scan has been so far the most precise method for noninvasive assessment of bone structure.^[34–37] We combined the evaluation of panoramic radiographs with analysis of CT images in order to assess the bone remodeling of postoperational

mandible as thorough as possible.^[38,39] Third, bone remodeling controlled by mechanical loading may also account for such discrepancy. For those patients receiving BSSRO surgery, they usually possess a balanced mechanical loading and masticatory

Table 4
Lingual cortex thickness (mm).

	Right (pre)	Left (pre)	Right (3M)	Left (3M)	Right (6M)	Left (6M)
Patient 1	3.60	3.34	3.92	3.67	3.92	3.76
Patient 2	4.07	4.04	3.79	3.49	3.95	3.53
Patient 3	2.71	3.19	3.02	3.53	2.66	2.97
Patient 4	3.07	3.93	3.01	4.43	3.41	4.31
Patient 5	4.21	4.36	3.44	4.54	3.53	4.86
Patient 6	3.88	3.83	3.92	3.73	3.15	4.66
Patient 7	3.48	3.83	3.17	3.91	3.92	3.47
Patient 8	3.75	3.66	3.81	3.89	3.71	3.93
Patient 9	4.11	3.72	3.72	3.88	4.02	3.11
Patient 10	3.93	4.02	3.80	4.06	3.27	3.84

3M = 3-month, 6M = 6-month.

Table 5
Mean trabecular density (HU).

	Right (pre)	Left (pre)	Right (3M)	Left (3M)	Right (6M)	Left (6M)
Patient 1	335.47	353.76	330.60	320.83	286.90	261.18
Patient 2	401.60	167.24	502.76	169.14	493.80	204.24
Patient 3	283.31	178.58	263.86	170.73	268.32	182.63
Patient 4	231.10	508.23	371.55	525.40	329.27	414.76
Patient 5	67.31	89.52	161.76	294.20	174.55	575.93
Patient 6	131.10	124.74	145.71	152.66	461.16	337.80
Patient 7	327.10	278.68	344.62	321.70	353.45	309.52
Patient 8	229.34	356.70	236.62	326.88	277.84	318.73
Patient 9	382.93	452.65	425.76	432.29	369.32	398.78
Patient 10	157.31	205.84	252.80	271.44	206.41	221.20

3M = 3-month, 6M = 6-month.

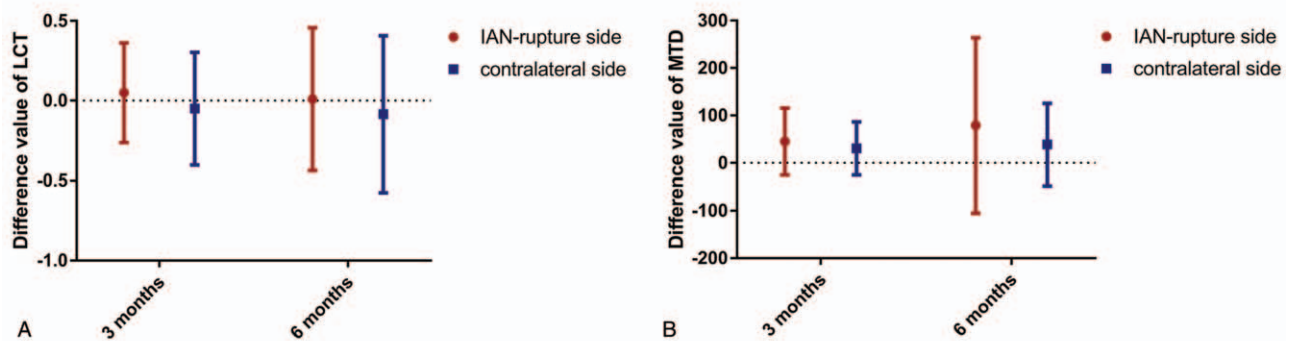


Figure 6. The difference values of LCT and MTD. (A) Difference value of LCT, $p_{3\text{-month}} = .48$, $p_{6\text{-month}} = .51$; (B) difference value of MTD, $p_{3\text{-month}} = .51$, $p_{6\text{-month}} = .29$. LCT = lingual cortical thickness, MTD = mean trabecular density.

function of the mandible after surgery, which is different with the experimental animals in which the nerve transection may lead to disuse of unilateral mandible. The negative influence of disuse of unilateral hind limbs on distraction osteogenesis highlighted the vital effect of mechanical stimulation on bone remodeling.^[15] Particularly, bone turnover stimulated by mechanical loads may influence the effect of neural transmitter on experimental animals likewise.^[33]

Admittedly, there are limitations in our study. The sample size of the present study was relatively limited since the rather rare incidence rate of IAN rupture. In addition, the radiographic follow-up of 6 months was short, and long-term follow-up was warranted to demonstrate the reproducibility of our radiographic findings. Given these limitations, more cases with long-term observation will be needed to achieve a clear vision in the future.

In conclusion, we found that the remodeling pattern of bone at the IAN-rupture side was no different from that at the contralateral side, as indicated that IAN rupture might not significantly impair the short-term bone healing process of human mandible. Multiple factors rather than sensory nerve alone may play more crucial roles in mandibular bone remodeling when IAN was ruptured.

Author contributions

Data curation: Shuze Wang, Yin Zhi.

Formal analysis: Jun Shi.

Funding acquisition: Jiawen Si.

Investigation: Hongzhou Shen, Jiawen Si.

Methodology: Jun Shi.

Project administration: Hongzhou Shen, Jiawen Si, Jun Shi.

Software: Yin Zhi.

Writing – original draft: Hongzhou Shen, Yin Zhi.

Writing – review and editing: Shuze Wang, Jiawen Si, Jun Shi.

References

- [1] Burr DB. Targeted and nontargeted remodeling. *Bone* 2002;30:2–4.
- [2] Parfitt AM. Targeted and nontargeted bone remodeling: relationship to basic multicellular unit origination and progression. *Bone* 2002;30:5–7.
- [3] Jonasson G, Jonasson L, Kiliaridis S. Changes in the radiographic characteristics of the mandibular alveolar process in dentate women with varying bone mineral density: a 5-year prospective study. *Bone* 2006;38:714–21.
- [4] Kim Y, Hamada N, Takahashi Y, et al. Cervical sympathectomy causes alveolar bone loss in an experimental rat model. *J Periodontol Res* 2010;44:695–703.
- [5] Pagani F, Sibilia V, Cavani F, et al. Sympathectomy alters bone architecture in adult growing rats. *J Cell Biochem* 2010;104:2155–64.
- [6] Chenu C. Role of innervation in the control of bone remodeling. *J Musculoskelet Neuronal Interact* 2004;4:132–4.
- [7] Wu Q, Yang B, Cao C, et al. Age-dependent impact of inferior alveolar nerve transection on mandibular bone metabolism and the underlying mechanisms. *J Mol Histol* 2016;47:1–8.
- [8] Tamaki H, Yotani K, Ogita F, et al. Changes over time in structural plasticity of trabecular bone in rat tibiae immobilized by reversible sciatic denervation. *J Musculoskelet Neuronal Interact* 2013;13:289–96.
- [9] He H, Tan Y, Yang M. Effect of substance P in mandibular osteotomies after amputation of the inferior alveolar nerve. *J Oral Maxillofac Surg* 2010;68:2047–52.
- [10] Zhang YB, Wang L, Jia S, et al. Local injection of substance P increases bony formation during mandibular distraction osteogenesis in rats. *Br J Oral Maxillofac Surg* 2014;52:697–702.
- [11] Ding Y, Arai M, Kondo H, et al. Effects of capsaicin-induced sensory denervation on bone metabolism in adult rats. *Bone* 2010;46:1591–6.

- [12] Cao J, Wang L, Lei DL, et al. Local injection of nerve growth factor via a hydrogel enhances bone formation during mandibular distraction osteogenesis. *Oral Surg Oral Med Oral Pathol Oral Radiol* 2012; 113:48–53.
- [13] Henmi A, Nakamura M, Echigo S, et al. Involvement of sensory neurons in bone defect repair in rats. *J Electron Microsc* 2011;60:393–400.
- [14] Idayanemochi H, Yamada Y, Yoshikawa H, et al. Locally produced BDNF promotes sclerotic change in alveolar bone after nerve injury. *Plos One* 2017;12:e0169201.
- [15] Song D, Jiang X, Zhu S, et al. Denervation impairs bone regeneration during distraction osteogenesis in rabbit tibia lengthening. *Acta Orthopaedica* 2012;83:406–10.
- [16] Wang L, Cao J, Lei DL, et al. Application of nerve growth factor by gel increases formation of bone in mandibular distraction osteogenesis in rabbits. *Br J Oral Maxillofac Surg* 2010;48:515–9.
- [17] Yu X, Lv L, Zhang J, et al. Expression of neuropeptides and bone remodeling-related factors during periodontal tissue regeneration in denervated rats. *J Mol Histol* 2015;46:195–203.
- [18] D'Agostino A, Trevisiol LF, Bondi V, et al. Complications of orthognathic surgery: the inferior alveolar nerve. *J Craniofac Surg* 2010;21:1189–95.
- [19] Aizenbud D, Ciceu C, Hazan-Molina H, et al. Relationship between inferior alveolar nerve imaging and neurosensory impairment following bilateral sagittal split osteotomy in skeletal class III cases with mandibular prognathism. *Int J Oral Maxillofac Surg* 2012;41:461–8.
- [20] Gertjan M, Albert Z, Ron W, et al. Neurosensory disturbances one year after bilateral sagittal split osteotomy of the mandibula performed with separators: a multi-centre prospective study. *J Cranio-Maxillofac Surg* 2012;40:763–7.
- [21] Marcelo Silva M, Mario Francisco RG, Luis Augusto P. Cutaneous sensibility impairment after mandibular sagittal split osteotomy: a prospective clinical study of the spontaneous recovery. *J Oral Maxillofac Surg* 2012;70:696–702.
- [22] Nesari S, Kahnberg KE, Rasmusson L. Neurosensory function of the inferior alveolar nerve after bilateral sagittal ramus osteotomy: a retrospective study of 68 patients. *Int J Oral Maxillofac Surg* 2005;34:495–8.
- [23] Takazakura D, Ueki K, Nakagawa K, et al. A comparison of postoperative hypoesthesia between two types of sagittal split ramus osteotomy and intraoral vertical ramus osteotomy, using the trigeminal somatosensory-evoked potential method. *Int J Oral Maxillofac Surg* 2007;36:11–4.
- [24] Westermark A, Bystedt H, Von KL. Patients' evaluation of the final result of sagittal split osteotomy: is it influenced by impaired sensitivity of the lower lip and chin? *Int J Adult Orthodon Orthognath Surg* 1999;14:135–9.
- [25] Klemetti E, Collin HL, Forss H, et al. Mineral status of skeleton and advanced periodontal disease. *J Clin Periodontol* 1994;21:184–8.
- [26] Halling A, Persson GR, Berglund J, et al. Comparison between the Klemetti index and heel DXA BMD measurements in the diagnosis of reduced skeletal bone mineral density in the elderly. *Osteoporos Int* 2005;16:999–1003.
- [27] Grethe J, Marianne R. Alveolar bone loss in osteoporosis: a loaded and cellular affair? *Clin Cosmet Investig Dent* 2016;8:95–103.
- [28] Valerio CS, Trindade AM, Mazzeiro ET, et al. Use of digital panoramic radiography as an auxiliary means of low bone mineral density detection in post-menopausal women. *Dentomaxillofac Radiol* 2013;42: 20120059.
- [29] Yamada S, Uchida K, Iwamoto Y, et al. Panoramic radiography measurements, osteoporosis diagnoses and fractures in Japanese men and women. *Oral Dis* 2015;21:335–41.
- [30] Lv L, Wang Y, Zhang J, et al. Healing of periodontal defects and calcitonin gene related peptide expression following inferior alveolar nerve transection in rats. *J Mol Histol* 2014;45:311–20.
- [31] Hert J, Sklenská A, Lisková M. Reaction of bone to mechanical stimuli. 5. Effect of intermittent stress on the rabbit tibia after resection of the peripheral nerves. *Folia Morphologica* 1971;19:378–87.
- [32] Lv S, Liu H, Cui J, et al. Histochemical examination of cathepsin K, MMP1 and MMP2 in compressed periodontal ligament during orthodontic tooth movement in periostin deficient mice. *J Mol Histol* 2014;45:303–9.
- [33] Li J, Ahmed M, Bergstrom J, et al. Occurrence of substance P in bone repair under different load comparison of straight and angulated fracture in rat tibia. *J Orthop Res* 2010;28:1643–50.
- [34] Mauffrey C, Stacey S, York PJ, et al. Radiographic evaluation of acetabular fractures: review and update on methodology. *J Am Acad Orthop Surg* 2018;26:83–93.
- [35] Ito M. New methods for the evaluation of bone quality. Assessment of bone structural property using imaging. *Clin Calcium* 2017;27:1089–96.
- [36] Pwl TB, Mga DR, Maas M, et al. Is there a trend in CT scanning scaphoid nonunions for deformity assessment? – A systematic review. *Eur J Radiol* 2017;91:124–9.
- [37] Treece G, Gee A. Cortical bone mapping: measurement and statistical analysis of localised skeletal changes. *Curr Osteoporos Rep* 2018; 16:617–25.
- [38] Meazzini MC, Corno M, Novelli G, et al. Long-term computed tomographic evaluation of alveolar bone formation in patients with unilateral cleft lip and palate after early secondary gingivoalveoloplasty. *Plast Reconstr Surg* 2016;137:365e–74e.
- [39] Blessmann Weber JB, De MML, Azeredo F, et al. Volumetric assessment of alveolar clefts: a literature review. *J Oral Pathol Med* 2017;46:569–73.