

Just another chalazion?

Case

A 60-year-old Caucasian male noted a red lesion on the right lower eyelid which was growing over 3 months. He revealed previously treated cancers of the colon, ureter, and skin, all under control without recurrence. He also noted previous eyelid surgery 2 years ago revealing a well-differentiated sebaceous carcinoma. Family history disclosed multiple members with skin and colon carcinomas. On examination of the patient, visual acuity was 20/20 OD and 20/30 OS. There was an elevated, lightly colored cutaneous lesion on the right lower eyelid margin, temporal to the site of the previous biopsy and measuring 6 × 4 × 3 mm.

What is your next step?

- Shave biopsy of the lesion and follow up in 3 months.
- Wedge resection with immunohistochemical testing for Muir-Torre syndrome (MTS).
- Close monitoring with daily applications of hot compresses and topical corticosteroid ointment.
- Test for Gorlin-Goltz syndrome and proceed with photodynamic therapy.

Findings

A pentagonal eyelid resection of the mass [Fig. 1a and b] was performed. Histopathology revealed a low-grade sebaceous neoplasm most consistent with sebaceous adenoma. Immunohistochemical testing for DNA mismatch repair proteins in the excised tissue demonstrated normal staining for MLH1 [Fig. 1c] and abnormal absence (lack of staining, mutation) for MSH2 [Fig. 1d]. These findings were suggestive of underlying MTS.

Diagnosis

Sebaceous adenoma in the setting of MTS.

Correct Answer: B.

Discussion

MTS is a rare variant of Lynch syndrome found in <1% of the population. This syndrome is clinically suspected by the occurrence of both a visceral cancer, usually involving the colon or genitourinary system, along with cutaneous sebaceous neoplasms. This constellation of neoplasms is typically multiple, occur at an early age, and are generally histopathologically low grade.^[1] Colorectal carcinoma is the most common primary malignancy, found in approximately 51% of MTS patients and generally localized proximal to the splenic flexure.^[2] Other common internal malignancies include cancer of the endometrium, ovary, and uroepithelium which make up 24% of cases. Mismatch repair gene mutations in MLH1 and MSH2 spawn the development of various neoplasms.^[3]

Acknowledgements

Acknowledgment to Dr. Tatyana Millman and Dr. Ralph Eagle for their contributions to histopathology photomicrographs.

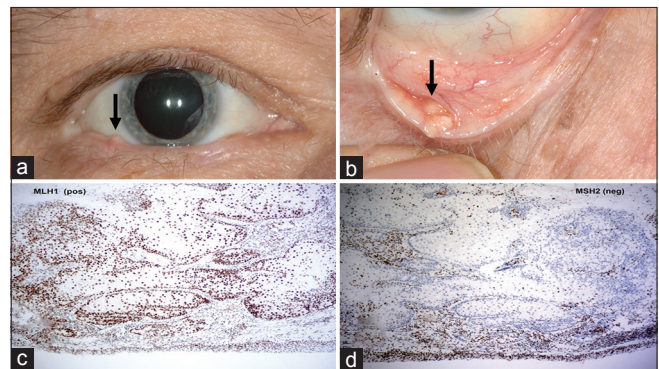


Figure 1: External photograph showing nodular lesion on the right lower lid margin (a) and invading the tarsus (b). Immunohistochemical staining for DNA mismatch repair proteins revealed normal staining for MLH1 (c) and lack of staining for MSH2 (d), suggestive of Muir-Torre syndrome

Declaration of patient consent

The authors certify that they have obtained all appropriate patient consent forms. In the form the patient(s) has/have given his/her/their consent for his/her/their images and other clinical information to be reported in the journal. The patients understand that their names and initials will not be published and due efforts will be made to conceal their identity, but anonymity cannot be guaranteed.

Financial support and sponsorship

Nil.

Conflicts of interest

There are no conflicts of interest.

References

- Lee JB, Litzner BR, Vidal CI. Review of the current medical literature and assessment of current utilization patterns regarding mismatch repair protein immunohistochemistry in cutaneous Muir-Torre syndrome-associated neoplasms. *J Cutan Pathol* 2017;44:931-7.
- Schwartz RA, Torre DP. The Muir-Torre syndrome: A 25-year retrospect. *J Am Acad Dermatol* 1995;33:90-104.
- Jagan L, Zoroquiain P, Bravo-Filho V, Logan P, Qutub M, Burnier J, et al. Sebaceous adenomas of the eyelid and Muir-Torre syndrome. *Brti J Ophthalmol* 2015;99:909-13.

Jonathan McLaughlin, Sara E Lally, Carol L Shields

Oncology Service, Wills Eye Hospital, Thomas Jefferson University, Philadelphia, PA, USA

Correspondence to: Dr. Carol L Shields,

Oncology Service, Wills Eye Hospital, Thomas Jefferson University, Philadelphia, PA - 19107-5109, USA.

E-mail: carolshields@gmail.com

Access this article online

Quick Response Code:



Website:

www.ijjo.in

DOI:

10.4103/ijjo.IJO_18_19

This is an open access journal, and articles are distributed under the terms of the Creative Commons Attribution-NonCommercial-ShareAlike 4.0 License, which allows others to remix, tweak, and build upon the work non-commercially, as long as appropriate credit is given and the new creations are licensed under the identical terms.

For reprints contact: reprints@medknow.com

Cite this article as: McLaughlin J, Lally SE, Shields CL. Just another chalazion? *Indian J Ophthalmol* 2019;67:195.