

Available online at www.sciencedirect.com

ScienceDirect

journal homepage: www.elsevier.com/locate/radcr

Case Report

Common celiomesenteric-renal trunk – First description of a rare combined variation of abdominal visceral arteries ☆

Fabian Hack, MD*, Robert Steinbach, MD, Gerard Mertikian, MD, Friedrich M. Lomoschitz, MD

Department of Radiology, Klinik Hietzing, Wolkersbergenstraße 1, 1130 Vienna, Austria

ARTICLE INFO

Article history:

Received 9 December 2021

Revised 9 March 2022

Accepted 12 March 2022

Keywords:

Cardiovascular radiology

Arc of Riolan

Celiac trunk

Abdominal aorta

Aortic branches

ABSTRACT

Different variations and anomalies are known of the abdominal visceral branches of the aorta, whereas concomitant variations including both renal and inferior phrenic arteries are exceedingly rare. We report the case of a 28-year-old female, presenting with stomachache, nausea and emesis. Computer tomography revealed a large common trunk consisting of the celiac trunk, both inferior phrenic and renal arteries and the superior mesenteric artery. Due to a hypoplastic aorta a wide Arc of Riolan was present. This is the first description of a unique variation of a common celiomesenteric-renal trunk, emphasizing the need for further classification of the visceral vascularity.

© 2022 The Authors. Published by Elsevier Inc. on behalf of University of Washington.

This is an open access article under the CC BY-NC-ND license (<http://creativecommons.org/licenses/by-nc-nd/4.0/>)

Introduction

In 2010, Song et al. [1] evaluated the pattern of abdominal aortic branches in 5002 patients, revealing a normal anatomy in 89,1% of the cases, defined by a trifurcating celiac trunk giving rise to the left gastric artery, the common hepatic and splenic arteries; the superior mesenteric artery arising independently from the abdominal aorta. Several different combinations of the branches are reported, but a celiomesenteric trunk is described in only 1,06% of the cases. Involvement of the renal arteries being exceedingly rare [2].

The Arc of Riolan, also known as the meandering mesenteric artery, connects the superior mesenteric artery with the inferior mesenteric artery [3]. It plays a dominant role in cases of insufficient visceral perfusion, due to stenosis or occlusion of the superior mesenteric artery, colon cancer and ulcerative colitis [4].

Case

We report the case of a 28-year-old female, presenting to the emergency room with a longer than 12 hours lasting history

☆ Competing interests: The authors have declared that no competing interests exist.

* Corresponding author.

E-mail addresses: fabian_hack@hotmail.com (F. Hack), robert.steinbach@gesundheitsverbund.at (R. Steinbach), gerard.mertikian@gesundheitsverbund.at (G. Mertikian), friedrich.lomoschitz@gesundheitsverbund.at (F.M. Lomoschitz).
<https://doi.org/10.1016/j.radcr.2022.03.048>

1930-0433/© 2022 The Authors. Published by Elsevier Inc. on behalf of University of Washington. This is an open access article under the CC BY-NC-ND license (<http://creativecommons.org/licenses/by-nc-nd/4.0/>)

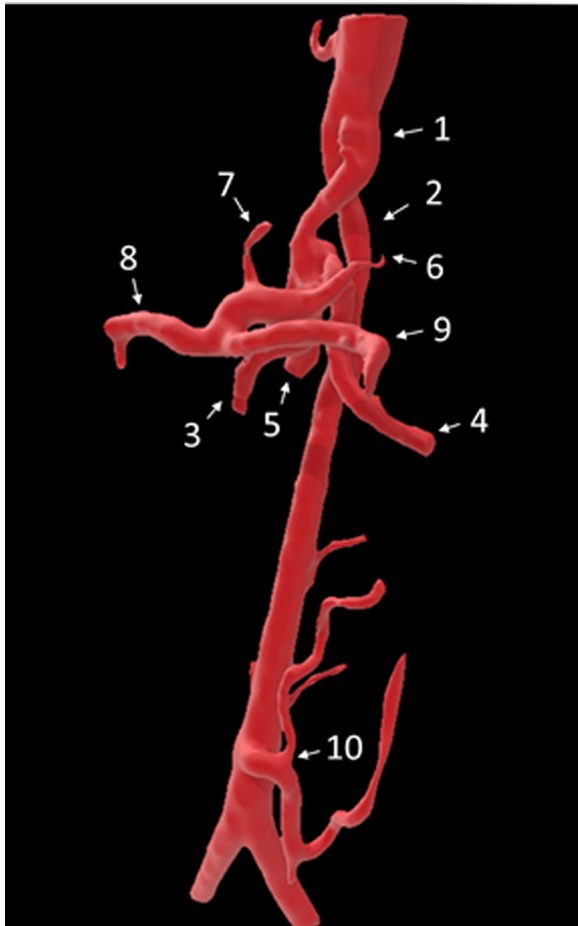


Fig. 1 – 3D view of the abdominal aorta; 1: Common celiomesenteric-renal trunk; 2: narrowed abdominal aorta; 3: superior mesenteric artery; 4: left renal artery; 5: right renal artery; 6: left inferior phrenic artery; 7: left gastric artery; 8: common hepatic artery; 9: splenic artery; 10: inferior mesenteric artery.

of stomachache, nausea and emesis. The patient was afebrile and hemodynamically stable. The initial clinical examination showed diffuse abdominal pain with marked tenderness in the right upper quadrant. Blood samples showed elevated white blood cell count and liver enzymes.

Ultrasonography revealed a subtle dilatation of the intra- and extrahepatic bile ducts and gallstones in absence of gall bladder inflammation, notably reporting hypoplasia of the abdominal aorta with an abnormal configuration.

A CT-scan of the abdomen in both arterial and venous phases was performed, which demonstrated a unique configuration of the visceral aortic branches (Fig. 1). The common trunk comprised a large bore celiac trunk, 12 mm in diameter, emulating a duplication of and running parallel to the hypoplastic aorta, which at its narrowest measured 4 mm. The first paired vessels that leave the trunk are the right and left renal arteries, following which a cranially oriented branch gives rise to both inferior phrenic arteries and subsequently

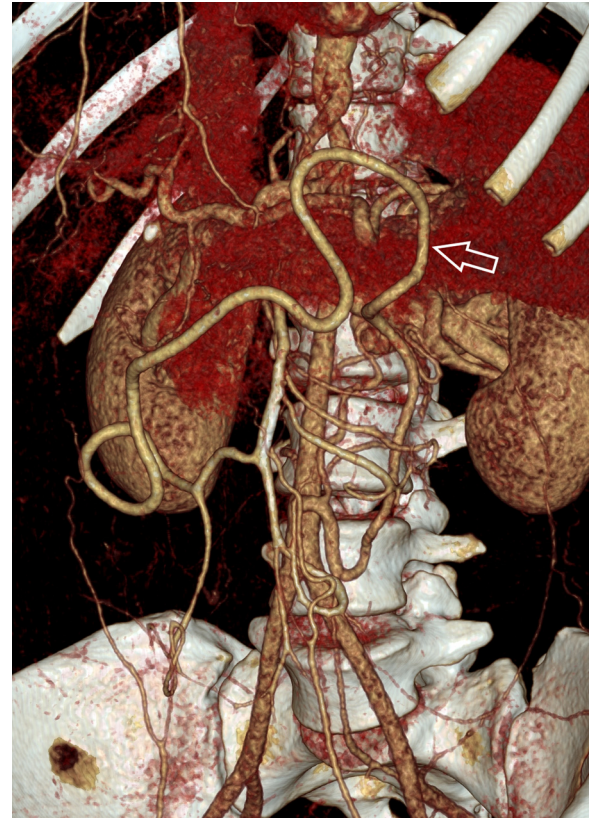


Fig. 2 – 3D view: Expansion of the Arc of Rioloan (arrow) due to hypoplasia of the infrarenal aorta.

forms the actual coeliac trunk, where the gastric, the common hepatic and the splenic arteries originate. The superior mesenteric artery leaves the common trunk as the last vessel. The Arc of Rioloan, which is widely patent, reflects the hypoperfusion of the left sided colon, and forms the anastomosis between the superior and inferior mesenteric arteries.

No further abnormal findings regarding the abdominal organs were detected in the CT scan. The complaints of the patient were therefore solely attributed to the gallstones. With no further pathologic findings present, she was discharged from the emergency department and was recommended a follow up sonography.

Discussion

In 2012 Connolly et al. [2] presented the case of a 14-year-old girl with a large common celiomesenteric-renal trunk in combination with a narrowed abdominal aorta. The main trunk gave rise to left renal, but contrary to this case, the right renal artery originated between the celiac trunk and the superior mesenteric artery as the third branch. Involvement of the inferior phrenic arteries was not described.

Another case with a combined trunk, but involving only 1 renal artery has been reported by Daraghmeah et al. [5] in 2014.

To our knowledge and after review of the literature this is the first description of a unique variation of a common celiomesenteric-renal trunk, including the origin of both renal arteries arising as the first branches from a large common trunk with a concomitant involvement of both inferior phrenic arteries. In addition, a strong Arc of Riolan, subsequent to a hypoplastic infrarenal aorta was found (Fig. 2).

This report and the case described by Connolly et al. [2] show the existence of different variations of an exceedingly rare common celiomesenteric-renal trunk and imply the need of accurate anatomic knowledge of aortic variations. A correct radiologic description and further classification of the visceral vascularity can help to better plan interventions such as abdominal surgery, embolization therapy and repair of thoracoabdominal aortic aneurysms to improve clinical outcome.

Patient consent

Patient consent was obtained for the publication of this Case Report.

REFERENCES

- [1] Song SY, Chung JW, Yin YH, Jae HJ, Kim HC, Jeon UB, et al. Celiac axis and common hepatic artery variations in 5002 patients: systematic analysis with spiral CT and DSA. *Radiology* 2010;255(1):278–88 PMID: 20308464. doi:[10.1148/radiol.09090389](https://doi.org/10.1148/radiol.09090389).
- [2] Connolly PH, Meltzer AJ, Gallagher KA, Dayal R. A visceral aortic branch anomaly presenting with a common celiomesenteric-renal trunk. *J Vasc Surg* 2013;57(6):1675. PMID: 23719039. doi:[10.1016/j.jvs.2012.08.097](https://doi.org/10.1016/j.jvs.2012.08.097).
- [3] Gourley EJ, Gering SA. The meandering mesenteric artery: a historic review and surgical implications. *Dis Colon Rectum* 2005;48(5):996–1000. PMID:15933893. doi:[10.1007/s10350-004-0890-7](https://doi.org/10.1007/s10350-004-0890-7).
- [4] Xie Y, Jin C, Zhang S, Wang X, Jiang Y. CT features and common causes of arc of Riolan expansion: an analysis with 64-detector-row computed tomographic angiography. *Int J Clin Exp Med* 2015;8(3):3193–3201. PMID: 26064208;PMCID: [PMC4443042](https://pubmed.ncbi.nlm.nih.gov/PMC4443042/).
- [5] Daraghmeah A, Feldman D, Barbat J, Zughaib M. Ectopic right renal artery originating from anomalous common celio-mesenteric trunk: multifaceted imaging approach. *Tex Heart Inst J* 2014;41(6):673–674. PMID: 25593541;PMCID: [PMC4251348](https://pubmed.ncbi.nlm.nih.gov/PMC4251348/). doi:[10.14503/THIJ-13-3453](https://doi.org/10.14503/THIJ-13-3453).