

Utilization of the Pedicled and Free Fibula Flap for Ankle Arthrodesis

Rohun Gupta, BA*
 Mitchell Pfennig, BS*
 James Gannon, BS*
 Devin Young, BA*
 Monik Gupta, BA†
 Sean Chaiyasate‡
 Gretchen Stieg, MD§
 Brian G. Kissel, DPM, MBA,
 FAFAS¶
 Erik C. Kissel, DPM, FAFAS¶
 Paul Fortin, MD**
 Kongkrit Chaiyasate, MD***

Background: Ankle arthrodesis has become a common surgical procedure for individuals with end-stage ankle arthritis, chronic infection, and bony misalignment. Although arthrodesis is typically managed with arthrodesis in situ or realignment, reconstruction may be utilized for patients with more complicated cases that involve metatarsal defects. Our institution utilizes both the pedicled and free fibula flaps for surgical management pertaining to ankle arthrodesis. Our study looks to evaluate the work of a single plastic surgeon and identify patient postoperative outcomes.

Methods: A retrospective chart review was conducted at Beaumont Health System, Royal Oak, for patients who underwent ankle arthrodesis with a pedicled fibula flap for nonunion or avascular necrosis of the talus between the years 2014 and 2022. Demographic data, operative details, complications, medical comorbidities, and patient outcomes were retrospectively gathered and analyzed.

Results: A total of six patients were isolated, with three patients undergoing a free fibula approach and three patients undergoing the pedicled fibula approach. All patients were found to have tolerated the procedure well and had no intraoperative complications. In addition, all patients had clinically viable flaps and were satisfied with their surgical result.

Conclusions: Both free and pedicled free fibula flaps may be used effectively in the management of ankle arthrodesis in patients who have failed prior therapy. In our study, free fibula flaps were utilized in a medial approach, while the pedicled fibula flap was utilized in a lateral approach. With the right expertise and patient population, the free and pedicled fibula flaps can be highly successful in the repair of ankle defects. (*Plast Reconstr Surg Glob Open* 2022;10:e4670; doi: 10.1097/GOX.0000000000004670; Published online 22 November 2022.)

INTRODUCTION

Ankle arthrodesis is a surgical procedure consisting of fusion of two or more bones to the ankle.¹ Ankle arthrodesis was first described by Albert² in 1879 as a surgical technique pertaining to pediatric knee and ankle fusion. Although the surgical principles guiding arthrodesis have

*From the *Oakland University William Beaumont School of Medicine, Rochester, Mich.; †The University of Toledo Health Science Campus, Toledo, Ohio.; ‡International Academy, Bloomfield Hills, Mich.; §Department of Plastic and Reconstructive Surgery, Wayne State University, Detroit, Mich.; ¶Department of Podiatric Surgery, Beaumont Health Systems, Royal Oak, Mich.; ||Department of Orthopedic Surgery, Beaumont Health Systems, Royal Oak, Mich.; and ***Department of Plastic Surgery, Beaumont Health Systems, Royal Oak, Mich.*

Received for publication August 7, 2022; accepted September 27, 2022.

Copyright © 2022 The Authors. Published by Wolters Kluwer Health, Inc. on behalf of The American Society of Plastic Surgeons. This is an open-access article distributed under the terms of the Creative Commons Attribution-Non Commercial-No Derivatives License 4.0 (CCBY-NC-ND), where it is permissible to download and share the work provided it is properly cited. The work cannot be changed in any way or used commercially without permission from the journal.

DOI: 10.1097/GOX.0000000000004670

remained the same, there have been drastic advances in fixation modalities, including the utilization of screw fixation, external fixation, and minimally invasive approaches.³ Ankle arthrodesis has become a critical procedure in patients with end-stage ankle arthritis, chronic infection, and bony misalignment.^{4,5} Other conditions include rheumatoid arthritis, osteonecrosis, gout, and idiopathic arthritis.^{6,7}

Studies have found that type of fracture, open injuries, medical comorbidities, and avascular necrosis are commonly associated with ankle nonunion after arthrodesis.⁸ Some sources have found that nonunion postankle arthrodesis has ranged from 0% to 40%.⁹ Patients with persistent nonunion may require multiple attempts at arthrodesis, which can lead to substantial decreases in bone volume.¹⁰ Furthermore, it has been determined

Disclosure: *The authors have no financial interest to declare in relation to the content of this article.*

Related Digital Media are available in the full-text version of the article on www.PRSGlobalOpen.com.

that age, technique, and history of multiple arthrodesis operations were not associated with increased rate of non-union.⁸ In addition, due to limited collateral blood supply in the ankle, studies have determined that fractures of the talar neck may lead to avascular necrosis.⁹

There are several surgical techniques that have been utilized for arthrodesis. Ankle arthrodesis is broken down into two general categories: arthrodesis in situ and realignment.¹¹ For cases with ankle arthrodesis in situ, the procedure can be performed adequately with arthroscopy or screw fixation with arthrotomy.^{12,13} Although minimally invasive, arthroscopy requires increased provider experience and special equipment and has been reported to be more demanding than other arthrodesis techniques.¹⁴ Also, Morash et al¹⁵ have found that total ankle arthroplasties tend to have higher reoperation rates when compared with that of ankle arthrodesis. On the other hand, several approaches have been utilized for open arthrodesis, including an anterior, posterior, medial, lateral, and a combined medial and lateral approach.

Autologous bone grafting is a procedure that utilizes the patient's own bony tissue in order to restore native structure and function to a recipient site.¹⁶ Two main categories of grafting include vascularized and nonvascularized bone grafts. Although more technically challenging, the vascularized flap demonstrates superior healing compared with the nonvascularized flap, likely due to preserving osteocyte life and function in the donor tissue.¹⁷ A study comparing bone grafts used for mandibular reconstruction in cancer patients found higher rates of osseointegration and lower rates of reoperation for patients receiving vascularized grafts.¹⁸ These techniques have also proven successful in lower extremity reconstruction. A review by Beris et al¹⁹ outlined the use of the fibula bone as a vascularized graft and its usage for reconstruction of the lower limb in cases of malignancy, infection, and trauma. The authors emphasized the superiority of the vascularized graft over the nonvascularized graft in reconstructing large defects (>6 cm).¹⁹ Despite being a long-trusted technique, prior surgery, infections, or other insults can create bone defects, which worsen patient outcomes.²⁰ Several types of vascularized flaps have proven successful, including the free fibula,²¹ the pedicled fibula,²² the medial femoral condyle,²³ and the free iliac crest.²⁴ Although some authors have shown their preference to certain grafts, to our knowledge no studies have directly compared these flaps in ankle arthrodesis salvage procedures.²⁵

Our institution utilizes both the pedicled and free fibula flaps for surgical management pertaining to ankle arthrodesis. Our study looks to evaluate the work of an experienced plastic surgeon regarding patient outcomes undergoing reconstruction of the ankle.

METHODS

A retrospective analysis of all patients who underwent surgery between 2014 and 2022 for salvage ankle arthrodesis with vascularized bone grafting by the senior surgeon was conducted. Demographic data, operative details, complications, medical comorbidities, and

Takeaways

Question: Should surgeons look to utilize the pedicled or free fibula flap for ankle arthrodesis?

Findings: Both pedicled and free fibula flaps lead to successful operative outcomes after a detailed preoperative analysis is conducted.

Meaning: In patients where limited reconstructive techniques are possible, physicians should look to utilize the pedicled or free fibula flap for ankle arthrodesis.

patient outcomes were retrospectively gathered and analyzed. Six patients who met the inclusion criteria were identified. Each patient underwent computed tomography angiography (CTA) of bilateral lower extremities as part of preoperative workup. Surgical risks were discussed at length, and informed written consent was obtained before all surgical procedures. All procedures were performed under general anesthesia unless otherwise stated in the patient descriptions. Ipsilateral fibula flaps were preferred regardless of preoperative plan for the use of a pedicled or free flap. If the ipsilateral fibula was not available due to history of surgery or injury, the contralateral fibula was utilized.

Free fibula flaps were harvested in the standard surgical fashion. Osteocutaneous rather than pure osseous flaps were routinely used with extra skin to prevent compression of the vascular pedicle. Choice of end-to-end or end-to-side anastomosis was left to the surgeon's discretion at the time of operation. For pedicled fibula flaps, the initial flap dissection was performed in a similar surgical fashion. The peroneal artery was dissected to its take-off from the tibioperoneal trunk to maximize pedicle length. To maximize bony length of the flap, rather than performing a distal osteotomy, the lateral malleolus was separated from tibia and talus completely, and the synovial joint tissues were completely excised. Of note, no skin paddle was harvested with pedicled flaps as there was no anastomosis to protect. Once the fibula bone flap was completely mobilized, the pedicle flap could be mobilized distally to the level of the midcalcaneus. (See Video [online], which demonstrates the rotational arc of the harvested pedicle fibula flap from two of our patients.) For both free and pedicled fibula flaps, the fibula was shaped and rigidly fixated to the surrounding bone by orthopedic or podiatric surgeons.

RESULTS

Free Fibula Approach

Case 1

This is a 20-year-old White woman with a medical history of hypothyroidism, current tobacco use, and spinal fusion complicated by Charcot neuroarthropathy of the right ankle, nontraumatic talus fracture, and avascular necrosis of the talus (Table 1). The patient had undergone prior reconstructive ankle surgery in 2015 followed by ankle arthrodesis with nonvascularized fibula bone

Table 1. Overview of Cases

Case	Age/Gender	Indication	Procedure
Case 1	20 F	Failed right ankle arthrodesis + fibular osteotomy for charcot neuropathy and nonunion of subtalar joint	Free fibula flap for lateral defect
Case 2	39 F	Right talus and right medial malleolus fracture nonunion s/p ORIF	Free fibula flap for medial defect
Case 3	40 M	Right limb salvage s/p chronic refractory osteomyelitis of right distal tibia	Free fibula flap for medial defect
Case 4	52 F	Nonunion following multiple failed left ankle procedures for osteoarthritis	Pedicle fibula flap for lateral defect
Case 5	51 F	Avascular necrosis of left distal tibia and posterior calcaneus	Pedicle fibula flap for lateral defect
Case 6	40 M	Distal tibia osteonecrosis s/p ankle fracture ORIF complicated by septic arthritis	Pedicle fibula flap lateral defect

graft from the left leg in 2019 (Fig. 1). She presented to our clinic with chronic right ankle pain and persistent nonunion of the subtalar joint. Despite the lateral nature of her bony defect, due to her previous ankle fusions, a pedicled fibula flap was not possible, and she was recommended a free fibula flap reconstruction. After obtaining informed consent, the patient underwent revision of the right ankle arthrodesis with hardware removal, external fixator placement, and ipsilateral osteocutaneous free fibula flap (Figs. 2, 3). There were no postoperative complications, and the patient was discharged on postoperative day 8. At 2-month follow-up, the flap was found to be healing well.

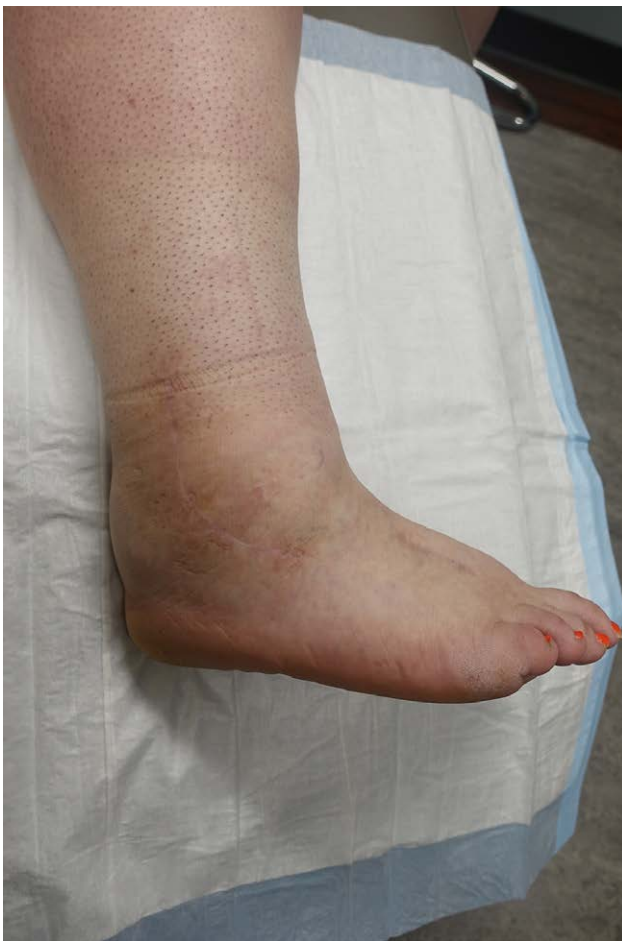

Fig. 1. Case 1. Preoperative image of a patient with prior right ankle reconstruction presenting with chronic right lower extremity pain due to avascular necrosis of the talus.

Case 2

This is a 39-year-old White woman with a medical history of systemic lupus erythematosus, Raynaud's phenomenon, diabetes mellitus, hypothyroidism, and anemia, who presented with nonunion of the right talus and medial malleolus (Table 1). She had previously undergone open reduction internal fixation (ORIF) of a talus fracture including medial malleolar osteotomy, and subsequently developed medial malleolar nonunion that persisted after nonvascularized bone grafting (Fig. 4). The patient was recommended vascularized free fibula flap due to the medial nature of the defect. Once the risks and benefits were discussed, the patient agreed to proceed with surgical intervention. The patient underwent hardware removal from the right tibia and right talus, excision of medial malleolar fracture fragment, fusion of distal tibiofibular joint, ankle fusion, and application of external multiplane

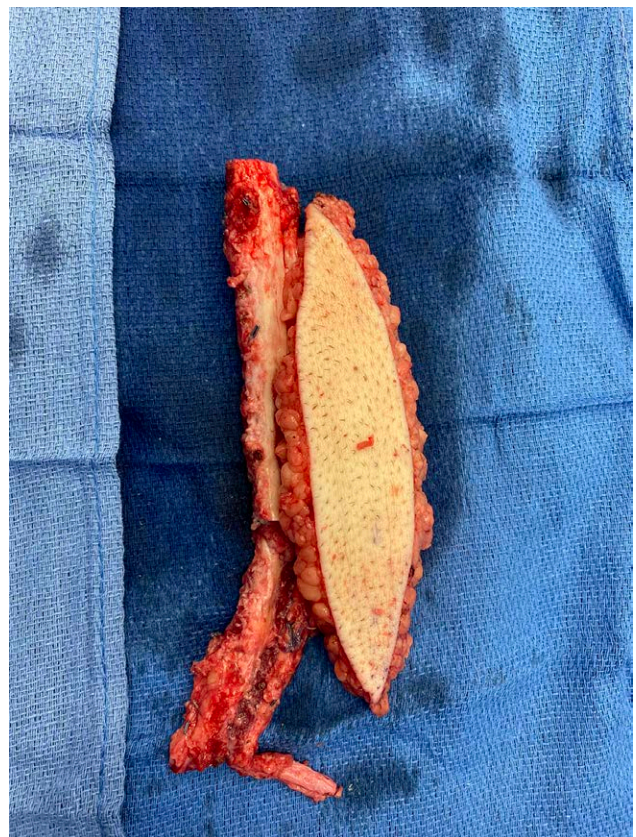

Fig. 2. Case 1. Intraoperative image demonstrates right osteocutaneous free flap utilized for ankle arthrodesis.

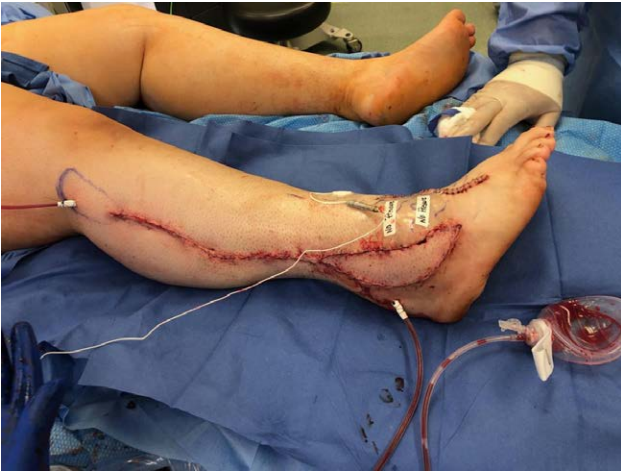

Fig. 3. Case 1. Intraoperative image of right ankle revision and tarsal arthrodesis with right fibula osteocutaneous free flap and hardware removal before external fixator placement.

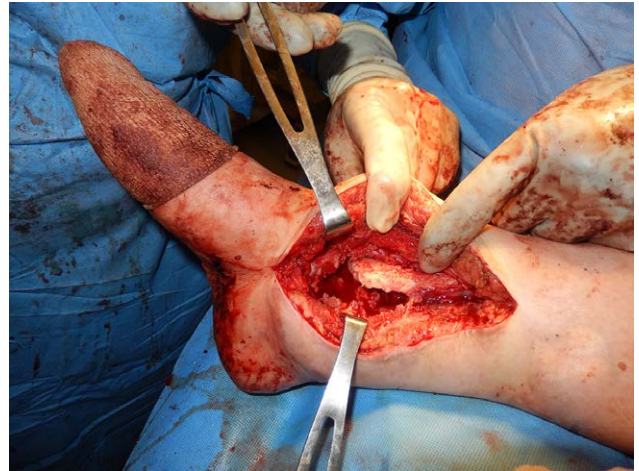


Fig. 5. Case 2. Intraoperative image demonstrates preparation of the recipient site by creation of a bone slot for free fibula flap to be placed.

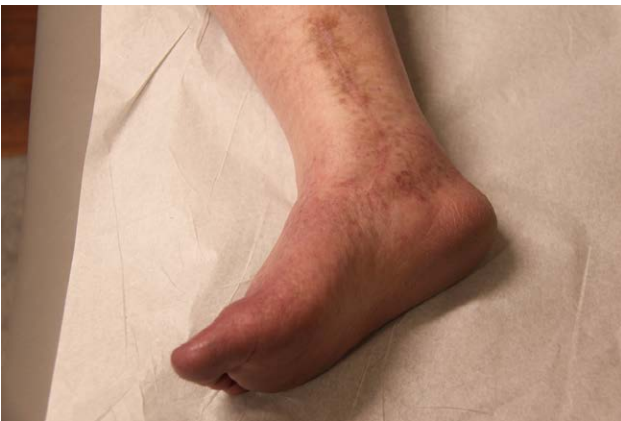

Fig. 4. Case 2. Preoperative image of a patient with prior right ankle fracture status after ORIF with subsequent development of medial malleolar nonunion.

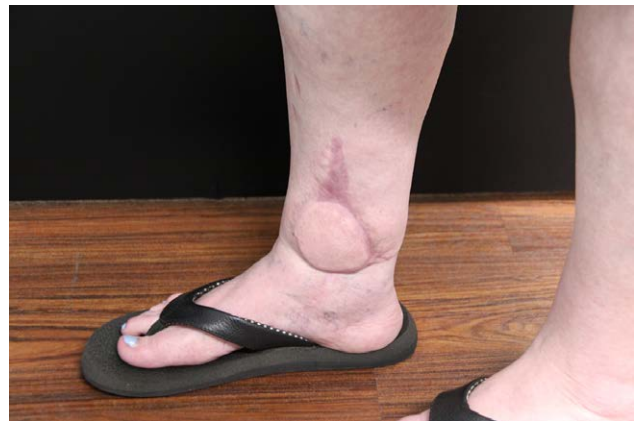

Fig. 6. Case 2. One-year follow-up demonstrates that the flap has healed without complications and that the patient is able to successfully bear weight on her right lower extremity.

fixation to the ankle (Fig. 5). In addition, the patient had subsequent reconstruction with a fibula osteocutaneous flap and Z-plasty of the right leg. She developed venous congestion on postoperative day 1 and required take-back to the operating room and revision of the venous anastomosis due to a kink. The patient was discharged after 6 days and presented for follow-up appointment 2 weeks later, where the flap was found to be healing well. The patient followed up at 1 year and was able to bear weight on the ankle (Fig. 6).

Case 3

This is a 40-year-old African American man with a history of smoking and a right ankle pilon fracture 4 years prior that was initially managed with ORIF and ankle fusion (Table 1). The patient then developed osteomyelitis, which required washout, removal of four inches of infected tibia, placement of antibiotic spacer, and soft tissue coverage with anterolateral thigh flap that later dehisced due to recurrent infection (Fig. 7). The

patient presented at our clinic to discuss possible bone grafting options for limb salvage. He was counseled on options including risks and benefits of each and decided to proceed with vascularized bone grafting. The patient underwent removal of prior implants, debridement of tibia to healthy bone, and placement of external fixator with orthopedic surgery. Two days later, reconstruction of the right distal tibia with free fibula osteocutaneous flap from the contralateral leg was performed (Fig. 8). He tolerated the procedure well with no immediate postoperative complications. Six months later, the patient was found to have nonunion at the distal fibula and talus junction. He later underwent multiple debridements and eventually a salvage operation with a chimeric medial femoral condyle free flap using an interpositional vein graft (Figs. 9, 10). The patient tolerated the procedure well, and there were no intraoperative or postoperative complications. The patient followed up 2 weeks later, and he reported that he was doing well with a clinically viable flap on examination.

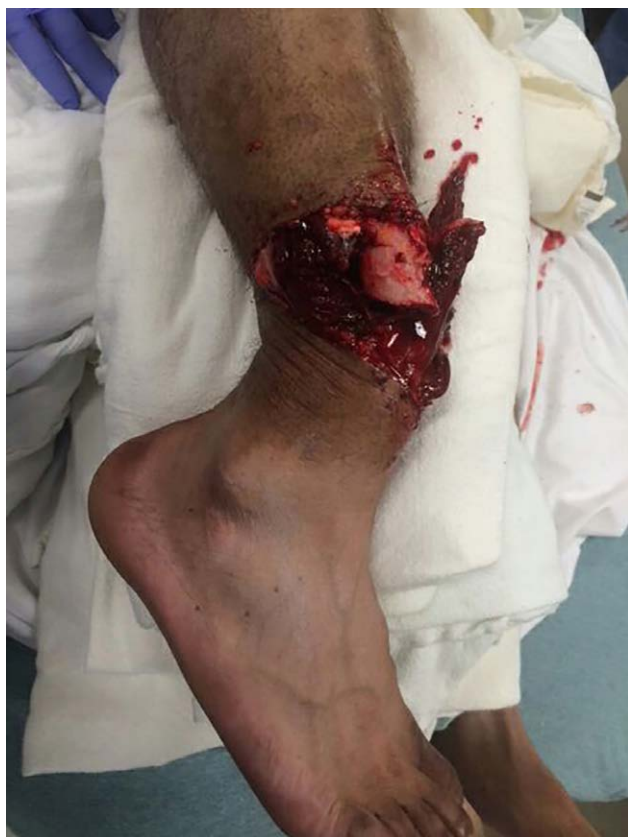

Fig. 7. Case 3. Preoperative image of a patient who presents with initial right open pilon fracture before surgical intervention with ORIF. He subsequently developed infected hardware and osteomyelitis, which led to hardware removal, bone debridement, and placement of antibiotic spacer.

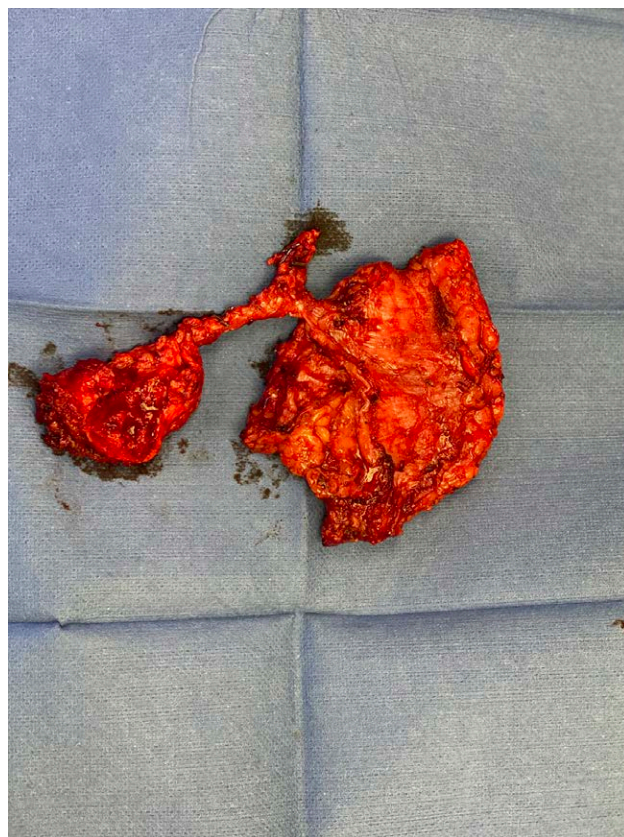

Fig. 9. Case 3. Intraoperative image of the chimeric medial femoral condyle free flap.

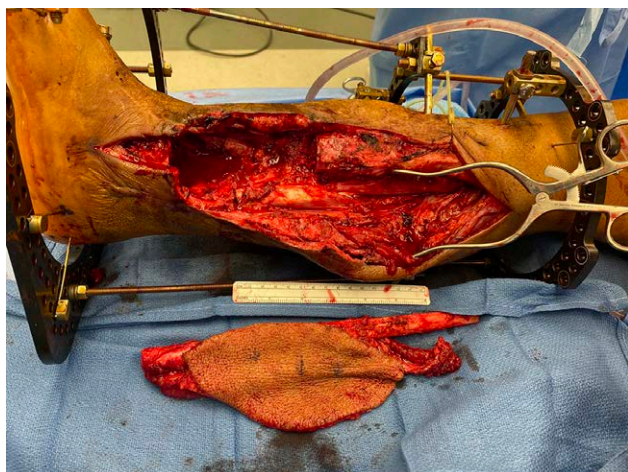


Fig. 8. Case 3. Intraoperative image demonstrates removal of the antibiotic bone spacer and preparation of the recipient site for free fibula flap.

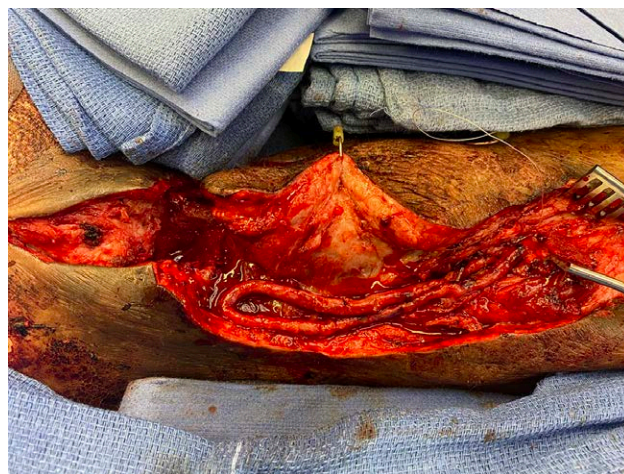


Fig. 10. Case 3. Intraoperative image demonstrates creation of an arteriovenous loop.

Pediced Fibula Approach

Case 4

This is a 52-year-old Hispanic woman with a medical history of left ankle osteoarthritis for the past 10 years (Table 1). To correct her ankle and foot pain, the patient

reported that she had previously undergone seven procedures, including hardware implantation, bone grafting, and neurectomy. She developed ankle nonunion after her prior procedures and had ongoing pain requiring daily narcotic use. After discussing treatment options, including risks and benefits, the patient wished to proceed with pediced left fibula vascularized bone flap and left ankle arthrodesis in conjunction with podiatry

(Fig. 11). (See Video [online], which demonstrates the rotational arc of the harvested pedicle fibula flap from two of our patients.) The fibula was burred and shaped to create tibiotalar fusion. The patient was discharged 13 days after the procedure with no complications. At her 2-week follow-up visit, the patient demonstrated appropriate wound healing, pain control, and neurologic function (Fig. 12).

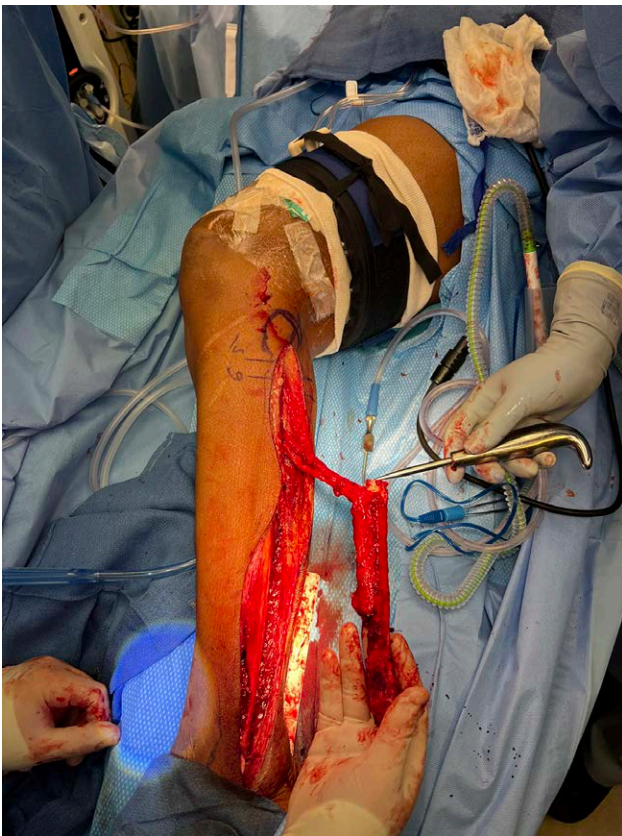


Fig. 11. Case 4. Intraoperative image of the harvested left fibula rotational bone flap that would be utilized for ankle arthrodesis.

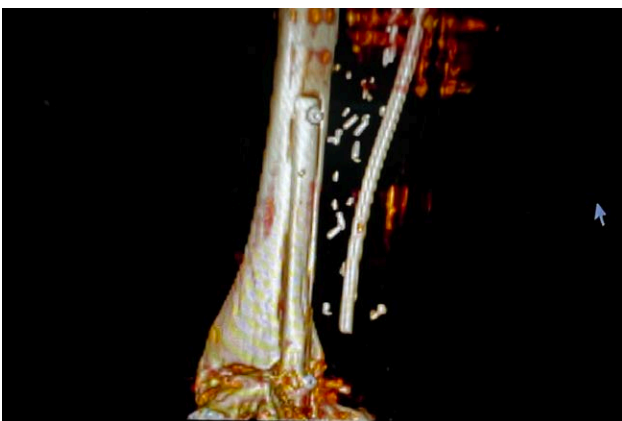

Fig. 12. Case 4. Postoperative three-dimensional CT scan demonstrates placement of the fibula flap in the bone slot for ankylosis.

Case 5

This is a 51-year-old White woman with a medical history of myelodysplastic syndrome and stem cell transplant requiring extended dexamethasone course who presented to our office with a 9-month history of left ankle swelling and pain (Table 1). CT and CTA of the left ankle revealed evidence of avascular necrosis in the distal tibial and posterior calcaneus. Various treatment options were discussed, and the patient elected to undergo operative repair involving left tibiotalar arthrodesis using pedicled vascularized fibula bone graft, application of an external fixator, and left-leg tissue rearrangement with the assistance of podiatry (Fig. 13). (See Video [online], which demonstrates the rotational arc of the harvested pedicle fibula flap from two of our patients.) There were no intraoperative complications, and her hospital course was uneventful. She was discharged 4 days postoperatively and followed up after 1 month. At her follow-up appointment, the patient had minimal pain and swelling, and a physical examination demonstrated a clinically viable flap (Fig. 14).

Case 6

This is a 40-year-old White man with a medical history of an open right ankle fracture treated with ORIF. One year following surgery, the patient had complications of septic arthritis and subsequently underwent hardware removal

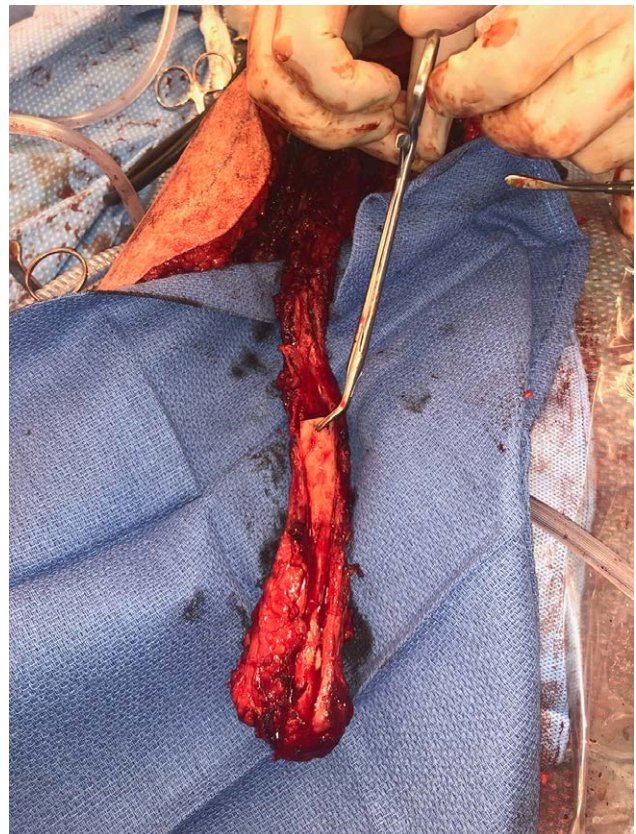

Fig. 13. Case 5. Intraoperative image of the harvested left fibula rotational bone flap that would be utilized for ankle arthrodesis.

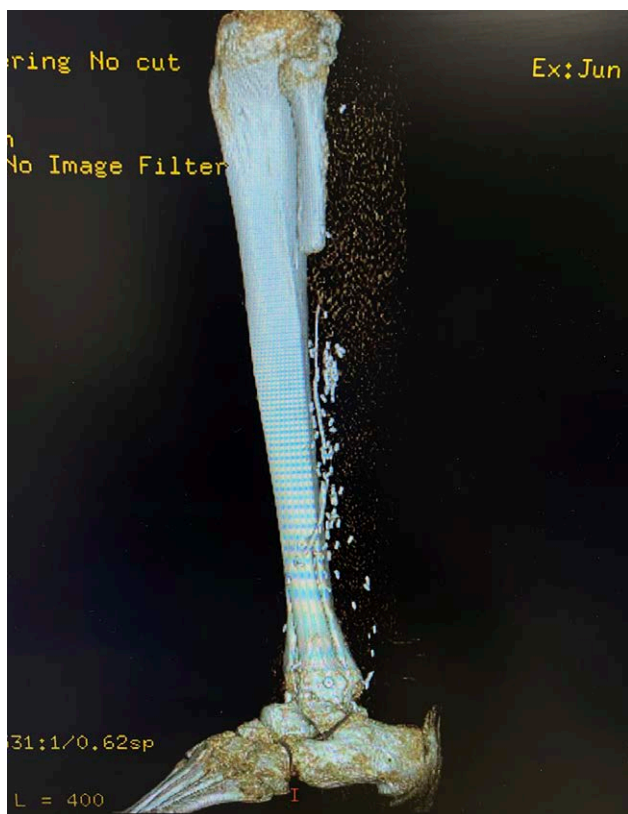

Fig. 14. Case 5. Postoperative three-dimensional CT scan demonstrates placement of the fibula flap in the bone slot for ankylosis.

and washout. The patient continued to have pain postoperatively. A follow-up CT 1 year later demonstrated osteonecrosis of the right distal tibia and incongruity of the right ankle mortise. CT angiogram of the right lower extremity demonstrated widely patent two-vessel runoff, distal posterior tibial artery occlusion, and a plantar arch reconstituted by the distal peroneal artery. Given the imaging and clinical findings, treatment options were discussed with the patient who agreed to proceed with staged right ankle arthrodesis with a combined right fibula pedicled flap. To ensure there was no remaining infectious process, the patient was first taken to the operating room with podiatry for debridement of necrotic portions of tibia and talus and implantation of an antibiotic spacer. Two weeks later, the patient underwent removal of the antibiotic spacer, right ankle reconstruction utilizing right pedicled fibula flap, and placement of a multiplane external fixator (Fig. 15). The patient tolerated the procedure well and was admitted to the surgical ICU postoperatively for flap maintenance. The rest of the hospital course was uneventful with no complications, and the patient was discharged on postoperative day 4.

DISCUSSION

The limited collateral blood supply of distal lower extremity has led to a high incidence of complication after conventional ankle arthrodesis, including nonunion requiring revision, hardware failure requiring removal, and below-the-knee amputation.²⁶ These incidences are more frequent in high-risk cases of ankle arthrodesis such

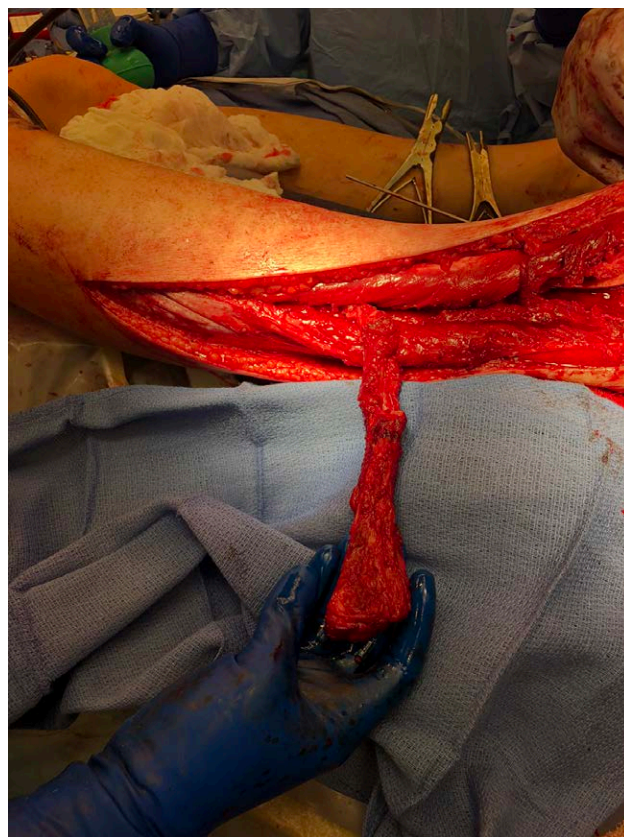


Fig. 15. Case 6. Intraoperative image of the harvested left fibula rotational bone flap that would be utilized for ankle arthrodesis.

as trauma, osteomyelitis, and tumor due to the additional presence of poor soft tissue quality and bone loss. In these situations, vascular bone grafts have been advocated for as a means of reconstruction or salvage. In comparison to nonvascular autografts, vascular bone grafts provide immediate vascularity for osteocyte preservation and accelerated healing rates.²⁷

Our six cases featured large bone defects, multiple prior attempts at fixation, and previous failed nonvascularized bone grafts that indicated use of a vascular bone graft. Several techniques for vascular bone grafting have been used for ankle arthrodesis such as the free medial femoral condyle flap, free iliac crest flap, pedicled fibula flap, and free fibula flap. Bishop et al²⁸ compared free fibula and iliac crest flaps, finding the blood supply to the skin paddle for iliac crest flaps to be unreliable. Yajima et al²² utilized a free fibula flap in seven cases, finding it superior to other grafts such as the iliac crest given the ease of harvesting the peroneal vessels along the fibula and the nature of the skin being more similar to the recipient site along the ankle. Most recently, Piccolo et al²¹ demonstrated 0% nonunion and 0% amputation rates in a cohort of 12 patients undergoing free vascularized fibula grafts for salvage ankle arthrodesis. In our patient population, there were no incidences of nonunion or amputation through the utilization of a pedicle or free fibula flap.

At our facility, we prefer the fibula flap based on its structural characteristics, including its long, thin shape,

mechanical strength, consistent blood supply with long pedicle, and ease of harvest, making it suitable for reconstructing ankle bone defects.²⁹ Iliac crest flaps and medial femoral condyle flaps have shorter pedicles, more difficult dissection, and significantly less bony volume that can be harvested making them less ideal options. When harvesting fibula flaps, the procedure remains the same for both free and pedicled flaps except that microvascular anastomosis is required for the free flap, which can be more technically challenging.³⁰ Additionally, during harvest of the pedicled flap, distal osteotomy of the fibula is not performed in order to preserve bony length for distal advancement.

Deciding between a pedicled flap and a free fibula flap for ankle arthrodesis remains a source of debate. Based on our experience, we have developed indications for the use of pedicled versus free fibula flap for complex ankle arthrodesis (Fig. 16). Pedicled fibula flap is advantageous as it requires shorter operative time and utilizes the ipsilateral fibula, limiting postoperative morbidity to just one lower extremity. However, if the peroneal vessels in the ipsilateral limb have been compromised, the option of pedicled fibula transfer is eliminated. Similarly, contralateral free fibula flap is necessary in cases when there is damage to the ipsilateral peroneal vessels.²² For these reasons, preoperative CTA is obtained to visualize the extent of vascular damage or vascular anomalies, such as a dominant peroneal artery nourishing the foot.³¹ The next consideration is whether the defect requiring reconstruction is in the medial or lateral ankle. Medial defects require free fibula flaps as a pedicled flap will not reach. If the defect is lateral but the lateral malleolus has been previously taken down or injured, or if you wish to preserve the lateral malleolus for future procedures, then again, a free fibula flap should be used. If the reconstruction requires vascularized bone for tibiocalcaneal fusion, a

pedicled flap likely cannot be mobilized that distally and will require free fibula flap. Lateral defects involving distal tibia or tibiotalar fusion are ideal for pedicled fibula flaps. From the six patients in our study, we have demonstrated that stable bony union can be achieved using vascularized bone grafts in patients with difficult ankle reconstructive problems.

This study has several strengths and limitations. There was no comparison group within our study; however, the intention of our study was primarily to demonstrate our experience and outcomes from six patients who underwent vascularized bone grafts using free fibula and pedicled fibula flaps to achieve ankle arthrodesis. The procedures were performed by a single surgeon within one major health institution in the United States, which helped provide consistency in surgical technique and postoperative follow-up. However, this may reduce generalizability of our results. The average follow-up time was 2 years; however, one patient was lost to long-term follow-up. The small sample size and the relatively short duration of follow-up are other limitations to this study. Additionally, there is always a consideration of a learning curve and surgeon skills that play a role in the overall success of the operation and postoperative course.

CONCLUSIONS

This study reports six successful cases of free fibula and pedicled fibula flaps to achieve ankle arthrodesis that were not amenable to primary surgical interventions or had failed prior interventions. Using the indications we have developed for free versus pedicled fibula flaps can help guide surgeons in determining the best option for these complex problems. With the right expertise and surgical indication, free and pedicled fibula flaps are options that surgeons should consider for salvage in ankle arthrodesis cases.

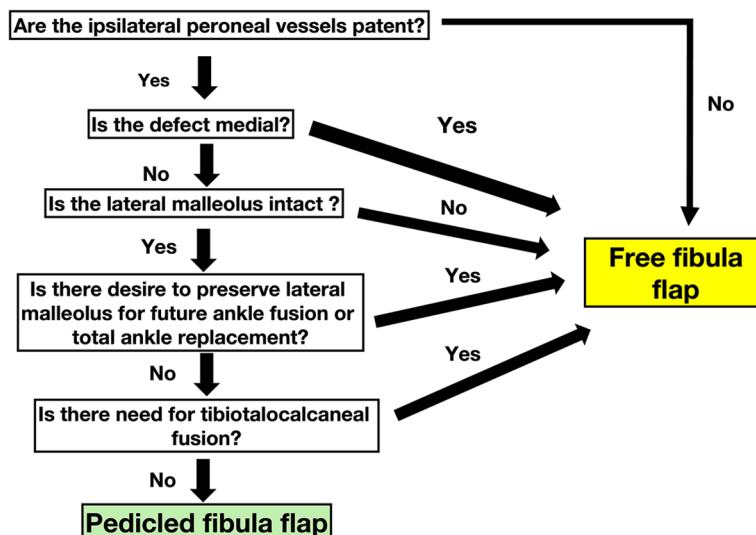


Fig. 16. Flowchart demonstrating our indications on when a fibula or pedicled fibula flap should be utilized for ankle arthrodesis.

Kongkrit Chaiyasate, MD

Department of Plastic Surgery
Beaumont Health Systems
3555 W 13 Mile Rd 120
Royal Oak, MI 48073

E-mail: kongkrit.chaiyasate@beaumont.org

PATIENT CONSENT

Patients provided written consent for the use of their images and for surgical treatment.

REFERENCES

- Carlsson AS, Montgomery F, Besjakov J. Arthrodesis of the ankle secondary to replacement. *Foot Ankle Int.* 1998;19:240–245.
- Albert E. *Zur Resektion des Kniegelenkes.* Wien Med Press. 1879;20:705–708.
- Mendicino SS, Krepleck AL, Walters JL. Open ankle arthrodesis. *Clin Podiatr Med Surg.* 2017;34:489–502.
- Yasui Y, Hannon CP, Seow D, Kennedy JG. Ankle arthrodesis: a systematic approach and review of the literature. *World J Orthop.* 2016;7:700–708.
- Bauer G, Kinzl L. Arthrodesen des oberen sprunggelenks [arthrodesis of the ankle joint]. *Orthopäde.* 1996;25:158–165.
- Saltzman CL, Salamon ML, Blanchard GM, et al. Epidemiology of ankle arthritis: report of a consecutive series of 639 patients from a tertiary orthopaedic center. *Iowa Orthop J.* 2005;25:44–46.
- Lawton CD, Butler BA, Dekker RG II, et al. Total ankle arthroplasty versus ankle arthrodesis—a comparison of outcomes over the last decade. *J Orthop Surg Res.* 2017;12:76.
- Frey C, Halikus NM, Vu-Rose T, et al. A review of ankle arthrodesis: predisposing factors to nonunion. *Foot Ankle Int.* 1994;15:581–584.
- Midis N, Conti SF. Revision ankle arthrodesis. *Foot Ankle Int.* 2002;23:243–247.
- Puente-Alonso C, Higuera-Suñe C, González-Vargas JA, et al. Use of fibula flaps to treat persistent talonavicular nonunion: a report of three cases. *Microsurgery.* 2016;36:430–434.
- Mann RA, Van Manen JW, Wapner K, et al. Ankle fusion. *Clin Orthop Relat Res.* 1991;268:49–55.
- Crosby LA, Yee TC, Formanek TS, et al. Complications following arthroscopic ankle arthrodesis. *Foot Ankle Int.* 1996;17:340–342.
- Paremain GD, Miller SD, Myerson MS. Ankle arthrodesis: results after the miniarthrotomy technique. *Foot Ankle Int.* 1996;17:247–252.
- Nihal A, Gellman RE, Embil JM, et al. Ankle arthrodesis. *Foot Ankle Surg.* 2008;14:1–10.
- Morash J, Walton DM, Glazebrook M. Ankle arthrodesis versus total ankle arthroplasty. *Foot Ankle Clin.* 2017;22:251–266.
- Dimitriou R, Jones E, McGonagle D, et al. Bone regeneration: current concepts and future directions. *BMC Med.* 2011;9:66.
- Arata MA, Wood MB, Cooney WP, III. Revascularized segmental diaphyseal bone transfers in the canine. An analysis of viability. *J Reconstr Microsurg.* 1984;1:11–19.
- Foster RD, Anthony JP, Sharma A, et al. Vascularized bone flaps versus nonvascularized bone grafts for mandibular reconstruction: an outcome analysis of primary bony union and endosseous implant success. *Head Neck.* 1999;21:66–71.
- Beris AE, Lykissas MG, Korompilias AV, et al. Vascularized fibula transfer for lower limb reconstruction. *Microsurgery.* 2011;31:205–211.
- Zwipp H. Arthrodesis of the ankle. *Acta Chir Orthop Traumatol Cech.* 2017;84:13–23.
- Piccolo PP, Ben-Amotz O, Ashley B, et al. Ankle arthrodesis with free vascularized fibula autograft using saphenous vein grafts: a case series. *Plast Reconstr Surg.* 2018;142:806–809.
- Yajima H, Kobata Y, Tomita Y, et al. Ankle and pantalar arthrodeses using vascularized fibular grafts. *Foot Ankle Int.* 2004;25:3–7.
- Holm J, Vangelisti G, Remmers J. Use of the medial femoral condyle vascularized bone flap in traumatic avascular necrosis of the navicular: a case report. *J Foot Ankle Surg.* 2012;51:494–500.
- Repo JP, Barner-Rasmussen I, Roine RP, et al. Role of free iliac crest flap in foot and ankle reconstruction. *J Reconstr Microsurg.* 2016;32:386–394.
- Haddock NT, Wapner K, Levin LS. Vascular bone transfer options in the foot and ankle: a retrospective review and update on strategies. *Plast Reconstr Surg.* 2013;132:685–693.
- Roukis TS, Kang RB. Vascularized pedicled fibula onlay bone graft augmentation for complicated tibiotalar calcaneal arthrodesis with retrograde intramedullary nail fixation: a case series. *J Foot Ankle Surg.* 2016;55:857–867.
- Goldberg VM, Shaffer JW, Field G, et al. Biology of vascularized bone grafts. *Orthopedic Clinics of North America.* 1987;18:197–205.
- Bishop AT, Wood MB, Sheetz KK. Arthrodesis of the ankle with a free vascularized autogenous bone graft. Reconstruction of segmental loss of bone secondary to osteomyelitis, tumor, or trauma. *J Bone Joint Surg Am.* 1995;77:1867–1875.
- Yazar S, Lin C, Wei F. One-stage reconstruction of composite bone and soft-tissue defects in traumatic lower extremities. *Plast Reconstr Surg.* 2004;114:1457–1466.
- Shankhdhar VK, Yadav PS, Puri A, et al. Free fibula flap for lower limb salvage after tumour resection. *Indian J Plast Surg.* 2018;51:274–282.
- Garvey PB, Chang EI, Selber JC, et al. A prospective study of pre-operative computed tomographic angiographic mapping of free fibula osteocutaneous flaps for head and neck reconstruction. *Plast Reconstr Surg.* 2012;130:541e–549e.