

Minimal change disease in a patient with myasthenia gravis

A case report

Jun-Li Tsai, MD^a, Shang-Feng Tsai, MD^{b,c,d,e,*}

Abstract

Background: Myasthenia gravis superimposed with proteinuria is a very rare disorder with only 39 cases reported so far. Of these cases, the most commonly associated disorder is minimal change disease. Myasthenia gravis and minimal change disease are both related to the dysfunction of T lymphocytes and hence the 2 disorders may be connected.

Methods: Here we report the first case on a patient diagnosed with myasthenia gravis concurrently with the minimal change disease, and it was presented in the absence of thymoma or thymic hyperplasia.

Results: Treatment for myasthenia gravis also lowered proteinuria of minimal change disease. He ever experienced good control for myasthenia gravis and minimal change disease. However, pneumonia related septic shock occurred to him and finally he was dead. Minimal change disease is generally considered to occur subsequent to the onset of myasthenia gravis with causal association. After extensive literature review, we noted only 47.8% minimal change disease had occurred after the onset of myasthenia gravis.

Conclusion: Minimal change disease mostly occurs in children and if diagnosed in adults, clinicians should search for a potential cause such as myasthenia gravis and other associated thymic disorders.

Abbreviations: AChR = acetylcholine receptor, CT = computed tomography, EOM = extra-ocular movement, MG = myasthenia gravis.

Keywords: minimal change disease, myasthenia gravis, nephrotic syndrome

1. Introduction

Myasthenia gravis (MG) is a rather common disorder. But MG superimposed with proteinuria is very rare and there are only 39 cases reported so far.^[1–4] Minimal change disease (MCD)^[5] and MG are both related to the dysfunction of T lymphocytes and there may exist some connection between the 2 disorders. Here we report an 82-year-old man diagnosed at the same time with MG and MCD. We will also discuss their relationship and report on the results of literature review regarding the temporal onset of MCD against MG.

2. Case report

An 82-year-old man who had been robust in health before was admitted to our hospital due to dizziness, blurred vision, and fluctuating weakness that lasted for 2 months. Dysphagia also developed 1 month ago, especially with solid food. In addition to this chief complaint, nephrotic syndrome was found incidentally at the same time. He had severe legs edema but without lymphadenopathy. Neurological examinations showed limited extra-ocular movement (EOM) to the 4 directions, especially when looking to the left side. Bilateral ptosis and left ptosis were noted. Mild improvement of left eye size and EOM limitations were found 3-minute after ice pack treatment. Thyroid dysfunction-related problem was not favored due to negative laboratory data of thyroid function (13.1 pg/mL of free T₄, 11.6 ng/mL of thyroglobulin, <20 IU/mL of anti-TG antibody, 25.9 IU/mL of anti-TPO). Radiographic results showed no goiter or brain lesions according to chest computed tomography (CT) and brain magnetic resonance angiography. Electromyography findings were negative. The ophthalmology report on eye structures was normal. Autoimmune disease was not favored due to the negative finding of antinuclear antibody. The Jolly test showed positive finding on the nasalis muscle. Blink reflex was normal except for the reduced amplitude. Acetylcholine receptor (AChR) antibody was positive. Therefore, MG was suspected. As for his nephrotic syndrome, laboratory data showed 9.5 g of daily urine protein, 1.1 mg/dL of serum creatinine, 221 mg/dL of low-density lipoprotein cholesterol, and 1.6 g/dL of albumin. There was no diabetic mellitus and negative results for complement 3 (143 mg/dL), complement 4 (35.1 mg/dL), syphilis test, hepatitis B, hepatitis C, immunoglobulin G (898 mg/dL), immunoglobulin A (288 mg/dL), and

Editor: Ikechi Okpechi.

The authors have no funding and conflicts of interest to disclose.

^a Department of Family Medicine, Cheng Ching General Hospital, ^b Division of Nephrology, Department of Internal Medicine, Taichung Veterans General Hospital, ^c School of Medicine, China Medical University, ^d Department of Life Science, Tunghai University, Taichung, ^e Department of Medicine, Nation Yang Ming University, Taipei, Taiwan.

* Correspondence: Shang-Feng Tsai, Division of Nephrology, Department of Medicine, Taichung Veterans General Hospital, Taichung, Taiwan (e-mail: s881056@gmail.com).

Copyright © 2016 the Author(s). Published by Wolters Kluwer Health, Inc. All rights reserved.

This is an open access article distributed under the Creative Commons Attribution-NoDerivatives License 4.0, which allows for redistribution, commercial and non-commercial, as long as it is passed along unchanged and in whole, with credit to the author.

Medicine (2016) 95:39(e5008)

Received: 25 July 2016 / Received in final form: 2 September 2016 / Accepted: 7 September 2016

<http://dx.doi.org/10.1097/MD.0000000000005008>

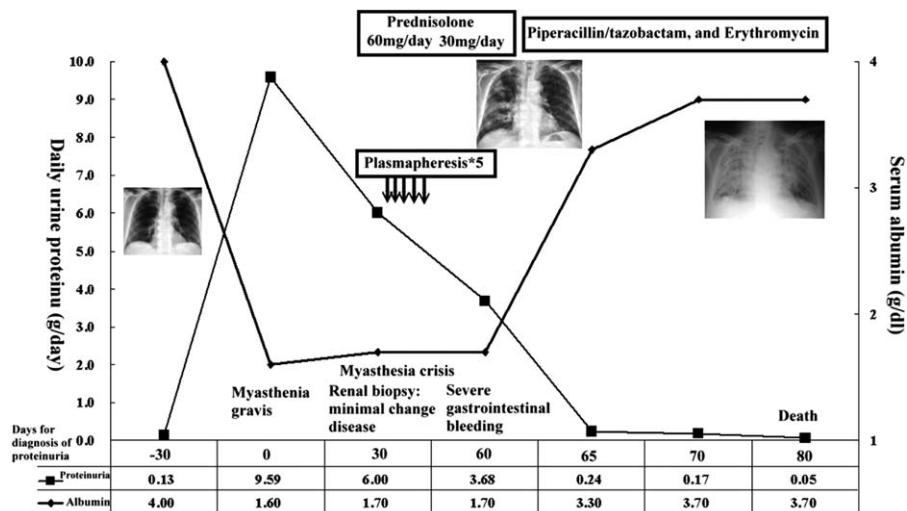


Figure 1. Summary of whole clinical course.

Immunoglobulin M (129 mg/dL). Kidney size was 12 cm on both sides. Immunofixation of blood and urine both showed no monoclonal bands. He denied any prior medications before this admission, including nonsteroidal anti-inflammatory drugs. Urinalysis 1 month before this admission was clean. Due to suspected MG, therapeutic treatment with Pyridostigmine (60 mg) was given 3 times. Each time 30 minutes after medication we found improvements for ptosis, EOM limitations, and blurred vision. Chest CT disclosed no evidence of thymoma, thymic hyperplasia, and lymphadenopathy. Therefore, MG, ocular type was confirmed. One month after the diagnosis of MG and nephrotic syndrome, he was admitted again for renal biopsy.

Renal biopsy was done smoothly but he started to have choking, dyspnea, and muscle weakness 2 days after this procedure. The proteinuria declined from 9.5 g to 6 g even without any treatment. However, myasthenic crisis was suspected and we performed 5-times plasmapheresis. Also, 60 mg/day Prednisolone was prescribed. Myasthenic crisis improved and soon he was discharged. One month after renal biopsy, his proteinuria declined to 3.68 g per day. We obtained 30 glomeruli and the depth renal biopsy was sampled between the cortex and medulla. The renal biopsy results were unremarkable with no glomerular, tubulointerstitial, or vascular lesions under light or immunofluorescence microscopy. Only severe foot process effacements were found under electron microscopy. These findings were consistent with a diagnosis of MCD.

After discharged from the hospital, we gradually tapered the doses of Pyridostigmine and steroid. Unfortunately, he developed severe gastrointestinal bleeding and steroid was discontinued 1 month after the renal biopsy. Then, he developed severe pneumonia (*Klebsiella pneumoniae* and *Staphylococcus aureus* of sputum cultures) and related respiratory distress syndrome before respiratory failure, followed by septic shock and death despite the treatment with Piperacillin/tazobactam and erythromycin. Finally, his proteinuria declined to 0.05 g per day and serum albumin was 3.7 g/dL. The whole clinical course was summarized in Fig. 1. This study had been approved by patient himself with signed consent form.

3. Discussion

MCD (also called NIL [i.e., Nothing-In-Light microscopy]) is a major cause of nephrotic syndrome in the population from children to adults. The most frequent malignancy in MCD is lymphoma^[6] and the association suggests that MCD is a disease of lymphocyte dysfunction. The benefit of therapy using steroids and immunosuppressants suggests that MCD is related to the disordered immune system. In some cases of nephrotic syndrome, including MCD, the mechanism is presumably an imbalance between T helper cells class 1 and 2.^[5] In brief, nephrotic syndrome, including MCD, is primarily due to immune dysregulation, especially the dysregulated T cell functions. Thymus is where T cells develop to maturity and where they get through positive and negative selection. In thymoma, thymic proliferation or MG, patients also show immune dysregulations. Growing evidence supported the association between MCD and thymic disease (thymoma, thymic hyperplasia, and MG). From literature reviews, nephrotic syndrome as a systemic manifestation of thymic disease is rarely encountered.^[2,3,7-12] So far, there are merely 39 cases (including the present one) reported with thymoma-related nephropathy.^[2-4,13] Of these cases, the most abundant type (22/39, 56.4%) is due to MCD, followed by other types like membranous nephropathy and glomerulonephropathy.

It is likely that MCD does not occur as a coincident event in patients with MG. The reasons are the following. First, most MCD cases occur in children. Their incidence rate in adults with nephrotic syndrome is rather low (10%–15%). Our case occurred with an old patient (82 years old). Focal segmental glomerulosclerosis though could not be excluded but we believed it was less favored. That is because the 30 glomeruli we obtained were from regions of the kidney as deep as the medulla. Such unusual late onset of MCD in our patient suggested some secondary causes of MCD, such as MG. Second, the proteinuria of MCD dropped (from 9.59 to 6.00 g) after treatment with Pyridostigmine (even before plasmapheresis and steroid). Because there is no plausible immune modulatory action of pyridostigmine in terms of antibody titer reduction, the possibility of ongoing spontaneous remission cannot be excluded. However,

we cannot still exclude less proteinuria is due to good treatment response of MG. Besides, there were no predisposing factors or secondary causes for his MCD. This closely clinical course, including diagnosis and treatment, cannot exclude the probability that MCD could be associated with MG. Third, T cell dysfunction could induce an imbalance between T helper and T suppressor cells.^[5] In our case, the T cell dysfunction occurring with MG could also lead to a concurrent MCD.

Interestingly, the onset time of MCD in patients with thymic disease is generally considered late.^[9–11] MCD had been reported to occur as late as 10 years after the diagnosis of thymoma and 15 years after MG.^[12] Some hypotheses were put forward in the literature regarding the delayed onset of MCD following thymoma. First, thymectomy might induce altered functions in lymphocytes and that take several years to manifest as MCD.^[10] Second, MCD-associated thymoma is caused by T cell dysfunction leading to the production of lymphokine, which increases the permeability of glomerular basement membrane.^[9] However, the delayed onset presentation of MCD following thymoma may not hold as a general statement as increasing number of cases are now reported. Of all these 23 cases,^[2,3,7–12] almost half of them (11 cases) the MCD had occurred months or years after thymic disease.^[1,2] On the contrary, only 6 cases developed thymoma after the diagnosis of MCD, and 6 cases (including our patient) had the diagnosis of MCD and MG at the same time. Thus, the temporal onset of MCD may or may not be delayed as previously thought. Finally, this case only had MG without thymoma or thymic hyperplasia. The majority of AChR antibody positive MG have thymic abnormalities: 60% to 70% thymic hyperplasia and 10% to 12% thymoma.^[14] What we have reported here is the first case with MCD and MG. But thymic hyperplasia or thymoma could not be demonstrated in this patient despite extensive imaging although the patient had positive AchR Abs. We hypothesized that the patient may have delayed diagnosis of thymic disorder after the diagnosis of MG. Since 1 case report described a thymoma which was confirmed 5 years after the diagnosis of MG.^[12] As severe pneumonia-related septic shock had occurred to our patient later on, it remained unclear whether delayed diagnosis of thymic disorder may occur after MG. Delayed onset of thymoma or thymic hyperplasia in MG and MCD is still rare and this is the second case reported so far. Moreover, there may be some autoantibodies,^[13] such as muscle-specific receptor tyrosine kinase

and low-density lipoprotein receptor-related protein, associated with MG without thymic disorder.

4. Conclusion

MCD mostly occurs in children and if diagnosed in adults, clinicians should search for a potential cause such as MG and other associated thymic disorders. In spite of its rarity, clinicians should keep in mind the association between MCD and MG and that MCD may not always occur long after the diagnosis of MG.

References

- [1] Kute VB, Shah PR, Shrimali JD, et al. Nephrotic syndrome after thymectomy for myasthenia gravis. *Ind J Nephrol* 2013;23:75–6.
- [2] Karras A, de Montpreville V, Fakhouri F, et al. Groupe d'Etudes des Néphropathies Associées aux T. Renal and thymic pathology in thymoma-associated nephropathy: report of 21 cases and review of the literature. *Nephrol Dialysis Transplant* 2005;20:1075–82.
- [3] Posner MR, Prout MN, Berk S. Thymoma and the nephrotic syndrome: a report of a case. *Cancer* 1980;45:387–91.
- [4] Zbiti N, Ouadnoui Y, Arrayhani M, et al. [Glomerulonephritis and thymoma: a case report and review of the literature]. *Revue Pneumologie Clinique* 2009;65:322–4.
- [5] Souadjian JV, Enriquez P, Silverstein MN, et al. The spectrum of diseases associated with thymoma. Coincidence or syndrome? *Arch Int Med* 1974;134:374–9.
- [6] Sherman RL, Susin M, Weksler ME, et al. Lipoid nephrosis in Hodgkin's disease. *Am J Med* 1972;52:699–706.
- [7] Varsano S, Bruderman I, Bernheim JL, et al. Minimal-change nephropathy and malignant thymoma. *Chest* 1980;77:695–7.
- [8] Chan PC, Lau CC, Cheng IK, et al. Minimal change glomerulopathy in two patients after thymectomy. *Singapore Med J* 1990;31:46–7.
- [9] Zinger C, Ben-Itzhak O, Szyman P, et al. Minimal-change nephropathy and malignant thymoma. *Am J Nephrol* 1998;18:61–3.
- [10] Lasseur C, Combe C, Deminiere C, et al. Thymoma associated with myasthenia gravis and minimal lesion nephrotic syndrome. *Am J Kidney Dis* 1999;33:e4.
- [11] Takahashi K, Inoue Y, Matsuda O, et al. [A case of myasthenia gravis, who developed minimal change nephrotic syndrome during immunosuppressive therapy after thymectomy]. *Nihon Jinzo Gakkai shi* 2000;42:394–8.
- [12] Yoshida T, Suzuki T, Suzuki S, et al. Nephrotic syndrome after extended thymectomy for thymoma with myasthenia gravis; report of a case. *Jap J Thorac Surg* 2006;59:247–50.
- [13] Motomura M, Higuchi O. Progress of myasthenia gravis: discovery of Lrp4 antibodies. *Clin Neurol* 2012;52:1303–5.
- [14] Drachman DB. Myasthenia gravis. *N Engl J Med* 1994;330:1797–810.