



## Case report

## Value of Broad Range 16S Ribosomal RNA Gene PCR / Sequencing (Br-PCR) of CSF in the Diagnosis of Bacterial Meningitis

Ashley Rogers<sup>a</sup>, Jahanavi M. Ramakrishna<sup>b</sup>, Claudia R. Libertin<sup>b</sup>, W. David Freeman<sup>a,\*</sup><sup>a</sup> Department of Neurology, Mayo Clinic, FL, United States<sup>b</sup> Division of Infectious Disease, Mayo Clinic, FL, United States

## ARTICLE INFO

## Article history:

Received 13 April 2020

Received in revised form 12 May 2020

Accepted 12 May 2020

## Keywords:

Bacterial meningitis

Haemophilus

16s ribosomal RNA gene

Broad Range PCR

Sequencing

Molecular diagnosis

## ABSTRACT

Bacterial meningitis is a life-threatening condition that requires quick and definitive diagnosis. Bacterial cultures from cerebrospinal fluid (CSF) return with a negative result as treatment with antimicrobials are sometimes started before sampling of CSF can be obtained which makes isolating the causative bacteria challenging. The value of Broad Range 16S Ribosomal RNA Gene Polymerase Chain Reaction / Sequencing of CSF (Br-PCR) can address this problem by amplifying and identifying any bacterial DNA present in a clinical sample.

A 65-year-old female presented with rapid onset of high fevers, headache, chills and right hip pain. She had blood cultures drawn, unremarkable CSF analysis in the emergency department, and was discharged home. Ten hours later, she developed vomiting and altered mental status, returned to hospital and started on antimicrobials for gram negative bacteremia and emergently intubated with repeat lumbar puncture showed evidence of bacterial meningitis with pleocytosis and elevated opening pressures. Empiric antimicrobial therapy was started. All subsequent CSF microbiological stains, cultures, and molecular analyses were negative. The blood cultures grew *Haemophilus influenzae* and *H. influenzae* meningitis was presumed to be the cause. Therefore, Br-PCR on CSF was sent which detected *Haemophilus* species DNA. She received a 3-week course of ceftriaxone. After rehabilitation, she returned home without any significant neurological deficits. No relapse of meningitis at 4 months was noted.

The application for Br-PCR in the setting of suspected bacterial meningitis with negative stains and cultures could improve a diagnostic algorithm for bacterial meningitis.

© 2020 The Author(s). Published by Elsevier Ltd. This is an open access article under the CC BY-NC-ND license (<http://creativecommons.org/licenses/by-nc-nd/4.0/>).

## Introduction

Bacterial meningitis is a life-threatening condition that requires swift and definitive diagnosis. Empiric antimicrobial therapy is often started at onset of suspicion of meningitis even before diagnostic testing is complete. Meningitis is suspected when cerebrospinal fluid (CSF) profiles from lumbar puncture show elevated white blood cells, elevated protein and decreased glucose (>5 leukocytes cells/uL, protein >40 mg/dL, glucose < 2/3 serum glucose). Initiating antimicrobials prior to CSF sampling has been shown to inhibit bacterial growth rendering cultures negative. This can lead to false negatives and makes isolating the causative bacteria challenging [1]. In cases of negative culture growth, Broad Range 16S Ribosomal RNA Gene Polymerase Chain Reaction / Sequencing (Br-PCR) of CSF holds value because it can amplify and


identify bacterial, including mycobacterial, DNA despite presence of antimicrobials. We present a case of bacteremic *Haemophilus influenzae* bacterial meningitis in the setting of both negative CSF culture and rapid meningitis-encephalitis panel, but there was a positive Br-PCR result.

## Case Summary

A 65-year-old female with a history of diabetes, hypertension, hyperlipidemia, chronic neck and back pain presented to the ER with a two day history of high fevers, headache, chills and right hip pain. Initial blood workup showed no leukocytosis, a normal lactate, and a head CT that was unremarkable. On physical exam, she was alert, with normal speech and no focal deficits but had some tenderness to right cervical paraspinal muscles. Lumbar puncture (LP) was performed showing 2 leukocytes  $\mu\text{L}^{-3}$ , protein 37 mg  $\text{dL}^{-1}$ , glucose 64 mg  $\text{dL}^{-1}$  on fluid analysis. The patient remained febrile despite being given acetaminophen and ketorolac. Blood cultures were drawn. She was discharged home that morning from the ER. Approximately 10 hours later, the patient

\* Corresponding author at: 4500 San Pablo Blvd, Jacksonville, FL, 32224, United States.

E-mail address: [freeman.william1@mayo.edu](mailto:freeman.william1@mayo.edu) (W. D. Freeman).



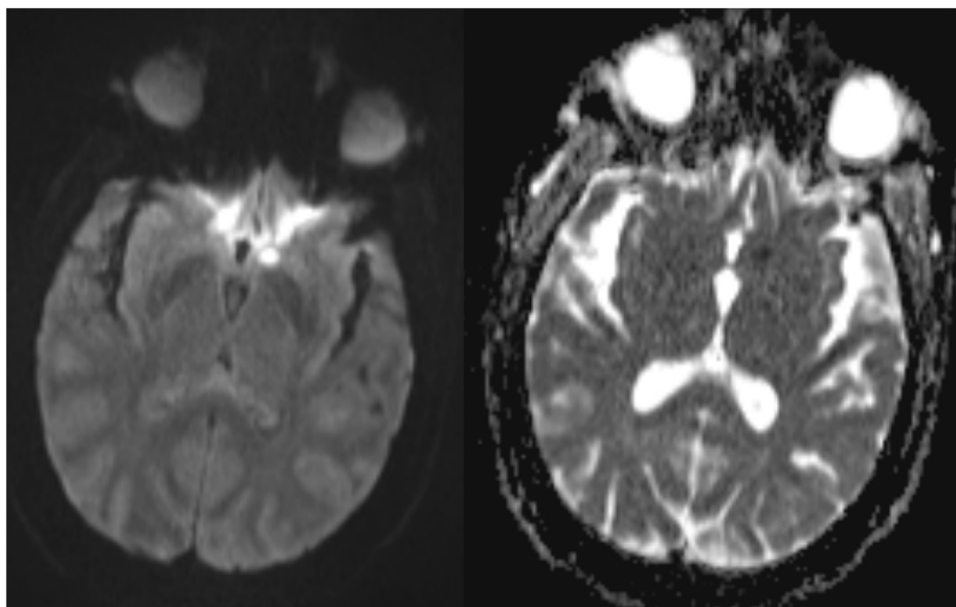
**Fig. 1.** Picture of the patient's cerebrospinal fluid taken from the second positive lumbar puncture.

returned to hospital after three episodes of vomiting and an episode of loss of consciousness at home. Her blood cultures from that morning grew gram-negative rods, later speciated to *H. influenzae*. She was admitted to the hospital and started on ceftriaxone for *H. influenzae* bacteremia. Quickly, she became encephalopathic with nuchal rigidity and encephalopathy with Glasgow Coma Scale of 6. The patient was immediately transferred to the intensive care unit and emergent intubation was performed. Her antimicrobials were escalated to vancomycin, ceftriaxone, ampicillin and acyclovir. Repeat LP was xanthochromic with an opening pressure of 52 cmH<sub>2</sub>O, 18,426 leukocytes cells/uL (98% PMN, 2% ANC 18,057.5 cells/uL), 153 red blood cells/uL, 975 mg/dL protein, and <2 mg/dL glucose. Repeat CSF cultures showed no growth. The BioFire FilmArray Meningitis/Encephalitis multiplex PCR (bioMerieux) was negative.

The patient continued to have serial large volume lumbar punctures (Fig. 1) to reduce intracranial pressure. As no clinical improvement was seen, a CSF sample was sent for Br-PCR. Using the same methodology as described by Ramakrishna et al., the DNA sequence detected by Br-PCR and analyzed by SmartGene's Integrated Database Network System ([www.smartgene.com](http://www.smartgene.com)) was identified as *Haemophilus* species [2]. She was successfully extubated four days later and complained of left shoulder pain, which led to investigation of septic arthritis without MRI evidence of osteomyelitis. Needle aspiration of left glenohumeral joint showed 13,930 leukocytes  $\mu\text{L}^{-3}$ , with 99% neutrophils with no crystals. The presence of negative bacterial culture was suggestive of partially treated septic arthritis. The patient's clinical course was also complicated by an asymptomatic MRI brain lesion characterized by a small diffusion restriction in left caudate head (Fig. 2), possibly due to infectious arteritis as well as mild SIADH. She successfully completed three weeks of treatment with IV ceftriaxone and was discharged to a rehabilitation facility. The patient was subsequently able to return home without any significant neurological deficits. No relapse of meningitis at 4 months follow-up was clinically noted.

## Discussion

Bacterial meningitis has high morbidity and mortality [3]. Worldwide, the three main pathogens for bacterial meningitis are *H influenzae*, *S pneumoniae* and *N meningitidis* account for 75-80% of cases after neonatal period [4]. This life-threatening condition requires immediate suspicion upon clinical presentation, administration of empiric antimicrobials, and diagnosis with cerebral spinal fluid sampling for analysis and cultures. Unfortunately, even when the lumbar puncture is performed before antimicrobial administration, 15-30% of CSF cultures show no bacterial growth despite being the source of bacterial disease [5]. In these cases, the clinician must decide whether to continue with empiric course of treatment for bacterial meningitis or to stop antimicrobial therapy. Br-PCR is a useful diagnostic tool in culture-negative meningitis [6]. The positive Br-PCR test prevents discontinuation of antimicrobials in the face of negative bacterial culture [7], and may allow for de-escalation of anti-microbial agents, as in this case. In



**Fig. 2.** MRI brain diffusion weighted image (left) with hyperintense signal in left caudate head with corresponding hypointense signal on apparent diffusion coefficient (right).

the setting of no bacterial growth after 48-72 hours despite abnormal CSF results ( $\geq 11$  leukocytes/uL, glucose  $< 10$  mg/dL, lactate  $> 4$  mmol/L), Br-PCR should be considered as next step in diagnosing bacterial meningitis [8]. Additionally, PCR can detect bacteria in CSF samples up to one week into antimicrobial therapy [9].

In our patient, she was at higher risk for invasive disease with *H. influenzae* as she was 65 years old and had diabetes [10], although moderately controlled with recent A1c of 6.7%. The role of Br-PCR in diagnosis of meningitis led to narrowing therapy to directly treat the causative bacterium which prevented potential adverse effects and potential resistances to develop from a full course of empiric antimicrobial.

### Funding

This research did not receive any specific grant from funding agencies in the public, commercial, or not-for-profit sectors.

### Consent

Written consent obtained by the patient.

### CRediT authorship contribution statement

**Ashley Rogers:** Writing - original draft, Writing - review & editing, Conceptualization. **Jahanavi M. Ramakrishna:** Resources, Writing - review & editing. **Claudia R. Libertin:** Writing - review & editing. **W. David Freeman:** Writing - review & editing.

### Declaration of Competing Interest

The authors have no conflicts of interest to report.

### Acknowledgment

None.

### References

- [1] du Plessis M, Smith AM, Klugman KP. Rapid Detection of Penicillin-Resistant *Streptococcus pneumoniae* in Cerebrospinal Fluid by a Seminested-PCR Strategy. *J Clin Microbiol.* 1998;36(2):453–7, doi:http://dx.doi.org/10.1128/jcm.36.2.453-457.1998.
- [2] Ramakrishna JM, Libertin CR, Yang JN, Diaz MA, Nengue AL, Patel R. 16S rRNA Gene PCR/Sequencing of Cerebrospinal Fluid in the Diagnosis of Post-operative Meningitis. *Access Microbiology.* 2020(February), doi:http://dx.doi.org/10.1099/acmi.0.000100.
- [3] Brouwer MC, Thwaites GE, Tunkel AR, van de Beek D. Dilemmas in the diagnosis of acute community-acquired bacterial meningitis. *The Lancet.* 2012;380(9854):1684–92, doi:http://dx.doi.org/10.1016/s0140-6736(12)61185-4.
- [4] Verma A, Solbrig MV. Infections of the nervous system: bacterial infections. In: Bradley WG, Daroff RB, Fenichel GM, Janokovic J, editors. *Neurology in clinical practice.* Boston, MA: Butterworth Heinemann; 2003. p. 1475–514.
- [5] Meddeb M, Koebel C, Jaulhac B, Schramm F. Comparison Between Broad-Range Real-Time and a Broad Range End-Point PCR Assays for the Detection of Bacterial 16S rDNA in Clinical Samples: A 1-Year Prospective Study in Routine Practice at the University Hospital of Strasbourg, France. *Am J Pathol.* 2014;142 (Suppl\_1), doi:http://dx.doi.org/10.1093/ajcp/142.suppl1.163 A163–A163.
- [6] Rafi W, Chandramuki A, Mani R, Satishchandra P, Shankar SK. Rapid Diagnosis of Acute Bacterial Meningitis: Role of a Broad Range 16S rRNA Polymerase Chain Reaction. *J Emerg Med.* 2010;38(2):225–30, doi:http://dx.doi.org/10.1016/j.jemermed.2008.02.053.
- [7] Srinivasan L, Pisapia JM, Shah SS, Halpern CH, Harris MC. Can Broad-Range 16S Ribosomal Ribonucleic Acid Gene Polymerase Chain Reactions Improve the Diagnosis of Bacterial Meningitis? A Systematic Review and Meta-analysis. *Ann Emerg Med* 2012;60(5):609–20, doi:http://dx.doi.org/10.1016/j.annemergmed.2012.05.040 e2.
- [8] Tunkel AR, Hasbun R, Bhimraj A, et al. 2017 Infectious Diseases Society of America's Clinical Practice Guidelines for Healthcare-Associated Ventriculitis and Meningitis\*. *Clin Infect Dis.* 2017;64(6):701–6, doi:http://dx.doi.org/10.1093/cid/cix152.
- [9] Brink M, Welinder-Olsson C, Hagberg L. Time window for positive cerebrospinal fluid broad-range bacterial PCR and *Streptococcus pneumoniae* immunochromatographic test in acute bacterial meningitis. *Infect Dis (Lond).* 2015;47(12):869–77, doi:http://dx.doi.org/10.3109/23744235.2015.1078907.
- [10] Blain A, MacNeil J, Wang X, et al. Invasive *Haemophilus influenzae* Disease in Adults  $\geq 65$  Years, United States, 2011. *Open Forum Infect Dis.* 2014;1(2), doi:http://dx.doi.org/10.1093/ofid/ofu044.