



Effectiveness of new selenium-enriched mutated probiotics in reducing inflammatory effects of piroxicam medication in liver and kidney

Ahmed Mohamed Darwish¹ · Abd El-Nasser A. Khattab² · Khaled A. Abd El-Razik³ · Sarah I. Othman⁴ · Ahmed A. Allam⁵ · Gasem M. Abu-Taweel⁶

Received: 3 August 2022 / Accepted: 24 August 2022 / Published online: 9 September 2022
© The Author(s), under exclusive licence to Springer Nature Switzerland AG 2022

Abstract

Piroxicam is used to treat the pain, swelling, and stiffness associated with osteoarthritis and rheumatoid arthritis, but it has many side effects, such as hypertension, elevation of liver enzymes, and hepatitis. This study used selenium-enriched probiotics to reduce the side effects of piroxicam on the liver and kidney tissues and functions. Forty-eight male albino mice were randomly assigned to control, piroxicam (P), piroxicam plus selenium-enriched *Lactobacillus plantarum* PSe40/60/1 (P + SP), piroxicam plus selenium-enriched *Bifidobacterium longum* BSe50/20/1 (P + SB), selenium-enriched *L. plantarum* PSe40/60/1 (SP), and selenium-enriched *B. longum* BSe50/20/1 (SB) groups. In this study, the function of the liver and kidney was biochemically determined; the histopathology of the liver and kidney tissues was microscopically examined and the expression of inflammatory and anti-inflammatory genes in liver and kidney tissues was determined by quantitative real-time polymerase chain reaction (qRT-PCR). Liver and kidney functions were significantly reduced in the piroxicam group compared with control. Liver and kidney tissues were damaged in the piroxicam group while they appeared more or less normal in the SB group. The expression of inflammatory genes was significantly up-regulated in the liver and kidney tissues of the piroxicam group compared to the control group. The expression of anti-inflammatory genes was significantly down-regulated in the liver and kidney of the piroxicam group and up-regulated in the liver and kidney of the SB group compared to the control group. Therefore, these mutated strains of probiotics were useful in reducing the side effects of the piroxicam drug on the liver and kidney.

Keywords Piroxicam · Selenium-enriched probiotics · Liver · Kidney · Gene expression · Mice

Introduction

Non-steroidal anti-inflammatory drugs (NSAIDs) are a class of pharmaceuticals used to treat inflammatory diseases such as rheumatoid arthritis, osteoarthritis, and other inflammatory conditions by reducing pain and inflammation (common symptoms in COVID-19 patients) by inhibiting cyclooxygenase enzymes (Ghlichloo and Gerriets 2022). These medicines are anti-inflammatory, analgesic, and antipyretic and are commonly used to treat non-specific fever disorders (Shekelle et al. 2017). More than 100 million NSAIDs are administered worldwide (Aithal 2011), and they have been linked to liver damage (Benesic and Gerbes 2015). Among all NSAIDs, piroxicam belongs to the oxycam group that treats pain and inflammation, as well as symptoms related to rheumatoid arthritis, ankylosing spondylitis, and musculoskeletal disorders (van den Bekerom et al. 2015). Piroxicam

✉ Ahmed Mohamed Darwish
adgene@yahoo.com

¹ Cell Biology Department, Biotechnology Research Institute, National Research Centre, Dokki, Giza, Egypt
² Genetics and Cytology Department, Biotechnology Research Institute, National Research Centre, Dokki, Giza, Egypt
³ Animal Reproduction Department, Veterinary Research Institute, National Research Centre, Dokki, Giza, Egypt
⁴ Department of Biology, Faculty of Science, Princess Nourah bint Abdulrahman University, P.O. Box 84428, Riyadh 11671, Saudi Arabia
⁵ Department of Zoology, Faculty of Science, Beni-Suef University, Beni Suef 65211, Egypt
⁶ Department of Biology, College of Science, Jazan University, P.O. Box 2079, Jazan 45142, Saudi Arabia

has recently acquired popularity as a treatment for tumors, invasive bladder cancer, and colorectal cancer (Ronald 2002). Despite its extensive usage, it has a number of negative side effects, including severe gastrointestinal toxicity, ulcerogenic gastropathy, renal hemostatic abnormalities (Harirforoosh et al. 2013), proteoglycan production from chondrocytes, fetotoxicity, and other prostaglandin-dependent activities (Sriuttha et al. 2018). Piroxicam's mode of action, like that of other NSAIDs, is to reduce prostaglandin production by inhibiting the cyclooxygenase enzyme through competitive antagonism with arachidonic acid (Chaiamnuay et al. 2006). As a result of limiting prostaglandin production, gastroprotective mucin secretion is reduced indirectly, increasing the risk of ulcers.

The liver's important responsibilities in drug processing make it vulnerable to toxicity. There is a risk of liver harm since piroxicam is metabolized in the liver. As a result, hepatic dysfunction and failure develop. This example has been shown to have negative effects on renal function, including salt retention, changes in estimated glomerular filtration rate (eGFR), and blood pressure elevation (Lafrance and Miller 2009). However, the link between NSAID usage and the risk of chronic kidney disease (CKD) has remained unclear (Nderitu et al. 2013). Furthermore, despite being one of the most susceptible populations prone to the development of CKD or end-stage renal disease, nothing is known regarding the impact of NSAID usage on CKD in hypertension patients (Gooch et al. 2007). Currently, only a few studies have been undertaken to look at the link between NSAID usage and CKD with hypertension through oxidative stress to produce its damaging effects on the liver and kidney (Levey and Coresh 2012).

Tumor necrosis factor- α (TNF- α) has a vital role in regulating biological functions and pro-inflammatory responses (Aggarwal et al. 2012). Tumor necrosis factor superfamily member 11 (TNFSF11) regulates osteoclast-induced bone resorption and has been found in inflammatory and synovial fibroblast cells isolated from rheumatoid arthritis (RA) patients' synovial fluid (Fuller et al. 1998; Tanaka 2018). The CKD-enhanced low level of α Klotho expression in the parathyroid glands reduces the functionality of the α Klotho/FGFR complex for *FGF23* signaling (Kawakami et al. 2017). It is also known that *FGF23* is increased from the early stage in patients with chronic kidney disease (Goswami 2016). The expression of osteopontin (Opn), vimentin (Vim), neutrophil gelatinase-associated lipocalin (Ngal), and kidney injury molecule 1 (Kim-1) genes increased significantly in the CKD model mice (Koppe et al. 2015).

Certainly, probiotics are gaining more and more interest as alternatives to antibiotics or anti-inflammatory drugs. Also, probiotics have a great and wonderful role in removing the side effects of harmful and dangerous substances, and therefore, they were used to remove the harmful side

effects of a high dose of piroxicam (which injured the small bowel, leading to great interest in the pathophysiology and treatment of piroxicam-induced small intestinal, liver, and kidney damage). For example, but not limited to, Verma and Shukla (2014) looked at the effect of supplementing with *Lactobacillus rhamnosus* GG, *Lactobacillus casei*, *Lactobacillus Plantarum*, *Lactobacillus acidophilus*, or *Bifidobacterium bifidum* for 7 weeks on DMH-induced colon. In DMH-mediated CRC-generated rats, supplementation with *L. rhamnosus* GG or *L. acidophilus* successfully decreased the generation of aberrant crypt foci (ACF) and β -glucuronidase activity. Supplementation of *L. plantarum* or *L. casei* reduced nitro-reductase activity in DMH-mediated CRC-induced rats, whereas supplementation of *B. bifidum* reduced glucuronidase activity. The growth of CT26 cells was significantly reduced in BALB/c mice treated with *L. plantarum* for 14 days compared with *L. rhamnosus* (Hu et al. 2015). Sharaf et al. (2018) used *L. rhamnosus* GG MTCC # 1408 and/or *L. acidophilus* NCDC # 15 in reducing the tumor burden and multiplicity of the tumor induced by celecoxib for 18 weeks in rats. Therefore, piroxicam's involvement in the etiology of liver and renal disease is still debated. Here, we investigated the impact of consumption of a high dose of piroxicam on the liver and kidney using a mouse model of under-feeding with selenium-enriched *Lactobacillus plantarum* and *Bifidobacterium longum* mutants.

Materials and methods

Animal

The experimental procedure used in this investigation was approved by the Animal Care and Use Committee of National Research Centre in Egypt. In this study, 48 male mice (Albino) were housed separately in cages that were kept at 22 ± 2 °C, 50% humidity, and a 12 h light/dark cycle. These mice were bought from Animal House at the National Research Centre, Egypt, when 2-week-old and weighed 22–26 g.

Preparation of selenium-enriched mutant strains

The two mutated probiotic strains (*Lactobacillus plantarum* PSe40/60/1 and *Bifidobacterium longum* BSe50/20/1) were obtained from the Applied Microbial Genetics Lab., Genetics and Cytology Dept., the National Research Centre, in Dokki, Cairo, Egypt. The selenium-resistant fast-growing EMS-mutants were cultivated in MRS for 24 h and then added selenium (IV) oxide (100 ppm). Under the same conditions, the flasks were incubated for another 24 h. After being centrifuged for 5 min at 6000 rpm (200 ppm) for

5 min, 7.5 10⁶/mL of mice drinking water containing piroxicam or not were suspended (Khattab et al. 2022).

Experimental design

For 6 weeks, the control group received a normal diet, and the piroxicam (P) group received 0.8 mg of piroxicam/kg body weight daily. During the first week, the P+SP and the P+SB groups received 0.8 mg of piroxicam/kg body weight daily, followed by 5 weeks of mutants of PSe40/60/1 and BSe50/20/1 enriched with selenium, respectively, as well as 0.8 mg of piroxicam. In the SP group, selenium-enriched PSe40/60/1 mutants were administered. Finally, The SB group received a selenium-enriched BSe50/20/1 mutant. The drug and probiotics were given to mice through drinking water (200 ppm drug and 10 mL of bacterial suspension/1000 mL of H₂O).

Biochemical analysis

Urea, creatinine, bilirubin, serum glutamic oxaloacetic transaminase (SGOT), serum glutamic pyruvic transaminase (SGPT), and alkaline phosphatase (ALP) were measured in serum at 546 nm using commercial diagnostic kits by a spectrophotometer (Shimadzu model UV-240).

Measurement of inflammatory immunoglobulin and cytokines in serum

Specific Elisa kits (Genorise Scientific, Inc) was used to determine level of IgG, IgM, IL-22, and tumor necrosis factor (TNF- α) in serum of the six groups.

Liver and kidney histopathology

The samples of liver and kidney tissues were fixed in 10% neutral buffered formalin and stained with hematoxylin and eosin (H&E). Light microscopy was used in histopathological analysis, and then photomicrographs were taken.

Gene expression

The easy-RED reagent (iNtRON Biotechnology, Korea) was used to extract total RNA from the liver and left kidneys according to the manufacturer's instructions. NanoDrop spectrophotometer (Thermo Fisher Scientific, USA) was used to measure the quantity and purity of RNA. The cDNA was built from total RNA using the TopscriptTM RT Dry-MIX (Cat. # RT220, Korea) according to the manufacturer's instructions. Primer sequences of TNF- α , TNFSF11, FAS,

Table 1 Sequence of primers

Gene	Accession no.	Nucleotide sequence 5'-3'	Size (bp)
TNF- α	NM_001278601.1	F-ATCCGCGACGTGGAAGT-3' R-ACCGCCTGGAGTTCTGGAA-3'	70
TNFSF11	NM_011613.3	F 5-GGGGGCCGTGGAGAAGGAAC-3' R 5-CTCAGGCTTGCCCTCGGTGGG-3'	112
FAS	NM_001146708.1	F 5-CTGCCTCTGGTGCTTGCTGGC-3' R 5-ACCCACCCCTTCTCCCAAT-3'	267
IL-22	NM_016971.2	F 5-TGCGATCTCTGATGGCTGTC R 5-CCTCGGAACAGTTTCTCCCC	256
Opn	NM_001204203.1	F 5-TCCAAAGAGAGCCAGGAGAG-3' R5-GGCTTTGGAAGTTGCTTGAC-3'	66
Vim	NM_011701.4	F 5-CTGCACGATGAAGAGATCCA-3' R5-AGCCACGCTTTCATACTGCT-3	132
Ngal	NM_008491.1	F 5-GAAATATGCACAGGTATCCTC-3' R5-GTAATTTTGAAGTATTGCTTGT-3'	124
Kim-1	NM_001166632.1	F5-CTGGAATGGCACTGTGACATCC-3' R 5-GCAGATGCCAACATAGAAGCCC-3'	112
α Klotho	NM_013823.2	F 5-CCCGATGTATGTGACAGCCAATGG-3' R 5-CTTGGGAGCTGAGCGATCACTAAG-3	175
β actin	NM_007393.5	F 5'-GGCACCACACCTTCTACAATG-3' R 5'-GGGGTGTGAAGGTCTCAAAC-3'	74

IL-22, Opn, Vim, Ngal, Kim-1, α -kolotho, and β -actin genes were synthesized by Macrogen Co., Ltd., Korea (Table 1). Real-time quantitative PCR (RT-qPCR) analysis was carried out on the AnalytikJena qTOWER3G Real-Time PCR System in a 20 μ L reaction volume containing 1 μ L cDNA, 0.5 μ L of forward primer (10 μ M) and 0.5 μ L of reverse primer (10 μ M), 10 μ L of QuantiNova SYBR Green PCR kit (catalog no.:208052, Qiagen, Germantown Rd, Germantown, United States) and 8 μ L of DNase-free water. The relative expression levels of genes normalized to β -Actin were calculated using the $2^{-\Delta\Delta C_T}$ method (Livak and Schmittgen 2001).

Statistical analysis

The collected data from biochemical analysis and gene expression were analyzed using a one-way ANOVA test (SPSS program version 18.0). The Duncan test was used to estimate the significance of the differences between means at $P \leq 0.05$.

Results

Biochemical analysis

Urea, creatinine, and bilirubin levels were significantly increased in serum of the piroxicam group compared with the control group. Serum glutamic oxaloacetic transaminase (SGOT), Serum glutamic pyruvic transaminase (SGPT), and alkaline phosphatase (ALP) were significantly increased in

the piroxicam group compared with the control group. The level of these components in the serum of the SB group had no significant difference from the control group (Table 2).

Serum inflammation and cytokines

In this study, levels of IgG and IL-22 significantly reduced in serum of the Piroxicam group compared with the control group. While, levels of IgM and TNF- α significantly increased in serum of Piroxicam group compared with the control group. In contrast, levels of IgG and IL-22 were recorded as the highest values in SB group, while levels of IgM and TNF- α were recorded as the lowest values in SB group (Table 3).

Histopathology examination

The normal histological features of the hepatic lobule were observed in the control group. The central vein and surrounding hepatocytes associated with round nuclei and hepatic sinusoids lined with Kupffer cells were noted in the control group (Fig. 1a). Congested portal tracts associated with cellular infiltrations and vesicular degeneration were found in the piroxicam group (Fig. 1b, c). The hepatic lobules appeared less than the normal form in both the P+SP and P+SB groups (Fig. 1d, f). A few vesicles were observed in the SP group. Furthermore, the portal tract exhibited nearly the normal structure (Fig. 2a, b). Examination of sections of the liver of the SB group showed both the hepatic

Table 2 Biochemical analysis for sexual hormones

	Control	Piroxicam	P+SP	P+SB	SP	SB
Urea	28 ^d \pm 0.2	52 ^a \pm 0.4	35 ^b \pm 0.1	31 ^c \pm 0.2	30 ^c \pm 0.2	28 ^d \pm 0.2
Creatinine	0.75 ^d \pm 0.04	1.69 ^a \pm 0.05	0.96 ^b \pm 0.05	0.87 ^c \pm 0.06	0.84 ^c \pm 0.07	0.79 ^d \pm 0.05
Bilirubin	0.45 ^e \pm 0.05	0.75 ^a \pm 0.06	0.65 ^b \pm 0.05	0.57 ^c \pm 0.07	0.55 ^c \pm 0.04	0.5 ^d \pm 0.06
SGOT	76 ^e \pm 0.4	295 ^a \pm 0.6	165 ^b \pm 0.5	105 ^c \pm 0.4	80 ^d \pm 0.3	76 ^e \pm 0.3
SGPT	26 ^b \pm 0.2	29 ^a \pm 0.2	27 ^b \pm 0.3	26 ^b \pm 0.4	26 ^b \pm 0.1	25 ^{bc} \pm 0.1
ALP	72 ^d \pm 0.3	92 ^a \pm 0.4	79 ^b \pm 0.2	75 ^c \pm 0.1	72 ^d \pm 0.1	71 ^d \pm 0.1

All data are expressed as the mean \pm SEM. ^{a, b, c, d, e} values within a row with different superscripts differ significantly at $P < 0.05$

Table 3 ELISA analysis of IgG, IgM, TNF- α , and IL-22 in serum

	Control	Piroxicam	P+SP	P+SB	SP	SB
IgG (μ g/mL)	60 ^c \pm 0.2	45 ^e \pm 0.3	55 ^d \pm 0.1	64 ^{bc} \pm 0.2	68 ^b \pm 0.2	74 ^a \pm 0.3
IgM (μ g/mL)	70 ^d \pm 0.1	180 ^a \pm 0.5	90 ^b \pm 0.4	78 ^c \pm 0.3	65 ^e \pm 0.2	58 ^f \pm 0.3
TNF- α (pg/mL)	23 ^{de} \pm 0.3	160 ^a \pm 0.8	85 ^b \pm 0.4	60 ^c \pm 0.3	26 ^d \pm 0.2	21 ^e \pm 0.2
IL-22 (pg/mL)	21 ^{ab} \pm 0.1	17 ^c \pm 0.2	19 ^b \pm 0.2	20 ^b \pm 0.3	22 ^a \pm 0.1	23 ^a \pm 0.1

All data are expressed as the mean \pm SEM. ^{a, b, c, d, e} values within a row with different superscripts differ significantly at $P < 0.05$

Fig. 1 **a** A section of liver of control group showing the normal histological features of the hepatic lobule. Note the central vein (blue arrow), and surrounding hepatocytes associated with round nuclei (arrowhead) and hepatic sinusoids lined with Kupffer cells (red arrow), **b** a section of liver of piroxicam group showing vesicular degeneration (arrow), **c** a section of liver of mice of piroxicam group showing congested portal tract (yellow arrow) that associated with cellular infiltrations around it (red arrow), **d** a section of liver of P + SP, **e** a section of liver of P + SP group, **f** a section of liver of P + SB group (hematoxylin and eosin stain, scale bar 100 μ m) (color figure online)

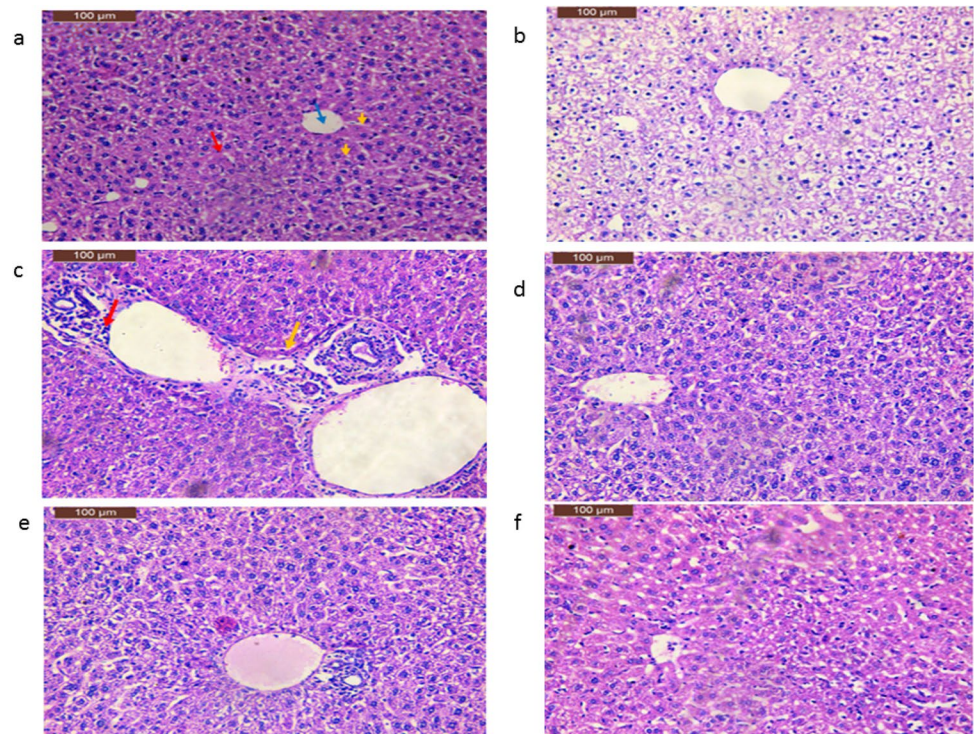


Fig. 2 **a** A section of liver of SP group. Note few vesicular degeneration (arrow), **b** a section of SP group, **c** a section of liver of SB group, **d** a section of liver of SB group (hematoxylin and eosin stain, scale bar 100 μ m)

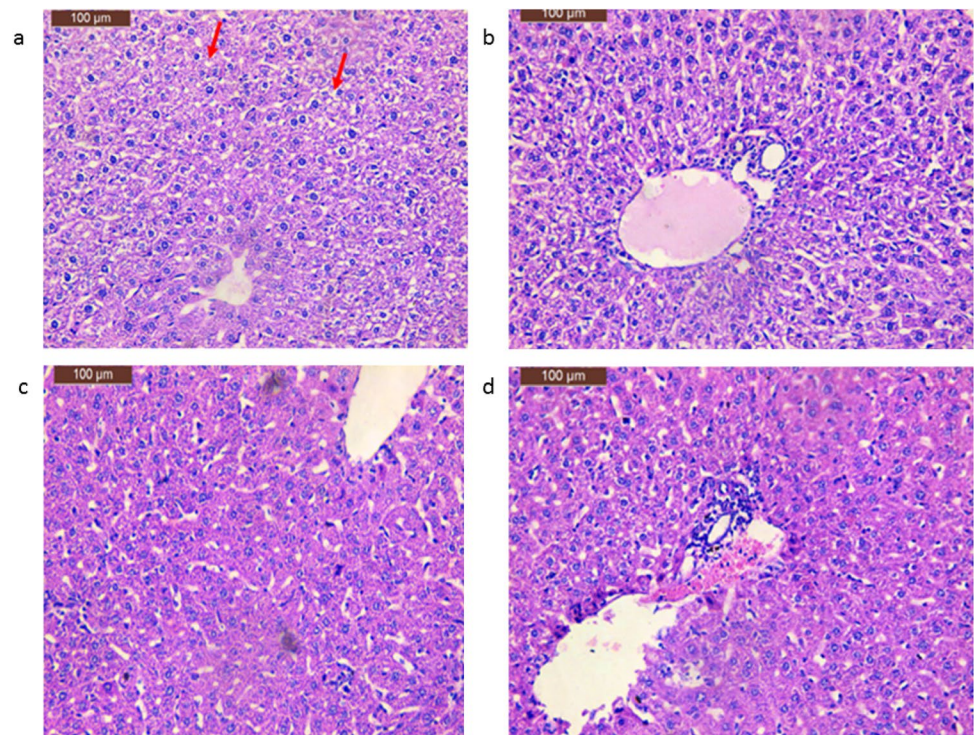


Fig. 3 **a** A section of kidney of control group showing the normal histological structure of the Bowman's capsules with peripheral squamous epithelium (yellow arrow), glomeruli (red arrow), urinary spaces (blue arrow) and convoluted tubules (black arrow), **b** a section of kidney of Piroxicam group showing glomerulus hyperemia (black arrow), granular degeneration (red arrow) and interstitial hyperemia (black arrow), **c** a section of kidney of P+SP group, **d** a section of kidney of P+SP group (hematoxylin and eosin stain, scale bar 100 μ m) (color figure online)

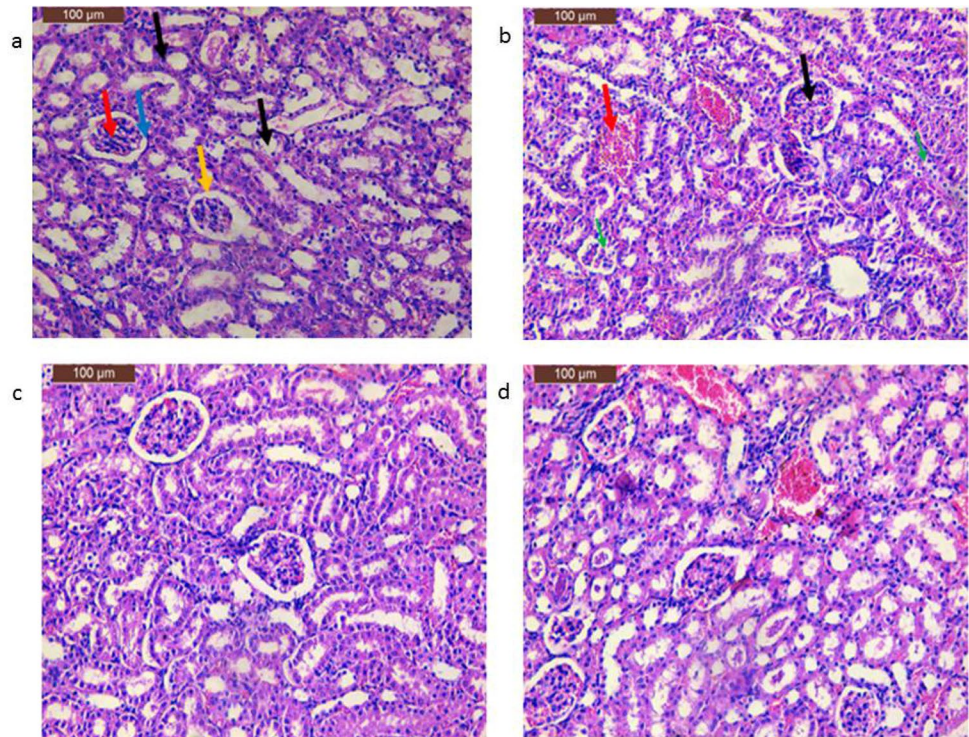
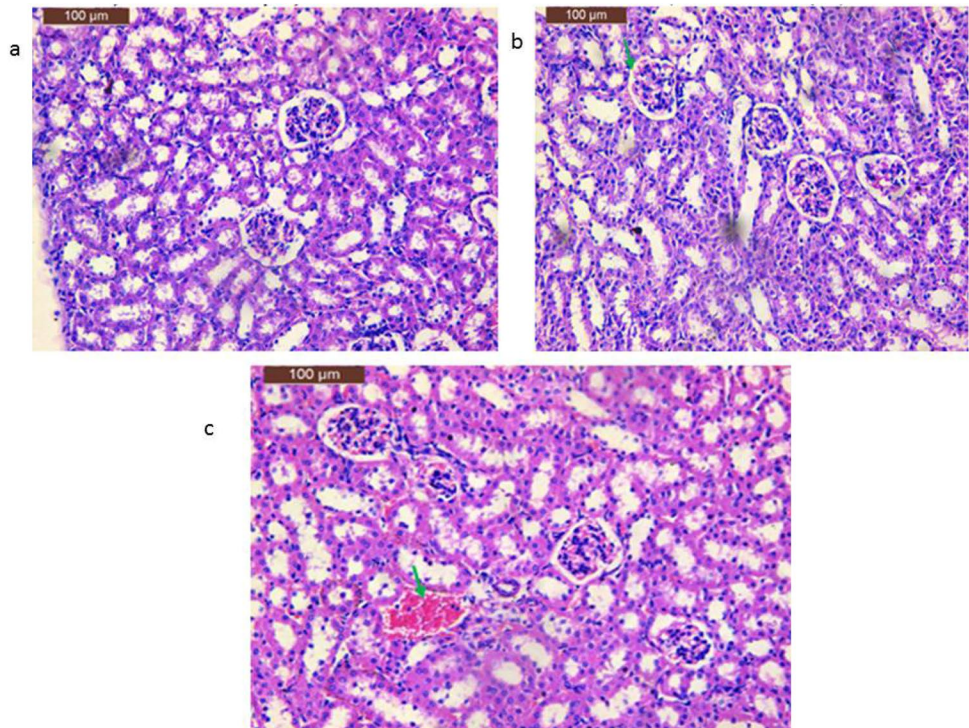


Fig. 4 **a** A section of kidney of P+SB group, **b** a section of kidney of SP group, note mild glomerulus hyperemia (arrow), **c** a section of kidney of mice of SB group, note interstitial hyperemia (arrow) (hematoxylin and eosin stain, scale bar 100 μ m)



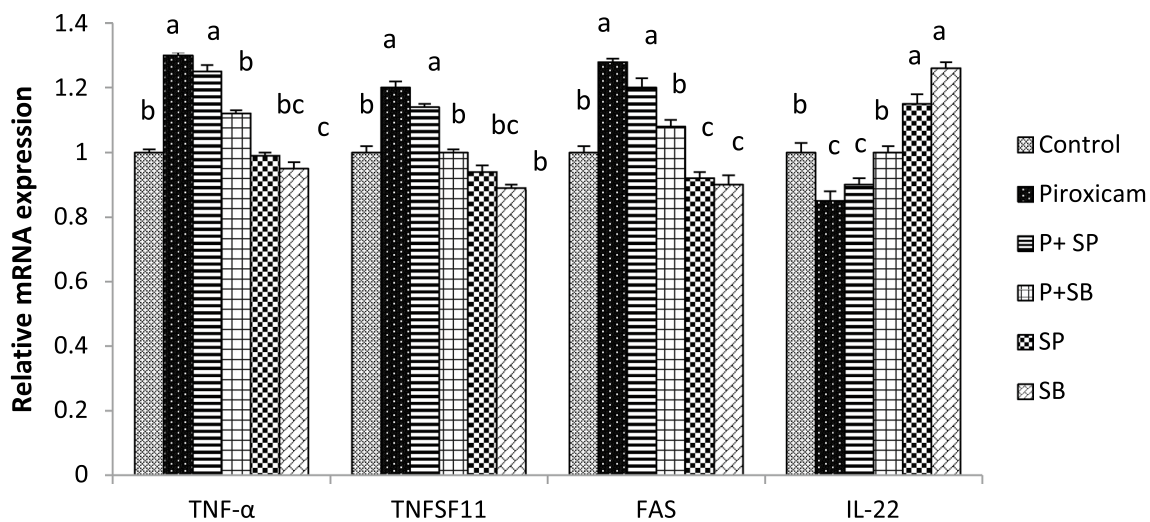


Fig. 5 Expression of TNF-α, TNFSF11, FAS, and IL-22 genes in mice liver under the effect of piroxicam drug and mutant strains enriched with selenium

lobules and portal tracts appeared more or less in normal form (Fig. 2c, d).

The normal histological structure of the Bowman’s capsules with peripheral squamous epithelium, glomeruli, urinary spaces, and convoluted tubules was observed in the control group (Fig. 3a). Glomerular hyperemia, granular degeneration, and interstitial hyperemia were observed in the piroxicam group (Fig. 3b). The interstitial hyperemia and cell debris in the lumen of convoluted tubules were observed in the P+SP group. No glomerulus hyperemia was found in this group (Fig. 3c, d). In the P+SB group, the renal corpuscles appeared more or less like control (Fig. 4a). The

Bowman’s capsules, glomeruli, urinary spaces, and convoluted tubules appeared more or less like normal form. Mild glomerular hyperemia was noted in the SP group (Fig. 4b). The glomeruli and renal tubules appeared more or less in normal form. Interstitial hyperemia was noted in the SB group (Fig. 4c).

Expression of inflammatory and anti-inflammatory genes in liver and kidney

Expression of TNF-α, TNFSF11, and FAS genes was significantly up-regulated in the liver of the piroxicam group compared with the control group. The same genes were

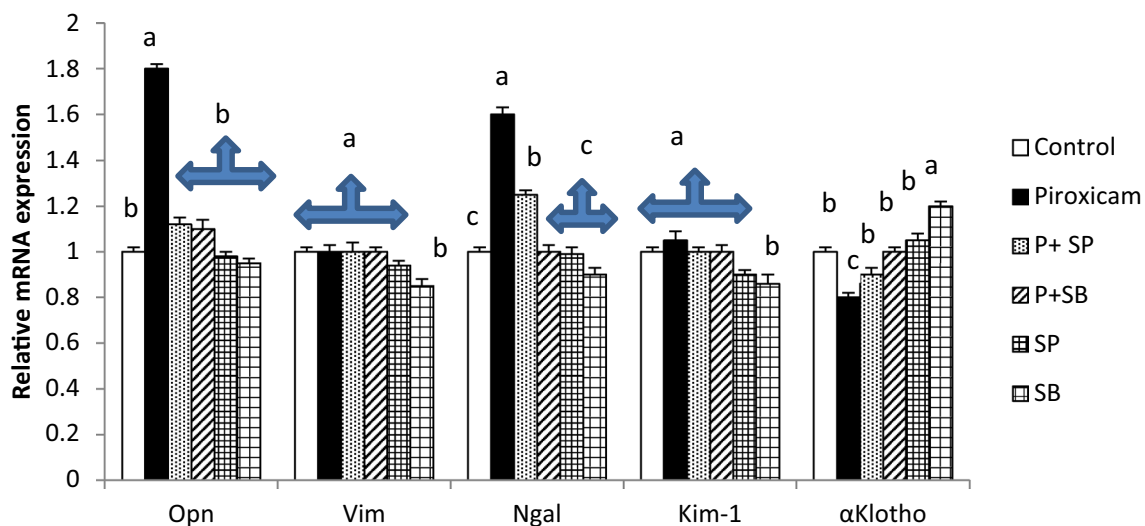


Fig. 6 Expression of Opn, Vim, Kim, Ngal, and α-klotho genes in mice kidney under the effect of piroxicam drug and mutant strains enriched with selenium

down-regulated in the livers of the SP and SB groups compared with the control group. There were no significant differences between control, P+SP, and P+SB groups. In contrast, expression of the IL-22 gene was down-regulated in the liver of the piroxicam group and up-regulated in the liver of the SP and SB groups compared with the control group (Fig. 5). Expression of *Opn* and *Kim* genes was significantly up-regulated in the kidneys of the piroxicam group compared to the control group. Expression of α *Klotho* gene was significantly down-regulated in the kidneys of the piroxicam group while it was significantly up-regulated in the kidneys of the SB group compared with the control group (Fig. 6).

Discussion

Recently, probiotics were used as a supplement for reaching optimal health. However, because there is a lack of research on using biological methods to prevent the adverse effects of some of the most commonly used drugs, the goal of this study was to see if probiotic mutants with high amounts of selenium uptake are better able to alleviate the oxidative stress caused by piroxicam in mice. Probiotics may have high potential when used as a treatment for kidney disease due to their beneficial effects in reducing inflammation and uremic toxins, which improve kidney function (Vaziri et al. 2016). *Bifidobacterium* was able to reduce the levels of urea nitrogen and ammonia in the blood (Fagundes et al. 2018). *Lactobacillus delbrueckii* and *Sporosarcina pasteurii* hydrolyze urea in vitro and have been shown to be potential urea-targeted agents for enteric dialysis (Ranganathan et al. 2006). *Bacillus pasteurii* or *Sporosarcina pasteurii* reduced the development of kidney disease and helped to extend the life span (Néstor et al. 2020). In the present study, levels of urea, creatinine, bilirubin, Serum glutamic oxaloacetic transaminase (SGOT), Serum glutamic pyruvic transaminase (SGPT), and Alkaline Phosphatase (ALP) were significantly increased in the piroxicam group compared with the control group. In contrast, the previous levels of liver and kidney functions were reduced in SB group compared with the control group. These results are consistent with the study of Pandit et al. (2012). Hussaini and Farrington (2014) documented the relative rise of ALT and ALP accompanying the liver injury. Blood urea nitrogen and ammonia levels were reduced by *Bifidobacterium* genera (Fagundes et al 2018).

Several studies have revealed that tumor necrosis factor (TNF- α) gene and tumor necrosis factor superfamily member11 (TNFSF11) gene were up-regulated in inflammatory cells (Aggarwal et al 2012). Another study indicated that *Fas* gene has a vital role in delivering death signals to the immune system (da Fonseca et al 2010). Also, it was observed that downregulation of the expression of the *Fas* gene causes lymphocyte proliferation and autoimmune

disease (Rieux-Laucat et al 1995). Increasing the IL-22 expression in intestinal mucosa has enhanced intestinal repair. Moreover, IL-22 deficiency can change the intestinal microbiota, thus worsening disease severity (Pickert et al 2009; Zenewicz et al 2013). Some investigations on mice indicated that overexpression of *Opn*, *Vim*, *Ngal*, and *Kim-1* genes were associated with chronic kidney disease (Koppe et al 2015). In contrast, the expression of α *Klotho* gene was significantly reduced in the CKD model mice (Goswami 2016).

The present study showed that the liver vesicles were degraded, and a clogged portal accompanied by piroxicam-induced cellular infiltration was revealed. Hepatic lobules were observed less or more than normal in the P-SP and P-SB groups. These findings support our previous findings that oxidative stress caused increased damage to the liver and kidney tissues in a mouse model via Piroxicam toxicity, as well as the role of probiotics in overcoming these damages (Bindu et al. 2020; Liu et al. 2020). Also, *L. plantarum* is involved in the anti-inflammatory activity which increases interleukin production by reducing the secretion of pro-inflammatory cytokines (Noh et al. 2015).

The results of the expression of TNF- α , TNFSF11, *FAS*, *Opn*, and *Kim* genes showed a significant increase in the piroxicam group and a significant reduction in the BS group. While expression of IL-22 and α *Klotho* genes showed a significant reduction in the piroxicam group and a significant increase in the BS group. This clear change in gene expression reflects the role of probiotics in restoring balance in gene expression, especially in genes responsible for the proper functioning of the liver and kidney in mice. There is a lot of research supporting this trend, and it strongly supports the extensive use of probiotics to maintain optimal health even under difficult stresses, such as the side effects of many therapeutically important drugs. In mice, selenium-enriched *Bifidobacterium longum* reduced ulcerative colitis (UC) and was associated with TNF- and IL-6 gene down-regulation and IL-2 and IL-10 gene up-regulation (Khattab et al. 2022). Also, treatment with probiotics (*L. rhamnosus* MTCC 5957, *L. rhamnosus* MTCC 5897, *L. fermentum* MTCC 5898, and *L. rhamnosus GG*) similarly improved liver *Pepck* and *G6pc* gene expression (Dang et al. 2018; Verma and Shukla 2014; Kim et al. 2013). Furthermore, *L. plantarum* therapy reduced the expression of *FAS* and TNF- α genes (Balakumar et al. 2018; Soundharrajan et al. 2020). Treatment of cholesterol-treated cells with *L. plantarum* AR113 or *L. casei* pWQH01 decreased the expression of SREBP-1c, ACC, *FAS*, and TNF α gene, and increased the expression of AMPK and PPAR α gene (Huang et al. 2020). Moreover, *L. plantarum* YYC-3 had reduced expression of the inflammatory cytokine interleukin IL-22 gene (Yue et al. 2020). The present study showed that expression of inflammatory genes

was reduced while expression of anti-inflammatory genes was increased in the SB group in liver and kidney tissues. Therefore, the selenium-enriched BSe50/20/1 mutant strain is useful for limiting the side effects of the piroxicam drug.

Conclusion

This study contributes to our understanding of the critical cause incidence of liver and kidney injury resulting in administration of high-dose of piroxicam drug. Our data suggest that high-dose piroxicam medication shifts the biochemical parameters of liver and kidney function and causes vesicular degeneration in liver tissue and causes glomerular hyperemia, granular degeneration, and interstitial hyperemia in the kidney. The selenium-enriched BSe50/20/1 mutant can repair liver and kidney damage, improve liver and kidney function, reduce expression of inflammatory genes, and increase expression of anti-inflammatory genes in the liver and kidney.

Acknowledgements The authors acknowledge Princess Nourah bint Abdulrahman University Researchers Supporting Project number (PNURSP2022R5), Princess Nourah bint Abdulrahman University, Riyadh, Saudi Arabia

Author contributions This study was done in collaboration with all authors. AD and AK, designed this study. AA, AD and SO, participated in the conduct of the study. AD, extracted RNA and cDNA synthesis. AA, KhA and GA, analyzed the data. AD and AK, drafted the manuscript. AD and AK, critically revised the manuscript. All authors read and approved the final manuscript.

Funding No funding received.

Data availability The datasets used and/or analyzed during the current study are available from the corresponding author on reasonable request.

Declarations

Conflict of interest The authors declare that they have no conflict of interest.

Ethical approval The experimental procedure used in this investigation was approved by the Animal Care and Use Committee of National Research Centre in Egypt.

Informed consent The authors declare that they consent to participate to this study.

Consent for publication All authors have given consent for the paper to be published by the corresponding author.

References

- Aggarwal BB, Gupta SC, Kim JH (2012) Historical perspectives on tumor necrosis factor and its superfamily: 25 years later, a golden journey. *Blood* 119(3):651–665. <https://doi.org/10.1182/blood-2011-04-325225>
- Aithal GP (2011) Hepatotoxicity related to antirheumatic drugs. *Nat Rev Rheumatol* 7:139–150. <https://doi.org/10.1038/nrrheum.2010.214>
- Balakumar M, Prabhu D, Sathishkumar C, Prabu P, Rokana N, Kumar R, Raghavan S, Soundarajan A, Grover S, Batish VK, Mohan V (2018) Improvement in glucose tolerance and insulin sensitivity by probiotic strains of Indian gut origin in high-fat diet-fed C57BL/6J mice. *Eur J Nutr* 57(1):279–295. <https://doi.org/10.1007/s00394-016-1317-7>
- Benesic A, Gerbes AL (2015) Drug-induced liver injury and individual cell models. *Dig Dis* 33(4):486–491. <https://doi.org/10.1159/000374094>
- Bindu S, Mazumder S, Bandyopadhyay U (2020) Non-steroidal anti-inflammatory drugs (NSAIDs) and organ damage: a current perspective. *Biochem Pharm* 180:1141–1147. <https://doi.org/10.1016/j.bcp.2020.114147>
- Chaïmnuay S, Allison JJ, Curtis JR (2006) Risks versus benefits of cyclooxygenase-2-selective nonsteroidal antiinflammatory drugs. *Am J Health Syst Pharm* 63(19):1837–1851. <https://doi.org/10.2146/ajhp050519>
- da Fonseca RR, Kosiol C, Vinař T, Siepel A, Nielsen R (2010) Positive selection on apoptosis related genes. *FEBS Lett* 584:469–476. <https://doi.org/10.1016/j.febslet.2009.12.022>
- Dang F, Jiang Y, Pan R, Zhou Y, Wu S, Wang R, Zhuang K, Zhang W, Li T, Man C (2018) Administration of *Lactobacillus paracasei* ameliorates type 2 diabetes in mice. *Food Funct* 9(7):3630–3639. <https://doi.org/10.1039/C8FO00081F>
- Fagundes RAB, Soder TF, Grokoski KC, Benetti F (2018) Mendes RH probiotics in the treatment of chronic kidney disease: a systematic review. *J Bras Nefrol* 40(3):278–286. <https://doi.org/10.1590/2175-8239-JBN-3931>
- Fuller K, Wong B, Fox S, Choi Y, Chambers TJ (1998) TRANCE is necessary and sufficient for osteoblast-mediated activation of bone resorption in osteoclasts. *J Exp Med* 188:997–1001. <https://doi.org/10.1084/jem.188.5.997>
- Ghlichloo I, Gerriets V (2022) Nonsteroidal anti-inflammatory drugs (NSAIDs). In: StatPearls [Internet]. StatPearls Publishing, Treasure Island. <https://www.ncbi.nlm.nih.gov/books/NBK547742/>
- Gooch K, Culleton BF, Manns BJ, Zhang J, Alfonso H, Tonelli M, Frank C, Klarenbach S, Hemmelgarn BR (2007) NSAID use and progression of chronic kidney disease. *Am J Med* 120:280.e1–280.e7. <https://doi.org/10.1016/j.amjmed.2006.02.015>
- Goswami R (2016) Primer on the metabolic bone diseases and disorders of mineral metabolism. *Indian J Med Res* 144(3):489–490. <https://doi.org/10.4103/0971-5916.198664>
- Harirforoosh S, Asghar W, Jamali F (2013) Adverse effects of non-steroidal antiinflammatory drugs: an update of gastrointestinal, cardiovascular and renal complications. *J Pharm Pharm Sci* 16(5):821–847. <https://doi.org/10.18433/J3VW2F>
- Hu J, Wang C, Ye L, Yang W, Huang H, Meng F, Ding Z (2015) Antitumour immune effect of oral administration of *Lactobacillus plantarum* to CT26 tumour-bearing mice. *J Biosci* 40(2):269–279
- Huang W, Wang G, Xia Y, Xiong Z, Ai L (2020) Bile salt hydrolase-overexpressing *Lactobacillus* strains can improve hepatic lipid accumulation in vitro in an NAFLD cell model. *Food Nutr Res* 12:64. <https://doi.org/10.29219/fnr.v64.3751>
- Hussaini SH, Farrington EA (2014) Idiosyncratic drug-induced liver injury: an update on the 2007 overview. *Expert Opin Drug Saf* 13(1):67–81. <https://doi.org/10.1517/14740338.2013.828032>

- Kawakami K, Takeshita A, Furushima K, Miyajima M, Hatamura I, Kuro-o M, Furuta Y, Sakaguchi K (2017) Persistent fibroblast growth factor 23 signalling in the parathyroid glands for secondary hyperparathyroidism in mice with chronic kidney disease. *Sci Rep* 7:1–14. <https://doi.org/10.1038/srep40534> **Benesic**
- Khattab AA, Darwish AM, Othman SI, Allam AA, Alqhtani HA (2022) Anti-inflammatory and immunomodulatory potency of selenium-enriched probiotic mutants in mice with induced ulcerative colitis. *Biol Trace Elem Res*. <https://doi.org/10.1007/s12011-022-03154-1>
- Kim SW, Park KY, Kim B, Kim E, Hyun CK (2013) *Lactobacillus rhamnosus* GG improves insulin sensitivity and reduces adiposity in high-fat diet-fed mice through enhancement of adiponectin production. *Biochem Biophys Res Commun* 431(2):258–263. <https://doi.org/10.1016/j.bbrc.2012.12.121>
- Koppe L, Mafra D, Fouque D (2015) Probiotics and chronic kidney disease. *Kidney Int* 88:958–966. <https://doi.org/10.1038/ki.2015>
- Lafrance JP, Miller DR (2009) Selective and non-selective non-steroidal antiinflammatory drugs and the risk of acute kidney injury. *Pharmacoevidmiol Drug Saf* 18:923–931. <https://doi.org/10.1002/pds.1798>
- Levey AS, Coresh J (2012) Chronic kidney disease. *Lancet* 379:165–180. [https://doi.org/10.1016/S0140-6736\(11\)60178-5](https://doi.org/10.1016/S0140-6736(11)60178-5)
- Liu Y, Chen K, Li F, Gu Z, Liu Q, He L, Shao T, Song Q, Zhu F, Zhang L, Jiang M (2020) Probiotic LGG prevents liver fibrosis through inhibiting hepatic bile acid synthesis and enhancing bile acid excretion in mice. *Hepatology* (baltim, Md) 71(6):2050–2066. <https://doi.org/10.1002/hep.30975>
- Livak KJ, Schmittgen TD (2001) Analysis of relative gene expression data using real-time quantitative PCR and the 2^{(-Delta Delta C (T))} method. *Methods* 25:402–408. <https://doi.org/10.1006/meth.2001.1262>
- Nderitu P, Doos L, Jones PW, Davies SJ, Kadam UT (2013) Non-steroidal anti-inflammatory drugs and chronic kidney disease progression: a systematic review. *Fam Pract* 30:247–255. <https://doi.org/10.1093/fampra/cms086>
- Néstor DLV, Robles-Vera N, Toral I, O'Valle M, Moleon F, Gómez-Guzmán J, Romero M, Duarte M, Sánchez M, Jiménez M, Duarte RJ (2020) *Lactobacillus fermentum* CECT5716 prevents renal damage in the NZBWF1 mouse model of systemic lupus erythematosus. *Food Funct* 11:5266–5274. <https://doi.org/10.1039/D0FO00578A>
- Noh SY, Kang SS, Yun CH, Han SH (2015) Lipoteichoic acid from *Lactobacillus plantarum* inhibits Pam2CSK4-induced IL-8 production in human intestinal epithelial cells. *Mol Immunol* 64(1):183–189. <https://doi.org/10.1016/j.molimm.2014.11.014>
- Pandit A, Sachdeva T, Bafna P (2012) Drug-induced hepatotoxicity: a review. *J Appl Pharm Sci* 2(5):233–243. <https://doi.org/10.7324/JAPS.2012.2541>
- Pickert G, Neufert C, Leppkes M, Zheng Y, Wittkopf N, Warntjen M, Lehr HA, Hirth S, Weigmann B, Wirtz S, Ouyang W (2009) STAT3 links IL-22 signaling in intestinal epithelial cells to mucosal wound healing. *J Exp Med* 206:1465–1472. <https://doi.org/10.1084/jem.20082683>
- Ranganathan N, Patel BG, Ranganathan P, Marczylo J, Dheer R, Pechenyak B, Dunn SR, Verstraete W, Decroos K, Mehta R, Friedman EA (2006) In vitro and in vivo assessment of intraintestinal bacteriotherapy in chronic kidney disease. *Asaio J* 52:70–79. <https://doi.org/10.1097/01.mat.0000191345.45735.00>
- Rieux-Laucat F, Le Deist F, Hivroz CE, Roberts IA, Debatin KM, Fischer A, De Villartay JP (1995) Mutations in Fas associated with human lymphoproliferative syndrome and autoimmunity. *Science* 268:1347–1349. <https://doi.org/10.1126/science.7539157>
- Ronald RB (2002) Non-steroidal anti-inflammatory agents. In: Foye WO (ed) Principles of medical chemistry, 5th edn. Williams and Wilkins, New York, pp 1059–1069. <https://doi.org/10.4137/CMAMD.S29463>
- Sharaf LK, Sharma M, Chandel D, Shukla G (2018) Pro-phylactic intervention of probiotics (*L. acidophilus*, *L. rhamnosus* GG) and celecoxib modulate Bax-mediated apoptosis in 1,2-dimethylhydrazine-induced experimental colon carcinogenesis. *BMC Cancer* 18(1):1–3. <https://doi.org/10.1186/s12885-018-4999-9>
- Shekelle PG, Newberry SJ, FitzGerald JD, Motala A, O'Hanlon CE, Tariq A, Okunogbe A, Han D, Shanman R (2017) Management of gout: a systematic review in support of an American college of physicians clinical practice guideline. *Ann Intern Med* 166(1):37–51. <https://doi.org/10.7326/M16-0461>
- Soundharajan I, Kuppusamy P, Srisesharam S, Lee JC, Sivanesan R, Kim D, Choi KC (2020) Positive metabolic effects of selected probiotic bacteria on diet-induced obesity in mice are associated with improvement of dysbiotic gut microbiota. *FASEB J* 34(9):12289–12307. <https://doi.org/10.1096/fj.202000971R>
- Sriutha P, Sirichanchuen B, Permsuwan U (2018) Hepatotoxicity of nonsteroidal anti-inflammatory drugs: a systematic review of randomized controlled trials. *Int J Hepatol*. <https://doi.org/10.1155/2018/5253623>
- Tanaka Y (2018) Clinical immunity in bone and joints. *J Bone Miner Metab* 37(1):2–8. <https://doi.org/10.1007/s00774-018-0965-5>
- Van den Bekerom MPJ, Sjer A, Somford MP, Bulstra GH, Struijs PAA, Kerkhoffs GMJ (2015) Non-steroidal anti-inflammatory drugs (NSAIDs) for treating acute ankle sprains in adults: benefits outweigh adverse events. *Knee Surg Sports Traumatol Arthrosc* 23(8):2390–2399
- Vaziri ND, Zhao YY, Pahl MV (2016) Altered intestinal microbial flora and impaired epithelial barrier structure and function in CKD: the nature, mechanisms, consequences and potential treatment. *Nephrol Dial Transplant* 31:737–746. <https://doi.org/10.1093/ndt/gfv095>
- Verma A, Shukla G (2014) Synbiotic (*Lactobacillus rhamnosus* + *Lactobacillus acidophilus* + inulin) attenuates oxidative stress and colonic damage in 1,2 dimethylhydrazine dihydrochloride-induced colon carcinogenesis in Sprague-Dawley rats. *Eur J Cancer Prev* 23(6):550–559
- Yue Y, Ye K, Lu J, Wang X, Zhang S, Liu L, Yang B, Nassar K, Xu X, Pang X, Lv J (2020) Probiotic strain *Lactobacillus plantarum* YYC-3 prevents colon cancer in mice by regulating the tumour microenvironment. *Biomed Pharmacother* 127:110159. <https://doi.org/10.1016/j.biopha.2020.110159>
- Zenewicz LA, Yin X, Wang G, Elinav E, Hao L, Zhao L, Flavell RA (2013) IL-22 deficiency alters colonic microbiota to be transmissible and colitogenic. *J Immunol* 190:5306–5312. <https://doi.org/10.4049/jimmunol.1300016>

Publisher's Note Springer Nature remains neutral with regard to jurisdictional claims in published maps and institutional affiliations.

Springer Nature or its licensor holds exclusive rights to this article under a publishing agreement with the author(s) or other rightsholder(s); author self-archiving of the accepted manuscript version of this article is solely governed by the terms of such publishing agreement and applicable law.