

Clavicle Elevation or Shoulder Girdle Depression in Acromioclavicular Joint Dislocation

A Radiological Investigation

Fady Azar,^{*†} MD, Christian Pfeifer,[†] MD, Volker Alt,[†] MD, Benedikt Pregler,[‡] MD, Isabella Weiss,[†] Agnes Mayr,[†] and Maximilian Kerschbaum,^{†§} MD

Investigation performed at Clinic of Trauma Surgery, University Medical Center Regensburg, Regensburg, Germany

Background: The side-comparative coracoclavicular (CC) distance is used to describe the vertical instability component of acute acromioclavicular (AC) joint dislocations. Elevation of the clavicle or a depression of the shoulder girdle can lead to an increased CC distance. The dislocation direction has not yet been investigated and is not included in common classification systems.

Hypothesis: Clavicle elevation is primarily responsible for vertical dislocation in AC joint separation.

Study Design: Cross-sectional study; Level of evidence, 3.

Methods: Weighted and nonweighted bilateral plain anteroposterior views of the shoulder girdles of patients with AC joint dislocations (Rockwood [RW] types III and V), diagnosed in our trauma department between 2001 and 2018, were included in this study. After determining the CC distance, a side-comparative determination of the positions of both the clavicle and shoulder girdle, with reference to the spinal column, was conducted.

Results: In total, 245 bilateral plain anteroposterior views were evaluated (RW III, n = 116; RW V, n = 129). All patients showed a side-comparative clavicle elevation (mean ± SD: RW III, 5 ± 14 mm; RW V, 11 ± 17 mm) in weighted and nonweighted views. While no depression of the shoulder girdle was measured in RW III injuries (weighted and nonweighted views, 0 ± 11 mm), dropping of the shoulder girdle in RW V lesions on nonweighted views was observed (-5 ± 11 mm).

Conclusion: Vertical dislocation is mostly associated with clavicle elevation in RW III injuries, while in high-grade AC joint dislocations (RW V), a combination of clavicle elevation and shoulder girdle depression is present. A significantly greater superior displacement of the clavicle in RW V injuries was seen in weighted views, while a depression of the shoulder girdle could be detected in nonweighted views. For the first time, these results include the dislocation direction in the classification of an AC joint injury. Further studies are needed to investigate the extent to which dislocation types differ in optimal therapy and outcome.

Keywords: AC joint dislocation; acromioclavicular joint; Rockwood classification; vertical instability; shoulder girdle

Acromioclavicular (AC) joint dislocations are one of the most common shoulder injuries that typically occur in young adult athletes.⁸ Direct or indirect mechanical trauma to the AC joint can result in ligament rupture with a subsequent instability.⁶ Especially in higher-grade AC joint dislocations, persistent impairment of shoulder function can occur.⁵ The classification of injury severity and therapy recommendations is essentially based on the degree of vertical and horizontal displacement.⁷ While

current studies investigate mainly the horizontal instability component,^{3,13} the degree of vertical instability is classified according to the radiological classification system presented by Rockwood¹² in 1989. In addition to an anatomic description of injured structures, the side-comparative coracoclavicular (CC) distance is used to describe the vertical instability component.¹² Vertical instability, as measured by the increased CC distance, becomes clinically visible by elevation of the injured clavicle. In contrast, some authors describe a “pseudo-elevation” of the clavicle in which the clavicle retains its position but depression of the shoulder girdle occurs owing to the loss of the bony bridge to the thorax.⁶

The Orthopaedic Journal of Sports Medicine, 7(11), 2325967119879927

DOI: 10.1177/2325967119879927

© The Author(s) 2019

This open-access article is published and distributed under the Creative Commons Attribution - NonCommercial - No Derivatives License (<http://creativecommons.org/licenses/by-nc-nd/4.0/>), which permits the noncommercial use, distribution, and reproduction of the article in any medium, provided the original author and source are credited. You may not alter, transform, or build upon this article without the permission of the Author(s). For article reuse guidelines, please visit SAGE's website at <http://www.sagepub.com/journals-permissions>.

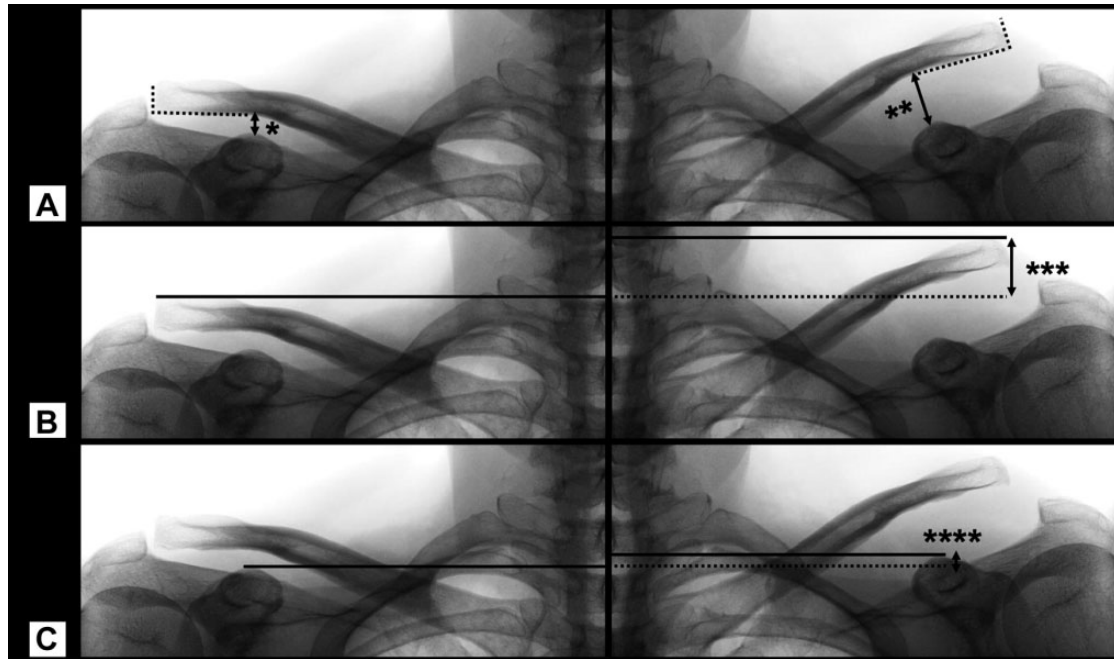


Figure 1. Standardized radiological measurement (mm) in a patient with a Rockwood type V injury of the left acromioclavicular joint. Bilateral plain views of the shoulder girdles with a 15-kg axial load on both sides (weighted). (A) Measurement of the coracoclavicular distance on the nonaffected side (*) and the affected side (**). (B) Position determination of the clavicle (***). In this case, a superior displacement of the affected clavicle is measured. (C) Position determination of the shoulder girdle (****). In this case, a slightly higher shoulder girdle of the affected side as compared with the nonaffected side is measured.

Increased CC distance is caused by elevation of the distal clavicle, depression of the shoulder girdle, or both. The direction of dislocation is not currently taken into account, nor is it included in current classification systems, which are based on only the increased CC distance. Therefore, the aim of the study was to evaluate whether the elevation of the clavicle or the depression of the shoulder girdle is mainly responsible for the vertical dislocation.

METHODS

This study was approved by the ethics committee of the University of Regensburg. Patients with acute high-grade AC joint separations (Rockwood III and V) diagnosed in our trauma department between 2001 and 2018 were identified. Patients with bilateral plain anteroposterior views of the shoulder girdles (weightbearing or nonweightbearing) were included. Bilateral views with incorrect projection or low image quality and patients with bilateral AC joint injuries, fractures of the shoulder girdle, or concomitant injuries of the upper extremities were excluded.

Radiological Evaluation

Radiological evaluation was carried out on the basis of bilateral plain anteroposterior views of the shoulder girdles in the upright position. Nonweightbearing views and stress views with 15-kg axial load on both sides (weighted views) were evaluated.

Radiological measurements were carried out after an exact perpendicular alignment of the spinal column (Figures 1 and 2). All measurements were performed digitally using OsiriX MD (Pixmeo) software.

CC Distance and Rockwood Classification

The CC distance is the distance between the coracoid process (highest point) and the clavicle (inferior cortex). After the CC distance was measured on the affected and nonaffected side, ΔCC was calculated as the percentage increase of the CC distance of the affected side as compared with the nonaffected side, $\Delta CC (\%) = (\text{affected side} / \text{nonaffected side} \times 100) - 100$. The CC distance measurements

[§]Address correspondence to Maximilian Kerschbaum, MD, Clinic of Trauma Surgery, University Medical Center Regensburg, Franz-Josef-Strauss Allee 11, D-93053 Regensburg, Germany (email: maximilian.kerschbaum@ukr.de).

^{*}Clinic of Trauma Surgery, Hospital Weiden, Weiden in der Oberpfalz, Germany.

[†]Clinic of Trauma Surgery, University Medical Center Regensburg, Regensburg, Germany.

[‡]Clinic of Radiology, University Medical Center Regensburg, Regensburg, Germany.

The authors declared that there are no conflicts of interest in the authorship and publication of this contribution. AOSSM checks author disclosures against the Open Payments Database (OPD). AOSSM has not conducted an independent investigation on the OPD and disclaims any liability or responsibility relating thereto.

Ethical approval for this study was obtained from the University Medical Center Regensburg (ID No. 18-1254-104).

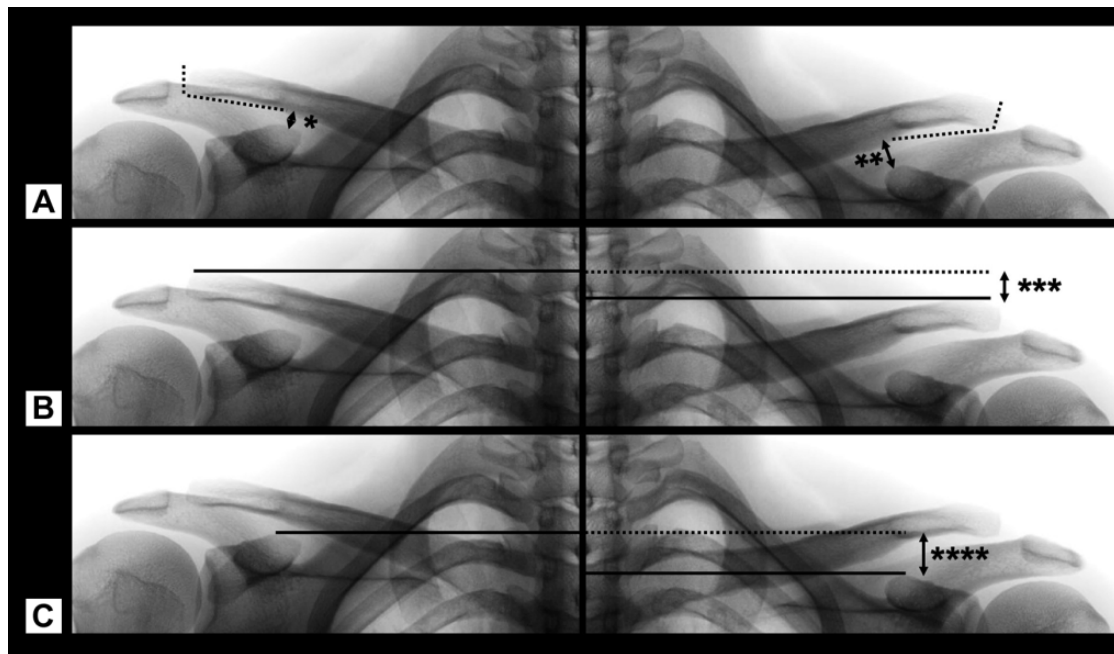


Figure 2. Standardized radiological measurement (mm) in a patient with a Rockwood type V injury of the left acromioclavicular joint. Bilateral plain views of the shoulder girdles without axial load (nonweighted). (A) Measurement of the coracoclavicular distance on the nonaffected side (*) and the affected side (**). (B) Position determination of the clavicle (***). In this case, a slightly inferior displacement of the affected clavicle is measured. (C) Position determination of the shoulder girdle (****). In this case, dropping of the affected shoulder girdle as compared with the nonaffected side is measured.

were performed on both sides using the same distance of 3 cm to the lateral clavicle end (Figures 1A and 2A, dotted line).

ΔCC was used to grade the injuries according the Rockwood classification.¹² In Rockwood type III injuries, ΔCC is between 25% and 100%. In Rockwood type V, ΔCC is >100%.

Position Determination of the Clavicle

The position of the clavicle was determined by a side-comparative height measurement with reference to the spinal column. After perpendicular alignment of the spine, horizontal lines (90° to the spine) could be drawn up to the upper cortex of the lateral end of the clavicles on both sides. The height difference of both clavicles was then measured in millimeters (ΔCCl). Figure 1B shows a superior displacement of the clavicle as compared with the nonaffected side, while a slightly inferior displacement can be observed in Figure 2B.

Position Determination of the Shoulder Girdle

The position of the shoulder girdle was also evaluated by a side-comparative height measurement. The highest point of the coracoid process was defined as reference for the shoulder girdle. Analogous to the clavicle measurement, horizontal lines 90° to the spine were used for the side-comparative position determination. The height difference of both shoulder girdles was then measured in millimeters

(ΔSG). Figure 2C shows a dropping of the shoulder girdle as compared with the nonaffected side, while the affected shoulder girdle in Figure 1C is slightly higher.

Statistical Analysis

Statistical analysis was carried out using SPSS (v 25; IBM). The chi-square independence test was performed to compare categorical variables, and the independent *t* test was used to compare continuous variables after determining that all variables were normally distributed (Kolmogorov-Smirnov normality test). *P* values <.05 were considered significant. All graphs are displayed as mean value and 95% CI.

RESULTS

In total, 245 patients (female, 24; male, 221) met the inclusion and exclusion criteria. Table 1 summarizes the injury patterns and radiological modalities of the included patients.

Dislocation Direction Depending on Rockwood Classification

The overall collective (weighted and nonweighted views) showed a mean \pm SD side-comparative clavicle elevation (ΔCCl) of 8 ± 16 mm, while a mean dropping of the shoulder girdle (ΔSG) of 1 ± 12 mm could be measured.

TABLE 1
Injury Patterns of Included Patients

	Total	Rockwood Type III	Rockwood Type V
Patients, n	245	116	129
CC difference, ^a mm, mean ± SD	8.6 ± 5.1	4.5 ± 2.1	12.4 ± 4.1
ΔCC, ^b %, mean (minimum-maximum)	100 (25-373)	48 (25-91)	147 (100-373)
Bilateral plain views, weighted:nonweighted, n	153:92	84:32	69:60

^aCC difference: difference between coracoclavicular distance of the affected and nonaffected sides.

^bΔCC: percentage increase of the coracoclavicular distance of the affected side as compared with the nonaffected side.

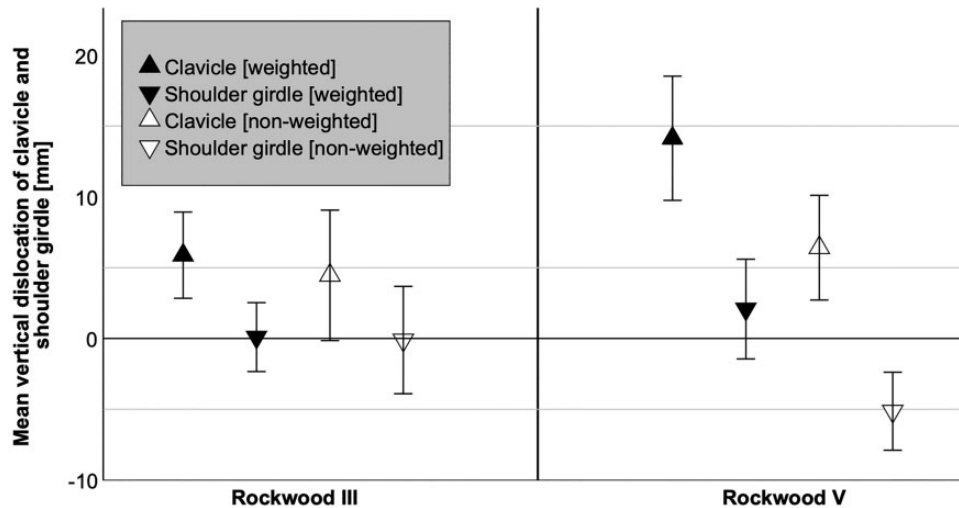


Figure 3. Mean vertical dislocation of the clavicle and shoulder girdle in relation to the Rockwood classification and imaging study modality (weightbearing vs nonweightbearing). Error bars indicate 95% CI.

In total, 116 patients with Rockwood III and 129 patients with Rockwood V AC joint dislocations were analyzed. In patients with Rockwood III injuries, a superior clavicle dislocation, regardless of weighted ($n = 84$) or nonweighted views ($n = 32$), could be found (ΔCla weighted views, 6 ± 14 mm; ΔCla nonweighted views, 4 ± 14 mm; $P = .619$). In these patients, no side-comparative dropping of the shoulder girdle was measured (ΔSG weighted views, 0 ± 11 mm; ΔSG nonweighted views, 0 ± 11 mm; $P = .927$).

In patients with high-grade AC joint dislocations (Rockwood V), differences between weighted ($n = 69$) and nonweighted ($n = 60$) views were observed. A significantly greater superior displacement of the clavicle in weighted versus nonweighted views was measured (ΔCla weighted views, 14 ± 18 mm; ΔCla nonweighted views, 6 ± 14 mm; $P = .009$). In nonweighted views, a greater depression of the shoulder girdle was detected as compared with weighted views (ΔSG nonweighted views, -5 ± 11 mm; ΔSG weighted views, 2 ± 15 mm; $P = .002$) (Figure 3).

Dislocation Direction Depending on CC Distance

Figure 4 shows the side-comparative vertical position of the clavicle (ΔCla) and shoulder girdle (ΔSG) as a function of the relative CC distance (ΔCC , %) in nonweightbearing views. With increasing CC distance, a significant elevation

of the clavicle could be detected ($P = .026$). Additionally, a depression of the shoulder girdle is present from $\Delta\text{CC} > 100\%$, whereby no significant trend toward an increase in shoulder girdle depression can be shown with increasing ΔCC ($P = .239$).

In contrast, the analysis of weightbearing views showed that elevation of the clavicle occurs with increasing ΔCC ($P < .001$), but the side-comparative shoulder girdle position remains unchanged ($P = .219$) (Figure 5).

DISCUSSION

The key findings of the present study are as follows:

- In Rockwood III injuries, the pathological CC distance is caused by an elevation of the clavicle, while the side-comparative shoulder girdle position is equal.
- Rockwood V AC joint separations show different findings: In nonweighted views, a combination of clavicle elevation and depression of the shoulder girdle is responsible for the vertical displacement.

The severity of AC joint dislocations and the treatment decision are primarily determined by the degree of vertical and horizontal instability. In clinical practice, the radiological classification system according to Rockwood¹² is




Figure 4. Analysis of nonweightbearing views: Mean vertical dislocation of the clavicle and shoulder girdle in relation to the relative coracoclavicular distance, Δ CC (coracoclavicular distance of the affected vs nonaffected side). With increasing Δ CC, a side-comparative elevation of the clavicle and depression of the shoulder girdle could be detected.

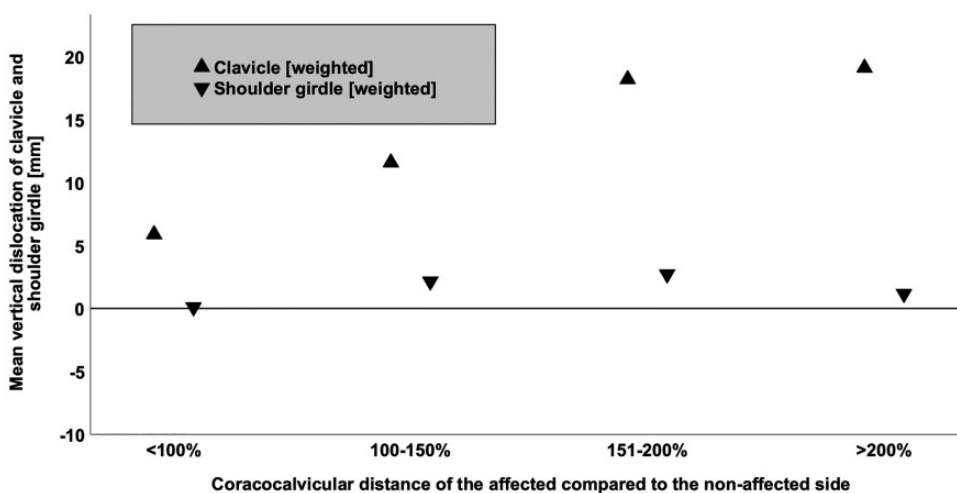


Figure 5. Analysis of weightbearing views: Mean vertical dislocation of the clavicle and shoulder girdle in relation to the relative coracoclavicular distance, Δ CC (coracoclavicular distance of the affected vs nonaffected side). With increasing Δ CC, a side-comparative elevation of the clavicle could be detected. The side-comparative shoulder girdle position remained unchanged.

established, wherein the degree of vertical instability is based on a side-to-side comparison of the CC distance. The pathogenesis of vertical instability is not yet fully understood. The pathognomonic sign of an AC joint dislocation is elevation of the clavicle, while many authors understand this phenomenon as a “pseudo-elevation” with concomitant depression of the injured shoulder girdle owing to a loss of bony fixation of the scapula to the thorax.^{4,6} The present study deals for the first time with the question of what causes vertical dislocation: elevation of the clavicle or depression of the shoulder girdle. Standard imaging studies include conventional assessment of bilateral AC joints. Weighted and nonweighted conventional images are used in clinical practice to assess vertical instability.^{1,2,9}

Patients who received a conventional radiological examination of both AC joints (weightbearing and nonweightbearing views) within high-grade AC joint separations (Rockwood III and V) were included in the present study. When all patients were analyzed, regardless of radiological imaging modality (weightbearing or nonweightbearing), an elevation of the clavicle was measured with increasing vertical dislocation, while no depression of the shoulder girdle could be observed. These results support the clinical observation of an elevated clavicle within AC joint separations. If differences in the radiological modality are taken into account, differences between weightbearing and nonweightbearing conventional radiographs, especially in Rockwood V injuries, become apparent. By analyzing

nonweightbearing views in Rockwood V AC joint dislocations, a combination of clavicle elevation and shoulder girdle depression was observed.

These results are accompanied by the assumption of some authors that vertical dislocation is a “pseudo-elevation” of the clavicle with concomitant shoulder girdle depression of the injured side.^{4,6,11} A possible explanatory model for the elevation of the clavicle can be found analogous to the mechanisms described in a clavicle fracture. It is assumed that muscular traction, especially of the sternocleidomastoid muscle, leads to a displacement of the clavicle upward.¹⁰ Nevertheless, this explanatory model cannot explain the observed dropping of the shoulder girdle. This phenomenon can most likely be explained by a loss of the bony connection between the scapula and the thorax, analogous to the observations made by Martetschläger et al.⁶

While the scapula can still be sufficiently stabilized in Rockwood III injuries, this seems to be no longer possible in Rockwood V injuries with additional rupture of the delto-trapezial fascia, which leads to a depression of the shoulder girdle. However, by analyzing weightbearing views in Rockwood V AC joint dislocations, an elevation of the clavicle without side-comparative dropping of the shoulder girdle seems to be primarily responsible for the vertical dislocation.

Several limitations of the present study have to be discussed. First, this was a radiological study without evaluation of clinical parameters. Nevertheless, clinical data could not help answer the questions of the present study. Additionally, there is a risk of measurement inaccuracy, although all conventional radiographs with incorrect projection or low image quality have been excluded. Furthermore, it would have been desirable to have views of all patients with and without weightbearing, which was not possible because of radiation hygiene considerations. However, the separate evaluation of weighted and nonweighted radiographs makes it possible to evaluate and discuss both radiological modalities.

Despite the limitations listed, this is the first study to clarify the question of what is responsible for vertical dislocation in AC joint separations. While in Rockwood III injuries an elevation of the clavicle could be shown, in Rockwood V injuries the shoulder girdle was also depressed. Further studies must clarify to what extent these results may influence treatment strategies for such injuries—for example, through modified posttreatment protocols for surgically treated AC joint separations—or whether dropping of the shoulder girdle should be used as an additional factor in the severity classification or as prognostic tool of such injuries.

CONCLUSION

In Rockwood III injuries, vertical dislocation is mostly associated with clavicle elevation, while in high-grade AC joint dislocations (Rockwood V), a combination of clavicle elevation and shoulder girdle depression is present. A significantly greater superior displacement of the clavicle in Rockwood V injuries was seen in weighted views, while a depression of the shoulder girdle could be detected in nonweighted views.

REFERENCES

- Gastaud O, Raynier JL, Duparc F, et al. Reliability of radiographic measurements for acromioclavicular joint separations. *Orthop Traumatol Surg Res*. 2015;101(8):S291-S295.
- Ibrahim EF, Forrest NP, Forester A. Bilateral weighted radiographs are required for accurate classification of acromioclavicular separation: an observational study of 59 cases. *Injury*. 2015;46(10):1900-1905.
- Kraus N, Hann C, Gerhardt C, Scheibel M. Dynamic instability of the acromioclavicular joint: a new classification for acute AC joint separation. *Obere Extremität*. 2018;13(4):279-285.
- Kraus N, Scheibel M. Injuries of the acromioclavicular joint in athletes [in German]. *Chirurg*. 2014;85(10):854-863.
- Li X, Ma R, Bedi A, Dines DM, Altchek DW, Dines JS. Management of acromioclavicular joint injuries. *J Bone Joint Surg Am*. 2014;96(1):73-84.
- Martetschläger F, Kraus N, Scheibel M, Streich J, Venjakob A, Maier D. The diagnosis and treatment of acute dislocation of the acromioclavicular joint. *Dtsch Arztebl Int*. 2019;116(6):89-95.
- Melenevsky Y, Yablon CM, Ramappa A, Hochman MG. Clavicle and acromioclavicular joint injuries: a review of imaging, treatment, and complications. *Skeletal Radiol*. 2011;40(7):831-842.
- Nordqvist A, Petersson CJ. Incidence and causes of shoulder girdle injuries in an urban population. *J Shoulder Elbow Surg*. 1995;4(2):107-112.
- Pogorzelski J, Beitzel K, Ranuccio F, et al. The acutely injured acromioclavicular joint—which imaging modalities should be used for accurate diagnosis? A systematic review. *BMC Musculoskelet Disord*. 2017;18(1):515.
- Smekal V, Oberladstaetter J, Struve P, Krappinger D. Shaft fractures of the clavicle: current concepts. *Arch Orthop Trauma Surg*. 2009;129(6):807-815.
- Warth RJ, Martetschläger F, Gaskill TR, Millett PJ. Acromioclavicular joint separations. *Curr Rev Musculoskelet Med*. 2013;6(1):71-78.
- Williams GR, Nguyen VD, Rockwood CA Jr. Classification and radiographic analysis of acromioclavicular dislocations. *Appl Radiol*. 1989;18:29-34.
- Zumstein MA, Schiessl P, Ambuehl B, et al. New quantitative radiographic parameters for vertical and horizontal instability in acromioclavicular joint dislocations. *Knee Surg Sports Traumatol Arthrosc*. 2018;26(1):125-135.