



Since January 2020 Elsevier has created a COVID-19 resource centre with free information in English and Mandarin on the novel coronavirus COVID-19. The COVID-19 resource centre is hosted on Elsevier Connect, the company's public news and information website.

Elsevier hereby grants permission to make all its COVID-19-related research that is available on the COVID-19 resource centre - including this research content - immediately available in PubMed Central and other publicly funded repositories, such as the WHO COVID database with rights for unrestricted research re-use and analyses in any form or by any means with acknowledgement of the original source. These permissions are granted for free by Elsevier for as long as the COVID-19 resource centre remains active.

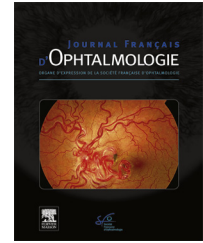


Disponible en ligne sur

**ScienceDirect**  
www.sciencedirect.com

Elsevier Masson France

**EM|consulte**  
www.em-consulte.com



## LETTER TO THE EDITOR

### Acute macular neuroretinopathy and SARS-CoV-2 infection: Case report



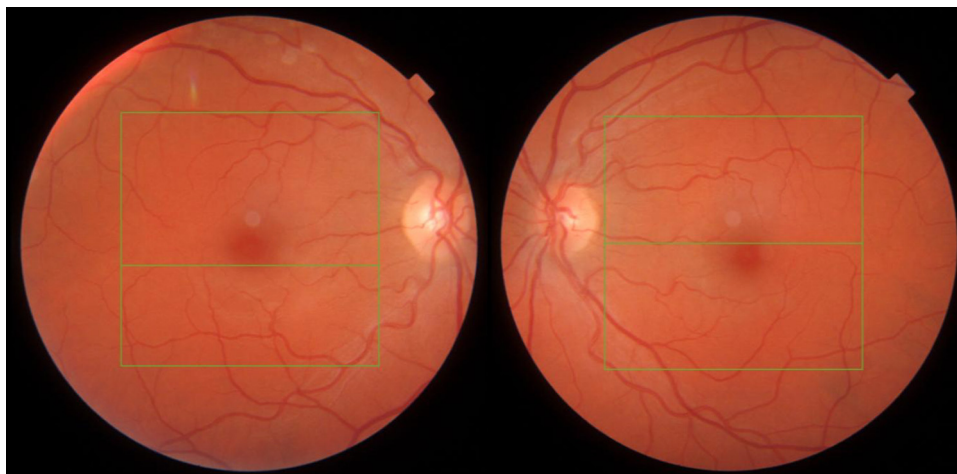Since the COVID-19 pandemic, several ophthalmological damages have been reported in relation with this infection. Acute macular neuroretinopathy (AMN) is a retinal pathology rarely described in the literature and even less in SARS-CoV-2 infection. We report the case of a young woman with AMN while being infected with the english variant of Covid-19. The patient gave us her oral agreement to publish her case.

We describe a 39-years-old woman without medical antecedent, who presented to the ophthalmologic emergency for the onset of photopsia and bilateral para-central scotoma upon awakening. In addition, the patient had also been suffering from a symptomatic form of Covid-19 certified by polymerase chain reaction (PCR), the english variant, for 2 days. The patient had a cough and fever during the consultation. On examination, visual acuity corrected to -0.50 diopters was 10/10 in both eyes. The slit lamp examination was strictly normal, photomotor reflexes were present and symmetrical. The fundus examination was without pathological findings (Fig. 1). Macular optical coherence tomography (OCT) showed bilateral outer plexiform layer hyper-reflectivity in inter papillo-macular (Fig. 2). The visual field 10.2 was normal on the right and was observed an inferior para-central scotoma on the left. Infrared (IR) showed a bilateral greyish perifoveolar petaloids lesions. Fluorescein and indocyanine green angiographies were normal (Fig. 3) as autofluorescence (AF) images. In view of the

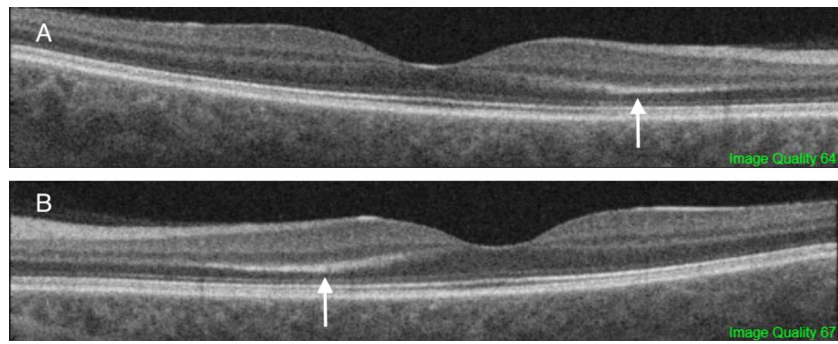
background of the infection with the english variant Covid-19 with a flu-like syndrome, the age of the patient, and multimodal imaging, we concluded to an AMN.

After 1 month, the patient's ophthalmologic symptoms persisted. A hyper-reflectivity of the external plexiform gave way to an iso-reflective thickening of this layer and to a disruption of the interdigitation zone on OCT.

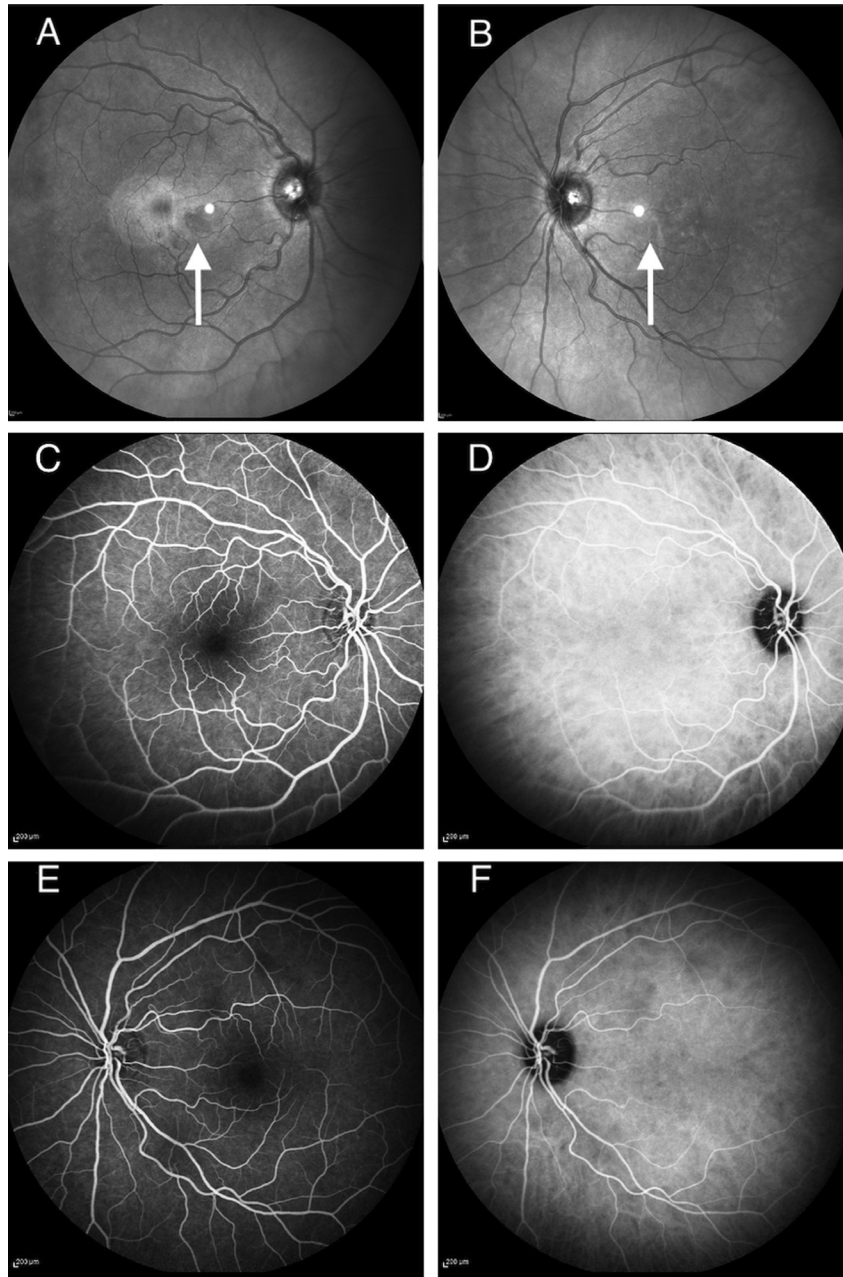
AMN is a rare retinal disease. A few cases are reported in the literature. In Bhavsar KV's literature review, only 101 cases were described between 1975 and 2004 [1]. The physiopathology remains poorly explained but the vascular theory remains the most present in the literature [1,2]. AMN is more often seen in young women with myopia, during or after a flu-like syndrome. Patients describe a para-central scotoma and photopsia. On OCT, hyper-reflectivity of the plexiform and the external nuclear are present. A disruption of the interdigitation zone can also be found. Symptoms and damages to OCT resolve gradually and spontaneously over a few months. Since the SARS-Cov2 pandemic, several ophthalmological damages have been described such as conjunctivitis, cotton wool spots, Roth spots, paracentral acute middle maculopathy [3–7]. Only 2 cases of AMN in the context of Covid-19 infection are reported in the literature [3,4]. We must differentiate AMN and PAMM. The latter appear as placoid, hyperreflective bands at the level of the inner nuclear layer, sparing the outer retina while lesions affect the outer retina in the AMN. The vasculitis caused by this infection could explain the appearance of AMN and so reinforces the vascular pathophysiology of this damage.



**Figure 1.** Non-mydiatic retinography right and left of the patient.



**Figure 2.** Macular optical coherence tomography right (A) and left (B) with outer plexiform layer hyper-reflectivity (white arrows).



**Figure 3.** IR right eye (A) and IR left eye (B) with greyish perifoveolar petaloids lesions (white arrows). Fluorescein (C) and indocyanine green (D) angiographies of the right eye. Fluorescein (E) and indocyanine green (F) angiographies of the left eye.

### Disclosure of interest

The authors declare that they have no competing interest.

### Références

- [1] Bhavsar KV, Lin S, Rahimy E, et al. Acute macular neuroretinopathy: A comprehensive review of the literature. *Surv Ophthalmol* 2016;61:538–65.
- [2] Zamani G, Ataei Azimi S, Aminizadeh A, et al. Acute macular neuroretinopathy in a patient with acute myeloid leukemia and deceased by COVID-19: a case report. *J Ophthalmic Inflamm Infect* 2021;10:39.
- [3] Gascon P, Briantais A, Bertrand E, et al. Covid-19-Associated Retinopathy: A Case Report. *Ocul Immunol Inflamm* 2020;28:1293–7.
- [4] Virgo J, Mohamed M. Paracentral acute middle maculopathy and acute macular neuroretinopathy following SARS-CoV-2 infection. *Eye (Lond)* 2020;34:2352–3.
- [5] Wu P, Duan F, Luo C, et al. Characteristics of Ocular Findings of Patients With Coronavirus Disease 2019 (COVID-19) in Hubei Province, China. *JAMA Ophthalmol* 2020;138:575–8.
- [6] Amesty MA, Alió Del Barrio JL, Alió JL. COVID-19 Disease and Ophthalmology: An Update. *Ophthalmol Ther* 2020;9:1–12.
- [7] Marinho PM, Marcos AAA, Romano AC, Nascimento H, Belfort R. Retinal findings in patients with COVID-19. *Lancet* 2020;395:1610.

T. Macé<sup>a,b,\*</sup>, V. Pipelart<sup>a</sup>

<sup>a</sup> *Department of Ophthalmology, Angers University Hospital, 4, rue Larrey, 49933 Angers cedex, France*

<sup>b</sup> *Department of Ophthalmology, Le Mans Hospital, 194, avenue Rubillard, 72037 Le Mans, France*

\* Corresponding author at: CHU d'Angers, 49933 Angers cedex, France.

Adresse e-mail : [thibault.mace@hotmail.fr](mailto:thibault.mace@hotmail.fr)  
(T. Macé)

Reçu le 8 mai 2021 ;

accepté le 5 juillet 2021

Disponible sur Internet le 9 septembre 2021

<https://doi.org/10.1016/j.jfo.2021.07.004>

0181-5512/© 2021 Elsevier Masson SAS. Tous droits réservés.