



Case report

“Elephant-trunk” negative pressure wound therapy for fixing artificial dermis with basic fibroblast growth factor for critical limb ischemia

Yosuke Niimi^{*}, Kan Nakamoto, Wataru Kamei, Nagisa Osa, Kejiro Hori, Hiroyuki Sakurai

Department of Plastic and Reconstructive Surgery, Tokyo Women's Medical University, 8-1 Kawada-cho, Shinjuku-ku, Tokyo 162-8666, Japan

ARTICLE INFO

Article history:

Received 15 April 2021

Received in revised form

11 July 2021

Accepted 9 August 2021

Keywords:

Negative pressure wound therapy

NPWT

Critical limb ischemia

CLI

Peripheral arterial disease

Collagen-gelatin sponge

ABSTRACT

Introduction: The treatment of intractable toe ulcer with critical limb ischemia (CLI) is a challenge because of its poor blood flow and the wound. Here, a novel fixation technique for artificial dermis with negative pressure wound therapy (NPWT) was reported.

Method: After the amputation of toe, artificial dermis made of collagen-gelatin sponge (CGS) was grafted onto the wound where human recombinant basic fibroblast growth factor (bFGF) was sprayed. The foot was put on adhesive iodine-impregnated drape, the artificial-dermis area was covered with a sponge dressing of which another end reached to the drape, and the vacuum port was applied on the dressing sponge sandwiched with two drapes and connected to an NPWT system. Since the shape of sponge-dressing was similar to that of elephant-trunk, the technique in this study was named an “Elephant-trunk” technique.

Result: During NPWT period, no complications such as air leakage, skin erosion, ischemic around tissue were confirmed. The artificial dermis was engrafted completely at one week after surgery, and the wound was confirmed to close completely.

Conclusion: This NPWT technique with bFGF and CGS accelerated the healing of wound treated conservatively with artificial dermis in CLI patients.

© 2021, The Japanese Society for Regenerative Medicine. Production and hosting by Elsevier B.V. This is an open access article under the CC BY-NC-ND license (<http://creativecommons.org/licenses/by-nc-nd/4.0/>).

1. Introduction

The treatment of intractable toe ulcer with critical limb ischemia (CLI) is a challenge, because the amputation risk is approximately 40% at 1 year, and the mortality rates are over 20% at 6 months [1]. Recent study show that major amputation rate is 16.6% at 90 days, and the mortality rate is 9.9% at 90 days [2]. Total management with medication such as statins, endovascular therapy or surgical revascularization, and wound care are important [2].

Although the effectiveness of negative pressure wound therapy (NPWT) for the diabetic foot ulcer is well known [3], CLI patients treated with NPWT show the highest frequency of complications such as erosion, blister, and skin ulcer surrounding the wound [4].

^{*} Corresponding author. Fax: +81 3 3225 0940.

E-mail addresses: niimi.yosuke@twmu.ac.jp (Y. Niimi), nakamoto.kan@twmu.ac.jp (K. Nakamoto), kamei.wataru@twmu.ac.jp (W. Kamei), osa.nagisa@twmu.ac.jp (N. Osa), hori.kejiro@twmu.ac.jp (K. Hori), sakurai.hiroyuki@twmu.ac.jp (H. Sakurai).

Peer review under responsibility of the Japanese Society for Regenerative Medicine.

This report showed a novel NPWT technique for fixing artificial dermis with basic fibroblast growth factor (bFGF) for two critical limb ischemia patients.

2. Material and methods

2.1. Novel fixation technique for artificial dermis with an “Elephant-trunk” technique

The distal part of metatarsal bone of the toe was amputated, and artificial dermis made of collagen-gelatin sponge (PELNAC G plus) (Gunze, Kyoto, Japan) was grafted onto the wound where human recombinant bFGF (Fiblast® spray, Kaken Pharmaceutical, Tokyo) was sprayed (Fig. 1). The foot was put on adhesive iodine-impregnated drape (Ioban) (3M, St. Paul, MN, USA), the artificial-dermis area was covered with a sponge dressing of which other end reached to the iodine drape. Thereafter, another iodine drape was applied to the dorsal side. Finally, the vacuum port was applied on the dressing sponge sandwiched with two iodine drapes and connected to an NPWT system. The pressure of NPWT was set

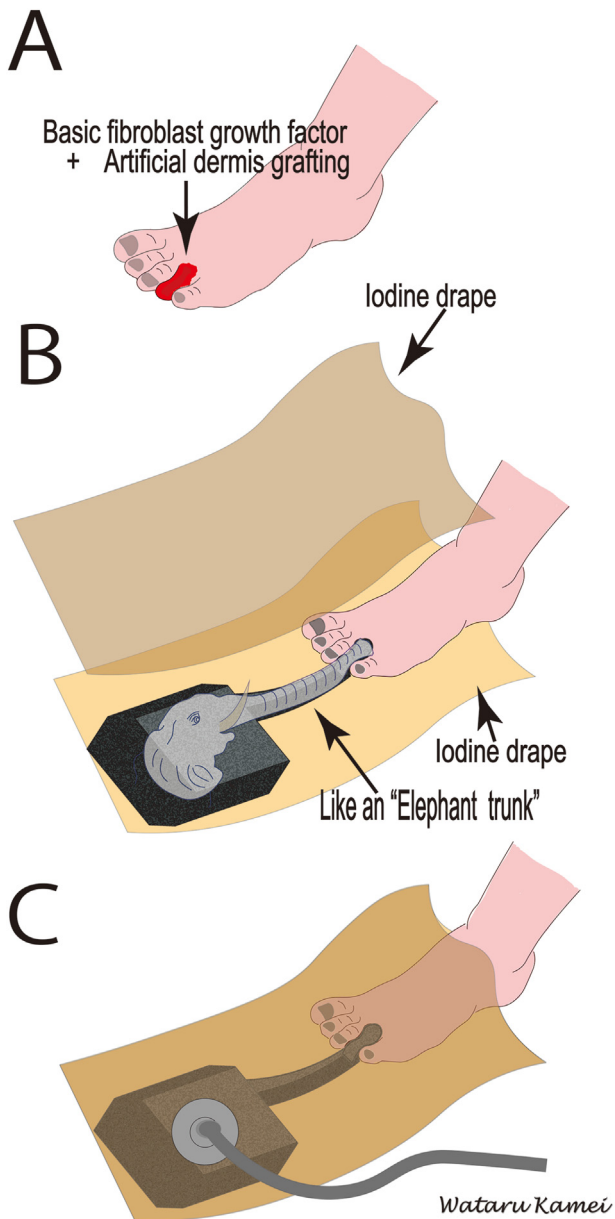


Fig. 1. Schematic illustration of applying negative pressure wound therapy (NPWT) by an "Elephant trunk" technique to the fourth toe of critical limb ischemia patient. A. The distal part of metatarsal bone of fourth toe was amputated, and artificial dermis was grafted with human recombinant basic fibroblast growth factor. B. The foot was put on adhesive iodine-impregnated drape (Ioban) (3M, St. Paul, MN), and the artificial-dermis area was covered with a sponge dressing of which another end reached to the iodine drape. Thereafter, another iodine drape was applied to the dorsal side to sandwich the sponges. The sponge looks like "Elephant trunk". C. The vacuum port was applied on the dressing sponge sandwiched with two iodine drapes and connected to an NPWT system.

at -80 mmHg. Since the shape of sponge-dressing was similar to that of elephant-trunk, the technique in this study was named an "Elephant-trunk" technique.

3. Results

Case 1. A 58-year-old male patient with CLI, diabetes, and cardiac disease found that his left fourth toe underwent necrosis (Fig. 2). His angiography showed severe stenosis of anterior tibial artery,

and his ankle brachial pressure index was 0.77. Then, he received an endovascular therapy with a balloon catheter 1 month before surgery. Since infection or wound dehiscence due to the primary closure was considered, the wound site was sprayed with bFGF and grafted with artificial dermis, which was fixed with NPWT (Kinetic Concepts, San Antonio, TX) by the "Elephant-trunk" technique. No air leakage was confirmed after applying vacuum (Fig. 2). During NPWT period, the patient was able to walk with NPWT. The artificial dermis was engrafted completely at one week after surgery without complications, and NPWT dressing was exchanged twice a week. After a 2-week-NPWT, the wound was treated conservatively with Vaseline ointment. At three months after surgery, the wound closed completely. Morphology at 4 months was favorable (Fig. 3).

Case 2. A 57-year-old male patient with CLI, diabetes, cardiac disease, kidney transplantation, and cerebral infarction found that his right first toe underwent necrosis. He received stump-plasty of the first toe 1 month later, and he received an endovascular therapy with a balloon catheter and stent implantation, and the dehiscence and surgical site infection were found (Fig. 4B). The distal part of metatarsal bone of the first toe was amputated, and artificial dermis was grafted onto the wound site where bFGF was sprayed (Fig. 4C) and fixed with NPWT system (RENASYS, Smith & Nephew, Memphis, TN) by the elephant-trunk technique as described in Case 1. The pressure of NPWT was set at -80 mmHg. No air leakage was confirmed after applying vacuum (Fig. 4D). During NPWT period, the patient was able to walk with NPWT. The artificial dermis was engrafted completely at one week after surgery without complications, and NPWT dressing was exchanged twice a week. After a 2-week-NPWT, the wound was treated conservatively with Vaseline ointment. At three months after surgery, the wound closed completely. Morphology at 7 months was favorable (Fig. 5).

4. Discussion

This report showed a novel fixation technique with NPWT for treating toes and suggested that NPWT was effective for fixing artificial dermis even for CLI patients.

Recently, in the field of clinical research for treating CLI and intractable foot-ulcer due to diabetes mellitus (DM), there are many reports describing the applications of regenerative medicine employing stem cells [5–7], scaffold [8], nanoparticle [9], and proangiogenic growth factor including vascular endothelial growth factor (VEGF), fibroblast growth factor (FGF), hepatocyte growth factor (HGF), and insulin-like growth factor (IGF-1) [10]. Although conventional therapeutic strategies for CLI treatment attempt to increase the processes of neoangiogenesis, neovascularization at the ischemic tissues is known to be difficult. For solving the issue, this study bFGF onto the wound site where artificial dermis would be grafted. bFGF is known (1) to increase the number of vessels around ulcer [11] and (2) to mature grafted artificial dermis through the adequate granulation via promoting proliferation of fibroblast [12].

In the proliferative phase of the cutaneous wound healing, dermal fibroblasts proliferate and migrate into the wound for producing new extracellular matrix (ECM) [13]. Enhancing the proliferation and migration of these cells [14], NPWT is known to increase the number of blood vessels. Erba et al. report NPWT increase the number of blood vessels by stabilizing VEGF dimers, oxygenate hypoxia wound bed through the sponge form interface, and directly provide suitable scaffolds allowing fibroblasts to proliferate [15]. Consequently, the synergy effect of NPWT and pre-sprayed bFGF, which can promote the production of ECM, was speculated to allow the wound to close adequately. As other beneficial effects, NPWT (1) removes exudate and bacteria from the

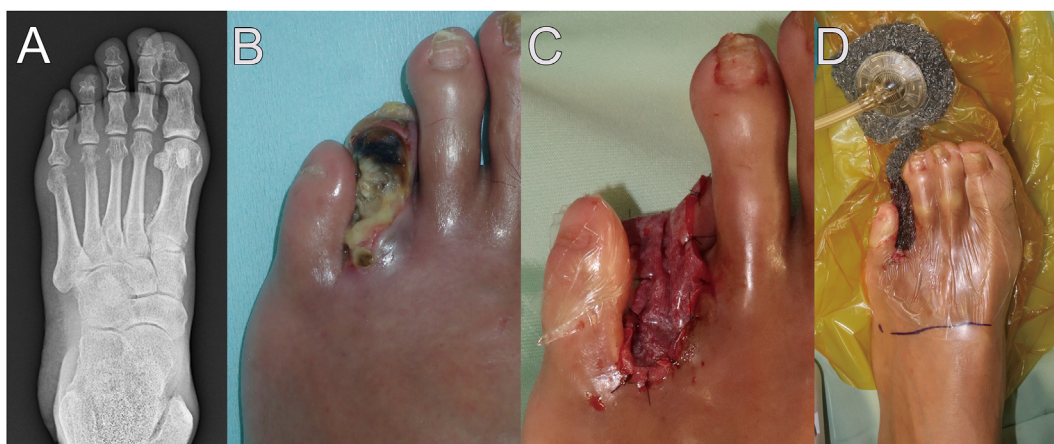

Fig. 2. Preoperative X-ray image and intraoperative findings during the treatment of the left necrotic fourth toe of a 58-year-old male with critical limb ischemia. A. X-ray image of the left foot revealed the destruction of distal phalanx of the fourth toe. B. The left fourth toe found to be necrosis. C. After the distal part of metatarsal bone of fourth toe was amputated under local anesthesia, human recombinant basic fibroblast growth factor was sprayed, and artificial dermis was grafted onto the wound site with 5-0 nylon. D. The artificial dermis was fixed using NPWT with “Elephant-trunk” technique.

wound site, (2) improves an oxygen environment in the tissue [16], (3) equalizes body-fluid pressure between the irregular-shape wound and highly mobile areas [17], and (4) immobilizes the grafted site without splint [17]. This study suggested NPWT was an effective dressing for fixing artificial dermis found in the poor blood flow such as critical limb ischemia. During NPWT treatment in this study, the pressure was set at -80 mmHg, which is reported to be used for fixing full thickness skin graft without complications such as hematoma, seroma, and pressure pore [18].

Although NPWT is used for various tissue fixations such as the free arterialized venous flap [19], full thickness skin graft [18], as well as split thickness skin graft [20], Fagerdahl et al. report more than 3% NPWT-patients have skin complications around the wound [4]. “Elephant-trunk” technique in this study gave (1) no skin complications because of no direct contact between the normal skin and the sponge form, (2) no air-leakage because of the sponge form sandwiched between two film drapes as described in the authors' previous report [18], and (3) the reduction of surgical time by performing simply and safety maneuver.

As the beneficial effects, artificial dermis provided (1) scaffolds for promoting the granulation of tissue, (2) protection for the wound area from mechanical forces, and (3) the sustainable releasing effect of impregnated bioactive agent. Collagen-gelatin sponge (CGS) in artificial dermis used in this study contains a lot of gelatin microspheres (MSs), which held impregnated bFGF, and during the degradation process of the dermis with MSs, the contained bFGF gradually detached from MSs, resulting in the sustainable releasing of bFGF [21]. Morimoto reports that artificial dermis having a drug delivery system for bFGF is used for treating chronic ulcer [22]. Matsumine et al. also report the efficacy of artificial-dermis CGS containing bFGF for the full thickness skin ulcer [23]. In this study, being fixed by NPWT, artificial dermis was able to release bFGF sustainably for one week.

As a limitation, this study showed only two cases, and the authors will accumulate cases and evaluate the wound closure rate between ointment treatment and this method. In addition, these

two cases contained no nonrevascularizable patients who are known as no-option CLI patients, and for treating no-option CLI patients, the application of “Elephant-trunk” technique will require more attention, because the patient's blood stream is known to be quite poor, and the wound site could be intolerable against infection and necrosis.

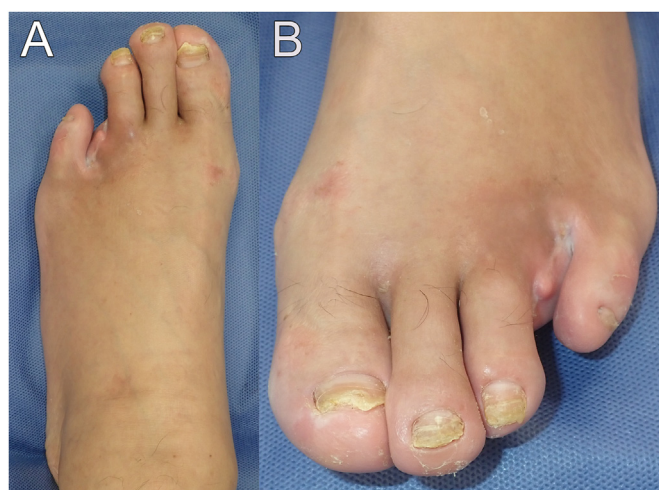

Fig. 3. Post operative findings of the 58-years old male. Photograph (A) and (B) show the front and expanded views of the fourth toe removed area treated by “Elephant-trunk” technique, respectively. At 4 months after artificial dermis grafting, no recurrence of ulcer was observed. The morphology of the fourth toe removed area was favorable.

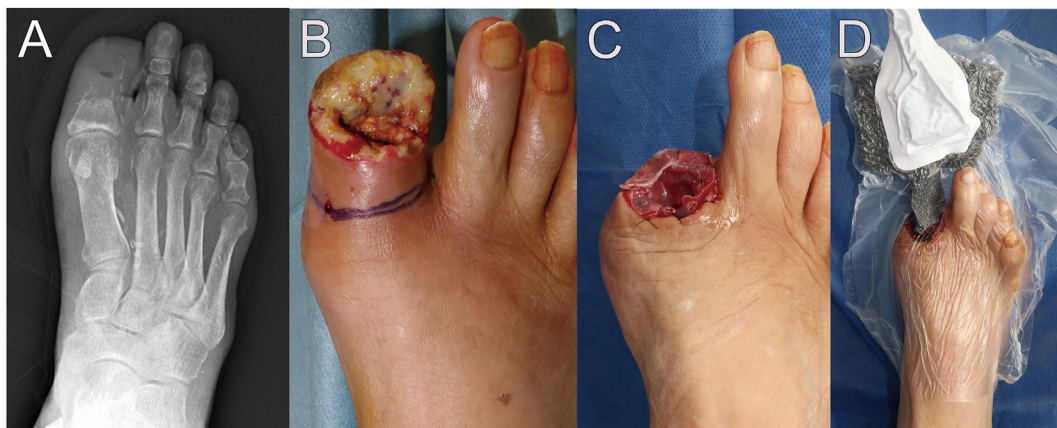


Fig. 4. Preoperative X-ray image and intraoperative findings during the treatment of a 57-year-old male with critical limb ischemia. A. X-ray image of the right foot revealed the destruction of proximal phalanx of the first toe and severe arterial calcification. B. The first toe was infected and surgical wound dehiscence after the amputation surgery. C. The distal part of metatarsal bone of first toe was amputated under local anesthesia, human recombinant basic fibroblast growth factor was sprayed, and artificial dermis was grafted onto the wound site with 5-0 nylon. D. The artificial dermis was fixed by NPWT with “Elephant-trunk” technique.

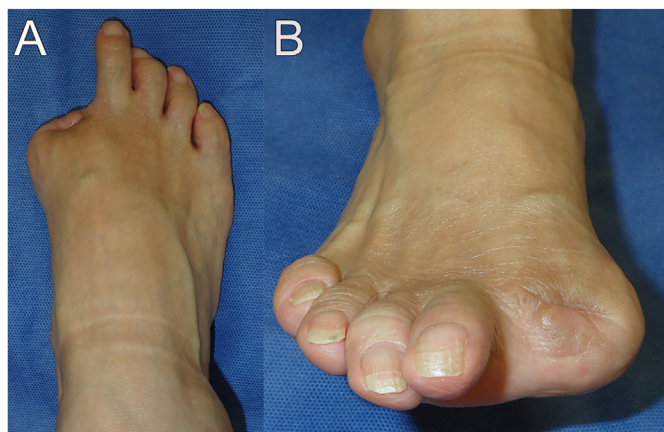

Fig. 5. Post operative findings of the 58-years old male. Photograph (A) and (B) show the front and expanded views of the fourth toe removed area treated by “Elephant-trunk” technique, respectively. The morphology of the 7 months after artificial dermis grafting, no recurrence of ulcer was observed. Morphology of the first toe removed area was favorable.

Ethical statement

This study was carried out in accordance with the World Medical Association Declaration of Helsinki (June 1964) and subsequent amendments. The patients voluntarily gave written informed consent to participate in this study.

Financial disclosure statement

None of the authors has a financial interest in any of the products, devices, or drugs mentioned in this manuscript.

Declaration of competing interest

The authors declare that they have no known competing financial interests or personal relationships that could have appeared to influence the work reported in this paper.

References

- [1] Varu VN, Hogg ME, Kibbe MR. Critical limb ischemia. *J Vasc Surg* 2010;51(1):230–41.
- [2] Mentias A, Qazi A, McCoy K, Wallace R, Vaughan-Sarrazin M, Girotra S. Trends in hospitalization, management, and clinical outcomes among veterans with critical limb ischemia. *Circ Cardiovasc Interv* 2020;13(2):e008597.
- [3] Armstrong DG, Lavery LA, Consortium DFS. Negative pressure wound therapy after partial diabetic foot amputation: a multicentre, randomised controlled trial. *Lancet* 2005;366(9498):1704–10.
- [4] Fagerdahl AM. Risk factors for unsuccessful treatment and complications with negative pressure wound therapy. *Wounds* 2012;24(6):168.
- [5] Bura A, Planat-Benard V, Bourin P, Silvestre JS, Gross F, Grolleau JL, et al. Phase I trial: the use of autologous cultured adipose-derived stroma/stem cells to treat patients with non-revascularizable critical limb ischemia. *Cytotherapy* 2014;16(2):245–57.
- [6] Katagiri T, Kondo K, Shibata R, Hayashida R, Shintani S, Yamaguchi S, et al. Therapeutic angiogenesis using autologous adipose-derived regenerative cells in patients with critical limb ischaemia in Japan: a clinical pilot study. *Sci Rep* 2020;10(1):16045.
- [7] Nammian P, Asadi-Yousefabad SL, Daneshi S, Sheikhha MH, Tabei SMB, Razban V. Comparative analysis of mouse bone marrow and adipose tissue mesenchymal stem cells for critical limb ischemia cell therapy. *Stem Cell Res Ther* 2021;12(1):58.
- [8] DeQuach JA, Lin JE, Cam C, Hu D, Salvatore MA, Sheikh F, et al. Injectable skeletal muscle matrix hydrogel promotes neovascularization and muscle cell infiltration in a hindlimb ischemia model. *Eur Cell Mater* 2012;23:400–12. discussion 12.
- [9] Park IS, Mahapatra C, Park JS, Dashnyam K, Kim JW, Ahn JC, et al. Revascularization and limb salvage following critical limb ischemia by nanoceria-induced Ref-1/APE1-dependent angiogenesis. *Biomaterials* 2020;242:119919.
- [10] Hassanshahi M, Khabbazi S, Peymanfar Y, Hassanshahi A, Hosseini-Khah Z, Su YW, et al. Critical limb ischemia: current and novel therapeutic strategies. *J Cell Physiol* 2019;234(9):14445–59.
- [11] Tanaka E, Ase K, Okuda T, Okumura M, Nogimori K. Mechanism of acceleration of wound healing by basic fibroblast growth factor in genetically diabetic mice. *Biol Pharm Bull* 1996;19(9):1141–8.
- [12] Ono I. The effects of basic fibroblast growth factor (bFGF) on the breaking strength of acute incisional wounds. *J Dermatol Sci* 2002;29(2):104–13.
- [13] Singer AJ, Clark RA. Cutaneous wound healing. *N Engl J Med* 1999;341(10):738–46.
- [14] Lalezari S, Lee CJ, Borovikova AA, Banyard DA, Paydar KZ, Wirth GA, et al. Deconstructing negative pressure wound therapy. *Int Wound J* 2017;14(4):649–57.
- [15] Erba P, Ogawa R, Ackermann M, Adini A, Miele LF, Dastouri P, et al. Angiogenesis in wounds treated by microdeformational wound therapy. *Ann Surg* 2011;253(2):402–9.
- [16] Moisisidis E, Heath T, Boorer C, Ho K, Deva AK. A prospective, blinded, randomized, controlled clinical trial of topical negative pressure use in skin grafting. *Plast Reconstr Surg* 2004;114(4):917–22.
- [17] Hoeller M, Schintler MV, Pfurtscheller K, Kamolz LP, Tripolt N, Trop M. A retrospective analysis of securing autologous split-thickness skin grafts with

- negative pressure wound therapy in paediatric burn patients. *Burns* 2014;40(6):1116–20.
- [18] Niimi Y, Ito H, Sakurai H. Negative-pressure wound therapy for fixing full-thickness skin graft on the thumb. *JPRAS Open* 2018;18:22–7.
- [19] Niimi Y, Mori S, Takeuchi M. A new procedure for wrapped-negative pressure wound therapy for congestion after arterialized venous flap surgery. *Clin Med Insights Case Rep* 2017;10. 1179547617747279.
- [20] Kamolz LP, Lumenta DB. Topical negative pressure therapy for skin graft fixation in hand and feet defects: a method for quick and easy dressing application—the “sterile glove technique”. *Burns* 2013;39(4):814–5.
- [21] Takemoto S, Morimoto N, Kimura Y, Taira T, Kitagawa T, Tomihata K, et al. Preparation of collagen/gelatin sponge scaffold for sustained release of bFGF. *Tissue Eng Part A* 2008;14(10):1629–38.
- [22] Morimoto N, Yoshimura K, Niimi M, Ito T, Aya R, Fujitaka J, et al. Novel collagen/gelatin scaffold with sustained release of basic fibroblast growth factor: clinical trial for chronic skin ulcers. *Tissue Eng Part A* 2013;19(17–18):1931–40.
- [23] Matsumine H, Fujimaki H, Takagi M, Mori S, Iwata T, Shimizu M, et al. Full-thickness skin reconstruction with basic fibroblast growth factor-impregnated collagen-gelatin sponge. *Regen Ther* 2019;11:81–7.