

Access this article online
Quick Response Code:

Website: www.e-tjo.org
DOI: 10.4103/tjo.tjo_51_18

Photorefractive keratectomy for correcting residual refractive error following cataract surgery with premium intraocular lens implantation

Yuan-Yao Fan¹, Chi-Chin Sun^{2,3}, Hung-Chi Chen^{1,4,5,6}, David Hui-Kang Ma^{1,3,5,6,7}

Abstract:

PURPOSE: The aim of this study is to evaluate the effectiveness and predictability of photorefractive keratectomy (PRK) for correcting residual refractive error following cataract surgery with premium intraocular lens (IOL) implantation.

METHODS: We conducted a retrospective review of the medical records of patients who received PRK for correcting residual hyperopia, myopia, and/or astigmatism due to unsatisfied uncorrected distance visual acuity (UDVA) after cataract extraction with implantation of aspheric, diffractive multifocal, or toric IOL from September 2011 to December 2017. Pre-cataract surgery, pre- and post-PRK data including UDVA, best-corrected distance visual acuity, and refractive status were analyzed.

RESULTS: A total of 18 consecutive eyes in 17 patients were included in this study. The UDVA after PRK improved 1 line or more in 10 eyes, remained unchanged in five eyes, and decreased in three eyes. The overall improvement in the logarithm of minimal angle of resolution (logMAR) UDVA after PRK was significant ($P < 0.05$). While dividing patients into subgroups based on IOL type, significant improvement in logMAR UDVA was found in patients with aspheric IOL or diffractive multifocal IOL implantation ($P < 0.05$). No significant improvement of UDVA was found in patients with toric IOL implantation. All eyes achieved ± 1.00 D of the attempted spherical correction, demonstrating good predictability of PRK.

CONCLUSIONS: PRK was a safe and effective procedure to correct residual refractive error following cataract extraction with premium IOL implantation. Although satisfactory for all patients, the outcome is better and more predictable in patients with aspheric and diffractive multifocal IOL implantation and is less satisfactory and unpredictable in patients with toric IOL implantation.

Keywords:

Cataract surgery, intraocular lens, photorefractive keratectomy, refractive error

Introduction

Phacoemulsification and intraocular lens (IOL) implantation are one of the most common ophthalmic operations in Taiwan.^[1,2] Nowadays, premium IOL, including aspheric IOL, diffractive multifocal IOL, and toric IOL, are in growing demand compared to standard spherical IOL. Satisfying uncorrected distance

visual acuity (UDVA) with spectacle independence also becomes most patients' expectation following cataract surgery with premium IOL implantation. However, despite improvement in surgical technique and the introduction of new-generation of IOL power calculation formulas in recent years,^[3-5] residual refractive error after the cataract surgery, together with unsatisfied UDVA as well as disappointments of the patients, is still much a live issue. Under the circumstances, additional treatment to

This is an open access journal, and articles are distributed under the terms of the Creative Commons Attribution-NonCommercial-ShareAlike 4.0 License, which allows others to remix, tweak, and build upon the work non-commercially, as long as appropriate credit is given and the new creations are licensed under the identical terms.

For reprints contact: reprints@medknow.com

How to cite this article: Fan YY, Sun CC, Chen HC, Ma DH. Photorefractive keratectomy for correcting residual refractive error following cataract surgery with premium intraocular lens implantation. Taiwan J Ophthalmol 2018;8:149-58.

¹Department of Ophthalmology, Chang Gung Memorial Hospital, ⁵Department of Ophthalmology, Limbal Stem Cell Laboratory, Chang Gung Memorial Hospital, ⁶Center for Tissue Engineering, Chang Gung Memorial Hospital, Linkou, ²Department of Ophthalmology, Chang Gung Memorial Hospital, Keelung, Departments of ³Chinese Medicine and ⁴Medicine, College of Medicine, Chang Gung University, Taoyuan, Taiwan, ⁷Department of Ophthalmology, Xiamen Chang Gung Hospital, Xiamen, China

Address for correspondence:

Prof. David Hui-Kang Ma,
No. 5, Fuxing Street, Gueishan, Taoyuan 333, Taiwan.
E-mail: davidhkma@yahoo.com

Submission: 27-04-2018
Accepted: 30-06-2018

correct refractive errors for those patients is of clinical importance to achieve good UDVA, and to maximize patients' satisfaction, particularly when the patients choose to pay extra money for the IOLs.

For the correction of the pseudophakic refractive error, currently, several modalities are available, including laser keratorefractive procedures such as laser *in situ* keratomileusis (LASIK) and photorefractive keratectomy (PRK), and intraocular surgical procedures such as piggyback IOLs and IOL exchange.^[6,7] Laser vision correction with LASIK or PRK has been shown to be more precise and predictable for correction of small spherical and cylindrical error, whereas piggyback IOLs and IOL exchange were more effective in correcting large spherical errors.^[6-9] Several previous studies validated the safety and predictability using laser refractive surgeries for correction of residual refractive error after cataract surgery [Table 1],^[3,8-15] refractive lens exchange,^[16-19] and phakic IOL implantation.^[20] However, in most of the studies, the IOL types were not mentioned, and the residual refractive errors after cataract surgery were relatively large. To the best of our knowledge, no report has directly compared the outcome of laser refractive surgeries for residual refractive errors in pseudophakic patients with implantation of different premium IOLs. Therefore, the purpose of this study is to assess visual and refractive outcomes in patients who had small residual refractive error following cataract surgery with premium IOL implantation, which were subsequently corrected with PRK.

Materials and Methods

This retrospective, noncomparative study included 18 consecutive eyes in 17 patients who received PRK for correction of residual hyperopia, myopia, and/or astigmatism with unsatisfied UDVA after uneventful cataract surgery with aspheric IOL, diffractive multifocal IOL or toric IOL use in Chang Chung Memorial Hospital Linkou Medical Center from September 2011 to December 2017. The surgical technique for cataract surgery in all patients consisted of standard phacoemulsification and IOL implantation into the capsular bag through a 2.65-mm corneal incision at the temporal side or at the steep axis of keratometric astigmatism. All the cataract surgeries were performed by a single surgeon (DHKM).

The indication for PRK enhancement was patients' subjective dissatisfaction with UDVA caused by a residual refractive error, which remained stable for at least 3 months after the cataract surgery. This dissatisfaction mostly occurred when the difference between the UDVA and best-corrected distance visual

acuity (BCDVA) was >2 lines, or when the fellow eye had experienced satisfactory results after PRK previously.

Before PRK, all the patients had undergone a complete ophthalmologic evaluation, including medical and ocular history, UDVA, BCDVA, keratometry, axial length, Pentacam corneal topography (OCULUS GmbH, Wetzlar, Germany), corneal pachymetry, slit lamp examination, and fundus examination with indirect ophthalmoscopy. All patients were given a thorough explanation of the efficacy of and possible complications from PRK, and informed consent was obtained from all patients. This study was performed with the approval of the Chang Gung Medical Foundation Institutional Review Board (contracts IRB No. 201800230B0), and was in accordance with the Declaration of Helsinki, which guides studies involving human subjects.

Surgical technique

PRK was performed 3–27 months after the cataract surgery. The preoperative manifest refraction was selected as the target for correction. After topical anesthesia, the corneal epithelium was removed by mechanical scraping with a blade, and the cornea was cleaned thoroughly with a cellulose sponge. Laser ablation was performed using a VISX STAR S4 IR Excimer Laser System (Abbott Medical Optics Inc., Abbott Park, IL, USA). The optical zone ranged from 6.0 mm to 6.5 mm with or without a blended area extending to 8.0 mm. All the surgeries were done by a single surgeon (DHKM) and were uneventful.

After the surgery, a therapeutic soft contact lens was placed. Depending on the speed of re-epithelialization, the contact lens was removed from postoperative 3–7 days. Postoperatively, the patients were instructed to apply Tobradex solution (Alcon Laboratories Inc., Fort Worth, TX, USA) q3h, 0.5% Levofloxacin ophthalmic solution (Cravit; Santen Pharmaceutical, Osaka, Japan) qid, and Balanced Salt Solution (BSS Sterile Irrigating Solution; Alcon Laboratories Inc.) q1h for lubrication. Three weeks later, the medications were changed to 0.25% chloramphenicol ophthalmic solution (Kingdom Pharmaceutical, Taoyuan, Taiwan) qid and 0.1% fluorometholone (FML) (Viscone; Sinphar pharmaceutical, Ilan, Taiwan) ophthalmic suspension qid, and were further tapered to 0.02% FML (Foxone; Winston Medical Supply, Tainan, Taiwan) qid 3 months later.

Outcome measures and statistical analysis

Pre-cataract surgery, pre-PRK and post-PRK data including UDVA, BCDVA, IOL types, manifest refraction, targeted correction, and achieved correction were recorded

Table 1: Previous studies regarding laser *in situ* keratomileusis and/or photorefractive keratectomy for correction of residual refractive error after phacoemulsification and intraocular lens implantation for cataract patients

Journal	Author	Surgery	Number of eye	IOL	pre-operative spherical equivalent	postoperative spherical equivalent	UDVA >20/40 (%)	UDVA change (P)
J Cataract Refract Surg 1999	Artola <i>et al.</i> ^[3]	PRK	30	N/A	-5.00±2.50 D	-0.25±0.50 D	53.3	<0.001
J Cataract Refract Surg 2000	Patterson <i>et al.</i> ^[10]	PRK	20	N/A	-4.21±2.86 D (range-1.00 to-9.75 D)	-0.56±2.11 D (range+3.00 to-4.25 D)	52	<0.001
J Refract Surg 2001	Ayala <i>et al.</i> ^[11]	LASIK	22	N/A	-2.90±1.80 D (range-0.80 to-8.50 D)	+0.40±0.60 D (range-0.60 to+1.50 D)	45.4	<0.01
J Cataract Refract Surg 2005	Kim <i>et al.</i> ^[12]	LASIK	12	N/A	Myopic group-3.08±0.84 D (range-4.75 to-2.00 D)	-0.54±0.59 D (range-1.5 to-0.5 D)	91.7	0.001
			11	N/A	Hyperopic group+1.82±1.03 D (range+0.75 to+3.00 D)	+0.09±0.36 D (range-0.25 to+0.75 D)	90.9	0.008
J Cataract Refract Surg 2005	Kuo <i>et al.</i> ^[13]	PRK	5	One silicone IOL, others PMMA IOLs	-3.73±2.33 D (range-7.50 to-1.88 D)	-0.45±1.70 D (range-2.63 to+2.13 D)	60.0	N/A
		LASIK	6	PMMA IOLs	-2.92±3.03 D (range-6.50 to+0.75 D)	-1.23±1.20 D (range-2.75 to 0.00 D)	66.7	N/A
J Cataract Refract Surg 2008	Jin <i>et al.</i> ^[8]	LASIK	28	N/A	-0.91±1.43 D	+0.09±0.37 D	96.0	<0.001
J Cataract Refract Surg 2009	Muftuoglu <i>et al.</i> ^[14]	LASIK	85	AcrySof® IQ ReSTOR®	-0.34±0.90 D (range-2.58 to+1.63D)	-0.07±0.29 D (range-1.18 to+0.63 D)	100.0	<0.001
J Refract Surg 2011	Kamiya <i>et al.</i> ^[15]	PRK	88	KS-1TM	-3.16±1.71 D (range 0.00 to-7.75 D)	-1.15±1.10 D	94.0	N/A
J Refract Surg 2013	Fernández-Buenaga <i>et al.</i> ^[9]	LASIK	28	Monofocal IOLs	Median-0.37 D (range-1.00 to+1.47 D)	Median 0.00 D (range-0.09 to+0.46 D)	N/A	N/A
Current study		PRK	7	Aspheric IOLs	-0.46±1.06 D (range-2.00 to+1.00 D)	-0.23±0.36 D (range-1.00 to 0.00)	85.7	0.037
		PRK	6	Diffraction multifocal IOLs	-0.29±1.24 D (range-2.00 to+1.25 D)	-0.02±0.46 D (range-0.75 to+0.50 D)	66.7	0.025
		PRK	5	Toric IOLs	+0.10±0.81 D (range-0.75 to+1.13 D)	-0.45±0.62 D (range-1.38 to+0.13 D)	40	0.174

IOL=Intraocular lens, LASIK = Laser in situ keratomileusis, N/A = Not available, PMMA = Polymethyl methacrylate, PRK = Photorefractive keratectomy, UDVA = Uncorrected distance visual acuity, D = Diopter

and evaluated. The UDVA and BCDVA measurements on Snellen charts were converted to logarithm of minimal angle of resolution (logMAR) values. Pre-PRK keratometry and axial length measurements were also collected for analysis. All data were incorporated in a spreadsheet using Microsoft Excel (Microsoft Corp., Seattle, WA, USA) version 2016 for Windows. Statistical analyses were performed using SPSS (Statistical Package for the Social Science; SPSS Inc., Chicago, IL, USA) version 17.0 for Windows. Categorical variables were presented with number and percentage, where as continuous variables were described as mean ± standard deviation with ranges or frequencies when appropriate. The paired Student *t*-test was performed to compare pre- and post-PRK outcome. The one-way analysis of

variance (ANOVA) test and Scheffe's *post hoc* test was performed to compare continuous variables between subgroups. Categorical variables were compared using Chi-square test. Differences were considered statistically significant when *P* < 0.05.

Results

In this study, 18 consecutive eyes of 17 patients were included. The mean time between cataract surgery and PRK was 10.5 ± 5.9 months (range 3–27 months). The mean age of the patients at the time of PRK was 67.0 years (range 45.4–78.3 years), and 14 patients (82.4%) were older than 60 years. The male-to-female ratio was 6:11. Among the 18 eyes, six presented with concomitant age-related

macular degeneration (AMD), and two with mild nonproliferative diabetic retinopathy (NPDR). No concomitant eye diseases were present in the other eyes.

The pre- and post-PRK refractive status are summarized in Table 2. Six months after PRK, 14 eyes (77.8%) showed a final spherical equivalent (SE) within ± 0.50 D, and 17 eyes (94.4%) within ± 1.00 D. Before PRK, the post-cataract eyes had the UDVA ranging 0.2–0.7, and the mean logMAR UDVA was 0.45 ± 0.18 (range 0.15–0.70) [Figure 1]. It improved significantly to 0.27 ± 0.26 (range 0.00–0.70) after PRK ($P < 0.05$) [Table 2]. The UDVA improved 1 line or more in 10 eyes (55.6%), remained unchanged in five eyes (27.8%), and decreased in three eyes (16.7%) [Figure 2]. There was no significant change in logMAR BCDVA after PRK. The corneal haze after PRK had diminished in all eyes by 6 months. Although topical steroid was given after PRK, no rise of intraocular pressure was noted in any of the eyes. One eye, which

had PRK at 27 months after cataract surgery with UDVA of 1.0 after PRK, developed after-cataract with decreased vision at 5 months after PRK (32 months after cataract surgery). Neodymium: yttrium aluminum garnet (Nd:YAG) laser capsulotomy was then applied for after-cataract at 11 months after PRK, which restored the vision to UDVA of 1.0. No other serious complications occurred to any of the eyes during or after PRK until the last follow-up.

While dividing the patients into the myopic group and hyperopic group according to pre-PRK SE, the change of spherical refraction and SE after PRK was significant in both groups [Table 2]. However, the cylindrical refraction change was significant in the myopic group but not in the hyperopic group [Table 2]. Furthermore, the change of UDVA was significant in myopic group but did not reach a statistical significance in the hyperopic group [Table 2].

Table 2: The age, sex, pre- and post-photorefractive keratectomy refractive status, uncorrected distance visual acuity and best-corrected distance visual acuity in (A) all patients, (B) myopic eyes, and (C) hyperopic eyes

A. All patients			
Mean \pm SD (range)			
	Pre-PRK	Post-PRK	P
Age (year)	67.0 \pm 8.5 (45.4-78.3)		
Sex (male: female)	6:1		
Spherical refraction (D)	+0.21 \pm 1.07 (-1.75+1.75)	+0.04 \pm 0.33 (-0.75+0.75)	
Cylindrical refraction (D)	-0.92 \pm 0.55 (-2.25-0.00)	-0.53 \pm 0.70 (-2.75-0.00)	
Spherical equivalent (D)	-0.25 \pm 1.03 (-2.00+1.25)	-0.22 \pm 0.48 (-1.38+0.50)	
Axial length (mm)	23.78 \pm 1.39 (22.31-28.29)		
UDVA (logMAR)	0.47 \pm 0.21 (0.15-1.00)	0.24 \pm 0.24 (0.00-0.70)	0.009
BCDVA (logMAR)	0.14 \pm 0.11 (0.00-0.40)	0.18 \pm 0.22 (0.00-0.70)	0.220
B. Myopic eyes			
Mean \pm SD (range)			
	Pre-PRK	Post-PRK	P
Age (year)	65.8 \pm 9.8 (45.4 to 78.3)		
Sex (male: female)	3:8		
Spherical refraction (D)	-0.43 \pm 0.85 (-1.75 to+1.00)	+0.14 \pm 0.26 (0.00 to+0.75)	0.023
Cylindrical refraction (D)	-0.98 \pm 0.59 (-2.25 to 0.00)	-0.25 \pm 0.32 (-0.75 to 0.00)	0.0003
Spherical equivalent (D)	-0.92 \pm 0.65 (-2.00 to-0.13)	+0.01 \pm 0.23 (-0.38 to+0.50)	0.0007
Axial Length (mm)	23.96 \pm 1.67 (22.41 to 28.29)		
UDVA (logMAR)	0.54 \pm 0.22 (0.22 to 1.00)	0.25 \pm 0.28 (0.00 to 0.70)	0.025
BCDVA (logMAR)	0.16 \pm 0.09 (0.00 to 0.22)	0.21 \pm 0.24 (0.00 to 0.70)	0.210
C. Hyperopic eyes			
Mean \pm SD (range)			
	Pre-PRK	Post-PRK	P
Age (year)	68.7 \pm 6.3 (57.9 to 73.5)		
Sex (male: female)	3:4		
Spherical refraction (D)	+1.21 \pm 0.30 (+0.75 to+1.75)	-0.11 \pm 0.40 (-0.75 to+0.50)	0.0001
Cylindrical refraction (D)	-0.82 \pm 0.51 (-1.50 to 0.00)	-0.96 \pm 0.92 (-2.75 to 0.00)	0.327
Spherical equivalent (D)	+0.80 \pm 0.41 (+0.25 to+1.25)	-0.59 \pm 0.54 (-1.38 to+0.25)	0.0005
Axial length (mm)	23.53 \pm 0.92 (22.31 to 25.02)		
UDVA (logMAR)	0.36 \pm 0.14 (0.15 to 0.52)	0.23 \pm 0.19 (0.00 to 0.52)	0.099
BCDVA (logMAR)	0.11 \pm 0.15 (0.00 to 0.40)	0.12 \pm 0.17 (0.00 to 0.40)	0.436

D = Diopter, logMAR = Logarithm of minimal angle of resolution, UDVA = Uncorrected distance visual acuity, BCDVA = Best-corrected distance visual acuity, PRK = Photorefractive keratectomy, SD = Standard deviation

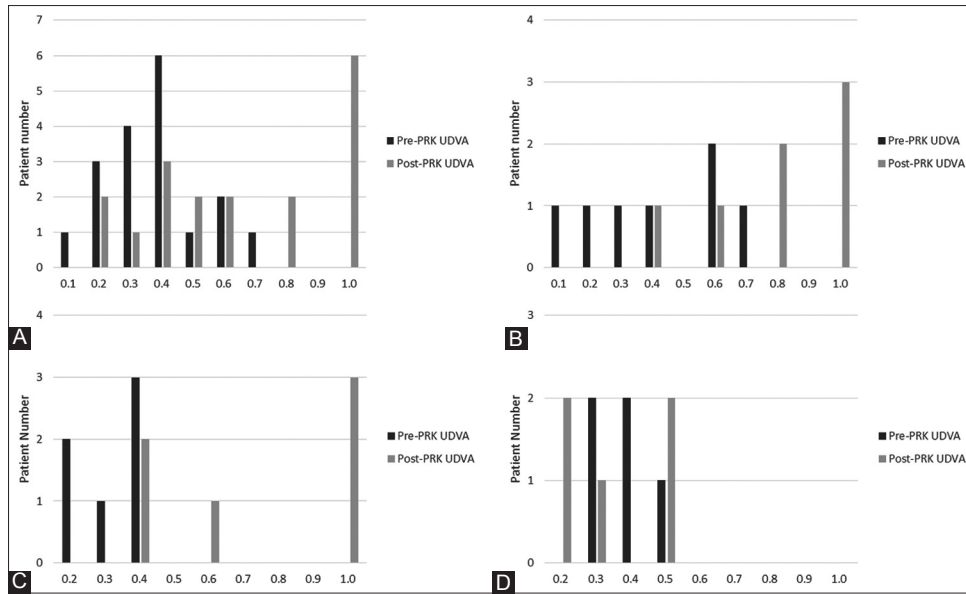


Figure 1: Pre- and post-PRK UDVA in (A) all eyes, (B) Group 1: aspheric IOL group, (C) Group 2: diffractive multifocal IOL group, and (D) Group 3: toric IOL group. UDVA = Uncorrected distance visual acuity, IOL = Intraocular lens, PRK = Photorefractive keratectomy

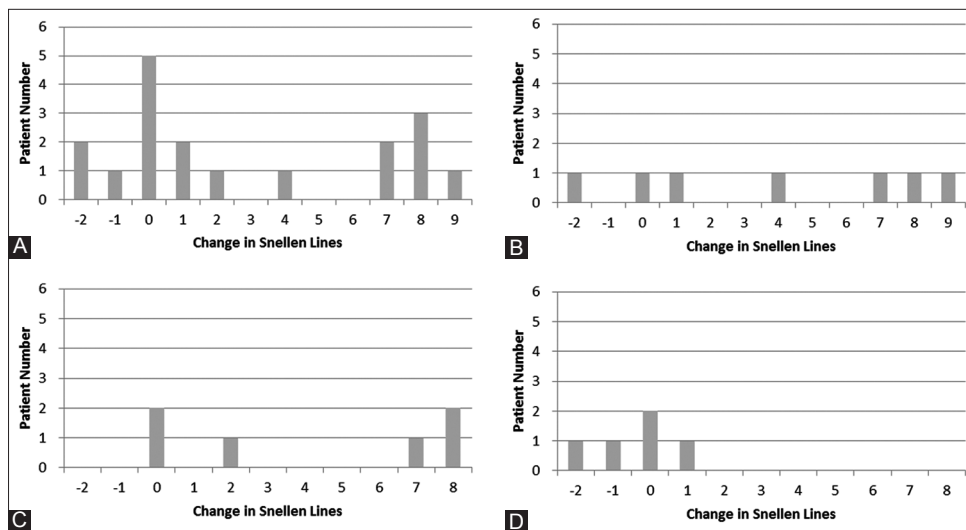


Figure 2: Change in Snellen lines of UDVA after PRK in (A) all eyes, (B) Group 1: aspheric IOL group, (C) Group 2: diffractive multifocal IOL group, and (D) Group 3: toric IOL group. UDVA = Uncorrected distance visual acuity, IOL = Intraocular lens, PRK = Photorefractive keratectomy

We further divided our patient into three groups according to the IOL models that were implanted. Group 1 includes seven eyes in seven patients with aspheric IOL implantation, Group 2 six eyes in five patients with diffractive multifocal IOL implantation, and Group 3 five eyes in five patients with toric IOL implantation. The pre-PRK condition in three groups is shown in Table 3. There were no significant differences in the prevalence of AMD and NPDR, the time between cataract surgery and PRK, pre-PRK spherical refraction, SE, UDVA, BCDVA and axial length among the three groups. Although the patients in Group 3 seemed to be older, and ANOVA test showed a significant difference in age between groups, the *post hoc* analysis revealed

no significant differences between any two of the three groups. However, the pre-PRK cylindrical refraction was significantly larger in Group 3 than in Group 2, and there was also significantly larger pre-PRK keratometric astigmatism in Group 3 comparing to either Group 1 or Group 2, as shown by the *post hoc* analysis [Table 3].

Group 1 includes seven eyes in seven patients with aspheric IOL implantation. In this group, the pre-PRK logMAR UDVA was 0.46 ± 0.31 (range 0.15–1.00). The UDVA improved 1 line or more in five eyes, remained unchanged in one eye, and lost 2 lines in one eye after PRK [Figure 2]. The logMAR UDVA after PRK was 0.12 ± 0.15 (range 0.00–0.40), and the improvement of

Table 3: Comparison of pre-photorefractive keratectomy condition between the three groups

	Aspheric IOL group	Diffraction multifocal IOL group	Toric IOL group	P
Age at PRK (years)	64.2±9.2	63.4±7.0	75.0±2.5	0.032*
AMD, n (%)	1 (14.3)	3 (50.0)	2 (40.0)	0.369
NPDR, n (%)	1 (14.3)	0 (0)	1 (20.0)	0.543
Time between cataract surgery and PRK (months)	10.27±5.31	10.46±8.91	10.81±2.61	0.989
Pre-PRK spherical refraction (D)	-0.04±1.13	0.00±1.17	+0.80±0.78	0.367
Pre-PRK cylindrical refraction (D)	-0.86±0.48	-0.58±0.41 [†]	-1.40±0.52 [†]	0.034
Pre-PRK spherical equivalent (D)	-0.46±1.06	-0.29±1.24	+0.10±0.81	0.667
Pre-PRK keratometric astigmatism (D)	0.58±0.27 [‡]	0.72±0.34 [§]	1.81±0.87 ^{§§}	0.004
Axial length (mm)	24.32±2.01	23.61±0.53	23.20±0.68	0.397
Pre-PRK UDVA (logMAR)	0.46±0.31	0.52±0.15	0.43±0.09	0.780
Pre-PRK BCDVA (logMAR)	0.08±0.10	0.19±0.13	0.16±0.08	0.179

P values were calculated with Chi-square test for categorical variables, and with one-way ANOVA test and Scheffe's post hoc test for continuous variables. *Post hoc analysis no significant difference between groups, [†]Post hoc analysis P=0.036, [‡]Post hoc analysis P=0.006, [§]post hoc analysis P=0.021. ANOVA: Analysis of variance. PRK=Photorefractive keratectomy, IOL=Intraocular lens, AMD=Age-related macular degeneration, NPDR=Non-proliferative diabetic retinopathy, D=Diopter, UDVA=Uncorrected distance visual acuity, BCDVA=Best-corrected distance visual acuity, logMAR=Logarithm of minimal angle of resolution

UDVA was statistically significant ($P = 0.037$) [Table 4]. Except for the eye with deteriorated UDVA, other six eyes (85.7%) had final UDVA $>20/40$.

Group 2 includes six eyes in five patients with diffractive multifocal IOL implantation, in whom the pre-PRK logMAR UDVA was 0.52 ± 0.15 (range 0.40–0.70). The final UDVA improved 1 line or more in four eyes, and remained unchanged in two eyes. The improvement of UDVA after PRK in this group was also significant ($P = 0.025$), with post-PRK logMAR UDVA 0.17 ± 0.20 (range 0.00–0.40) [Table 4]. The four eyes (66.7%) with UDVA improvement all had final UDVA $>20/40$, and three of the four eyes achieved the UDVA of 20/20.

Group 3 includes five eyes in five patients who had a toric IOL implantation. The final UDVA after PRK improved 1 line in one eye, remained unchanged in two eyes, and decreased in two eyes [Figure 2]. The logMAR UDVA before and after PRK were 0.43 ± 0.09 (range 0.30–0.52) and 0.50 ± 0.20 (range 0.30–0.70), respectively, and the change was not significant ($P = 0.174$). In this group, only 2 eyes (40%) achieved final UDVA $>20/40$. However, it is worth noting that the logMAR BCDVA decreased significantly in this group ($P = 0.003$) [Table 4]. The pre- and post-PRK visual acuity and refractive status of the three groups is summarized in Table 4.

Figure 3 shows the scatterplots of the targeted versus the achieved manifest spherical and cylindrical corrections. All the 18 eyes were within ± 1.00 D of the attempted spherical correction, although there was a trend toward slight under-correction. However, only 13 of the 18 eyes (72.2%) were within ± 1.00 D of the attempted cylindrical correction. While dividing the patients into the myopic group and hyperopic group according to pre-PRK SE, there seemed to be a more obvious trend toward slight under-correction for spherical

error for myopic eyes. For cylindrical correction, the predictability was also higher in myopic eyes: 9 out of 11 eyes (81.8%) were within ± 1.00 D of the attempted cylindrical correction in myopic eyes, whereas only 4 out of 7 eyes (57.1%) were within ± 1.00 D of the attempted cylindrical correction in hyperopic eyes [Figure 3]. The scatterplots of the attempted versus achieved manifest spherical and cylindrical correction for both groups are shown in Figure 3.

Discussion

Phacoemulsification and IOL implantation are one of the most frequent ophthalmological procedures in clinical practice in Taiwan. From 2005 to 2014, an average of 126,500 cases of cataract extraction with IOL implantation was performed every year, and the average cataract surgery rate was 6,120 per million people per year.^[2] About 95% of those cataract surgeries were done with phacoemulsification.^[2] In recent years, premium IOL, including aspheric IOL, diffractive multifocal IOL, and toric IOL are also in growing demand, even though the patients need to pay extra money for the premium IOLs, while the standard spherical IOLs was covered by the National Health Insurance in Taiwan. Today, the frequency and incidence of severe complications of cataract surgery are relatively low. The most frequent postoperative problem is a residual refractive error, which may lead to suboptimal visual outcomes and patient's dissatisfactions since patients generally consider spectacle-free as an important issue.^[3,4,21-24] Causes of residual refractive error include errors in biometry measurement and the use of inappropriate power calculation formulas, as well as IOL manufacturing inaccuracies, displacement of the IOL in the capsular bag, the excessive rotational divergence of a toric IOL, and other reasons.^[3,6,7,25-28] For successful outcome with premium IOLs, accurate correction of even small spherical and cylindrical errors is necessary,

Table 4: The age, sex, pre- and post-photorefractive keratectomy refractive status, uncorrected distance visual acuity and best-corrected distance visual acuity in (A) Group 1: aspheric Intraocular lens group, (B) Group 2: diffractive multifocal Intraocular lens group, and (C) Group 3: toric Intraocular lens group

A. Group 1: Aspheric IOL group				
Mean±SD (range)				
	Pre-PRK	Post-PRK	P	
Age (year)	64.2±9.2 (45.4 to 72.6)			
Sex (male: female)	4:3			
Spherical refraction (D)	-0.04±1.13 (-1.50 to+1.25)	-0.07±0.19 (-0.50 to 0.00)		
Cylindrical refraction (D)	-0.86±0.48 (-1.50 to 0.00)	-0.32±0.37 (-1.00 to 0.00)		
Spherical equivalent (D)	-0.46±1.06 (-2.00 to+1.00)	-0.23±0.36 (-1.00 to 0.00)		
Keratometric astigmatism (D)	0.58±0.27 (0.25 to 0.97)			
Axial length (mm)	24.32±2.01 (22.31 to 28.29)			
UDVA (logMAR)	0.46±0.31 (0.15 to 1.00)	0.12±0.15 (0.00 to 0.40)	0.037	
BCDVA (logMAR)	0.08±0.10 (0.00 to 0.22)	0.05±0.09 (0.00 to 0.22)	0.259	
B. Group 2: Diffractive multifocal IOL group				
Mean±SD (range)				
	Pre-PRK	Post-PRK	P	
Age (year)	63.4±7.0 (53.4 to 71.0)			
Sex (male: female)	2:3			
Spherical refraction (D)	0.00±1.17 (-1.75 to+1.25)	+0.13±0.52 (-0.75 to+0.75)		
Cylindrical refraction (D)	-0.58±0.41 (-1.25 to 0.00)	-0.29±0.33 (-0.75 to 0.00)		
Spherical equivalent (D)	-0.29±1.24 (-2.00 to+1.25)	-0.02±0.46 (-0.75 to+0.50)		
Keratometric astigmatism (D)	0.72±0.34 (0.40 to 1.17)			
Axial Length (mm)	23.61±0.53 (23.13 to 24.30)			
UDVA (logMAR)	0.52±0.15 (0.40 to 0.70)	0.17±0.20 (0.00 to 0.40)	0.025	
BCDVA (logMAR)	0.19±0.13 (0.00 to 0.40)	0.10±0.16 (0.00 to 0.30)	0.161	
C. Group 3: Toric IOL group				
Mean±SD (range)				
	Pre-PRK	Post-PRK	P	
Age (year)	75.0±2.5 (73.0 to 78.3)			
Sex (male: female)	0:5			
Spherical refraction (D)	+0.80±0.78 (0.00 to+1.75)	+0.10±0.22 (0.00 to+0.50)		
Cylindrical refraction (D)	-1.40±0.52 (-2.25 to-1.00)	-1.10±1.07 (-2.75 to 0.00)		
Spherical equivalent (D)	+0.10±0.81 (-0.75 to+1.13)	-0.45±0.62 (-1.38 to+0.13)		
Keratometric astigmatism (D)	1.81±0.87 (0.94 to 3.25)			
Axial Length (mm)	23.20±0.68 (22.41 to 24.11)			
UDVA (logMAR)	0.43±0.09 (0.30 to 0.52)	0.50±0.20 (0.30 to 0.70)	0.174	
BCDVA (logMAR)	0.16±0.08 (0.05 to 0.22)	0.44±0.17 (0.30 to 0.70)	0.003	

D = Diopter, logMAR = Logarithm of minimal angle of resolution, UDVA = Uncorrected distance visual acuity, BCDVA = Best-corrected distance visual acuity, PRK = Photorefractive keratectomy, SD = Standard deviation, IOL = Intraocular lens

especially for those with diffractive multifocal IOL implantation.^[14,15,18,29]

The aim of our study was to evaluate the outcome of correcting residual refractive error after cataract surgery with premium IOL implantation by PRK. Patients enrolled in our study were older, and they may have higher socioeconomic status and higher demand for vision. We demonstrated that in this patient group PRK is suitable for correcting the relatively small residual refractive error, and thus results in improvement in UDVA and patient satisfaction, especially in patients with aspheric IOL and diffractive multifocal IOL implantation. For patients with toric IOL implantation, the results were suboptimal. This may be related to the patients' older

age in the toric IOL group, which may make PRK less predictable and less effective,^[30] although the difference in age did not reach a statistical significance. The toric IOL position in the eye also matters, which may also make the correction less predictable.^[26,31] Moreover, the patients' larger pre-PRK cylindrical refraction as well as larger pre-PRK keratometric astigmatism may also result in less predictable outcomes, as demonstrated in this study as well as previous studies.^[15,32] Nevertheless, regarding the decreased BCDVA in eyes with toric IOL implantation, the reasons for this unfavorable result still remained unclear since there were no corneal haze, after-cataract or other media opacities that could be identified in the medical record. More coincidental progression of concomitant retinal disorders in the toric IOL group may

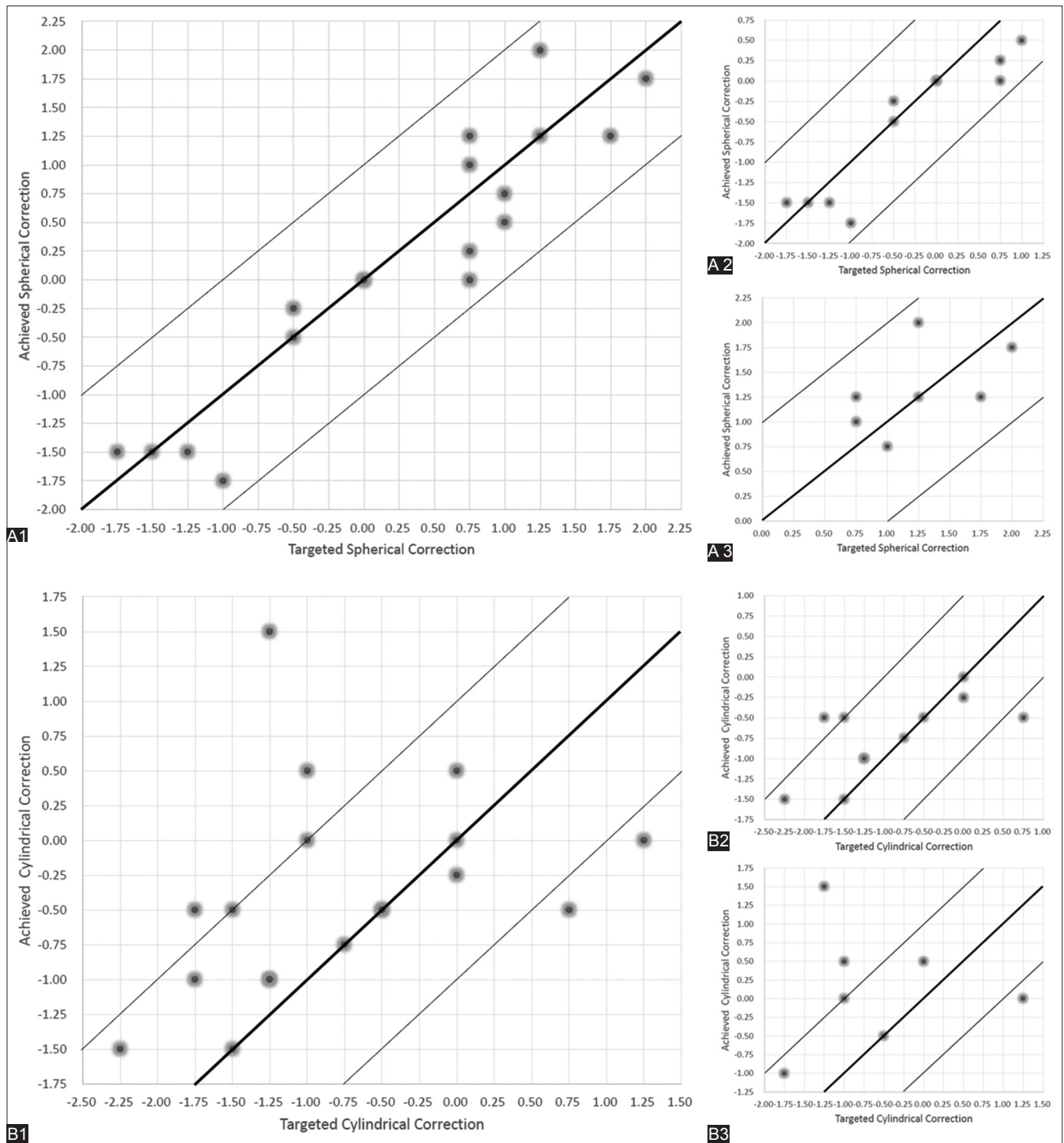


Figure 3: (A) Scatterplots of the attempted versus achieved manifest spherical correction in (A1) all eyes, (A2) myopic eyes, and (A3) hyperopic eyes. (B) Scatterplots of the attempted versus achieved manifest cylindrical correction in (B1) all eyes, (B2) myopic eyes, and (B3) hyperopic eyes.

contribute to the worsened BCDVA, as there seemed to be a slightly higher percentage of retinal disorders in those eyes with toric IOL implantation. However, this could not be confirmed in this retrospective study due to lack of detailed records regarding retinal conditions, and the differences in the percentage of retinal disorders did not reach statistical significance. Since we are the first to report the results of PRK on residual refractive

error after toric IOL implantation, and are also the first to present the worsened BCDVA after this procedure, it still could not be excluded that the treatment itself could lead to this unfavorable outcome in this specific patient group, for some reasons not being discovered yet. If this phenomenon is repeatedly observed in the future, then further investigations regarding this issue will be needed. Currently, given that PRK is inferior in correcting

residual astigmatism after toric IOL implantation, surgeons should detect the problem as soon as possible, and should consider IOL rotation as the first choice for management of residual refractive error.

LASIK and PRK were both been studied regarding their utilization for correcting residual refractive error after cataract surgery^[3,8-15] [Table 1], refractive lens exchange,^[16-19] and phakic IOL implantation,^[20] with similar efficacy, safety and predictability being demonstrated.^[13,18,20] Compared to PRK, LASIK is associated with more rapid recovery of vision, less postoperative discomfort, less corneal haze formation, and less need for prolonged steroid use.^[33] However, PRK is more suitable for patients with preexisting dry eye syndrome, decreased corneal thickness, and/or irregular astigmatism.^[7,20] In addition, although generally safe, several complications may still occur during or after LASIK, including flap-related complications such as opaque bubble layer, flap buttonholes, free flaps or incomplete flaps, as well as diffuse lamellar keratitis, flap striae, flap displacement, epithelial ingrowth, and stromal wrinkles.^[34-36] Once happened, the visual prognosis may possibly be affected. Therefore, regarding safety issue, PRK represents a more reasonable choice relative to LASIK for correcting the residual refractive error, for avoiding the aforementioned complications,^[7,15] especially in this patient population with higher demand on vision and lower tolerance to risks. Moreover, since the residual refractive error was supposed to be relatively small in this patient group, the severity and duration of corneal haze after PRK would not be significant, and would not affect final visual outcomes, as demonstrated in our study.

It is worth noting that in previous studies regarding the use of LASIK and/or PRK for correcting residual refractive error after cataract surgery,^[3,8-15] the residual refractive errors were still relatively large since a lower limit of the manifest refraction was usually set as one of the criteria for the treatment. Comparing to those studies, the residual refractive error in our patients were relatively small, and thus an improvement in UDVA might not be that significant in some patients. Nevertheless, the changes of refractive results were still significant in both myopic and hyperopic eyes, and the improvements in UDVA were still promising, especially in patients with aspheric IOL and diffractive multifocal IOL implantation. More importantly, all patients were satisfied with the post-PRK results, and no serious complications were observed.

We also demonstrated good predictability of PRK in this study. With analyzing the attempted versus the achieved manifest spherical and cylindrical corrections, we demonstrated that all eyes in our study could achieve ± 1.00 D of the targeted spherical correction. Furthermore, we found that cylindrical correction was

less predictable, which was similar to a previous study.^[15] Moreover, there is also a trend toward under-correction for myopic eyes, which was also similar to a previous study.^[12]

There are several limitations in our study. First, this is a retrospective noncomparative study including a relatively small number of cases. Second, the time between cataract surgery and PRK varied between cases. Finally, other outcome measurements including spectacle dependence, contrast sensitivity, and patient-reported outcomes such as the satisfaction of treatment and quality of life were not recorded in the chart, thus making them impossible to be evaluated in this retrospective study. If available, analyzing those data may provide more information about the impact of PRK on those patients with higher expectations.

Conclusion

Our study showed that PRK is a safe, effective, and predictable surgical method for correcting small residual refractive error following phacoemulsification with premium IOL implantation in the elderly population. Although satisfactory for all patients, the outcomes were better and more predictable in patients with aspheric and diffractive multifocal IOL implantation and were less satisfactory and unpredictable in patients with toric IOL implantation. To the best of our knowledge, this study is the first to evaluate the outcome of PRK in correcting residual refractive error in patients with toric IOL implantation and is also the first to compare the results between patients with aspheric, diffractive multifocal, and toric IOL implantation. Further large-scale studies with randomized controlled prospective design and with patient-reported outcome measurements are still needed to further verify the efficacy, safety, predictability, advantages, and disadvantages of PRK in this patient group with premium IOL implantation, and even in patients with implantation of newer IOL designs such as bifocal IOL, trifocal IOL, rotationally asymmetric refractive multifocal IOL, and the next generation accommodative IOL in the future.

Declaration of patient consent

The authors certify that they have obtained all appropriate patient consent forms. In the form the patient(s) has/have given his/her/their consent for his/her/their images and other clinical information to be reported in the journal. The patients understand that their names and initials will not be published and due efforts will be made to conceal their identity, but anonymity cannot be guaranteed.

Acknowledgment

This study was partially supported by Chang Gung Memorial Hospital Research Grants (CMRPG3E1831).

The sponsor had no role in the design or conduct of this research.

Financial support and sponsorship

Nil.

Conflicts of interest

The authors declare that there are no conflicts of interests of this paper.

References

- Hsu WM, Liu JH. Ophthalmology in Taiwan. *Taiwan J Ophthalmol* 2014;4:59-62.
- Hsu WM. Current status of ophthalmology in Taiwan. *J Clin Exp Ophthalmol* 2015;6:485.
- Artola A, Ayala MJ, Claramonte P, Pérez-Santonja JJ, Alió JL. Photorefractive keratectomy for residual myopia after cataract surgery. *J Cataract Refract Surg* 1999;25:1456-60.
- Raman S, Redmond R. Reasons for secondary surgical intervention after phacoemulsification with posterior chamber lens implantation. *J Cataract Refract Surg* 2003;29:513-7.
- Narváez J, Zimmerman G, Stulting RD, Chang DH. Accuracy of intraocular lens power prediction using the hoffer Q, holladay 1, holladay 2, and SRK/T formulas. *J Cataract Refract Surg* 2006;32:2050-3.
- Sáles CS, Manche EE. Managing residual refractive error after cataract surgery. *J Cataract Refract Surg* 2015;41:1289-99.
- Moshirfar M, McCaughey MV, Santiago-Caban L. Corrective techniques and future directions for treatment of residual refractive error following cataract surgery. *Expert Rev Ophthalmol* 2014;9:529-37.
- Jin GJ, Merkley KH, Crandall AS, Jones YJ. Laser *in situ* keratomileusis versus lens-based surgery for correcting residual refractive error after cataract surgery. *J Cataract Refract Surg* 2008;34:562-9.
- Fernández-Buenaga R, Alió JL, Pérez Ardoy AL, Quesada AL, Pinilla-Cortés L, Barraquer RI, *et al.* Resolving refractive error after cataract surgery: IOL exchange, piggyback lens, or LASIK. *J Refract Surg* 2013;29:676-83.
- Patterson A, Kaye SB, O'Donnell NP. Comprehensive method of analyzing the results of photoastigmatic refractive keratectomy for the treatment of post-cataract myopic anisometropia. *J Cataract Refract Surg* 2000;26:229-36.
- Ayala MJ, Pérez-Santonja JJ, Artola A, Claramonte P, Alió JL. Laser *in situ* keratomileusis to correct residual myopia after cataract surgery. *J Refract Surg* 2001;17:12-6.
- Kim P, Briganti EM, Sutton GL, Lawless MA, Rogers CM, Hodge C. Laser *in situ* keratomileusis for refractive error after cataract surgery. *J Cataract Refract Surg* 2005;31:979-86.
- Kuo IC, O'Brien TP, Broman AT, Ghajarnia M, Jabbur NS. Excimer laser surgery for correction of ametropia after cataract surgery. *J Cataract Refract Surg* 2005;31:2104-10.
- Muftuoglu O, Prasher P, Chu C, Mootha VV, Verity SM, Cavanagh HD, *et al.* Laser *in situ* keratomileusis for residual refractive errors after apodized diffractive multifocal intraocular lens implantation. *J Cataract Refract Surg* 2009;35:1063-71.
- Kamiya K, Umeda K, Ando W, Igarashi A, Shimizu K. Clinical outcomes of photoastigmatic refractive keratectomy for the correction of residual refractive errors following cataract surgery. *J Refract Surg* 2011;27:826-31.
- Pop M, Payette Y, Amyot M. Clear lens extraction with intraocular lens followed by photorefractive keratectomy or laser *in situ* keratomileusis. *Ophthalmology* 2001;108:104-11.
- Leccisotti A. Secondary procedures after presbyopic lens exchange. *J Cataract Refract Surg* 2004;30:1461-5.
- Macsai MS, Fontes BM. Refractive enhancement following presbyopia-correcting intraocular lens implantation. *Curr Opin Ophthalmol* 2008;19:18-21.
- Alfonso JF, Fernández-Vega L, Montés-Micó R, Valcárcel B. Femtosecond laser for residual refractive error correction after refractive lens exchange with multifocal intraocular lens implantation. *Am J Ophthalmol* 2008;146:244-50.
- Sánchez-Galeana CA, Smith RJ, Rodriguez X, Montes M, Chayet AS. Laser *in situ* keratomileusis and photorefractive keratectomy for residual refractive error after phakic intraocular lens implantation. *J Refract Surg* 2001;17:299-304.
- Oshika T, Yoshitomi F, Fukuyama M, Hara Y, Shimokawa S, Shiwa T, *et al.* Radial keratotomy to treat myopic refractive error after cataract surgery. *J Cataract Refract Surg* 1999;25:50-5.
- Pineda-Fernández A, Jaramillo J, Celis V, Vargas J, DiStacio M, Galíndez A, *et al.* Refractive outcomes after bilateral multifocal intraocular lens implantation. *J Cataract Refract Surg* 2004;30:685-8.
- Hawker MJ, Madge SN, Baddeley PA, Perry SR. Refractive expectations of patients having cataract surgery. *J Cataract Refract Surg* 2005;31:1970-5.
- Mesci C, Erbil HH, Olgun A, Yaylali SA. Visual performances with monofocal, accommodating, and multifocal intraocular lenses in patients with unilateral cataract. *Am J Ophthalmol* 2010;150:609-18.
- Eleftheriadis H. IOLMaster biometry: Refractive results of 100 consecutive cases. *Br J Ophthalmol* 2003;87:960-3.
- Jin H, Limberger IJ, Ehmer A, Guo H, Auffarth GU. Impact of axis misalignment of toric intraocular lenses on refractive outcomes after cataract surgery. *J Cataract Refract Surg* 2010;36:2061-72.
- Murphy C, Tuft SJ, Minassian DC. Refractive error and visual outcome after cataract extraction. *J Cataract Refract Surg* 2002;28:62-6.
- Norrby S. Sources of error in intraocular lens power calculation. *J Cataract Refract Surg* 2008;34:368-76.
- Lee ES, Lee SY, Jeong SY, Moon YS, Chin HS, Cho SJ, *et al.* Effect of postoperative refractive error on visual acuity and patient satisfaction after implantation of the array multifocal intraocular lens. *J Cataract Refract Surg* 2005;31:1960-5.
- Loewenstein A, Lipshitz I, Levanon D, Ben-Sirah A, Lazar M. Influence of patient age on photorefractive keratectomy for myopia. *J Refract Surg* 1997;13:23-6.
- Alpins N, Ong JK, Stamatelatos G. Refractive surprise after toric intraocular lens implantation: Graph analysis. *J Cataract Refract Surg* 2014;40:283-94.
- Katz T, Wagenfeld L, Galambos P, Darrelmann BG, Richard G, Linke SJ. LASIK versus photorefractive keratectomy for high myopic (>3 diopter) astigmatism. *J Refract Surg* 2013;29:824-31.
- Sun CC, Chang CK, Ma DH, Lin YF, Chen KJ, Sun MH, *et al.* Dry eye after LASIK with a femtosecond laser or a mechanical microkeratome. *Optom Vis Sci* 2013;90:1048-56.
- Stulting RD, Carr JD, Thompson KP, Waring GO 3rd, Wiley WM, Walker JG. Complications of laser *in situ* keratomileusis for the correction of myopia. *Ophthalmology* 1999;106:13-20.
- Sutton G, Lawless M, Hodge C. Laser *in situ* keratomileusis in 2012: A review. *Clin Exp Optom* 2014;97:18-29.
- Liu CH, Sun CC, Ma DH, Huang JC, Liu CF, Chen HF, *et al.* Opaque bubble layer: Incidence, risk factors, and clinical relevance. *J Cataract Refract Surg* 2014;40:435-40.