

Unmasking histoplasmosis immune reconstitution inflammatory syndrome in a patient recently started on antiretroviral therapy

Reuben Kiggundu^a, Henry W Nabeta^b, Richard Okia^b, Joshua Rhein^{a,c},
Robert Lukande^d

Kiggundu R, Nabeta HW, Okia R, Rhein J, Lukande R. Unmasking histoplasmosis immune reconstitution inflammatory syndrome in a patient recently started on antiretroviral therapy. *Autopsy Case Rep* [Internet]. 2016;6(4):27-33. <http://dx.doi.org/10.4322/acr.2016.048>

ABSTRACT

Histoplasmosis is the most common endemic mycoses among HIV-infected people. Patients with suppressed cell immunity mainly due to HIV are at increased risk of disseminated disease. Dermatological manifestations of immune reconstitution inflammatory syndrome (IRIS) and cutaneous manifestations of histoplasmosis similar to an IRIS event have been previously described. We report the case of a 43-year-old male who presented with cutaneous disseminated histoplasmosis due to *Histoplasma capsulatum* var. *capsulatum* 4 months after the onset of the antiretroviral therapy and some improvement in the immune reconstitution. After 2 weeks of amphotericin B and itraconazole therapy, the scheduled treatment involved fluconazole maintenance therapy, which resulted in an improvement of his skin lesions.

Keywords

Histoplasmosis; Immune Reconstitution Inflammatory Syndrome; Antiretroviral Therapy, Highly Active, Fluconazole

INTRODUCTION

Histoplasmosis is a systemic fungal infection caused by the intracellular dimorphic fungus *Histoplasma capsulatum*. It is endemic in the USA, but has been reported in South America and Africa.^{1,2} Clinical presentation of histoplasmosis is nonspecific, and 95% of the patients with *H. capsulatum* infections are asymptomatic. Therefore, the clinical presentation of histoplasmosis may vary from asymptomatic to disseminated disease depending on the patient's immunological status.³⁻⁵ Histoplasmosis is an

AIDS-defining opportunistic infection presenting as an invasive form.⁶⁻⁸

Immune reconstitution inflammatory syndrome (IRIS)-related dermatological manifestations of HIV are common, and cutaneous histoplasmosis following antiretroviral therapy (ART) was previously described.^{9,10} We report the case of an HIV-infected patient who presented with cutaneous histoplasmosis 4 months after the onset of ART, with viral suppression and immunological recovery, which were consistent with

^a College of Health Sciences - Infectious Disease Institute - Makerere University, Kampala – Uganda.

^b College of Health Sciences - School of Medicine - Makerere University, Kampala – Uganda.

^c Department of Medicine - University of Minnesota, Minneapolis/MN – USA.

^d College of Health Sciences - School of Biomedical Sciences - Makerere University, Kampala – Uganda.



an IRIS event. The clinical manifestations, diagnosis, and management of histoplasmosis IRIS are reviewed.

CASE REPORT

A 43-year-old male, known to be HIV infected for 6 months, was referred by his primary HIV clinic to the Mulago National Referral Hospital in Uganda with a 2-month history of nodular lesions in the face. Skin findings were also associated with a nonproductive cough, dyspnea, and fever over the past month. The skin nodules started to appear 2 months after ART was initiated, and began as small lesions on the nose that progressed in size and number throughout the face. The patient was initially and empirically treated with azithromycin with the hypothesis of atypical *Mycobacterium cuneiform* infection, with mild clinical improvement. The patient was started on ART (tenofovir 300 mg/day, lamivudine 300 mg/day, and efavirenz 600 mg/day) and trimethoprim/sulfamethoxazole for prophylaxis at the time of HIV infection diagnosis.

His past medical history included the diagnosis of HIV infection 6 months earlier, with a nadir CD4 determination of 42 cells/mm³.

On examination, his general condition was fair, with no lymphadenopathy, normal vital signs, and a clear chest exam. Skin examination showed hyper-pigmented nodular lesions on his face with varying diameters. The larger lesions (approximately 2 cm × 3.5 cm) were on the nose (Figure 1). The abdominal examination did not reveal hepatosplenomegaly.

The patient's chest x-ray was normal; thoracic computed tomography was not performed. Laboratory investigations revealed normal hematological indices and serum electrolytes.

The serological test for HIV was positive. The viral load for HIV was undetectable, and CD4 was 108 cells/mm³. Diagnoses of Kaposi sarcoma, bacillary angiomatosis, squamous cell carcinoma, and invasive mycosis were considered. A punch biopsy was obtained from two lesions of the face. Histological examination showed granulomatous dermatitis with round cytoplasmic organelles within the macrophages consistent with *H. capsulatum* var. *capsulatum* (Figure 2 and Figure 3).

A diagnosis of unmasking mucocutaneous histoplasmosis IRIS was made. The patient was started on intravenous amphotericin B (1 mg/kg) daily

and oral itraconazole (400 mg daily) for 2 weeks, besides potassium and magnesium supplementation, paracetamol, and 3 L of intravenous saline daily during hospitalization. Antiretroviral therapy was continued. The patient's renal function and complete blood count remained within normal ranges during the course of amphotericin.

On completion of the amphotericin treatment, the patient's symptoms regressed and he was discharged after 14 days on oral fluconazole 400 mg daily, as he could not afford the high cost of itraconazole. The patient has been monitored monthly since hospital discharge and continues to improve on fluconazole therapy and ART. His clinical status is favorable; the skin lesions are healing but leaving enduring scarring and partial destruction of the nasal cartilage (Figure 4).

DISCUSSION

Histoplasmosis is a common AIDS-defining illness¹¹ caused by *H. capsulatum*, a dimorphic fungus, which is distributed worldwide and is endemic in both South and North America, particularly in the Ohio and Mississippi river valleys in the latter. *H. capsulatum* var. *capsulatum* and *H. capsulatum* var. *duboisii* are the variants that cause human disease.^{12,13} *H. capsulatum* var. *duboisii* is described only in Africa; however, both variants are endemic in Uganda. Spores of *H. capsulatum* are found in the soil and caves inhabited by birds and bats.⁴

Primary lung infection results from the inhalation of microconidia, which turn into yeast in the lungs. The yeast is then spread to the reticuloendothelial system within 2-3 weeks by tissue macrophages.^{5,14}

The clinical presentation of histoplasmosis depends on the integrity of the immune system. Nearly 95% of the infected people with normal immune systems will remain asymptomatic,^{1,15} and the remaining will present acute or chronic pulmonary histoplasmosis.¹⁵

However, individuals with immunosuppressive disorders affecting cell-mediated immunity may present with disseminated histoplasmosis. HIV-infected people with a CD4 cell count below 100 cells/mm³ are at increased risk for the development of disseminated histoplasmosis,^{14,15} which was the case with our patient, who had a CD4 cell count of 42 cells/mm³.

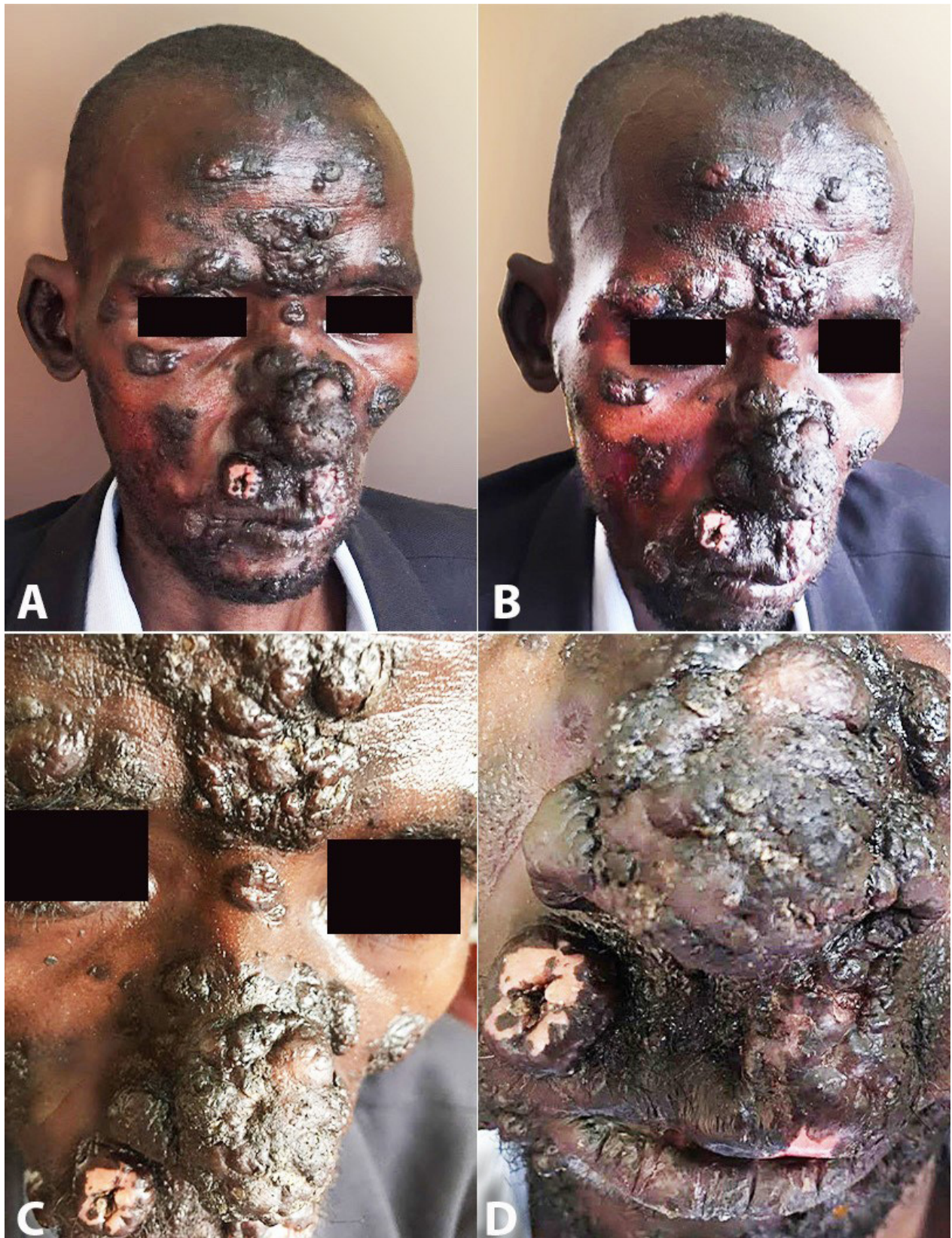


Figure 1. Cutaneous lesions throughout on the face before the antifungal treatment.

Cough, fever, malaise, weight loss, and hepatosplenomegaly represent the most common clinical features of disseminated histoplasmosis. Although gastrointestinal symptoms are rare, 70% of patients with this disease present gastrointestinal

involvement on autopsy.^{1,16,17} Disseminated histoplasmosis may be misdiagnosed as tuberculosis or malaria due to the nonspecificity of the symptoms in many health facilities, especially when the laboratory work-up is limited.

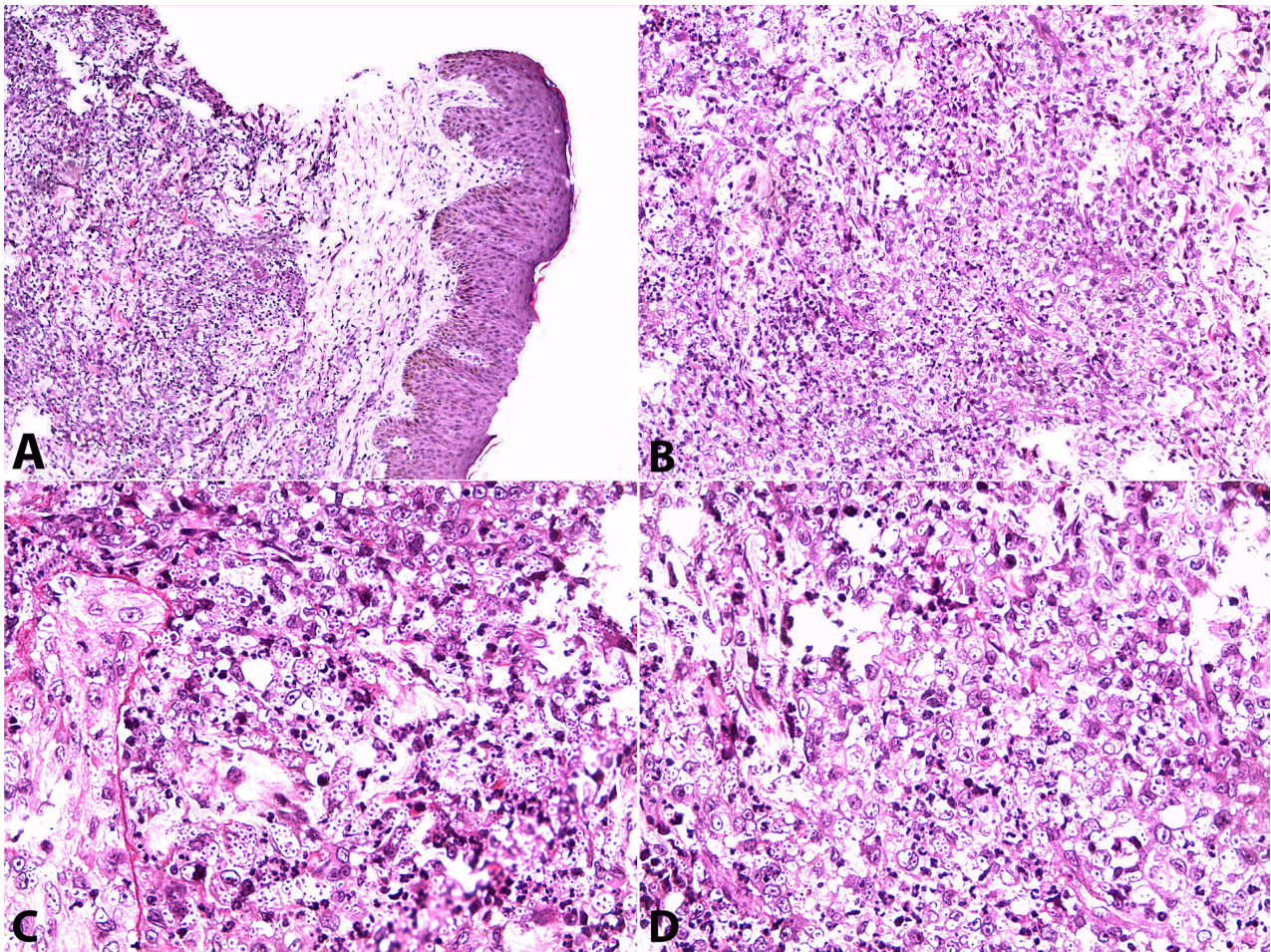


Figure 2. Photomicrography of the skin biopsy. **A** - Normal epidermis and infiltrated dermis (H&E, 100X); **B**, **C**, and **D** - Small, oval, narrow based yeasts consistent with *Histoplasma capsulatum* (H&E, 400X).

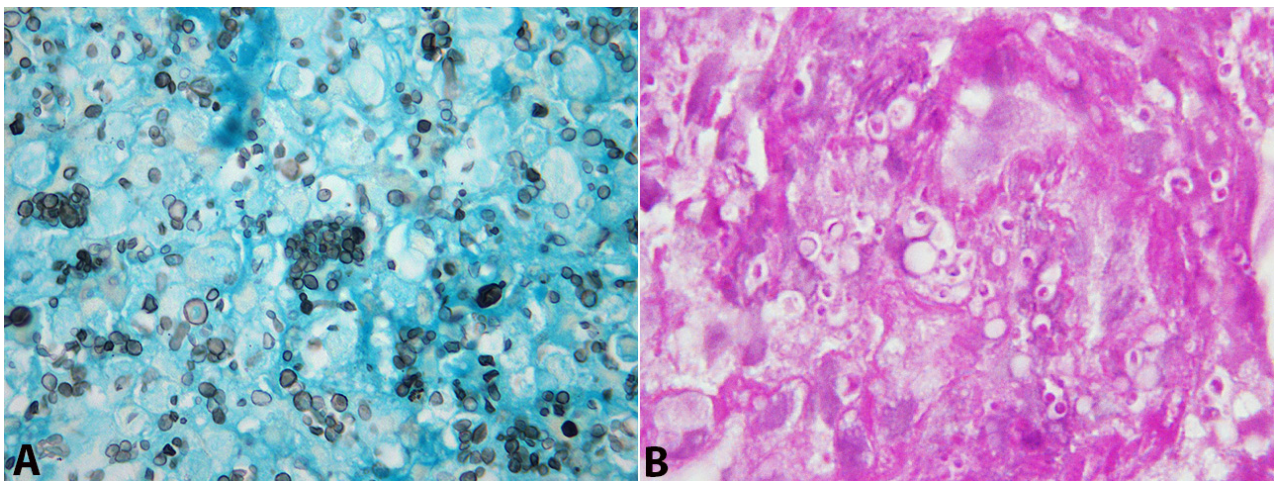


Figure 3. Photomicrography of the skin biopsy showing in **A** - multiple oval-shaped structures consistent with *Histoplasma* sp (Grocott, 1000X); in **B** - PAS staining spores appearing as round or oval structures within the cytoplasm of the macrophages (PAS, 1000X).

Cutaneous presentation is found in 6% of patients with disseminated histoplasmosis.^{5,16,18} However, mucocutaneous involvement varies by geographic location and occurs more commonly in AIDS patients, particularly in those with suspected IRIS.^{9,19} A review of the clinical manifestations of disseminated

histoplasmosis showed that the dermatological manifestation was more common and more extensive in Brazilian HIV-infected people when compared with North American counterparts.⁹ A similar tropism for skin and lymph nodes involvement has been observed in African histoplasmosis. Nacher et al.²⁰ described a

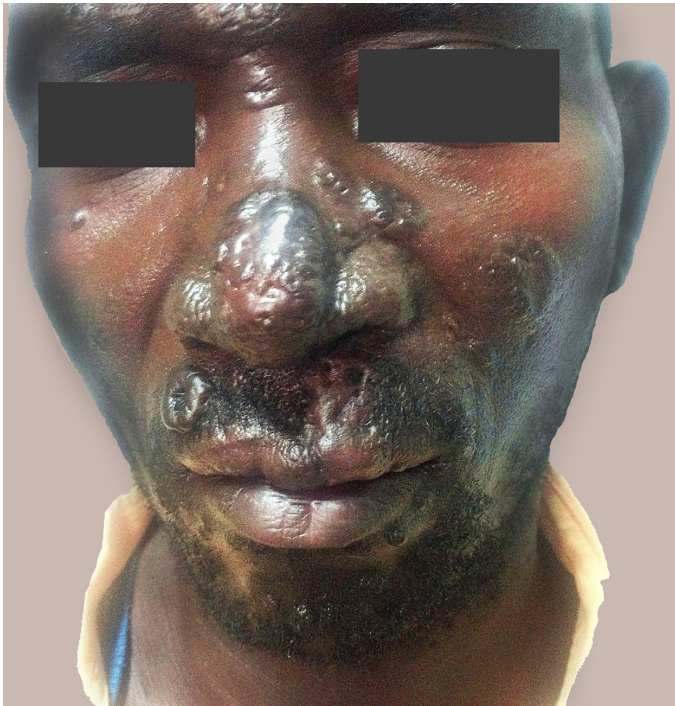

Figure 4. Skin examination after 6 months of treatment.

higher incidence of disseminated histoplasmosis among patients that recently started on antiretroviral therapy, suggesting that this treatment can lead to unmasking IRIS. Passos et al.²¹ reported the case of paradoxical histoplasmosis IRIS following re-introduction of HAART in a Brazilian patient that voluntarily stopped his HAART and itraconazole prophylaxis. Breton et al.²² presented four patients with HIV-associated with unmasking and paradoxical disseminated histoplasmosis IRIS. At the time of presentation, our patient was on ART for 4 months, with immunological response and viral suppression, which are features consistent with unmasking IRIS.^{23,24}

Diverse diagnostic modalities with varying sensitivity and specificity are available for the diagnosis of histoplasmosis, including tissue cultures, fungal stains, and serologic tests for detecting antibodies or antigens.⁵ Isolation of the pathogen in culture media (BACTEC™, Becton Dickinson, Sabouraud's agar) is the gold standard for the diagnosis; however, the isolation takes more than 4 weeks, which limits its clinical applicability.^{25,26} Culture specimens can be obtained from urine, blood, sputum, lymph nodes, bronchoalveolar lavage, or bone marrow aspirate. Serology, although rapid and sensitive, is limited by low specificity because of the cross-reactivity with other fungi. Moreover, serology shows reduced sensitivity in disseminated histoplasmosis and immune suppressed

patients, and the antibodies remain elevated for an extended time, limiting its use for differentiating relapse from an earlier infection.²⁵⁻²⁷ Urinary antigen testing offers rapid diagnosis with the sensitivity of 90% for patients with disseminated histoplasmosis and can be used for monitoring the response to therapy.^{2,25} Assays of histoplasma antigen in our patient's body fluids were not performed as they are not readily available in Uganda.

Histological examination with the aid of Giemsa, Wright, the periodic acid of Schiff (PAS), or methenamine silver stainings provides a less expensive and rapid diagnosis, but has loose sensitivity for the antigenic tests. *H. capsulatum* appears in macrophages as ovoid or spherical uninucleate yeasts of 2–4 micrometers with narrow base buds.⁵ *Pneumocystis jiroveci*, *Toxoplasma gondii*, *Penicillium marneffeii*, *Candida glabrata*, *Leishmania donovani*, and *Cryptococcus neoformans* may appear similar to *H. capsulatum* on direct microscopy. However, most of the serologic tests are expensive and barely available in Uganda. In our case, the diagnosis was based on the histologic examination of the skin biopsy.

Our patient received amphotericin B and itraconazole for 2 weeks, which is the regimen of choice for the management of disseminated histoplasmosis where liposomal or lipid formulations of amphotericin are not available.^{5,15} The Infectious Diseases Society of America guidelines recommend that patients with disseminated histoplasmosis and HIV should be treated with amphotericin B (0.7-1 mg/kg per day) for 2 weeks followed by itraconazole for at least 12 months.¹⁵ Secondary prophylaxis with itraconazole maintenance therapy (200 mg/day) should be considered for extended periods of immunosuppression. Some literature data suggest withdrawing prophylaxis at CD4 > 150 cells/mm³.^{12,28} Upon discharge, this patient was started on fluconazole instead of itraconazole because of the cost of the treatment and the unavailability of free dispensing of itraconazole in Uganda. Although fluconazole has some activity against histoplasmosis, it is less efficacious than itraconazole, and has been associated with higher resistance rates.²⁹⁻³¹

Antiretroviral therapy substantially improves the outcomes of HIV-infected people with disseminated histoplasmosis. Additionally, there is evidence suggesting that patients on ART who develop

disseminated histoplasmosis IRIS should continue on the ART.³²⁻³⁴

Literature data recommend continuing prophylaxis until the clinical and the laboratory results normalize.²⁹ Our patient received fluconazole 400 mg daily and was monitored monthly in the outpatient clinic. We intend to taper the dose of fluconazole to 200 mg at the twelfth week and withdraw it when the CD4 count exceeds 150 cells/mm³ and, if available, a normal laboratory antigen assay is achieved. Although our patient is showing immunological improvement, there is a risk of relapse since he is receiving a less suitable drug. Additional studies are needed concerning the management and length of treatment of histoplasmosis with fluconazole to provide a second choice where itraconazole remains prohibitively expensive. We also recommend that clinicians should consider a diagnosis of cutaneous histoplasmosis in HIV-infected persons that present with Kaposi sarcoma-like lesions.

Note: The patient signed an informed consent authorizing the publication the pictures of his face.

ACKNOWLEDGEMENTS

The authors wish to thank Dr. Tugume Lillian and Dr. Odong Daniel for participating in patient care.

REFERENCES

1. Wheat LJ. Histoplasmosis: a review for clinicians from non-endemic areas. *Mycoses*. 2006;49(4):274-82. <http://dx.doi.org/10.1111/j.1439-0507.2006.01253.x>. PMID:16784440.
2. Cottle LE, Gkrania-Klotsas E, Williams HJ, et al. A multinational outbreak of histoplasmosis following a biology field trip in the Ugandan rainforest. *J Travel Med*. 2013;20(2):83-7. <http://dx.doi.org/10.1111/jtm.12012>. PMID:23464714.
3. Regional T, Unit R, Helier S. Caecal perforation in a renal transplant patient with disseminated histoplasmosis. 1988;41(9):992-5. PMID: 3056989.
4. Kurowski R, Ostapchuk M. Overview of histoplasmosis. *Am Fam Physician*. 2002;66(12):2247-52. PMID:12507161.
5. Kauffman CA. Histoplasmosis: a clinical and laboratory update. *Clin Microbiol Rev*. 2007;20(1):115-32. <http://dx.doi.org/10.1128/CMR.00027-06>. PMID:17223625.
6. Pervez MM, Cobb B, Matin N, Shahrin L, Ford ER, Pietroni M. Disseminated histoplasmosis in a patient with advanced HIV disease-lessons learnt from Bangladesh. *J Health Popul Nutr*. 2010;28(3):305-7. <http://dx.doi.org/10.3329/jhpn.v28i3.5561>. PMID:20635643.
7. Gutierrez ME, Canton A, Sosa N, Puga E, Talavera L. Disseminated histoplasmosis in patients with AIDS in Panama: a review of 104 cases. *Clin Infect Dis*. 2005;40(8):1199-202. <http://dx.doi.org/10.1086/428842>. PMID:15791523.
8. Wheat LJ, Chetchotisakd P, Williams B, Connolly P, Shutt K, Hajjeh R. Factors associated with severe manifestations of histoplasmosis in AIDS. *Clin Infect Dis*. 2000;30(6):877-81. <http://dx.doi.org/10.1086/313824>. PMID:10854363.
9. Lehloenya R, Meintjes G. Dermatologic manifestations of the immune reconstitution inflammatory syndrome. *Dermatol Clin*. 2006;24(4):549-70. <http://dx.doi.org/10.1016/j.det.2006.06.007>. PMID:17010783.
10. Amerson EH, Maurer TA. Immune reconstitution inflammatory syndrome and tropical dermatoses. *Dermatol Clin*. 2011;29(1):39-43. <http://dx.doi.org/10.1016/j.det.2010.09.007>. PMID:21095526.
11. Centers for Disease Control – CDC. Revision of the CDC surveillance case definition for acquired immunodeficiency syndrome. Council of State and Territorial Epidemiologists; AIDS Program, Center for Infectious Diseases. *MMWR Suppl*. 1987;36(1):1S-15S. PMID: 3039334.
12. Loulergue P, Bastides F, Baudouin V, et al. Literature review and case histories of *Histoplasma capsulatum* var. *duboisii* infections in HIV-infected patients. *Emerg Infect Dis*. 2007;13(11):1647-52. PMID:18217546.
13. Gugnani HC. Histoplasmosis in Africa: a review. *Indian J Chest Dis Allied Sci*. 2000;42(4):271-7. PMID:15597674.
14. Chaturvedi S, Frame P, Newman SL. Macrophages from human immunodeficiency virus-positive persons are defective in host defense against *Histoplasma capsulatum*. *J Infect Dis*. 1995;171(2):320-7. PMID: 7844367.
15. Wheat LJ, Freifeld AG, Kleiman MB, et al. Clinical practice guidelines for the management of patients with histoplasmosis: 2007 update by the Infectious Diseases Society of America. *Clin Infect Dis*. 2007;45(7):807-25. <http://dx.doi.org/10.1086/521259>. PMID:17806045.
16. Bradsher RW. Histoplasmosis and blastomycosis. *Clin Infect Dis*. 1996;22(Suppl 2):S102-11. PMID:8722836.
17. Kahi CJ, Wheat LJ, Allen SD, Sarosi GA. Gastrointestinal histoplasmosis. *Am J Gastroenterol*. 2005;100(1):220-31. <http://dx.doi.org/10.1111/j.1572-0241.2005.40823.x>. PMID:15654803.
18. Verma SB. Chronic disseminated cutaneous histoplasmosis in an immunocompetent individual - a case report. *Int J Dermatol*. 2006;45(5):573-6. <http://dx.doi.org/10.1111/j.1365-4632.2006.02762.x>. PMID:16700795.
19. Delfino E, di Biagio A, Chandrapatham K, Viscoli C, Prinapori R. Disseminated histoplasmosis with mucocutaneous immune reconstitution inflammatory syndrome in an HIV-infected patient. *AIDS Res Hum*

- Retroviruses. 2015;31(3):274-5. <http://dx.doi.org/10.1089/aid.2014.0329>. PMID:25723353.
20. Nacher M, Sarazin F, El Guedj M, et al. Increased incidence of disseminated histoplasmosis following highly active antiretroviral therapy initiation. *J Acquir Immune Defic Syndr*. 2006;41(4):468-70. <http://dx.doi.org/10.1097/01.qai.0000209927.49656.8d>. PMID:16652055.
 21. Passos L, Talhari C, Santos M, Ribeiro-Rodrigues R, Ferreira LC, Talnari S. Histoplasmosis-associated immune reconstitution inflammatory syndrome. *An Bras Dermatol*. 2011;86(4 Suppl 1):S168-72. <http://dx.doi.org/10.1590/S0365-05962011000700044>. PMID:22068802.
 22. Breton G, Adle-Biassette H, Therby A, et al. Immune reconstitution inflammatory syndrome in HIV-infected patients with disseminated histoplasmosis. *AIDS*. 2006;20(1):119-21. <http://dx.doi.org/10.1097/01.aids.0000199014.66139.39>. PMID:16327328.
 23. Haddow LJ, Easterbrook PJ, Mosam A, et al. Defining immune reconstitution inflammatory syndrome: evaluation of expert opinion versus 2 case definitions in a South African cohort. *Clin Infect Dis*. 2009;49(9):1424-32. <http://dx.doi.org/10.1086/630208>. PMID:19788360.
 24. Robertson J, Meier M, Wall J, Ying J, Fichtenbaum CJ. Immune reconstitution syndrome in HIV: validating a case definition and identifying clinical predictors in persons initiating antiretroviral therapy. *Clin Infect Dis*. 2006;42(11):1639-46. <http://dx.doi.org/10.1086/503903>. PMID:16652323.
 25. Gómez BL, Figueroa JI, Hamilton AJ, et al. Detection of the 70-kilodalton *Histoplasma capsulatum* antigen in serum of histoplasmosis patients: correlation between antigenemia and therapy during follow-up. *J Clin Microbiol*. 1999;37(3):675-80. PMID:9986830.
 26. Durkin MM, Connolly PA, Wheat LJ. Comparison of radioimmunoassay and enzyme-linked immunoassay methods for detection of *Histoplasma capsulatum* var. *capsulatum* Antigen. *J Clin Microbiol*. 1997;35(9):2252-5. PMID:9276396.
 27. Gomez BL, Figueroa JI, Hamilton AJ, et al. Development of a novel antigen detection test for histoplasmosis. *J Clin Microbiol*. 1997;35(10):2618-22. PMID:9316918.
 28. Murata M, Furusyo N, Otaguro S, Nabeshima S, Ariyama I, Hayashi J. HIV infection with concomitant cerebral toxoplasmosis and disseminated histoplasmosis in a 45-year-old man. *J Infect Chemother*. 2007;13(1):51-5. <http://dx.doi.org/10.1007/s10156-006-0486-3>. PMID:17334730.
 29. Wheat J, Hafner R, Korzun AH, et al. Itraconazole treatment of disseminated histoplasmosis in patients with the acquired immunodeficiency syndrome. *Am J Med*. 1995;98(4):336-42. [http://dx.doi.org/10.1016/S0002-9343\(99\)80311-8](http://dx.doi.org/10.1016/S0002-9343(99)80311-8). PMID:7709945.
 30. Wheat LJ, Connolly P, Smedema M, Brizendine E, Hafner R. Emergence of resistance to fluconazole as a cause of failure during treatment of histoplasmosis in patients with acquired immunodeficiency disease syndrome. *Clin Infect Dis*. 2001;33(11):1910-3. <http://dx.doi.org/10.1086/323781>. PMID:11692303.
 31. Wheat J, Marichal P, Vanden Bossche H, Le Monte A, Connolly P. Hypothesis on the mechanism of resistance to fluconazole in *Histoplasma capsulatum*. *Antimicrob Agents Chemother*. 1997;41(2):410-4. PMID:9021199.
 32. Goldman M, Zackin R, Fichtenbaum CJ, et al. Safety of discontinuation of maintenance therapy for disseminated histoplasmosis after immunologic response to antiretroviral therapy. *Clin Infect Dis*. 2004;38(10):1485-9. <http://dx.doi.org/10.1086/420749>. PMID:15156489.
 33. Agudelo CA, Rosero DS, Ochoa JE, et al. Disseminated Histoplasmosis: a comparative study between patients with acquired immunodeficiency syndrome and non-human immunodeficiency virus – infected individuals. *Am Soc Trop Med Hyg*. 2005;73(3):576-82. PMID:16172484.
 34. Jenny-Avital E. Successful discontinuation of high-dose fluconazole for *Histoplasma capsulatum* meningitis in an AIDS Patient after sustained immune reconstitution. *J Chem Inf Model*. 2004;39(8):1261-2. <http://dx.doi.org/10.1086/424753>. PMID: 15486865.

Conflict of interest: None

Submitted on: July 7th, 2016

Accepted on: September 9th, 2016

Correspondence

Reuben Kiggundu

College of Health Sciences - Infectious Disease Institute - Mulago Hospital Complex - Makerere University

P.O. Box 22418 – Kampala – Uganda

reubenkaaja@yahoo.com