

Amniotic membrane transplant in acute ocular surface burns in Western India: A tertiary eye care center study

Dipali P Parmar, Pradnya K Bhole, Parita N Patel¹, Jagruti N Jadeja

Purpose: To evaluate the outcomes of early amniotic membrane transplant (AMT) in acute ocular surface burns using Dua's classification. **Methods:** In this retrospective analysis conducted at a tertiary eye care center in Western India. We included 27 eyes of 24 patients from May 2014 to May 2019 who underwent AMT within 2 weeks post insult along with medical treatment for acute ocular surface burns using Dua's classification for grading on presentation. Post-operative assessment for ocular surface epithelization, corneal vascularization, symblepharon formation, and visual outcome at the time of complete epithelization was done. **Results:** Eight, seven, three, and nine eyes with grade III, IV, V, and VI, respectively, were included in the study. The mean duration of the presentation was 5.5 ± 3.6 days, with the mean follow-up of 4.83 ± 2.2 months. Alkali burn (62.96%, 17/27 eyes) was the commonest. The mean epithelization time was 5.80 ± 2.92 weeks. Corneal vascularization for >6 clock hours was seen in 52.38% (11/21 eyes with vascularization). Symblepharon was seen in 55.55% (15/27 eyes). Vision improvement and corneal vascularization to a lesser extent (<6 clock hours) was observed in Group A (grades III and IV) as compared to group B (grades V and VI) and found to be significant (P -value = 0.031, P value = 0.007, respectively). **Conclusion:** Amniotic membrane grafting is a useful aid in moderate grades of acute ocular surface burns with an important adjunct role in severe cases.

Key words: Amniotic membrane transplant, ocular surface burns, ocular surface epithelization

Ocular surface burns are one of the true ophthalmic emergencies, where delay in treatment results in structural and functional loss of the eye. While adults are prone to occupational or household chemical or thermal burns, paediatric age group is at risk of corneal blindness while playing with lime packets or firecrackers.^[1] Acid injuries have been considered less destructive compared to alkali burns, however, strong acids like hydrochloric, nitric, and sulfuric acids can be as dangerous as alkali injuries.^[2] Although lime has poor penetration, it may cause a prolonged and severe damage as a retained particulate matter.^[3] On the other hand, thermal burns may cause severe ocular damage due to high temperature and severe inflammation especially if associated with superimposed infection.^[4] Irrespective of the nature of ocular surface burns, the aim of management in the acute phase includes removing the offending agent if any, promoting ocular surface epithelization, controlling the inflammation and intra ocular pressure (IOP), support of reparative process by avoiding further epithelial and stromal breakdown, preventing infection, and other complications.^[5] Since its first use in ophthalmic surgery by De Roth, Amniotic membrane (AM) is used for a variety of ocular surface conditions requiring either ocular surface healing or reconstruction, as in acute and chronic stages of ocular surface burns.^[6-9]

Restoration of vision after ocular surface burns is possible with the restoration of ocular surface later in stages with newer simple procedures like simple limbal stem cell transplant if one can achieve eye integrity with less or no ocular surface co-morbidities.^[10] Primary and intensive management or a timely referral in the acute phase to maintain eye integrity and reduce ocular surface co-morbidities needs to be reemphasized among the ophthalmic community. Hence, this study aims to evaluate the outcomes of early intervention with amniotic membrane transplantation (AMT) in acute ocular surface burns using Dua's classification at a tertiary eye care center in Western India.

Methods

A retrospective analysis of case records was performed for 27 eyes of 24 patients who underwent AMT at a tertiary eye care center in the west zone of India for acute ocular surface burns between May 2014 and May 2019. The study was conducted with the permission of institutional ethical committee and followed the principles of the Declaration of Helsinki.

This is an open access journal, and articles are distributed under the terms of the Creative Commons Attribution-NonCommercial-ShareAlike 4.0 License, which allows others to remix, tweak, and build upon the work non-commercially, as long as appropriate credit is given and the new creations are licensed under the identical terms.

For reprints contact: WKHLRPMedknow_reprints@wolterskluwer.com

Cite this article as: Parmar DP, Bhole PK, Patel PN, Jadeja JN. Amniotic membrane transplant in acute ocular surface burns in Western India: A tertiary eye care center study. Indian J Ophthalmol 2021;69:58-64.

Access this article online

Website:

www.ijo.in

DOI:

10.4103/ijo.IJO_2252_19

Quick Response Code:



Cornea Department, M and J Institute of Ophthalmology (Government Eye Hospital), B.J. Medical College, ¹PSM Department, GMERS Medical College, Sola, Ahmedabad, Gujarat, India

Correspondence to: Dr. Dipali P Parmar, M and J Institute of Ophthalmology (Government Eye Hospital), B.J. Medical College, Ahmedabad, Gujarat, India. E-mail: dipaliparmar@gmail.com

Received: 06-Dec-2019

Revision: 26-Mar-2020

Accepted: 07-Jun-2020

Published: 15-Dec-2020

Inclusion Criteria: Cases of acute ocular surface burns who underwent AMT within 2 weeks of injury with grades III and onwards on presentation, according to Dua's classification, along with medical management with follow-up period till complete ocular surface epithelization.

Exclusion Criteria: The cases of ocular surface burns with primary AMT were performed after 2 weeks of insult.

Data were analysed from the available records for age, gender, time of presentation to the study centre since injury, type of injury (accidental/assault), nature of injury (acid/alkali/thermal), site of injury (occupational/household), laterality, primary consultation and treatment taken if any. Other factors considered were interventions done at the study centre, visual acuity and clinical findings (corneal findings: presence of particulate agent, e.g., lime, epithelial defect, haze, melting, infection; conjunctival findings: presence of particulate agent, e.g., lime, epithelial defect area, blanching, subconjunctival haemorrhage, necrosis, symblepharon, etc.).

Treatment strategy: Thorough irrigation with normal saline or balanced salt solution (BSS) and removal of the particulate matter if any under local anaesthesia on presentation was performed in cases presenting in immediate phase. All cases were assessed for visual acuity, slit lamp/microscopic examination, intraocular pressure (IOP) measurement with digital/non-contact method if possible, and posterior segment assessment if indicated. Estimation of injury and grading was done as per Dua's classification.^[11] Cryopreserved Wet human AMT was performed with informed and written consent within 2 weeks post insult, under local or general anaesthesia with fibrin glue and/or anchoring sutures (10-nylon, 8-0 vicryl) in all cases. Debridement of retained chemical agent and necrotic tissue, tenonplasty, and tarsorrhaphy was performed as and when indicated along with the primary AMT.^[12] AM with the epithelial side up covered the corneal, limbal, and involved bulbar surface with fornices and tarsal surface as exposed on eversion and as required on table after debridement [Fig. 1]. Multiple layers of AM were used when AMT was performed with tenonplasty and for persistent epithelial defect (PED).^[13] All the patients received topical and systemic medication pre- and post AMTs as per the indications in the individual case.

Medications used were topical antibiotic eye drops (four times/day) and antibiotic eye ointments (once at night), artificial tear substitutes (hourly basis), topical steroid preparations (four times/day to hourly frequency as per inflammation severity and duration of presentation), Vitamin C eye drops preparations (hourly basis), Cycloplegic eye drops, and IOP-lowering agents if indicated as per the recommended frequency. Systemic doxycycline (if not C/I), analgesic/anti-inflammatory medications, and Vitamin C supplementation as per the age and weight of the patient were added to the treatment.^[2,3] The follow-up schedule was on the first post-operative day and as per requirement in individual case thereafter. Post-operatively steroid was used for 4-6 times a day and tapered as per the response over 4-6 weeks. The early post-operative assessment was done for (1) Symptomatic improvement (ocular pain, watering, and photophobia) and (2) Epithelization of cornea and conjunctiva [Fig. 1].

Symptomatic improvement was noted as subjective decrease of severity grade for the mild, moderate, and severe categories. Complete epithelization of ocular surface was considered as maintenance of intact epithelization without recurrence of defect in subsequent follow-up period with or without ocular surface scarring and/or vascularization.

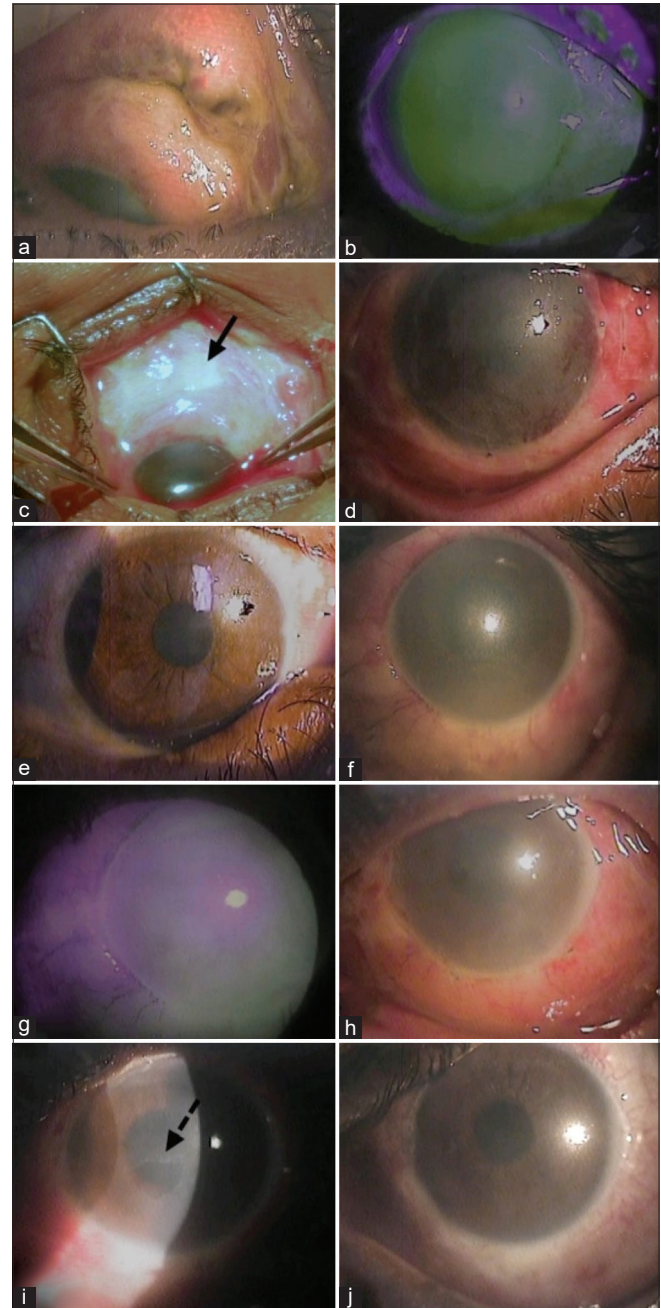


Figure 1: Assessment and management of ocular surface burns. Case 1. Dua's grade IV Lime burns (a-e) examination with upper lid eversion (a), fluorescein stain (b), debridement of necrotic tissue and removal of retained lime (black arrow) from superior fornix (c), AM with anchoring sutures on post-op day 1 (d), complete epithelization 3 weeks post-operatively (e). Case 2. Dua's grade VI Caustic burns (f-j). examination with fluorescein stain (f and g), AM with anchoring sutures on post-op day 1 (h), healing corneal epithelial defect (broken arrow) and complete epithelization 3 weeks post-operatively (i and j)

Additional surgical procedures performed were tectonic corneal transplant, tenoplasty and tarsorrhaphy primarily with first AMT procedure or later during follow-up other than repeat AM anchoring to ocular surface as and when indicated.^[14] Late outcomes were measured for corneal vascularization (clock hours) and symblepharon development (graded as mild, moderate, and severe for horizontal fornices and vertical bulbar involvement, higher grade considered in case of difference in grading for both for convenience).^[15] Visual acuity of more than two lines from the presentation on the Snellen chart was considered as improvement on complete epithelization. Each outcome was measured for the age groups (≤ 14 years of age as paediatric and >14 years of age as adult), each type of agents (acid, alkali, and thermal), each grade of Injury (grades III, IV, V, and VI as per Dua's classification), time of AMT performed (in ≤ 7 days and in $>7-14$ days post insult), for group A with moderate grades (grades III and IV) versus group B with severe grades (grades V and VI). The data were entered in the MS EXCEL spreadsheet and analysis was done using Statistical Package for Social Sciences (SPSS) version 21.0. A *P* value of <0.05 was considered statistically significant.

Results

The study included total 27 eyes of 24 patients. Five patients had bilateral accidental ocular burns out of which two eyes were of Grade I injury hence excluded from the study. The demographic and preoperative clinical data are given in Table 1.

The mean age of the patients was 19.85 ± 15 years (range: 1.5-60 years). The mean duration of the presentation was 5.5 ± 3.6 days (range: 1-12 days) post-insult, and the mean follow-up was 4.83 ± 2.2 months (range 2-9 months). The mean duration of the presentation was more in referred cases (6.21 ± 3.69 days) compared to the cases primarily presenting to the study centre itself (2.8 ± 1.3 days) (*P*-value = 0.057, not significant).

Eyes involved for grade III, IV, V, and VI and type of agents are as per Fig. 2.

Out of the 27 eyes, 15 eyes (55.55%) were involved in group A (moderate grades: III and IV) and 12 (44.44%) eyes were involved in group B (severe grades: V and VI).

The time of AMT performed after injury ranged from 2 to 14 days (average: 6.83 ± 4.2 days). Three patients required AM patch over the upper tarsal conjunctival surface in addition to bulbar conjunctiva and cornea. Primary AMT was combined with tenoplasty for limbal ischemia in five eyes including two tectonic keratoplasties for large corneal melting and thinning (one full thickness for the eye with grade VI alkali injury and one lamellar for eye with grade IV acid injury). Repeat AMT with tectonic corneal transplant (three lamellar and one full thickness) was needed in four eyes (three eyes with grade VI alkali injury and one eye with grade VI thermal injury). The mean time for keratoplasty was 5.75 ± 3.40 weeks post primary AMT. Tenoplasty was performed in three eyes (two eyes with grade VI alkali injury, one grade III thermal injury) [Table 2].

Repeat AMT for PED was needed in two eyes: one with grade VI and one with grade III injuries, both due to alkali

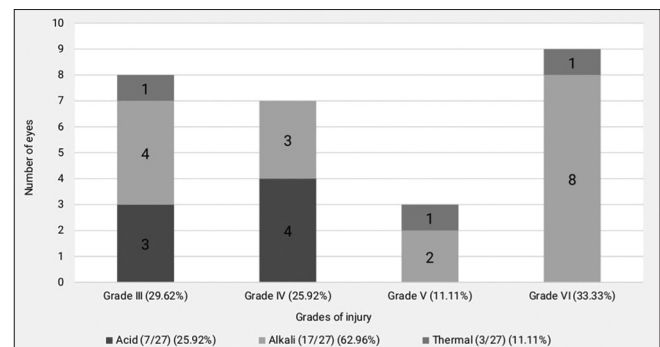


Figure 2: The number of eyes for grades of injury with the type of causative agents

Table 1: Demographic and pre-operative details

| Patient details | | No. of patients (%) | Total No. of patients |
|-----------------|-------------------------------------|---------------------|-----------------------|
| Age | ≤ 14 years | 13 (54.16%) | 24 |
| | >14 years | 11 (45.83%) | |
| Gender | Male | 17 (70.83%) | 24 |
| | Female | 7 (29.16%) | |
| Laterality | Unilateral | 19 (79.16%) | 24 |
| | Bilateral | 5 (20.83%) | |
| Location | Work | 7 (29.16%) | 24 |
| | Home/nearby | 17 (70.83%) | |
| Visit | Primary | 5 (20.83%) | 24 |
| | Referral | 19 (79.16%) | |
| Agents | Acid | 6 (25.00%) | 24 |
| | 4-factory work, 3-bathroom cleaner | | |
| | Alkali | 15 (62.50%) | |
| | 12-lime, 4-drain cleaner, 1-caustic | | |
| | Thermal | 3 (12.50%) | |
| | 2-hot metal, 1-firework | | |

burns. Eight eyes had AMT for two times and one eye had AMT for three times. Suture granuloma occurred in one eye of grade VI alkali injury after 1 month of AMT for which suture removal with granuloma excision was done.

On follow-up, by the first week, all the patients had subjective improvement in symptoms, pain being decreased in severity the most followed by photophobia and watering.

Mean epithelization time for each grade of injury, type of agents, time of AMT performed, and age group is listed in Table 3. Mean epithelization time for primary and referred cases were 5.6 ± 3.65 and 5.85 ± 2.83 days, respectively (P -value = 0.870, not significant)

Out of 11 eyes with corneal vascularization of >6 to 12 limbal clock hours, 72.72% (8/11 eyes) had alkali burns and 54.54% (6/11 eyes) had grade VI injuries. Association of corneal vascularization with grades of injury was found to be statistically significant (P -value = 0.009) but no significant association was noted with the type of agent (P = 0.228) [Table 4].

Table 2: Additional procedures performed with AMT

| Intervention | Along with primary AMT eyes | Secondary AMT eyes |
|-----------------------------|-----------------------------|--------------------|
| Debridement | 17 | |
| Tenonplasty | 5 | 3 |
| Tarsorrhaphy | 3 | 3 |
| Tectonic corneal transplant | 2 | 4 |
| Symblepharon lysis | | 1 |

Table 3: Epithelization time for grades of injury, type of injury, time of AMT, and age group

| Average Epithelization time in weeks: 5.80 ± 2.92 (range 2-12 weeks)* | | | |
|---|-----------------------|---------------------|-----------------------|
| Grades of injury | Types of agents | Time of AMT in days | Age in years |
| III: 4.75 ± 3.11 | Acid: 4.86 ± 1.34 | 0- ≤ 7 days: | ≤ 14: 5.35 ± 2.59 |
| IV: 5 ± 1.41 | Alkali : 6 ± 3.2 | 6.11 ± 3.35 | >14: 6.33 ± 3.31 |
| V: 4.67 ± 1.53 | Thermal: 7 ± 4.3 | >7-14 days: | |
| VI: 8.00 ± 3.25 | | 5.22 ± 1.92 | |
| $P=0.079$ | $P=0.540$ | $P=0.469$ | $P=0.407$ |

*one eye of grade VI alkali injury went into phthisis, not considered in the calculation for epithelization

Table 4: Corneal vascularization for grades of injury, type of injury, time of AMT, and age group

| Corneal vascularization in clock hours: 1- ≤ 6:10 eyes, >6-12:11 eyes, Total: 21/26* (80.76%) | | | |
|---|---|---|--------------------------------------|
| Grades of injury (affected eyes/total) % | Types of agents (affected eyes/total) % | Time of AMT in days (affected eyes/total) % | Age in years (affected eyes/total) % |
| III: 6/8 (75%) | Acid: 6/7 (85.71%) | ≤ 7 days: 14/17 (82.35%) | ≤ 14: 12/14 (85.71%) |
| IV: 6/7 (85.71%) | Alkali: 12/16* (75%) | >7-14 days: 7/9* (77.77%) | >14 : 9/12* (75%) |
| V: 2/3 (66.66%) | Thermal: 3/3 (100%) | | |
| VI: 7/8* (87.50%) | | | |
| $P=0.009$ | $P=0.228$ | $P=0.454$ | $P=0.635$ |

*One eye of grade VI alkali injury went into phthisis, not considered in calculation for corneal vascularization

Results of symblepharon for grades of injury, type of injury, time of AMT, and age group are listed in Table 5.

Nine eyes (six eyes out of nine of grade III) had the best-corrected visual acuity 6/12 or better on the Snellen chart while nine eyes (five eyes of grade VI) had visual acuity of less than CF 1 ft. More cases of improvement in lower grades were statistically significant (P -value = 0.041) [Table 6].

Outcomes of eyes with keratoplasty performed: Among the two eyes with Penetrating keratoplasty (PK) performed to salvage the eyes, the eye with the primary AMT and PK failed to achieve integrity leading to severe symblepharon with phthisis over 12 weeks. It was excluded from calculation of epithelization time and corneal vascularization. Other case in which PK was performed with repeat AMT developed vascularized opaque graft over 8 weeks with moderate symblepharon and visual acuity of perception of light with inaccurate projection of light rays. (Both cases had bilateral alkali injury with severely affected eyes of grade VI with total limbal ischemia and hypotony). Cases with lamellar transplant for corneal melting and thinning achieved and maintained integrity in all four cases till last follow-up (average 6.75 ± 2.21 months, range 4-9 months). Mild, moderate, and absent symblepharon was observed in two, one, and one eye, respectively. Visual acuity of hand movement perception in three cases and 6/36 (corrected) in one case was observed with graft vascularization and variable opacity.

Mean epithelization time in group A (grades III and IV) and in group B (grades V and VI) for referred cases was 4.54 ± 1.51 weeks (11/15 eyes) and 7.30 ± 3.31 weeks (10/12 eyes), respectively (P -value = 0.022, significant). Other results of outcomes for groups A and B are listed in Table 7.

Discussion

Amniotic membrane is very popular either as a patch or a graft or a combination of both in ocular surface burns with an important role in promoting epithelization, normal phenotype maintenance, and decreasing inflammation vascularization and scarring and as an excellent substrate for expanding epithelial stem cells ex vivo.^[9,16]

Visual, tectonic, and cosmetic outcomes of acute ocular surface burns are guarded depending on the nature of the causative agent and the extent of ocular surface damage at the time of injury. The cases considered for analysis in the present study were of grade III onwards as per Dua’s classification, as suggested in the study by Dua *et al.* that corneal stromal

Table 5: Symblepharon for grades of injury, type of injury, time of AMT, and age group

| Symblepharon: Mild (10), Moderate (4), Severe (1): (total) % 15/27 (55.55%) | | | |
|---|---|---|--------------------------------------|
| Grades of injury (affected eyes/total) % | Types of agents (affected eyes/total) % | Time of AMT in days (affected eyes/total) % | Age in years (affected eyes/total) % |
| III: 4/8 (50%) | Acid: 2/7 (28.57%) | ≤ 7 days: 8/17 (47.05%) | ≤ 14: 9/14 (64.28%) |
| IV: 3/7 (42.85%) | Alkali: 11/17 (64.70%) | >7-14 days: 7/10 (70%) | >14: 6/13 (46.15%) |
| V: 2/3 (66.66%) | Thermal: 2/3 (66.66%) | | |
| VI: 6/9 (66.66%) | | | |
| P=0.201 | P=0.651 | P=0.332 | P=0.151 |

Table 6: Visual acuity Improvement for grades of injury, type of injury, time of AMT, and age group

| Visual acuity Improvement (improved eyes/total) %: 18/27 (66.66%) | | | |
|---|---|---|--------------------------------------|
| Grades of injury (improved eyes/total) % | Types of agents (improved eyes/total) % | Time of AMT in days (improved eyes/total) % | Age in years (improved eyes/total) % |
| III: 8/8 (100%) | Acid: 6/7 (85.71%) | ≤ 7 days: 14/17 (82.35%) | ≤ 14: 8/14 (57.14%) |
| IV: 5/7 (71.42%) | Alkali: 11/17 (64.70%) | >7-14 days: 4/10 (40%) | >14: 10/13 (76.92%) |
| V: 1/3 (33.33%) | Thermal: 1/3 (33.33%) | | |
| VI: 4/9 (44.44%) | | | |
| P=0.041 | P=0.495 | P=0.197 | P=0.203 |

Table 7: Results of different outcomes for moderate group A and severe group B

| Outcomes | Moderate group A (15/27 eyes , 55.55%) | Severe group B (12/27 eyes , 44.44%) |
|--------------------------------------|---|--|
| Mean epithelization time P=0.053 | Group A: grade III, grade IV 15/15 eyes 4.86±2.38 weeks | Group B: grade V, grade VI 11/12* eyes 7.09±3.20 weeks |
| Corneal vascularization P=0.007 | Group A: grade III, grade IV 12/15 eyes (80%) | Group B: grade V, grade VI 9/11* eyes (81.81%) |
| 1-≤ 6 clock :10/21 (47.61%) | 9/12 (75%) | 1/9 (11.11%) |
| >6-12 clock :11/21 (52.38%) | 3/12 (25%) | 8/9 (88.88%) |
| Symblepharon P=0.053 | Group A: grade III, grade IV 7/15 eyes (46.66%) | Group B: grade V, grade VI 8/12 eyes (66.66%) |
| Mild | 7/7 (100%) | 3/8 (37.5%) |
| Moderate | 0/7 (0.0%) | 4/8 (50%) |
| Severe | 0/7 (0.0%) | 1/8 (12.5%) |
| Visual acuity Improvement P=0.031 | Group A: grade III, grade IV (15/15 eyes) | Group B: grade V, grade VI (12/12 eyes) |
| Improved | 13/15 (86.66%) | 5/12 (41.66%) |
| Not improved/same | 2/15 (13.33%) | 4/12 (33.33%) |
| Worsened | 0/15 (0.0%) | 3/12 (25%) |

*One phthisical eye excluded

surface is more vulnerable for damage from grade III onwards, requiring amniotic membrane transplantation to encourage re-epithelialization of the cornea.^[11]

In the present study, lime (70.58%) was the commonest agent among alkalis comparable to 66.66% cases in another study.^[17] The paediatric patients of age <14 years were affected more with lime (75% lime injury) in this study compared to (65.6% lime injury, <16 years of age) in the study by Vajpayee *et al.*^[1]

The researchers in a study reported overall success rate with AMT more in acute (87.5%) group (<1 month of injury)

than chronic group (73%) (>1 month) for outcome measures like ocular surface reconstruction, healing of epithelial defect, improving limbal stem cell function and symptomatic relief.^[18] A comparative study reported faster epithelial healing in a group where AM patching was performed within 5 days, compared to the group where patching was performed after 5 days, and the control group.^[19]

Meller *et al.* in their study with 13 eyes found epithelialization time within 2-5 weeks, which is comparable to 5.80 ± 2.92 weeks in the present study.^[20] The average epithelial defect healing time was high with higher grade with a persistent epithelial defect, symblepharon lysis, and premature detached amniotic

membrane as indications for the repeat AMT similar to another study reported from the west zone.^[21]

In a prospective study where AMT was performed within 3 weeks of injury in 15 consecutive eyes, symblepharon and superficial corneal vascularization were reported in 60% and 80% eyes compared to 55.55% and 80.76%, respectively, in the present study.^[17] Improvement in visual acuity was seen in 66.66% eyes in their study, which is similar to the present study and better compared to the visual improvement seen in 40.3% cases at a final visit in another study with 72 eyes of 54 patients.^[22]

Both success and failures with AMT have been reported by various studies for severe ocular surface burns.^[23-25] In a study, the high success rate of 62.5% was observed with AMT in the group without stem cell loss compared to 22% in the group with presence of stem cell loss apart from the need for more procedures in acute and sub-acute cases (<3 months) compared with chronic cases.^[26]

The present study does not compare the results with medical therapy alone for improvement in visual acuity, reduction of corneal vascularization, and symblepharon appearance. However, significant visual improvement and corneal vascularization to a lesser extent (<6 clock hours) noted in group A (grades III and IV) is encouraging to perform AMT in an early phase of the acute stage.^[27-30]

Different delivery techniques like AM extracts, Pro-Kera, and modified ocular surface ring (MOSR) for AMT in ocular surface burns have been studied, but their widespread use is limited due to varied extent of ocular surface burns in the early phase, affordability and availability of AM device or AM itself for repeated need in acute phase especially in the Indian scenario.^[31-33]

Most of the studies performed to evaluate the role of AMT in acute ocular surface burns used Roper-hall classification for grading the severity of injury.^[17,19-21,24,27,29] The authors routinely use, and hence, considered Dua's classification in the present study as the examination of a stained ocular epithelial surface is clinically easier to evaluate in acute ocular surface burns on presentation. Also, Limbal staining, rather than limbal ischemia is more evident for interpretation as it is often masked in the early phase of the acute stage due to chemosis and particulate matter (e.g., lime chunks near or at the limbus).^[11] This could have been the reason for variation in results for different outcomes with AMT, apart from the variation in different etiological agents for each grade of a different classification. The present study does not compare other classification systems; however, this is the only study in the authors' knowledge currently from the west zone of India where results of early surgical intervention with AMT in acute ocular surface burns are studied using Dua's classification for grading.^[21,30] It has a limitation of retrospective mode with a short follow-up period and a limited sample size. Also, Dua's grading system does not consider corneal epithelial defect size and clinically larger corneal defect with lesser limbal staining may exist as seen with overlapping of Dua's grade with a mismatch of limbal and conjunctival staining and thus making it vulnerable to direct damage by retained chemical itself or infective organisms. Hence, it is suggested to evaluate the adequate epithelization process, signs of ischemia, and infection in the

acute phase for timely intervention. Long-term follow-up for correlation of final outcome measures is required as eyes with ocular surface burns may have potential for visual and cosmetic improvement later in the chronic stage.

Conclusion

To conclude, moderate grades of burns (grades III and IV) can be benefited from AMT in the early phase for a faster recovery in adjunct to medical therapy. AMT alone has a limited role in the presence of extensive limbal ischemia as in severe grades (grades V and VI); however, the usefulness of AM with other surgical procedures like tenonplasty, limbal stem cell transplant, or tectonic transplant is justified to serve the ultimate purpose of maintaining the eye integrity for future visual rehabilitation.

Financial support and sponsorship

Nil.

Conflicts of interest

There are no conflicts of interest.

References

- Vajpayee RB, Shekhar H, Sharma N, Jhanji V. Demographic and clinical profile of ocular chemical injuries in the paediatric age group. *Ophthalmology* 2014;121:377-80.
- Pfister DA, Pfister RR. Acid injuries of the eye (Chapter 98). In: *Cornea*. Krachmer JH, Mannis MJ, Holland EJ editors. 3rd ed. 2011. p. 1187-92.
- Pfister RR, Pfister DR. Alkali injuries of the eye (Chapter 99). In: *Cornea*. Krachmer JH, Mannis MJ, Holland EJ. 3rd ed. 2011. p. 1193-1202.
- Arici C, Iskeleli G, Atalay E, Mangan MS, Kilic B. Molten metal-related ocular thermal burn: Report on two cases. *Arq Bras Oftalmol* 2015;78:379-81.
- Eslani M, Baradaran-Rafii A, Movahedan A, Djalilian AR. The ocular surface chemical burns. *J Ophthalmol* 2014;2014:196827.
- De Röth A. Plastic repair of conjunctival defects with fetal membranes. *Arch Ophthalmol* 1940;23:522-5.
- Dua HS, Azuara-Blanco A. Amniotic membrane transplantation. *Br J Ophthalmol* 1999;83:748-52.
- Sinha R, Tinwala SI, Shekhar H, Titiyal JS. Amniotic membrane transplantation in ocular surface disorders: A review. *J Clin Ophthalmol Res* 2013;1:64-9.
- Sangwan VS, Burman S, Tejwani S, Mahesh SP, Murthy R. Amniotic membrane transplantation: A review of current indications in the management of ophthalmic disorders. *Indian J Ophthalmol* 2007;55:251-60.
- Basu S, Sureka SP, Shanbhag SS, Kethiri AR, Singh V, Sangwan VS. Simple limbal epithelial transplantation: Long-term clinical outcomes in 125 Cases of unilateral chronic ocular surface burns. *Ophthalmology* 2016;123:1000-10.
- Dua HS, King AJ, Joseph A. Perspective. A new classification of ocular surface burns. *Br J Ophthalmol* 2001;85:1379-83.
- Kuckelkorn R, Schrage N, Keller G, Redbrake C. Emergency treatment of chemical and thermal eye burns. *Acta Ophthalmol Scand* 2002;80:4-10.
- Letko E, Stechschulte SU, Kenyon KR, Sadeq N, Romero TR, Samson CM, *et al.* Amniotic membrane inlay and overlay grafting for corneal epithelial defects and stromal ulcers. *Arch Ophthalmol* 2001;119:659-63.
- Baradaran-Rafii A, Eslani M, Haq Z, Shirzadeh E, Huvard MJ,

- Djalilian AR. Current and upcoming therapies for ocular surface chemical injuries. *Ocul Surf* 2016;15:48-64.
15. Tseng SCG, Blanco G. Cryopreserved amnion grafts for fornix reconstruction. The ocular surface research & education foundation: Vol 1, Number 6. Available from: http://www.osref.org/media/documents/osref_fornix_reconstruction_surgical_guide.pdf. [last accessed on 2019 Oct 16].
 16. Liu J, Sheha H, Fu Y, Liang L, Tseng SC. Update on amniotic membrane transplantation. *Expert Rev Ophthalmol* 2010;5:645-61.
 17. Arora R, Mehta D, Jain V. Amniotic membrane transplantation in acute chemical burns. *Eye (Lond)* 2005;19:273-8.
 18. Tejwani S, Kolari RS, Sangwan VS, Rao GN. Role of amniotic membrane graft for ocular chemical and thermal injuries. *Cornea* 2007;26:21-6.
 19. Prabhasawat P, Tesavibul N, Prakairungthong N, Booranapong W. Efficacy of amniotic membrane patching for acute chemical and thermal ocular burns. *J Med Assoc Thai* 2007;90:319-26.
 20. Daniel M, Pires RT, Mack RJ, Figueiredo F, Heiligenhaus A, Park WC, *et al.* Amniotic membrane transplantation for acute chemical or thermal burns. *Ophthalmology* 2000;107:980-9.
 21. Patil M, Ambarkar L. Study of amniotic membrane transplantation in the treatment of ocular injuries. *Int J Biomed Adv Res* 2015;6:656-9.
 22. Westekemper H, Figueiredo FC, Siah WF, Wagner N, Steuhl KP, Meller D. Clinical outcomes of amniotic membrane transplantation in the management of acute ocular chemical injury. *Br J Ophthalmol* 2017;101:103-7.
 23. Sridhar MS, Bansal AK, Sangwan VS, Rao GN. Amniotic membrane transplantation in acute chemical & thermal injury. *Am J Ophthalmol* 2000;130:134-7.
 24. Joseph A, Dua HS, King AJ. Failure of amniotic membrane transplantation in the treatment of acute ocular burns. *Br J Ophthalmol* 2001;85:1065-9.
 25. Azuara-Blanco A, Pillai CT, Dua HS. Amniotic membrane transplantation for ocular surface reconstruction. *Br J Ophthalmol* 1999;83:399-402.
 26. Maharajan VS, Shanmuganathan V, Currie A, Hopkinson A, Powell-Richards A, Dua HS. Amniotic membrane transplantation for ocular surface reconstruction: Indications and outcomes. *Clin Exp Ophthalmol* 2007;35:140-7.
 27. Tamhane A, Vajpayee RB, Biswas NR, Pandey RM, Sharma N, Titiyal JS. *et al.* Evaluation of amniotic membrane transplantation as an adjunct to medical therapy as compared with medical therapy alone in acute ocular burns. *Ophthalmology* 2005;112:1963-9.
 28. Tandon R, Gupta N, Kalaivani M, Sharma N, Titiyal JS, Vajpayee RB. Amniotic membrane transplantation as an adjunct to medical therapy in acute ocular burns. *Br J Ophthalmol* 2011;95:199-204.
 29. Eslani M, Baradaran-Rafii A, Cheung AY, Kurji KH, Hasani H, Djalilian AR, *et al.* Amniotic membrane transplantation in acute severe ocular chemical injury: A randomized clinical trial. *Am J Ophthalmol* 2019;199:209-15.
 30. Gupta N, Kalaivani M, Tandon R. Comparison of prognostic value of Roper Hall and Dua classification systems in acute ocular burns. *Br J Ophthalmol* 2011;95:194-8.
 31. Liang L, Li W, Ling S, Sheha H, Qiu W, Li C, *et al.* Amniotic membrane extraction solution for ocular chemical burns. *Clin Exp Ophthalmol* 2009;37:855-63.
 32. Suri K, Kosker M, Raber IM, Hammersmith KM, Nagra PK, Ayres BD. *et al.* Suture less amniotic membrane ProKera for ocular surface disorders: Short-term results. *Eye Contact Lens* 2013;39:341-7.
 33. Kara N. Suture less amniotic membrane transplantation with a modified ocular surface ring. *Can J Ophthalmol* 2018;53:e46-8.