



Original Article

The Role of Serial Radiographs in Diagnosing Diabetic Foot Bone Osteomyelitis

Antonio Leone¹, Nicola Carlo Bianco², Giulia D'Ambra², Salvatore Lucchesi², Elisa La Rosa², Amato Infante¹, Daniele Perla¹ and Consolato Gullì¹.

¹Department of Radiological and Hematological Sciences, Fondazione Policlinico Universitario A. Gemelli, IRCCS, Università Cattolica del Sacro Cuore, Largo A. Gemelli 1, 00168 Rome, Italy.

²Department of Radiological and Hematological Sciences, Università Cattolica del Sacro Cuore, Largo A. Gemelli 1, 00168 Rome, Italy.

Competing interests: The authors declare no conflict of Interest.

Abstract. Background and Objective: Diagnosing diabetes-related foot osteomyelitis is sometimes a challenge for clinicians since it may occur without local or systemic signs of infection. Thus, the primary purpose of this article was to evaluate the role of progressive radiographic changes in diagnosing diabetic foot osteomyelitis.

Materials and Methods: A retrospective review of databases of our Institution was performed to identify all long-standing diabetic foot patients who underwent two radiographic examinations spaced no more than five weeks apart and a subsequent magnetic resonance (MR) examination from November 2015 to November 2020. A total of 46 patients (32 men, 14 women; mean age, 57.3 years) were identified.

Results: serial radiographs showed 89% sensitivity, 38% specificity, 80% diagnostic accuracy, 87% positive predictive value (PPV), 43% negative predictive value (NPV) to diagnose osteomyelitis (P value < 0,05). Bone destruction was the most reliable radiographic sign with 89% sensitivity, 88% specificity, 89% diagnostic accuracy, 97% PPV, 64% NPV (P value < 0,05).

Conclusion: Progressive bony changes detected by serial radiographs are a useful tool to diagnose diabetic foot osteomyelitis.

Keywords: Diabetic foot; Osteomyelitis; Radiography; Magnetic resonance imaging.

Citation: Leone A., Bianco N.C., D'Ambra G., Lucchesi S., La Rosa E., Infante A., Perla D., Gullì C. The role of serial radiographs in diagnosing diabetic foot bone osteomyelitis. *Mediterr J Hematol Infect Dis* 2022, 14(1): e2022055, DOI: <http://dx.doi.org/10.4084/MJHID.2022.055>

Published: July 1, 2022

Received: March 24, 2022

Accepted: June 17, 2022

This is an Open Access article distributed under the terms of the Creative Commons Attribution License (<https://creativecommons.org/licenses/by-nc/4.0>), which permits unrestricted use, distribution, and reproduction in any medium, provided the original work is properly cited.

Correspondence to: Antonio Leone, MD. Department of Radiological and Hematological Sciences, Fondazione Policlinico Universitario A. Gemelli, IRCCS. Università Cattolica del Sacro Cuore, Largo A. Gemelli, 1,00168 Rome, Italy. Tel: +39-06-30156054, Fax: +39-06-35501928. E-mail: a.leonemd@tiscali.it. ORCID: <http://orcid.org/0000-0003-3669-6321>

Introduction. Osteomyelitis is the most common long-term complication of diabetic foot. Infective diabetic foot complications generally begin with a neuropathic ulcer which often develops on the plantar surface of the toes, the metatarsal heads, and the calcaneus. A prompt diagnosis of infective diabetic foot conditions is pivotal in the patients' management, treatment, and prognosis. Diagnostic evaluation starts clinically, based on the patient's history and physical examination. International

Working Group on the Diabetic Foot and Infectious Diseases Society of America proposed a clinical classification system to define the presence and severity of an infection of the diabetic foot.^{1,2} Blood tests are widely available and easily obtained as part of the diagnostic work-up. White blood cell count and inflammatory serum biomarkers (C-reactive protein, erythrocyte sedimentation rate, and procalcitonin) are considered the most useful.¹⁻³ The "probe-to-bone"

(PTB) test is a minimally invasive examination that explores a foot ulcer with a sterile blunt metal probe; the test is positive if the probe reaches the bone. However, its accuracy depends on the operator's experience, pre-test likelihood of infection, and ulcer's location.^{1,2,4} Bone biopsy, providing a histopathologic and microbiologic evaluation of the specimen, is the reference standard to diagnose osteomyelitis and determine the causative pathogen.^{1,2}

Nevertheless, it is an invasive procedure requiring time and experience.^{1,2} The culture of soft tissue specimens may be an alternative diagnostic approach. Still, it shows a relatively low concordance with bone biopsy, with the risk of missing pathogens or contaminating the sample.^{1,2,5} In this scenario, imaging is an additional, complementary, and less invasive diagnostic tool. Radiography should be the first imaging modality when diabetic foot osteomyelitis is suspected due to its low cost and wide availability.^{2,6,7} It is well known that radiography lacks sensitivity in early infection;^{3,6,8} the clinical manifestations of osteomyelitis can precede corresponding bone radiographic changes (such as demineralization, bone destruction, and periosteal reaction) by up to 4 weeks.^{7,9-12}

Furthermore, these radiographic changes can be caused by neuropathic osteoarthropathy.¹³⁻¹⁵ However, even when not diagnostic, it provides information on bone structure, alignment, and anatomic details of the area of interest and any pre-existing condition that could be misinterpreted in subsequent MR examinations.^{6,16} If suspicion of bone infection remains despite an initial negative radiographic examination, repeating radiography in a few weeks can either exclude or suggest the diagnosis of osteomyelitis (if progressive bony changes are evident).^{7,9,14} Several authors^{2,7,9,10,14,17-19} considered a possible role for serial radiographs in this clinical scenario. However, to the best of our knowledge, we are unaware of any studies of the role of serial radiographs in this setting; no studies compared the diagnostic accuracy of serial radiographs to MR imaging, which is currently considered the imaging modality of choice for diagnosing osteomyelitis in the diabetic foot.^{7,20} Therefore, this study's primary purpose was to evaluate serial radiographs' role in diagnosing diabetic foot osteomyelitis.

Materials and Methods. Our institutional review board approved this retrospective single-institution study and waived the informed consent requirement. We performed a computerized database search of our Institution's radiological records from November 2015 to November 2020; the keywords were diabetic foot, neuropathic osteoarthropathy, and osteomyelitis. A total of 133 long-standing diabetic foot patients were identified. For these patients, the inclusion criteria were: (a) patients had to have undergone two radiographic

examinations spaced between 14 and 35 days at our Institution for suspected bone and soft tissue infections; (b) Patients had to have undergone subsequent magnetic resonance (MR) imaging, including unenhanced T1-weighted, fluid-sensitive and gadolinium-enhanced sequences within two weeks after radiography. The exclusion criteria were: (a) presence of other relevant diseases other than diabetes; (b) no serial radiographs or time interposed between two radiographs for more than 35 days; (c) no MR imaging performed; (d) MR imaging performed without intravenous contrast agent; (e) MR imaging spaced more than two weeks from the second radiograph. Inclusion and exclusion criteria are summarized in the patients' flow diagram (**Figure 1**). Only those patients who met all inclusion criteria for the study were recruited. Patients' demographic and clinical data were collected through our Institution's medical record database. Age, sex, diabetes type, time since diabetes diagnosis, anatomic distribution of osteomyelitis, and microbiological findings, when present, were recorded.

Radiographic examinations were performed, including three standard views of the foot (lateral, anteroposterior, and medial oblique); four parameters were analyzed: periosteal reaction, osteopenia, gas in the soft tissues, and bone destruction. In addition, the accuracy of radiographic images was evaluated by comparing them with MR imaging. MR images were obtained with one of two 1.5 superconducting systems (Signa Excite GE Medical Systems, Milwaukee, Wis) and Magnetom Avanto, Siemens Healthcare, Erlangen, Germany. Both scanners were equipped with a dedicated coil, and the patient was lying supine with the knees bent at 35°. Two radiologists (30 and 3 years of clinical experience in muscle-skeletal radiology, respectively) reviewed all the radiographic and MR images in consensus.

Statistical Analysis. The sample is described in its clinical and demographic characteristics using descriptive statistics techniques: categorical variables are expressed as absolute frequencies and percentages. Quantitative variables are summarized with mean and standard deviation, if normally distributed, as median and interquartile range, if not normally distributed. Normality was checked with the Kolmogorov-Smirnov test. Chi-squared and parametric/not-parametric tests were applied according to quantitative variables' normal/not-normal distribution.

Sensitivity, specificity, positive predictive value (PPV), negative predictive value (NPV), and diagnostic accuracy were evaluated and compared between subgroups. Data were analyzed with dedicated software (SPSS for Windows, version 25.0; IBM, Chicago, IL, USA). The data were considered statistically significant at $P < .05$.

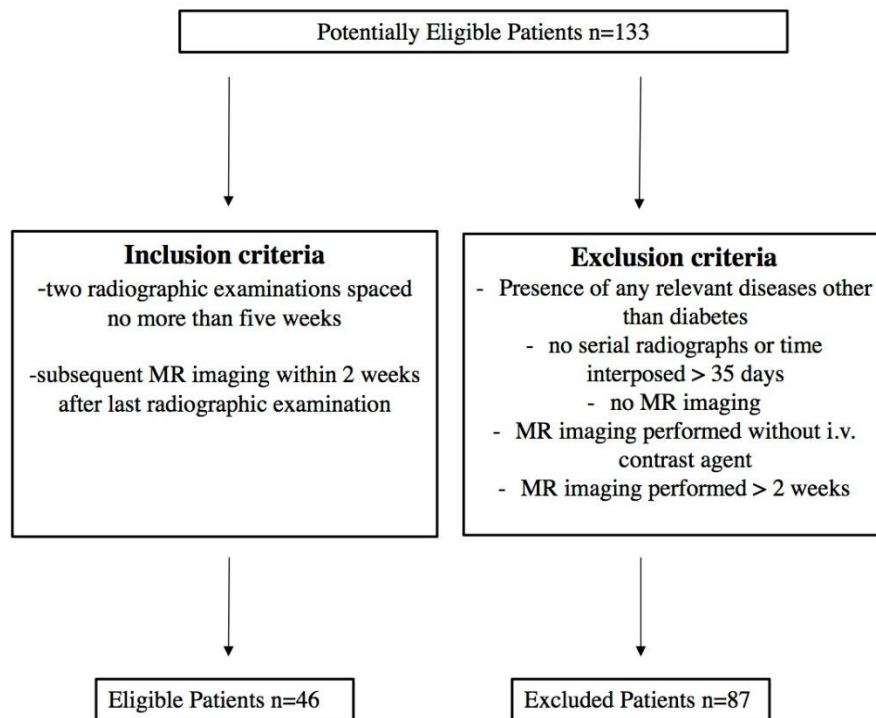


Figure 1. Patient's flow diagram.

Results. Forty-six patients with two serial radiographs spaced between 4 and 5 weeks and subsequent MR imaging (performed within 15 days) were included. The mean age was 57.3 years (range 32-84 years; standard deviation 13.6). In addition, 32 (70%) patients were male, and 14 (30%) were female. In addition, 41 patients (90%) had type 2 diabetes, and 5 had type 1 diabetes (10%). Mean duration of diabetes was 16.1 years (standard deviation 9). Osteomyelitis was located in the forefoot, midfoot, and hindfoot for 82%, 7%, and 11% of patients, respectively. Of the 46 patients, microbiological analysis was available in 26. Gram-positive bacteria were the most common organisms (n=22, 86%). Gram-negative bacteria were present in 4 cases (14%). The most common bacterium was methicillin-sensitive *S. aureus* (MSSA) (n=7, 28%). The clinical, demographic, and microbiological characteristics of patients are summarized in **Table 1**. The mean time between radiographs was 29 days (standard deviation of 6.6). The mean time between the second radiograph and MR imaging was 8 days (standard deviation 3.7). Time interposed between serial radiographs and second radiographic examination and MR imaging showed no statistical correlation with MR findings of osteomyelitis. Based on radiographic findings, bone destruction was seen in 35 patients, osteopenia in 16 patients, gas in the soft tissues in 10, and periosteal reaction in 6. The presence of at least one radiographic finding was seen in 39 patients (84.7%), showing 89% sensibility, 38% specificity, the accuracy of 80%, a positive predictive value (PPV) of 87%, negative predictive value (NPV) 43% ($p < 0,05$) and there was no statistical correlation

with age or sex. Among radiographic signs, bone destruction showed 89% sensibility, 88% specificity, 89% accuracy, 97% VPP, 64% VPN ($p < 0.001$). Other radiographic findings, isolated or in combination, showed no statistical correlation. Data are summarized in **table 2**.

Discussion. Diabetes-related foot osteomyelitis is a common clinical problem and almost invariably originates from an infected foot ulcer in adjacent soft tissue. The importance of correct diagnosis cannot be understated since osteomyelitis complicates treatment

Table 1. Clinical, demographic and microbiological characteristics of patients.

n = 46	
Age (years) (SD)	57,3 (13,6)
Gender	
M (%)	70
F (%)	30
Diabetes duration (years) (SD)	16,1 (9)
Diabetes type	
1 (%)	10
2 (%)	90
Site of osteomyelitis	
forefoot (%)	82
midfoot (%)	7
hindfoot (%)	11
Pathogens (n=26)	
Gram-positive bacteria (%)	86
Gram-negative bacteria (%)	14

Table 2. Diagnostic performance of radiographic signs.

	Sensibility	Specificity	Diagnostic accuracy	PPV	NPV	P-value
Presence of at least one radiographic finding	89%	38%	80%	87%	43%	0,050
Bone destruction	89%	88%	89%	97%	64%	<0,001
Osteopenia	32%	50%	35%	75%	13%	0,320
Gas in the soft tissues	18%	60%	26%	70%	14%	0,234
Periosteal reaction	11%	43%	19%	33%	15%	0,269

Note: PPV = positive predictive value; NPV = negative predictive value.

and is associated with more operations, limb amputation, and prolonged use of antibiotics. Diagnosis of osteomyelitis is sometimes challenging for clinicians since osteomyelitis may occur in the absence of local or systemic signs of infection because of the frequent presence of peripheral neuropathy or vascular insufficiency, especially in chronic infections.²¹ In agreement with previous studies in the literature,²²⁻²⁷ most patients of our population (**Table 1**) had long-standing diabetes (16.1 years), with the prevalence of type 2 (90%), and the forefoot was the most involved anatomic site (82%). Moreover, in our cohort of patients, most pathogens were Gram-positive bacteria, and Meticillin-Sensitive Staphylococcus Aureus was the most common, according to literature data.^{23,29} In fact, it is well known that *S. Aureus* is a bacterium frequently involved in skin, soft tissue, bone, and joint infection.^{29,30}

Diagnosis of osteomyelitis relies on clinical data and laboratory tests supplemented by various imaging modalities such as radiography and MR imaging.¹ Radiography is the first-line imaging modality when diabetic foot osteomyelitis is suspected.^{16,31,32} However, this imaging modality has low sensitivity and specificity for detecting acute osteomyelitis.^{6,17} In a metanalysis by Dinh et al.,¹⁷ radiography showed 54% pooled sensitivity, and 68% pooled specificity; a more recent metanalysis³³ showed 68.9% sensitivity and 77.9% specificity. Sensibility is low because bony abnormalities can be detected on radiographs only in the late stage of osteomyelitis when at least half of the bone has been destroyed;^{7,10,34} the timing of radiographs in relation to the chronicity of the ulcer is reported as another parameter that affects sensibility.^{11,33} In addition, reported specificity is low because differentiating infectious from noninfectious bone disorders may be difficult with radiographs; osteomyelitis can overlap with other common diabetic foot conditions, such as fractures and Charcot neuropathic osteoarthropathy, especially without adequate clinical data.¹³⁻¹⁵ MR imaging is the modality of choice for assessing diabetic foot osteomyelitis, with a sensitivity of 90% and specificity of 83%.^{1,20}

In this setting, several authors^{1,7,9,10,14,17-19} proposed serial radiographs as an additional diagnostic tool to detect diabetic foot osteomyelitis. However, to the best of our knowledge, no previous studies examined the

diagnostic performance of serial radiographs. Sensibility and PPV for radiography in detecting diabetic foot osteomyelitis range from 28% to 75%.^{17,32,34} In our experience, serial radiographs showed higher sensibility and PPV (89% and 97%, respectively). However, bone abnormalities can take at least 2-4 weeks to manifest on radiographs.^{7,9,10-12} Time interposed between serial radiographs (14-35 days) may allow bone changes to progress enough to be observed at the second examination (**Figure 2**); furthermore, comparing radiographs can help assess the evolution of pre-existing findings. However, within the selected time range, we did not find any exact timing associated with a better diagnostic performance. In accordance with Konarzewska et al.,¹⁰ our results may demonstrate that the continued absence of any bony abnormality on serial radiographs probably excludes osteomyelitis. Specificity and NPV for serial radiographs were 38% and 43%, respectively, lower than those reported in the literature for a single radiograph (pooled specificity 68%).^{17,33} These data may be explained by the low inner specificity of radiographical findings, which are more frequently identified by serial radiographs than by a single radiograph. In fact, bone destruction and osteopenia in the atrophic form of Charcot neuropathic osteoarthropathy or periosteal reaction, also following fractures, cannot be reliably distinguished, even when their progression over time is considered.^{1,2,7,11,14} Furthermore, the radiographic technique also plays a role; serial radiographs should be performed with the same technical parameters, as different kVp and mAs values may lead to false positives.¹¹ Among the four radiographic signs evaluated, bone destruction is the most reliable sign in the diagnosis of diabetic foot osteomyelitis. This finding is in agreement with Alvaro-Alfonso et al.³⁵ These authors were the first to stratify different signs in a single radiographic examination performed for suspected diabetic foot osteomyelitis, showing 76% sensibility and 45% specificity for bonedestruction. However, our results with serial radiographs demonstrated both higher sensibility (89%) and (88%) specificity for this sign (**Figure 3**). Other radiographic signs, alone or in association, showed lower diagnostic performance, and data were not statistically significant.

This study has several drawbacks. First, it has a

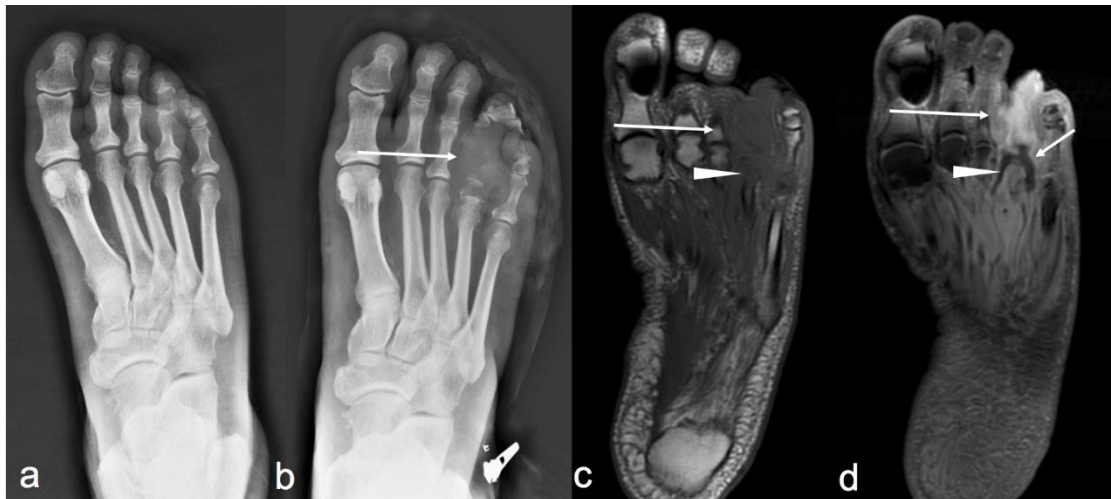

Figure 2. 62-year-old man with 16-years history of diabetes. **(a)** Anteroposterior view of the foot does not show bony abnormalities. **(b)** Corresponding anteroposterior view obtained 21 days later shows extensive bone destruction of the fourth proximal and intermediate phalanx with associated soft tissue thickening (arrow). **(c)** Axial T1-weighted and **(d)** axial post-contrast T1-weighted fat-suppressed MR images confirm phalangeal destruction (arrow in c, and d) extending to adjacent metatarsal head with decreased signal intensity (arrowhead in c) and post-contrast enhancement (arrowhead in d). Note also an adjacent soft tissue abscess with peripheral post-contrast rim enhancement (small arrow in d).

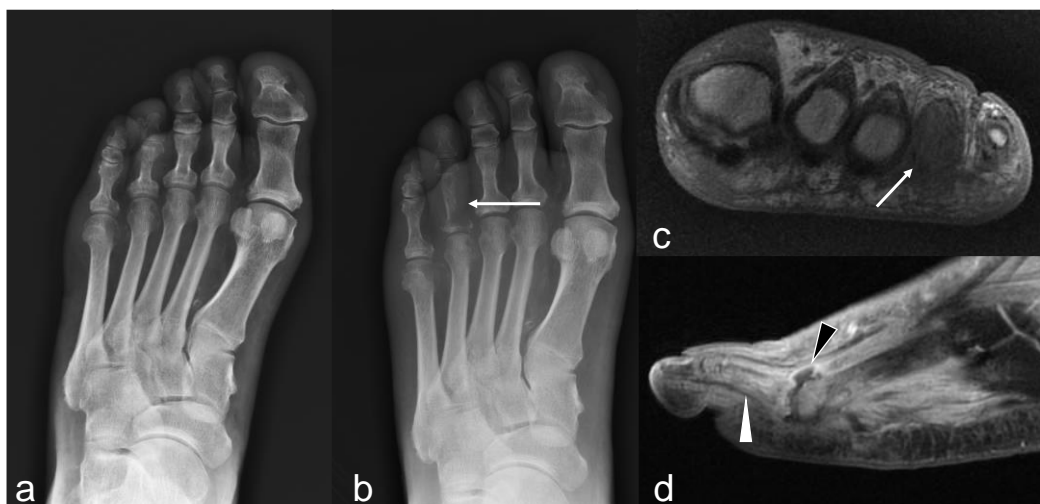

Figure 3. 67-year-old man with 24-years history of diabetes. **(a)** Anteroposterior view of the foot does not show any relevant finding. **(b)** Corresponding anteroposterior view obtained 16 days later shows extensive bone destruction at the base of the fourth proximal phalanx (arrow). **(c)** Coronal T1-weighted MR image demonstrates diffuse bone marrow hypointensity of the fourth proximal phalanx (arrow). **(d)** Sagittal post-contrast T1-weighted fat-suppressed MR image shows capsular distension and synovial post-contrast enhancement of the fourth metatarsophalangeal joint indicative of infected/septic arthritis (black arrowhead). Thus, the diffuse post-contrast enhancement of the fourth proximal phalanx is consistent with acute osteomyelitis (white arrowhead).

retrospective design, and the small population sampling may be prone to selection bias. Second, although radiographic findings were compared with MR imaging (the imaging modality of choice in this setting), we could not confirm data with bone biopsy for all patients. Finally, patients underwent radiography with the clinical suspicion of osteomyelitis; however, accurate information about the clinical signs and symptoms was frequently lacking, though the appropriateness and detail

of radiographic referral request play an important role in the image interpretation.

Conclusions. Detecting bone destruction with serial radiographs may be an additional diagnostic tool when diabetic foot osteomyelitis is suspected. However, further studies are required before the true management value of serial radiographs can be determined.

References:

1. Lipsky BA, Senneville É, Abbas ZG et al; International Working Group on the Diabetic Foot (IWGDF). Guidelines on the diagnosis and treatment of foot infection in persons with diabetes (IWGDF 2019 update). *Diabetes Metab Res Rev.* 2020 Mar;36 Suppl 1:e3280 <https://doi.org/10.1002/dmrr.3280> PMID:PMC7154668
2. Lipsky BA, Berendt AR, Cornia PB et al.; Infectious Diseases Society of America. 2012 Infectious Diseases Society of America clinical practice

- guideline for the diagnosis and treatment of diabetic foot infections. *Clin Infect Dis*. 2012 Jun;54(12):e132-73.
<https://doi.org/10.1093/cid/cis346>
PMid:22619242
3. Lauri C, Leone A, Cavallini M, Signore A, Giurato L, Uccioli L. Diabetic Foot Infections: The Diagnostic Challenges. *J Clin Med*. 2020 Jun 8;9(6):1779.
<https://doi.org/10.3390/jcm9061779>
PMid:32521695 PMCid:PMC7355769
 4. Lam K, van Asten SA, Nguyen T, La Fontaine J, Lavery LA. Diagnostic accuracy of probe to bone to detect osteomyelitis in the diabetic foot: a systematic review. *Clin Infect Dis*. 2016;63:944-948.
<https://doi.org/10.1093/cid/ciw445>
PMid:27369321
 5. Prompers L, Schaper N, Apelqvist J, et al. Prediction of outcome in individuals with diabetic foot ulcers: focus on the differences between individuals with and without peripheral arterial disease. The EURODIALE study. *Diabetologia*. 2008;51:747-755.
<https://doi.org/10.1007/s00125-008-0940-0>
PMid:18297261 PMCid:PMC2292424
 6. Leone A, Vitiello C, Gulli C, Sikora AK, Macagnino S, Colosimo C. Bone and soft tissue infections in patients with diabetic foot. *Radiol Med*. 2020;125(2):177-187.
<https://doi.org/10.1007/s11547-019-01096-8>
PMid:31650327
 7. Senneville EM, Lipsky BA, van Asten SAV, Peters EJ. Diagnosing diabetic foot osteomyelitis. *Diabetes Metab Res Rev*. 2020 Mar;36 Suppl 1:e3250
<https://doi.org/10.1002/dmrr.3250>
 8. Butalia S, Palda VA, Sargeant RJ, Detsky AS, Mourad O. Does this patient with diabetes have osteomyelitis of the lower extremity? *JAMA* 2008; 299(7):806-813.
<https://doi.org/10.1001/jama.299.7.806>
PMid:18285592
 9. Markanday A. Diagnosing diabetic foot osteomyelitis: narrative review and a suggested 2-step score-based diagnostic pathway for clinicians. *Open Forum Infect Dis*. 2014 Aug 7;1(2):ofu060.
<https://doi.org/10.1093/ofid/ofu060>
PMid:25734130 PMCid:PMC4281812
 10. Konarzewska A, Korzon-Burakowska A, Rzepecka-Wejs L, Sudol-Szopińska I, Szurowska E, Studniarek M. Diabetic foot syndrome: Charcot arthropathy or osteomyelitis? Part I: Clinical picture and radiography. *J Ultrason*. 2018 Mar;18(72):42-49. doi: 10.15557/JoU.2018.0007.
<https://doi.org/10.15557/JoU.2018.0007>
PMid:29844940 PMCid:PMC5911718
 11. Aragón-Sánchez J. Seminar review: A review of the basis of surgical treatment of diabetic foot infections. *Int J Low Extrem Wounds*. 2011 Mar;10(1):33-65.
<https://doi.org/10.1177/1534734611400259>
PMid:21444608
 12. Nawaz A, Torigian DA, Siegelman ES, Basu S, Chryssikos T, Alavi A. Diagnostic performance of FDG-PET, MRI, and plain film radiography (PFR) for the diagnosis of osteomyelitis in the diabetic foot. *Mol Imaging Biol*. 2010 Jun;12(3):335-42.
<https://doi.org/10.1007/s11307-009-0268-2>
PMid:19816744
 13. Linsley, J., & Reel, S. (2021). The appropriateness of X-ray referrals of osteomyelitis and its timely management with antibiotics: a service evaluation. *The Diabetic Foot Journal*, 24(3), 10-15
 14. Lee YJ, Sadigh S, Mankad K, Kapse N, Rajeswaran G. The imaging of osteomyelitis. *Quant Imaging Med Surg*. 2016 Apr;6(2):184-98.
<https://doi.org/10.21037/qims.2016.04.01>
PMid:27190771 PMCid:PMC4858469
 15. Lipsky BA. Osteomyelitis of the foot in diabetic patients. *Clin Infect Dis*. 1997 Dec;25(6):1318-26.
<https://doi.org/10.1086/516148>
PMid:9431370
 16. Vopat ML, Nentwig MJ, Chong ACM, Agan JL, Shields NN, Yang SY. Initial Diagnosis and Management for Acute Charcot Neuroarthropathy. *Kans J Med*. 2018 Nov 29;11(4):114-119.
<https://doi.org/10.17161/kjm.v11i4.8709>
PMid:30937152 PMCid:PMC6276967
 17. Dinh MT, Abad CL, Safdar N. Diagnostic accuracy of the physical examination and imaging tests for osteomyelitis underlying diabetic foot ulcers: meta-analysis. *Clin Infect Dis*. 2008 Aug 15;47(4):519-27.
<https://doi.org/10.1086/590011>
PMid:18611152 PMCid:PMC7450707
 18. Schinabeck MK, Johnson JL. Osteomyelitis in diabetic foot ulcers. Prompt diagnosis can avert amputation. *Postgrad Med*. 2005 Jul;118(1):11-5.
<https://doi.org/10.3810/pgm.2005.07.1678>
PMid:16106914
 19. Tran K, Mierzwinski-Urban M. Serial X-Ray Radiography for the Diagnosis of Osteomyelitis: A Review of Diagnostic Accuracy, Clinical Utility, Cost-Effectiveness, and Guidelines [Internet]. Ottawa (ON): Canadian Agency for Drugs and Technologies in Health; 2020 Mar 13.
 20. Donovan A, Schweitzer ME. Use of MR imaging in diagnosing diabetes-related pedal osteomyelitis. *Radiographics*. 2010 May;30(3):723-36.
<https://doi.org/10.1148/rg.303095111>
PMid:20462990
 21. Edmonds M. Double trouble: infection and ischemia in the diabetic foot. *Int J Low Extrem Wounds* 2009;8:62-63.
<https://doi.org/10.1177/1534734609337930>
PMid:19443892
 22. Faglia E, Clerici G, Caminiti M, Curci V, Somalvico F. Influence of osteomyelitis location in the foot of diabetic patients with transtibial amputation. *Foot Ankle Int*. 2013 Feb;34(2):222-7.
<https://doi.org/10.1177/1071100712467436>
PMid:23413061
 23. King CM, Castellucci-Garza FM, Lyon L, Doyle MD, Nimick C, Williams ML. Microorganisms Associated With Osteomyelitis of the Foot and Ankle. *J Foot Ankle Surg*. 2020 May-Jun;59(3):491-494.
<https://doi.org/10.1053/j.jfas.2019.08.032>
PMid:32354506
 24. Ledermann HP, Morrison WB, Schweitzer ME. MR image analysis of pedal osteomyelitis: distribution, patterns of spread, and frequency of associated ulceration and septic arthritis. *Radiology*. 2002 Jun;223(3):747-55.
<https://doi.org/10.1148/radiol.2233011279>
PMid:12034944
 25. Moura Neto A, Zantut-Wittmann DE, Fernandes TD, Nery M, Parisi MC. Risk factors for ulceration and amputation in diabetic foot: study in a cohort of 496 patients. *Endocrine*. 2013 Aug;44(1):119-24
<https://doi.org/10.1007/s12020-012-9829-2>
PMid:23124278
 26. Oyibo SO, Jude EB, Tarawneh I, Nguyen HC, Armstrong DG, Harkless LB, Boulton AJ. The effects of ulcer size and site, patient's age, sex and type and duration of diabetes on the outcome of diabetic foot ulcers. *Diabet Med*. 2001 Feb;18(2):133-8
<https://doi.org/10.1046/j.1464-5491.2001.00422.x>
PMid:11251677
 27. Mehmood K, Akhtar ST, Talib A, Abbasi B, Siraj-ul-Salekeen, Naqvi IH. Clinical profile and management outcome of diabetic foot ulcers in a tertiary care hospital. *J Coll Physicians Pak*. 18, 408-412 (2008)
 28. Lauterbach S, Kostev K, Becker R. Characteristics of diabetic patients visiting a podiatric practice in Germany. *J. Wound Care* 19, 140-144 (2010)
<https://doi.org/10.12968/jowc.2010.19.4.140>
PMid:20379125
 29. Macdonald KE, Boeckh S, Stacey HJ, Jones JD. The microbiology of diabetic foot infections: a meta-analysis. *BMC Infect Dis*. 2021 Aug 9;21(1):770.
<https://doi.org/10.1186/s12879-021-06516-7>
PMid:34372789 PMCid:PMC8351150
 30. Lowy FD. Staphylococcus aureus infections. *N Engl J Med*. 1998 Aug 20;339(8):520-32
<https://doi.org/10.1056/NEJM199808203390806>
PMid:9709046
 31. Hochman MG, Connolly C. (2018) Imaging of Infection in the Diabetic Foot. In: Veves A., Giurini J., Guzman R. (eds) *The Diabetic Foot*. Contemporary Diabetes. Humana, Cham.
https://doi.org/10.1007/978-3-319-89869-8_5
 32. Internal Clinical Guidelines team. *Diabetic Foot Problems: Prevention and Management*. London: National Institute for Health and Care Excellence (UK); 2015 Aug.
 33. Llewellyn A, Kraft J, Holton C, Harden M, Simmonds M. Imaging for detection of osteomyelitis in people with diabetic foot ulcers: A systematic review and meta-analysis. *Eur J Radiol*. 2020 Oct;131:109215.
<https://doi.org/10.1016/j.ejrad.2020.109215>
PMid:32862106
 34. Crim JR, Seeger LL. Imaging evaluation of osteomyelitis. *Crit Rev Diagn Imaging*. 1994;35(3):201-56.
 35. Álvaro-Afonso FJ, Lázaro-Martínez JL, García-Morales E, García-Álvarez Y, Sanz-Corbalán I, Molines-Barroso RJ. Cortical disruption is

the most reliable and accurate plain radiographic sign in the diagnosis of diabetic foot osteomyelitis. Diabet Med. 2019 Feb;36(2):258-259.

<https://doi.org/10.1111/dme.13824>
PMid:30246491