



CASE REPORT

REVISED Case Report: Cyclophosphamide in COVID-19 – when an absolute contraindication is an absolute necessity [version 2; peer review: 2 approved]

Kamila Bołtuć ¹, Ada Bielejewska¹, Alejandro Coloma-Millar², Robert Dziugieł¹, Arkadiusz Bociek¹, Agnieszka Perkowska-Ptasińska³, Andrzej Jaroszyński ^{1,2}

¹Collegium Medicum, Jan Kochanowski University, Kielce, Poland

²Nephrology Clinic, Voivodeship Hospital, Kielce, Poland

³Department of Pathomorphology, Medical University of Warsaw, Warsaw, Poland

v2 First published: 19 Aug 2021, 10:829
<https://doi.org/10.12688/f1000research.55625.1>
 Latest published: 25 Oct 2021, 10:829
<https://doi.org/10.12688/f1000research.55625.2>

Abstract

Background: Despite many studies on COVID-19, our knowledge of it remains incomplete. In some cases, treating SARS-CoV-2 infection concomitant with other diseases can be particularly challenging, as finding an appropriate treatment may involve some risks.

Case presentation: A 34-year-old SARS-CoV-2 positive patient admitted due to fever, dyspnoea, haemoptysis and pneumonia, developed alveolar haemorrhage and acute kidney injury. Due to his severe state, abnormalities in laboratory tests and rapidly progressing loss of kidney function, kidney biopsy, as well as antibody panel were carried out, in which perinuclear anti-neutrophil cytoplasmic antibodies (p-ANCA) were found with a high titer (>200; N: <1:20). The results of kidney biopsy, combined with clinical manifestation and laboratory findings prompted the diagnosis of rapidly progressing glomerulonephritis (RPGN) in the course of p-ANCA vasculitis. Initial treatment consisted of haemodialyses, remdesivir, plasmaphereses, intravenous immunoglobulins, antibiotics, corticosteroids and nadroparin. Once the haemorrhage had subsided, kidney function had been partially retrieved and haemodialyses had no longer been necessary, cyclophosphamide treatment was initiated, despite being contraindicated in COVID-19 according to its summary of product characteristics. Immunotherapy is still continued. The patient has already received a total of 2.4g of cyclophosphamide (4 cycles of 600mg each every three weeks). Pulmonary and radiological regression, as well as improvement of renal parameters have been achieved.

Conclusions: We suspect that cyclophosphamide, the drug of choice in p-ANCA vasculitis, could be a potential factor providing regression of the radiological changes in the lungs and it could have prevented the patient from developing acute respiratory distress syndrome.

Open Peer Review

Reviewer Status

Invited Reviewers

1 2

version 2

(revision)
25 Oct 2021



report



version 1

19 Aug 2021



report



report

1. **Anna Clementi**, Santa Marta and Santa Venera Hospital, Acireale, Catania, Italy
2. **Krzysztof J. Filipiak** , Medical University of Warsaw, Warsaw, Poland

Any reports and responses or comments on the article can be found at the end of the article.

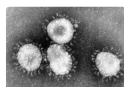
COVID-19 diagnosis should not exclude searching for other diseases which can have a similar course. When treating a patient in a life-threatening condition, a departure from trying to find the perfect timing of cyclophosphamide delivery should be considered, as delaying it could cause potentially greater harm.

Keywords

COVID-19, vasculitis, alveolar haemorrhage, p-ANCA, cyclophosphamide



This article is included in the **Emerging Diseases and Outbreaks** gateway.



This article is included in the **Coronavirus** collection.

Corresponding author: Andrzej Jaroszyński (jaroszynskiaj@interia.pl)

Author roles: **Bołtuć K:** Supervision, Visualization, Writing – Original Draft Preparation; **Bielejewska A:** Supervision, Visualization, Writing – Original Draft Preparation; **Coloma-Millar A:** Investigation, Resources; **Dziugiel R:** Visualization, Writing – Original Draft Preparation; **Bociek A:** Visualization, Writing – Original Draft Preparation; **Perkowska-Ptasińska A:** Resources; **Jaroszyński A:** Conceptualization, Supervision, Visualization, Writing – Original Draft Preparation, Writing – Review & Editing

Competing interests: No competing interests were disclosed.

Grant information: The author(s) declared that no grants were involved in supporting this work.

Copyright: © 2021 Bołtuć K *et al.* This is an open access article distributed under the terms of the [Creative Commons Attribution License](#), which permits unrestricted use, distribution, and reproduction in any medium, provided the original work is properly cited.

How to cite this article: Bołtuć K, Bielejewska A, Coloma-Millar A *et al.* **Case Report: Cyclophosphamide in COVID-19 – when an absolute contraindication is an absolute necessity [version 2; peer review: 2 approved]** F1000Research 2021, 10:829 <https://doi.org/10.12688/f1000research.55625.2>

First published: 19 Aug 2021, 10:829 <https://doi.org/10.12688/f1000research.55625.1>

REVISED Amendments from Version 1

One error in the treatment section was found and corrected (when the bleeding had stopped Nadroparin was prescribed, not Fraxiparine as previously stated).

Any further responses from the reviewers can be found at the end of the article

List of abbreviations

AKI: acute kidney injury
 ANA: antinuclear antibodies
 anti-GBM: anti-glomerular basement membrane antibodies
 ARDS: acute respiratory distress syndrome
 BP: blood pressure
 c-ANCA: cytoplasmic anti-neutrophil cytoplasmic antibodies
 CRP: C-reactive protein
 CT: chest computed tomography
 IL-6: interleukin 6
 IVIG: intravenous immunoglobulins
 p-ANCA: perinuclear anti-neutrophil cytoplasmic antibodies
 RPGN: rapidly progressing glomerulonephritis

Introduction

More than a year has passed since COVID-19 emerged as a global pandemic. Despite many studies, our knowledge of this disease remains incomplete, especially in SARS-CoV-2 infection with concomitant diseases. Thus, many clinicians face difficulties with finding an appropriate treatment for some cases.

Case report

A 34-year-old SARS-CoV-2-positive Caucasian male with a history of borderline hypertension, hypothyroidism and transient arthralgia 2 years prior (without any further investigation), was admitted to a pulmonology ward in November 2020 due to fever (up to 38.5°C), dyspnoea, haemoptysis and developing bilateral pneumonia. During hospitalization the patient developed alveolar haemorrhage followed by acute kidney injury (AKI), for which he was transferred to a Nephrology Clinic on November 21, 2020. On admission he was afebrile and presented with mild haemoptysis and conjunctivitis, oxygen saturation 86-94% (oxygen flow 10-15 l/min), blood pressure (BP) 120/70 mmHg, numerous erythrocytes in urine sediment and proteinuria of 0.47 g/l. His condition was severe and deteriorating.

Owing to the anamnesis of transient arthralgia and rapid deterioration of the kidney function, antibody panel was carried out in which anti-glomerular basement membrane antibodies (anti-GBM), antinuclear antibodies (ANA), as well as cytoplasmic anti-neutrophil cytoplasmic antibodies (c-ANCA) were negative, whereas perinuclear anti-neutrophil cytoplasmic antibodies (p-ANCA) were found with a high titer (>200; N: <1:20), suggesting p-ANCA vasculitis complicating COVID-19. Laboratory tests revealed AKI requiring haemodialysis. Anaemia was particularly noticeable. Additionally, leukocytosis, hypoproteinemia, dysproteinemia, elevated D-dimers, C-reactive protein (CRP), interleukin 6 (IL-6), creatinine and urea levels, proteinuria and haematuria were present (Table 1). The parameters of the blood coagulation system were within normal range. Chest computed tomography (CT) demonstrated changes suggesting both viral pneumonia and alveolar haemorrhage (Figure 1, scans A-C). Kidney biopsy performed on the first day of hospitalisation in the Nephrology Clinic and examined with a light microscope revealed crescents in segmental tuft necrosis in two, cellular crescent in one and fibrocellular crescents in three out of nine glomeruli. Glomerular lesions were accompanied by mild interstitial inflammation and acute tubular necrosis. There was no interstitial fibrosis nor tubular atrophy. Immunofluorescence did not reveal any deposits of immunoglobulins nor complement components (Figure 2). The biopsy result, combined with clinical manifestation, prompted the diagnosis of rapidly progressing glomerulonephritis (RPGN) in the course of p-ANCA vasculitis.

In spite of haemodialysis, the patient was treated with remdesivir (0.1 g). Parallely to remdesivir therapy, in order to stop the immunological process causing the bleeding, the patient underwent four plasmaphereses with both fresh frozen plasma and albumin as replacement fluids and citrate as anticoagulant. On account of anaemia, the patient was given four units of packed red blood cells. On the fifth and sixth day of hospitalization, a total of 40 g of intravenous immunoglobulins (IVIG) were ordered to inhibit the underlying immunological process responsible for alveolar bleeding in the course of p-ANCA vasculitis. Moreover, owing to the alveolar haemorrhage and probable bacterial superinfection,

Table 1. Patient's laboratory results on admission.

Parameter	Patient value	Normal range
Haemoglobin [g/dl]	9.3	13.7-16.5
Serum total protein [g/dl]	4.90	6.00-8.00
Alpha 1 [g/dl]	0.26	0.21-0.35
Alpha 2 [g/dl]	0.37	0.51-0.85
Beta 1 [g/dl]	0.25	0.34-0.52
Beta 2 [g/dl]	0.18	0.23-0.47
Gamma [g/dl]	0.56	0.80-1.35
D-dimer [ug/l]	2378.0	0.0-500.0
White blood cell count [K/u]	16.20	4.23-9.07
CRP [mg/l]	35.46	0.10-5.00
IL-6 [pg/ml]	92.0	<7.0
Creatinine [mg/dl]	3.2	0.70-1.30
Urea [mg/dl]	89	20-45
Total protein in urine [g/l]	0.47	0.05-0.08
Erythrocytes in urine sediment	numerous	0-5 in visual field

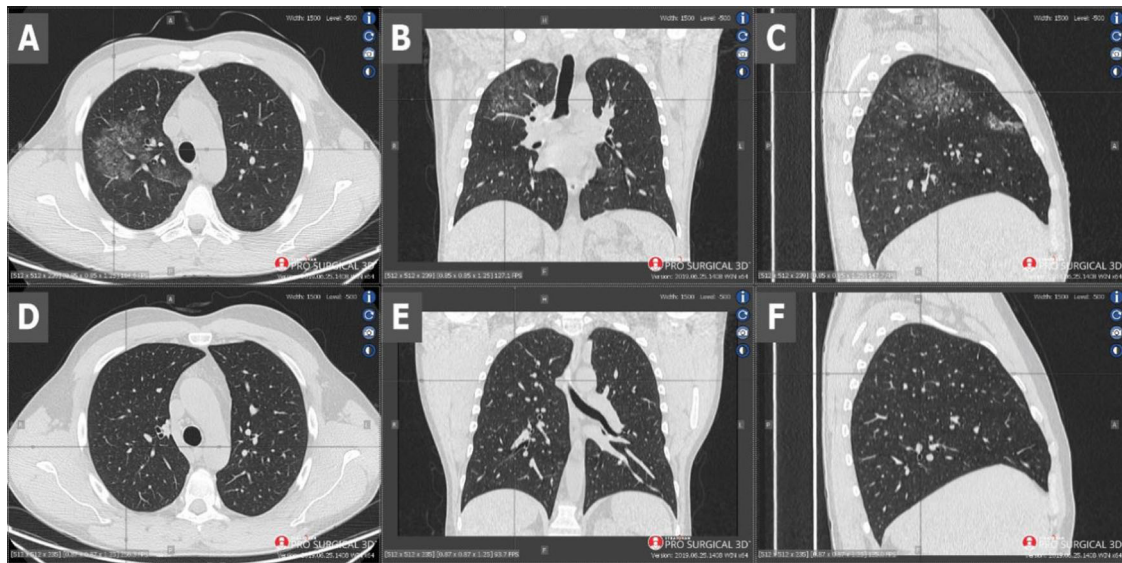


Figure 1. Scans A-C - CT performed on admission - scans show diffuse ground-glass opacities and septal interlobular thickening in the right lung, as well as paving-stone findings which could represent alveolar haemorrhage. Scans D-F - CT performed 2 months later - visible radiological regression.

clarithromycin and piperacillin with tazobactam were ordered. Simultaneously, corticosteroid treatment was started when the results of p-ANCA antibodies were received (1.0 g of intravenous methylprednisolone for 4 consecutive days, followed by 40 mg of oral prednisone). Initially, due to alveolar bleeding, nadroparin treatment could not be initiated, despite increasing values of D-dimers (2378.0 ug/l vs 4053.0 ug/l 3 days later; N: 0.0-500.0). It was not until after the bleeding had stopped, that it was prescribed (2x 0.6 ml). Once the haemorrhage had subsided, kidney function had been partially retrieved and haemodialyses had no longer been necessary, cyclophosphamide treatment was initiated on the eighth day of hospitalization, despite being contraindicated in COVID-19 according to its summary of product characteristics.

Currently, immunotherapy is continued. To date, the patient has received a total of 2.4 g (four cycles of 600 mg each, 3 weeks apart) of cyclophosphamide. The therapy is well-tolerated and a pulmonary clinical and radiological remission

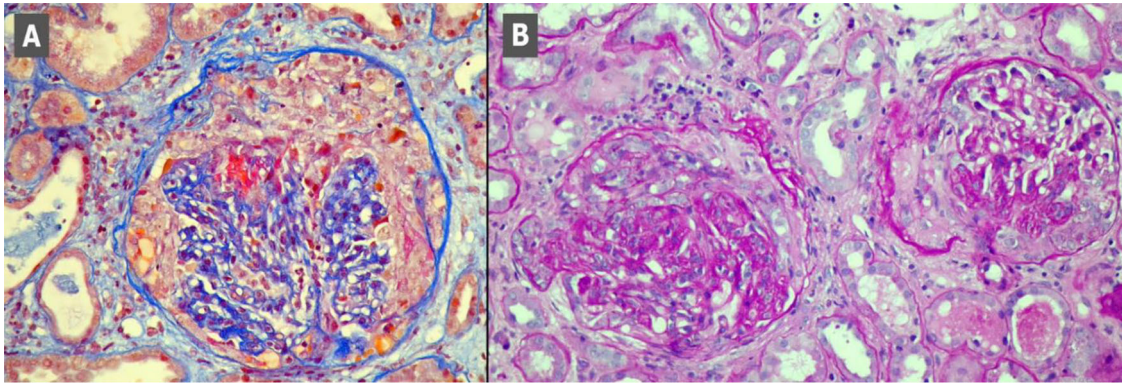


Figure 2. Kidney biopsy scans. Scan A - segmental necrosis and cellular crescent, Masson stain. Scan B - Glomeruli with fibrocellular crescents, PAS stain.

has been achieved (Figure 1, scans D-F). Additionally, renal parameters have improved with creatinine level at 1.1 mg/dl and stable proteinuria of 1.8 g/24 h.

Discussion

While there are cases of continuing immunosuppressive therapy during COVID-19, no data related to the onset of this treatment while undergoing the acute phase of SARS-CoV-2 infection and the follow-up has been reported yet. To our best knowledge, this is the first report of introducing the cyclophosphamide treatment during the acute phase of COVID-19 with the follow-up.

Our case presents a critically ill patient whose state was deteriorating despite the standard treatment. Even though SARS-CoV-2 has been known to induce AKI even in 22.2% of hospitalized patients,¹ as well as to cause pneumorrhagia,² the coincidence of renal and pulmonary symptoms prompted us to search for another reason for the patient's state other than merely COVID-19. Confirmed p-ANCA vasculitis was an indication to introduce immunosuppressive treatment. However, an active SARS-CoV-2 infection is considered an absolute contraindication for this therapy. Even so, the treatment was still initiated, since the patient's life was in danger and it was the last resort. We decided to try to stabilize the patient and wait till the estimated time of the viral replication phase end to introduce cyclophosphamide.³

Despite the fact that COVID-19 could have been the reason for pneumorrhagia and such severe state of the patient, systemic vasculitis seemed to be the more likely cause. Thus, the limitation of vasculitis effects and induction of immunosuppression was essential. To this end, plasmapheresis and high doses of IVIG were ordered. It is worth noting that IVIG and plasmapheresis could limit a SARS-CoV-2 infection and increase the tolerance to immunosuppressive treatment⁴ which was twice as beneficial for our patient. The patient also received remdesivir to inhibit the virus multiplication and invasion. It should be noted that starting immunosuppression in the acute phase of the disease was very risky. Surprisingly, not only did cyclophosphamide not harm the patient, but also the whole applied treatment improved the patient's state remarkably. CT performed 32 days after the initial CT (after three cycles of cyclophosphamide) showed total regression of ground-glass opacities and septal interlobular thickening and paving-stone findings (Figure 1, scans D-F), even though radiological changes in the lungs in COVID-19 can persist for a long time after recovering from the disease.⁵

It seems that our case may indirectly be in line with the hypothesis about the positive influence of immunosuppressive treatment in COVID-19.⁶ Although IVIG and plasmapheresis therapy was not meaningless, this treatment alone would not lead to remission. We suspect that it was in fact cyclophosphamide, the drug of choice in p-ANCA vasculitis, that could be a potential factor providing regression of the radiological changes in the lungs and it could have prevented the patient from developing acute respiratory distress syndrome (ARDS). It could have happened by the drug's immunomodulatory function - the second phase of COVID-19 is strongly linked to immunological response, as innate immunity mediated damage of pneumocytes and capillary leak, brought by activation of cytotoxic and effector T-cells, take place in it. The immunomodulatory function of cyclophosphamide led to the elimination of inflammatory damages' origin. We point out that the onset of treatment happened during the second phase of COVID-19. Having regard to the high potential of replication of SARS CoV-2, immunosuppressive treatment in the replication phase could be tragic.

Conclusion

COVID-19 diagnosis should not exclude searching for other diseases which can have a similar course. When treating a patient in a life-threatening condition, a departure from trying to find the perfect timing of cyclophosphamide delivery should be considered, as delaying it could cause potentially greater harm.

Declarations

Consent for publication – Written informed consent for publication was obtained from the patient.

Data availability - All data underlying the results are available as part of the article and no additional source data are required.

References

1. Richardson S, Hirsch JS, Narasimhan M, *et al.*: **Presenting Characteristics, Comorbidities, and Outcomes among 5700 Patients Hospitalized with COVID-19 in the New York City Area.** *JAMA - J Am Med Assoc.* 2020; **323**: 2052–9.
[PubMed Abstract](#) | [Publisher Full Text](#) | [Free Full Text](#)
2. Löffler C, Mahrhold J, Fogarassy P, *et al.*: **Two Immunocompromised Patients With Diffuse Alveolar Hemorrhage as a Complication of Severe Coronavirus Disease 2019.** *Chest.* 2020; **158**: e215–9.
[PubMed Abstract](#) | [Publisher Full Text](#) | [Free Full Text](#)
3. Griffin DO, Brennan-Rieder D, Ngo B, *et al.*: **The Importance of Understanding the Stages of COVID-19 in Treatment and Trials.** *Aids Rev.* 2021; **23**.
[PubMed Abstract](#) | [Publisher Full Text](#)
4. Pourahmad R, Moazzami B, Rezaei N: **Efficacy of Plasmapheresis and Immunoglobulin Replacement Therapy (IVIg) on Patients with COVID-19.** *SN Compr Clin Med.* 2020; **2**: 1407–11.
[PubMed Abstract](#) | [Publisher Full Text](#) | [Free Full Text](#)
5. Myall KJ, Mukherjee B, Castanheira AM, *et al.*: **Persistent Post-COVID-19 Inflammatory Interstitial Lung Disease: An Observational Study of Corticosteroid Treatment.** *Ann Am Thorac Soc.* 2021; **0**: AnnalsATS.202008-10020C.
[PubMed Abstract](#) | [Publisher Full Text](#) | [Free Full Text](#)
6. Revannasiddaiah S, Kumar Devadas S, Palassery R, *et al.*: **A potential role for cyclophosphamide in the mitigation of acute respiratory distress syndrome among patients with SARS-CoV-2.** *Med Hypotheses.* 2020; **144**: 109850.
[PubMed Abstract](#) | [Publisher Full Text](#) | [Free Full Text](#)

Open Peer Review

Current Peer Review Status:  

Version 2

Reviewer Report 26 October 2021

<https://doi.org/10.5256/f1000research.78504.r97919>

© 2021 Clementi A. This is an open access peer review report distributed under the terms of the [Creative Commons Attribution License](#), which permits unrestricted use, distribution, and reproduction in any medium, provided the original work is properly cited.



Anna Clementi

Nephrology and Dialysis Department, Santa Marta and Santa Venera Hospital, Acireale, Catania, Italy

I have no other comments.

Competing Interests: No competing interests were disclosed.

Reviewer Expertise: Nephrology

I confirm that I have read this submission and believe that I have an appropriate level of expertise to confirm that it is of an acceptable scientific standard.

Version 1

Reviewer Report 10 September 2021

<https://doi.org/10.5256/f1000research.59218.r93992>

© 2021 Filipiak K. This is an open access peer review report distributed under the terms of the [Creative Commons Attribution License](#), which permits unrestricted use, distribution, and reproduction in any medium, provided the original work is properly cited.



Krzysztof J. Filipiak 

1st Department of Cardiology, Medical University of Warsaw, Warsaw, Poland

A very interesting case report describing the possibility of cyclophosphamide use in COVID-19. Immunosuppressive treatment in COVID-19 is a question of discussion. Cyclophosphamide, the drug of choice in p-ANCA vasculitis, could be a potential factor providing regression of the

radiological changes in the lungs and it could have prevented the patient from developing acute respiratory distress syndrome (ARDS). The case is well illustrated and well written. As the immunomodulatory function of cyclophosphamide led to the elimination of inflammatory damages' origin, broader studies are needed.

One thing requiring change: there is no such drug as "fraxiparine" - do the authors mean nadroparin?

Is the background of the case's history and progression described in sufficient detail?

Yes

Are enough details provided of any physical examination and diagnostic tests, treatment given and outcomes?

Yes

Is sufficient discussion included of the importance of the findings and their relevance to future understanding of disease processes, diagnosis or treatment?

Yes

Is the case presented with sufficient detail to be useful for other practitioners?

Yes

Competing Interests: No competing interests were disclosed.

Reviewer Expertise: covid-19

I confirm that I have read this submission and believe that I have an appropriate level of expertise to confirm that it is of an acceptable scientific standard.

Author Response 03 Oct 2021

Kamila Bołtuć, Jan Kochanowski University, Kielce, Poland

Thank you so much for your review. In this particular case, we wanted to highlight the complexity of treatment in COVID-19 patients and present the difficulties associated with it. We are glad that this case report met your expectations and may be useful for other clinical practitioners. Additionally, thank you for finding an error with the drug. It should be Nadroparin and it will be changed.

Competing Interests: None

Reviewer Report 03 September 2021

<https://doi.org/10.5256/f1000research.59218.r92236>

© 2021 Clementi A. This is an open access peer review report distributed under the terms of the [Creative Commons Attribution License](#), which permits unrestricted use, distribution, and reproduction in any medium, provided the original work is properly cited.



Anna Clementi

Nephrology and Dialysis Department, Santa Marta and Santa Venera Hospital, Acireale, Catania, Italy

This case report is very well described. Both the patient's clinical history and progression are presented in a detailed way, as well as diagnostic tests and outcomes.

This is a case of p-ANCA (perinuclear anti-neutrophil cytoplasmic antibodies) vasculitis complicating COVID-19 in a 34-year-old Caucasian male with a history of borderline hypertension, hypothyroidism, and transient arthralgia 2 years prior admission.

The patient was admitted to the hospital because of fever, dyspnoea, haemoptysis, and bilateral pneumonia. Hospitalization was then complicated by acute kidney injury and alveolar haemorrhage. Due to his clinical history and progression, an antibody panel was carried out and a high titer of p-ANCA was found, suggesting another disease in addition to COVID-19. Chest computed tomography (CT) demonstrated the presence of both viral pneumonia and alveolar haemorrhage. A kidney biopsy revealed a rapidly progressing glomerulonephritis in the course of p-ANCA vasculitis. The patient was treated with remdesivir, antibiotics, corticosteroids, IV immunoglobulins, and hemodialysis, and plasmaphereses were performed as well. Also, cyclophosphamide treatment was initiated, despite being contraindicated in the case of COVID-19.

First of all, this case report highlights the importance of considering other diseases which can have a similar course to COVID-19. Furthermore, the choice of each treatment is reported in a reasonable and clear way. In particular, the introduction of immunosuppressive treatment with cyclophosphamide may have improved the patient's clinical condition by modifying the immune response to SARS-CoV-2.

I think this is a very interesting case report which can be very useful for clinicians, especially during this period of pandemic.

Is the background of the case's history and progression described in sufficient detail?

Yes

Are enough details provided of any physical examination and diagnostic tests, treatment given and outcomes?

Yes

Is sufficient discussion included of the importance of the findings and their relevance to future understanding of disease processes, diagnosis or treatment?

Yes

Is the case presented with sufficient detail to be useful for other practitioners?

Yes

Competing Interests: No competing interests were disclosed.

Reviewer Expertise: Nephrology

I confirm that I have read this submission and believe that I have an appropriate level of expertise to confirm that it is of an acceptable scientific standard.

Author Response 02 Oct 2021

Kamila Bołtuć, Jan Kochanowski University, Kielce, Poland

Thank you so much for this detailed review.

We tried to highlight the possibility of the COVID-19 concomitance with various diseases. Moreover, based on this case we wanted to demonstrate the complexity of treatment in COVID-19 patients.

We are glad that our case report met your expectations and due to sufficient detail may be useful for other clinicians.

Competing Interests: None

The benefits of publishing with F1000Research:

- Your article is published within days, with no editorial bias
- You can publish traditional articles, null/negative results, case reports, data notes and more
- The peer review process is transparent and collaborative
- Your article is indexed in PubMed after passing peer review
- Dedicated customer support at every stage

For pre-submission enquiries, contact research@f1000.com

F1000Research