

Fracture Union in Closed Interlocking Nail in Humeral Shaft Fractures

Ramji Lal Sahu, Rajni Ranjan, Ajay Lal

Department of Orthopaedics, SMS and RI Sharda University, Greater Noida, Uttar Pradesh, India

Abstract

Background: Fracture shaft humerus is a major cause of morbidity in patients with upper extremity injuries. The aim of this study was to evaluate the outcome of interlocking nail in humeral shaft fractures.

Methods: This study was conducted in the Department of Orthopedic Surgery in SMS and R Sharda University from January 2010 to November 2013. Seventy-eight patients were recruited from emergency and out-patient department having a close fracture of humerus shaft. All patients were operated under general anesthesia and closed reamed interlocking nailing was done. All patients were followed for 9 months.

Results: Out of 78 patients, 69 patients underwent union in 90–150 days with a mean of 110.68 days. Complications found in four patients who had nonunion, and five patients had delayed union, which was treated with bone grafting. All the patients were assessed clinically and radiologically for fracture healing, joint movements and implant failure. The results were excellent in 88.46% and good in 6.41% patients. Complete subjective, functional, and clinical recovery had occurred in almost 100% of the patients.

Conclusions: The results of the present study indicates that in the presence of proper indications, reamed antegrade intramedullary interlocked nailing appears to be a method of choice for internal fixation of osteoporotic and pathologic fractures.

Key words: Bone Grafting; Close Reamed Interlocking Nail; Humeral Shaft Fractures; Union

INTRODUCTION

Humeral shaft fractures account for 3–5% of all fractures.^[1-3] Nonoperative management has historically been the treatment of choice for many humeral shaft fractures; however in certain clinical scenarios these fractures may be well served by compression plating.^[4] It is advocated that compression plating offer the best treatment for humeral shaft fractures that require surgical intervention.^[5] However, the risks of any musculoskeletal procedure cannot be overlooked and in the case of compression plating include extensive dissection, iatrogenic radial nerve injury, an increased risk of infection, and nonunion. For these reasons, intramedullary (IM) fixation has become increasingly popular, offering load sharing biomechanics especially in osteoporotic bone. It is less invasive. IM devices such as ender nail failed to provide optimal rotational alignment.^[6] Interlocking screws addressed this problem, offering rotational control and length stability.^[7,8] There is considerable debate regarding the best method of treating humerus fractures. A method closely

approaching this perfection is IM interlocking nails. The objective of this prospective study is to achieve the ultimate goal of fracture union and early rehabilitation and good fracture healing response.

METHODS

This prospective study was carried out at Department of Orthopedic Surgery in SMS and R Sharda University from January 2010 to November 2013. The work was approved by institutional medical ethics committee. A total of 78 patients with fracture humerus admitted to our institute were included in the present study. A written informed consent was obtained from all the patients; they were explained about treatment plan, cost of operation, and hospital stay after surgery, complications of anesthesia.

Inclusion criteria

Patients with closed shoulder fracture with age more than 16 years and had presented within a week of the injury and did not have any previous surgical treatment for a fracture.

Exclusion criteria

Malnourished patients and those with open fractures, arterial injuries, nerve injuries, infected fractures.

Access this article online

Quick Response Code:



Website:
www.cmj.org

DOI:
10.4103/0366-6999.157630

Address for correspondence: Prof. Ramji Lal Sahu,
11284, Laj Building No. 1, Doriwalan, New Rohtak Road,
Karol Bagh, New Delhi, India
E-Mail: drrlsahu@gmail.com

Examination of patients was done thoroughly at the time of admission to exclude other injuries. In the majority of the patients close reamed interlocking nailing of the shoulder was performed within 7th to 14th day after the injury. In patients who were not fit for surgery due to associated injuries to vital organs, were hemodynamically unstable or due to active infection at injury site, or were pyrexial delayed interlocking nailing was performed when their over-all condition improved.

Technique of operation

All nailing procedures were performed under general anesthesia and image intensifier. The procedures were done in the supine position with the head rotated to contra lateral side on a radiolucent table. A longitudinal skin incision 1–3 cm centered over the tip of the greater tuberosity was given. An awl was passed just medial to the tip of the greater tuberosity, 0.5 cm posterior to biceptal groove to make an entry point. Close reduction was achieved under C-arm guidance and guidewire was passed, the length of the nail was measured by subtracting exposed guidewire from the total length of the guidewire. In two cases, where closed reduction failed minimum open reduction was done. While maintaining the reduction, guidewire was removed, and the nail of proper length and diameter was passed till its proximal end was beneath the bone by 0.5 cm to avoid subacromial impingement. Proximal and distal locking was done. The type of nailing is static antegrade interlocking nails. Postoperatively soft bulky dressings were used, and the limb was kept in shoulder arm pouch. Check X-ray was taken of the full humeral length. Patients were kept on antibiotic for 3–5 days depending upon the wound condition in most cases.

Rehabilitation

Passive range of motion exercises at shoulder and elbow were started on the 3rd postoperative day when pain and swelling had subsided. Regular antiseptic dressings were done, and the patients were discharged from 3rd to 5th postoperative day. Stitches were removed from 10th to 14th days postoperatively. Thereafter active ranges of motion exercises were started. Patients were followed-up every 4 weeks until 6 months, detailed examination and X-ray check were taken to see the progress of fracture healing. Radiological assessment was done to assess: Union, time of union (months), delayed union and nonunion. Union was said to have occurred when a mature callus formation bridging across the fracture on two radiographic views. Nonunion was said to have occurred when fracture had not achieved union by the end of 9 months [Table 1]. All radiologically united fractures were finally assessed at the end of 9 months clinically and functionally. Clinical assessment was based on severity of pain in operated limb and active range of motion of shoulder and elbow, functional assessment was done as per system of American Shoulder and Elbow Surgeons shoulder score as adopted by McCormack *et al.*^[9] They were followed-up after surgery, they were clinically and radiologically assessed for fracture healing, joint movements and implant failure.

According to the criteria the results are graded as excellent when the fractures unites within 16 weeks without any complication, good when union occur within 24 weeks with treatable complications like superficial infection and shoulder stiffness and poor when union occur before or after 24 weeks with one or more permanent complications like infection (osteomyelitis), implant failure, nonunion, limb shortening and permanent shoulder stiffness [Table 2]. Follow-up was done according to these criteria. As part of a subjective assessment, patients were asked in the questionnaire if they were very satisfied, satisfied or not satisfied with the outcome of treatment.

RESULTS

There were 78 patients in this study, out of 100% (78/78), 83.33% (65/78) patients were male and 16.66% (13/78) patients were females. Humeral fractures at middle one-third were 66.66% (52/78), at proximal one-third were 15.38% (12/78) and at distal one-third were 17.94% (14/78). The patients were divided into three groups according to their age for simplicity. Young age group included those patients whose age was < 40 years. In this group, there were 8.97% (7/78) females and 57.69% (45/78) males. Middle age group included patients, who were between the ages of 40 and 60 years. This group included 6.41% (5/78) females and 19.23% (15/78) males. Old age group included patients older than 60 years [Tables 3 and 4]. This group consisted of 1.28% (1/78) female and 6.41% (5/78) males. Below the age of 40 years, 23.07% (18/78) patients were transverse, 17.94% (14/78) were oblique, 20.51% (16/78)

Table 1: Percentage of cases who had unions, malunions, delayed unions, or nonunions (N = 78)

Items	n	Percentage (%)
Union	69	88.46
Nonunion	4	5.12
Delayed union	5	6.41
Malunion	0	0

Table 2: Outcomes of results of interlocking nails (N = 78)

Outcomes	n	Percentage (%)
Excellent	69	88.46
Good	5	6.41
Poor	4	5.12

Table 3: Age and sex variations in study group (N = 78)

Age	Male (n)	Female (n)	Total (n)
Less than 40	45	7	52
40–60	15	5	20
More than 60	5	1	6
Total	65	13	78

were spiral, 2.56% (2/78) were spiral wedge, 1.28% (1/78) were bending wedge and 1.28% (1/78) were fragmented wedge. Between the age of 40 and 60 years, 8.97% (7/78) patients were transverse, 6.41% (5/78) were oblique and 10.25% (8/78) were spiral fractures. Above the age of 60 years, 1.28% (1/78) was spiral fractures, 3.84% (3/78) were oblique, and 2.56% (2/78) were transverse fractures.

About 6.41% (5/78) patients were diabetics and 5.12% (4/78) of them were taking insulin. 1.28% (1/78, one female) patient was diabetic and was taking oral hypoglycemic. All the patients were assessed clinically and radiologically for fracture healing, joint movements and implant failure. The clinical results of our study were rated on the basis of the criteria of union, nonunion, delayed union or malunion. The patients were followed according to their clinical status. 88.46% (69/78) patients had union in 90–150 days with a mean of 110.68. Union was achieved in 10.25% (8/78) patients in 95–109 days with a mean of 103.38. All of our patients had full range of motion of their shoulders and elbows. 15.38% (12/78) patients had a significant restriction of shoulder movements, which was resolved in 4 weeks after guarded physiotherapy. 3.84% (3/78) patients out of 100% (78/78) complained postoperative shoulder pain, which was spontaneously resolved in 2 weeks. The screw of less critical stability was determined (the screw that was away from the fracture) and it was removed in local anesthesia. There were 6.41% (5/78) delayed unions that were treated by bone graft. In our study, only 5.12% of our patients was labeled as nonunion and was treated by bone graft. The results were excellent in 88.46% (69/78) and good in 6.41% (5/78) patients [Figures 1a and b, 2a and b, Tables 1 and 2]. At 9 months, complete subjective, functional, and clinical recovery had occurred in almost 100% of the patients. In subjective overall assessment 88.46% (69/78), patients were fully satisfied, and 6.41% (5/78) were satisfied with the outcome of treatment.

Table 4: Site of humeral fracture (N = 78)

Humeral site	n	Percentage (%)
Proximal one-third	12	15.38
Middle one-third	52	66.66
Distal one-third	14	17.95

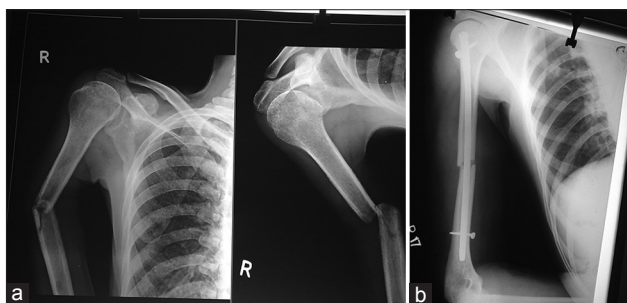


Figure 1: (a) Preoperative radiograph of fracture shaft of humerus of 40-year-old man; (b) Postoperative radiograph showing fracture fixation with interlocking nail.

DISCUSSION

A series of 78 cases of fracture shaft humerus treated by closed interlocked IM nailing were studied, which included 66 fresh fractures, 2 nonunion's, 16 pathological fractures and 10 delayed unions. The youngest patient was 18 years old, and oldest was 79 years old. Most of the patients were adults between the ages 20 and 40 years (66%). The commonest mode of injury was road traffic accidents (50%). The antegrade approach was used in all 78 cases, and all nails were inserted with reaming. Totally, 13 of the patients had associated injuries involving the axial and appendicular skeleton, other organs and viscera. One case had a superficial infection that healed with sterile dressing and antibiotics after culture and sensitivity. Twelve patients had a significant restriction of shoulder movements while 4% had elbow stiffness with no functional loss. The final functional outcome is good to excellent. Several reports have demonstrated that with newer implants and improved techniques, locked IM nailing can achieve a success rate as high as that of the other methods.^[10] In these studies, the incidence of nonunion is approximately 6%, the incidence of infection is 2%, and the incidence of radial nerve palsies is 3%. The nails are subjected to lower bending forces, making failure by fatigue less likely to occur.^[11] In our center, we routinely perform the locking in static mode. In this study, all the fractures were treated with statically locked IM nail. Sixty-nine out of 78 patients was united without any complication. Ten of our patients needed bone grafting. Five patients showed no radiological signs of union at 4th month. They were treated with bone grafting. One had comminution at fracture site; He was treated with bone graft. In our study, union rate is 88.46%, which is very close to the reported series. This result is comparable to the union rate achieved by McCormack *et al.* (89.48%),^[9] Cox *et al.* (87.9%),^[13] Crates and Whittle (94.5%),^[14] Robinson *et al.*^[15] and Hems and Bhullar^[16] reported nonunion rate of 23% and 29% respectively after Seidel's interlocking nailing. In our study four patients (5.12%) developed

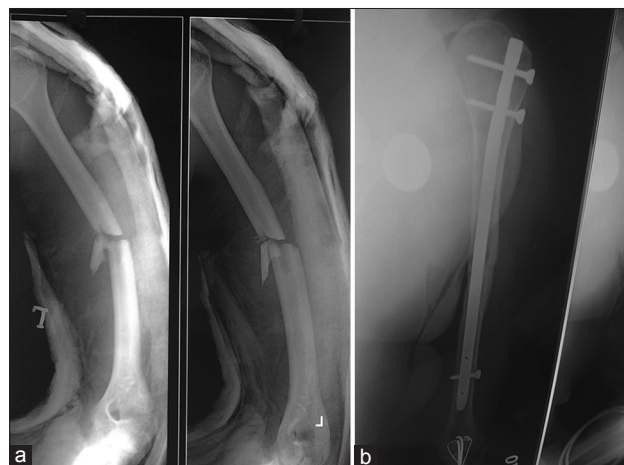


Figure 2: (a) Preoperative radiograph of fracture shaft of humerus of 46-year-old man; (b) Postoperative radiograph showing fracture fixation with interlocking nail.

nonunion, which we attribute to distraction at the fracture site. We believe that the distraction at the fracture site may be prevented during antegrade nailing by pushing or thumping at elbow after proximal locking. Once the distraction and rotations are corrected by thumping distal locking should be done. In our study union occurred in 90–150 days with a mean of 110.68 days that is very close to other studies. In our study, we did nailing after reaming the canal. This is a routine protocol in our center. There is reported literature, which shows increased blood loss, increased operating time, increased risk of pulmonary embolism and adult respiratory distress syndrome after reamed interlocking nail. We have a reasonable policy to wait and stabilize the patient who has certain risk factors such as associated chest trauma etc. When the patient is stable and fit for surgery, we perform close reamed statically locked IM nail. The functional outcome of patients with humeral shaft fracture is probably the most important consideration when deciding on the best mode of treatment for a particular fracture pattern. Twelve (15.38%) of our patients had mild shoulder stiffness at final follow-up. Shoulder stiffness is a significant problem in antegrade nailing, which can be minimized if care is taken to prevent the proximal protrusion of the nail and repair the rotator cuff properly. However, we agree with Rommens *et al.*^[7] that retrograde nailing will preserve shoulder function. We have not seen radial nerve palsy during surgery. Moran^[17] recommend open technique while passing distal interlocking screw from the lateral aspect of the humerus to avoid injury to the radial nerve and posterior coetaneous nerve of forearm. We encountered no such problem as we locked the nail with distal interlocking screw from anterior to posterior direction. McCormack *et al.*^[9] reported 14.2% of his patients developing radial nerve palsy, mostly neuropraxia, with full recovery in the postoperative period. Hems and Bhullar^[16] reported 9.5% radial nerve palsy during manipulative reduction of distal third fractures and claimed full recovery in his patients. Garnavos^[18] had proposed the aiming to improve outcomes include the categorization of humeral nails in two distinct groups: “Fixed” and “bio,” avoidance of reaming for the antegrade technique and utilization of “semi-reaming” for the retrograde technique, guidelines for reducing complications, setting the best “timing” for nailing and criteria for selecting the most appropriate surgical technique. Heineman *et al.*^[19] conclude that the current literature continues to favor plates over IM nails in humeral shaft fractures in the reduction of complication rates. However, the precision of our estimate is markedly improved (confidence interval [CI] = 0.41–0.97 instead of CI = 0.30–0.91). We have to remark though that the significance is a bit less than it was in 2010 ($P = 0.03$ instead of $P = 0.01$). Regarding our secondary outcomes there still is no significant difference between nails and plates. Carroll *et al.*^[20] had stated that a relatively high incidence of radial nerve injury has been associated with surgical management of humeral shaft fractures. van Middendorp *et al.*^[21] stated that the nonoperative management of humeral midshaft fractures could be expected to have similar functional outcomes and patient satisfaction at 1-year, despite an early

benefit to operative treatment. If no radiological evidence of fracture healing exists in nonoperatively treated patients during early follow-up, a switch to surgical treatment results in good functional outcomes and patient satisfaction. The results of the present study indicate that in the presence of proper indications, reamed antegrade IM interlocked nailing appears to be a method of choice for internal fixation of osteoporotic and pathologic fractures.

A potential limitation of our study was the absence of a control group treated by a different modality. Thus, we cannot actually determine if any other method of treatment would have led to different results. Nevertheless, our results are better than those of the previous studies in which other nails or plates have been used.

In conclusion, the IM fixation is a simple technique with minimal exposure and shorter operative time with less blood loss. The preservation of fracture hematoma, soft tissue and periosteum around the fracture that occurs with close nailing has been proposed for high rates of union and good results, with no risk of iatrogenic radial nerve palsy. Humeral nailing is associated with early return to function of the extremity, low infection rates and also very good pain relief in pathological fractures. It is an acceptable alternative for the treatment of acute humeral shaft fractures in multiple injured patients.

REFERENCES

1. Williams GR, Ramsey ML, Wiesel SW. Operative Techniques in Shoulder and Elbow Surgery. Philadelphia: Lippincott Williams and Wilkins; 2010.
2. Bodner G, Buchberger W, Schocke M, Bale R, Huber B, Harpf C, *et al.* Radial nerve palsy associated with humeral shaft fracture: Evaluation with US – initial experience. *Radiology* 2001;219:811-6.
3. Shao YC, Harwood P, Grotz MR, Limb D, Giannoudis PV. Radial nerve palsy associated with fractures of the shaft of the humerus: A systematic review. *J Bone Joint Surg Br* 2005;87:1647-52.
4. Sarmiento A, Zagorski JB, Zych GA, Latta LL, Capps CA. Functional bracing for the treatment of fractures of the humeral diaphysis. *J Bone Joint Surg Am* 2000;82:478-86.
5. Niall DM, O’Mahony J, McElwain JP. Plating of humeral shaft fractures – has the pendulum swung back? *Injury* 2004;35:580-6.
6. Brumback RJ, Bosse MJ, Poka A, Burgess AR. Intramedullary stabilization of humeral shaft fractures in patients with multiple trauma. *J Bone Joint Surg Am* 1986;68:960-70.
7. Rommens PM, Verbruggen J, Broos PL. Retrograde locked nailing of humeral shaft fractures. A review of 39 patients. *J Bone Joint Surg Br* 1995;77:84-9.
8. Ingman AM, Waters DA. Locked intramedullary nailing of humeral shaft fractures. Implant design, surgical technique, and clinical results. *J Bone Joint Surg Br* 1994;76:23-9.
9. McCormack RG, Brien D, Buckley RE, McKee MD, Powell J, Schemitsch EH. Fixation of fractures of the shaft of the humerus by dynamic compression plate or intramedullary nail. A prospective, randomised trial. *J Bone Joint Surg Br* 2000;82:336-9.
10. Mückley T, Diefenbeck M, Sorkin AT, Beimel C, Goebel M, Bühren V. Results of the T2 humeral nailing system with special focus on compression interlocking. *Injury* 2008;39:299-305.
11. Beaty JH. Humeral shaft fractures. In: *Orthopaedic Knowledge Update*. Rosemont, Ill: American Academy of Orthopaedic Surgeons; 1999:278-86.
12. Gregory PR, Sanders RW. Compression plating versus intramedullary fixation of humeral shaft fractures. *J Am Acad Orthop Surg* 1997;5:215-23.
13. Cox MA, Dolan M, Synnott K, McElwain JP. Closed interlocking

- nailing of humeral shaft fractures with the Russell-Taylor nail. *J Orthop Trauma* 2000;14:349-53.
14. Crates J, Whittle AP. Antegrade interlocking nailing of acute humeral shaft fractures. *Clin Orthop Relat Res* 1998; (350):40-50.
 15. Robinson CM, Bell KM, Court-Brown CM, McQueen MM. Locked nailing of humeral shaft fractures. Experience in Edinburgh over a two-year period. *J Bone Joint Surg Br* 1992;74:558-62.
 16. Hems TE, Bhullar TP. Interlocking nailing of humeral shaft fractures: The Oxford experience 1991 to 1994. *Injury* 1996;27:485-9.
 17. Moran MC. Distal interlocking during intramedullary nailing of the humerus. *Clin Orthop Relat Res* 1995; (317):215-8.
 18. Garnavos C. Diaphyseal humeral fractures and intramedullary nailing: Can we improve outcomes? *Indian J Orthop* 2011;45:208-15.
 19. Heineman DJ, Bhandari M, Poolman RW. Plate fixation or intramedullary fixation of humeral shaft fractures – an update. *Acta Orthop* 2012;83:317-8.
 20. Carroll EA, Schweppe M, Langfitt M, Miller AN, Halvorson JJ. Management of humeral shaft fractures. *J Am Acad Orthop Surg* 2012;20:423-33.
 21. van Middendorp JJ, Kazacsay F, Lichtenhahn P, Renner N, Babst R, Melcher G. Outcomes following operative and non-operative management of humeral midshaft fractures: A prospective, observational cohort study of 47 patients. *Eur J Trauma Emerg Surg* 2011;37:287-96.

Received: 23-10-2014 **Edited by:** Xiu-Yuan Hao

How to cite this article: Sahu RL, Ranjan R, Lal A. Fracture Union in Closed Interlocking Nail in Humeral Shaft Fractures. *Chin Med J* 2015;128:1428-32.

Source of Support: Nil. **Conflict of Interest:** None declared.