

Submitted:
02.11.2019
Accepted:
07.12.2019
Published:
31.12.2019

Color Doppler ultrasound of spiral artery blood flow in mid first trimester (4–8 weeks) in cases of threatened abortion and in normal pregnancies

Rohit Bhoil¹, Sushruti Kaushal², Reena Sharma², Jaswinder Kaur³,
Tanupriya Sharma², Rohini Thakur¹, Rakesh Sharma¹

¹ Department of Radiodiagnosis, SLBS Mandi, Himachal Pradesh, India

² Department of Obstetrics and Gynaecology, SLBS Mandi, Himachal Pradesh, India

³ Department of Community Medicine, SLBS Mandi, Himachal Pradesh, India

Correspondence: Rohit Bhoil, Department of Radiodiagnosis, SLBS Mandi (HP), India; tel.: +91-9418021905, e-mail: rohitbhoil@gmail.com

DOI: 10.15557/JoU.2019.0038

Keywords

uterine circulation,
trans-vaginal
ultrasound,
sonography,
spiral artery,
miscarriage

Abstract

Introduction: The aim of the study was to evaluate and compare the spiral artery flow in mid first trimester (4–8 weeks) in cases of threatened abortion and in normal pregnancies. **Material and methods:** Spiral artery was sonographically evaluated in 50 patients comprising two groups of 25 women each. The first group included patients presenting with threatened miscarriage (vaginal bleeding/spotting with or without abdominal pain). The second group comprised of females who had no complications, but had no desire to continue the pregnancy. Spiral artery flow velocity measurements were performed using Color Doppler (Pulsatility Indices, Resistive Indices and Systolic/diastolic values) in mid first trimester (between 4–8 weeks of gestation), each measurement was performed twice. Statistical analysis was performed using Statistical package for social sciences software. Values were rounded off to two digits after decimal point. **Results:** Significant differences were noted in the spiral artery Doppler values in the two groups. In particular, the Resistive Indices was higher in cases of women with threatened miscarriage. The difference in Pulsatility Indices was also statistically significant between the two groups. **Conclusion:** Doppler values of spiral artery may be used as a useful parameter in assessing the prognosis in cases presenting with threatened miscarriage.

Introduction

Threatened miscarriage is a clinical term for vaginal bleeding that occurs during the first 20 weeks of pregnancy where fetus is clinically supposed to be alive. This bleeding may or may not be associated with abdominal pain. About 1/5 of all pregnant females present with symptoms of threatened abortion in the first trimester and almost half of the women with threatened abortion result in pregnancy loss⁽¹⁾. Even women with threatened abortion and a living embryo have increased chances of pregnancy loss up-to 15% when compared with general population^(1,2). Due to the high prevalence of spontaneous miscarriage in this group of patients,

a method that could predict pregnancy outcome in early gestation would be of great clinical advantage.

The introduction of high-frequency transvaginal color Doppler ultrasonography with spectral analysis has allowed evaluation of uteroplacental circulation in early pregnancy, abnormalities of which have been linked to pregnancy complications such as hypertension, intrauterine growth restriction (IUGR), fetal distress, and early pregnancy failure^(2–4). The ability of trans-vaginal Doppler sonography to analyze the pattern of circulation in even terminal branches of the uteroplacental circulation has encouraged research for its potential application in predicting early and late

pregnancy complications related to abnormal placentation. Impaired vascular remodeling in the maternal fetal interface is one of the most important factors associated with early and late complications in pregnancy^(3,5-7). It is now widely accepted that the most common complications of pregnancy arise due to abnormalities in early trophoblast invasion and persistently increased resistance of the spiral arteries⁽²⁻⁵⁾. The purpose of this study was to demonstrate whether the possible modifications in blood flow patterns in spiral arteries can be picked up on trans-vaginal Doppler sonography and to investigate whether these Doppler findings could predict adverse pregnancy outcomes.

Patients and methods

This was a cross-sectional study performed between October 2017 and July 2018.

Criteria of selection

Pregnant women (positive urinary pregnancy test) with age less than 35 years, presenting in mid first trimester, i.e. 4–8 weeks, with threatened miscarriage (vaginal bleeding/spotting with or without abdominal pain) and with unremarkable medical history were included in the study. Only women with a single intra-uterine gestational sac visualized on real-time abdominal/trans-vaginal ultrasound were included. The gestational age was calculated on the basis of the duration of amenorrhea (weeks/days). Control group comprised of pregnant females with no complaints and who had had no desire to continue the pregnancy.

Exclusion criteria

The following patients were excluded from the study:

- patients who did not know or were not sure of their last menstrual period or had history of irregular menstrual cycle in the last 6 months;
- patients with a history of molar pregnancy or with previous 2 or more consecutive pregnancy losses;
- patients with ectopic pregnancy;
- patients with uterine pathology like malformations or fibroids; a vaginal or cervical lesion visualized clinically that could be the cause of the vaginal bleeding;
- patients in whom spiral artery could not be reliably evaluated and/or patients in whom examination could not be completed within 10 minutes.

Number of patients

Of the 86 patients considered; the study was conducted among 50 eligible pregnant females comprising two groups of 25 each. The first group – Group 1 ($n = 25$) comprised of women presenting with threatened miscarriage (vaginal bleeding/spotting with or without abdominal pain); the second group – Group 2 ($n = 25$) comprised of pregnant

females with no complaints and who had requested termination of pregnancy for various psychosocial reasons. Written informed consent was obtained from each patient who met the eligibility criteria and was included in the study.

Ultrasound/Doppler evaluation

All sonographic procedures were performed using a Siemens Acuson X300 ultrasound machine (Siemens Ultrasound, Munich, Germany) equipped with a real time 6.0 MHz endovaginal probe.

Before the examination, the women were asked to empty their urinary bladder. After gently inserting the trans-vaginal probe into the vagina, the uterus and adnexae were scanned to confirm the presence of intrauterine gestational sac.

Uterine spiral arteries were assessed by triplex mode examination (gray scale image combined with color Doppler and a flow spectrum on the spectral wave). Spiral arteries just beneath the chorion frondosum were assessed by power Doppler imaging (Fig. 1). Flow velocity waveforms were obtained by placing the Doppler gate over the colored areas and activating the pulsed-wave Doppler function. The pulsed Doppler sample volume was set at a width of 2 mm. The high-pass filter was set at 50 Hz. Mechanical index (MI) was 0.82 and thermal index for soft tissues (TIs) was 0.7.

Systolic/diastolic (S/D) ratio, resistance (RI) and pulsatility indices (PI) were calculated automatically by using the software program in the machine (Fig. 2; Fig. 3, and video recording – available at www.jultrason.pl). The average of the respective values from two consecutive flow velocity waveforms obtained from the spiral arteries was calculated. All sonographic procedures were performed by the same investigator to avoid inter-observer variations.

Statistical analysis

We used Statistical Package for Social Sciences (SPSS) 16.0 for Windows for the statistical analysis of the data obtained. Continuous variables of normally distributed data were analyzed using paired t-test at 0.05 level of significance.

Results

The mean age of the patients was 26.8 years, with a range of 16–35 years (Fig. 4). No significant difference was seen between the two groups regarding patients' age or body mass index (BMI).

The mean gestational age was 6 weeks 5 days (Fig. 5).

The RI, PI and S/D values were normally distributed, and were analyzed by using paired t test. A p -value of less than 0.05 was taken as statistically significant. The mean values of RI and PI were 0.48 and 0.72 in the threatened abortion

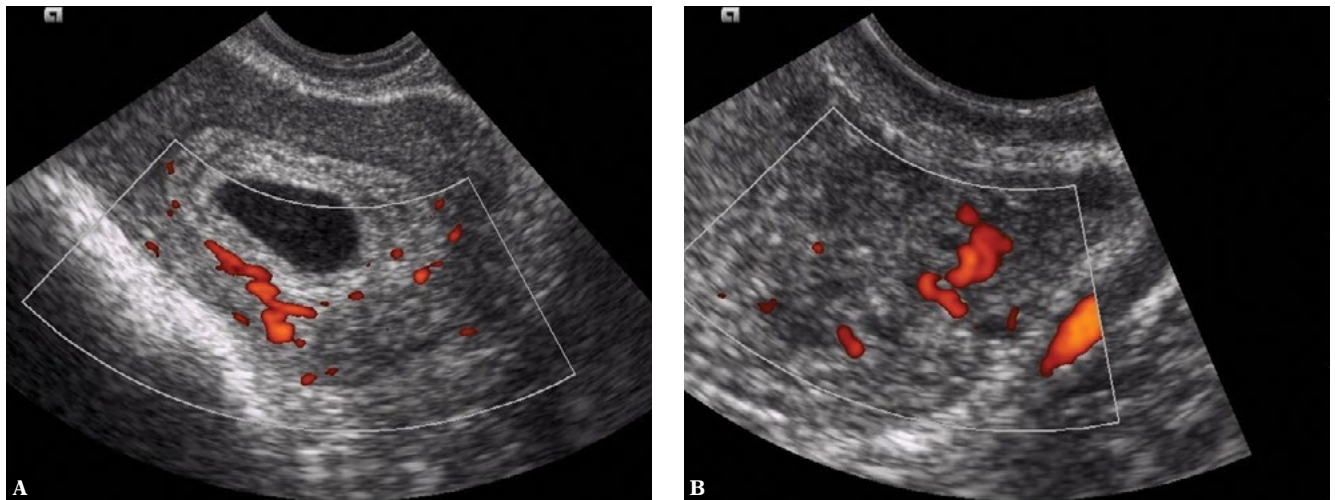


Fig. 1. Power Doppler images showing the spiral arteries in **A.** threatened abortion at 5 weeks; **B.** normal case at 4 weeks 5 days

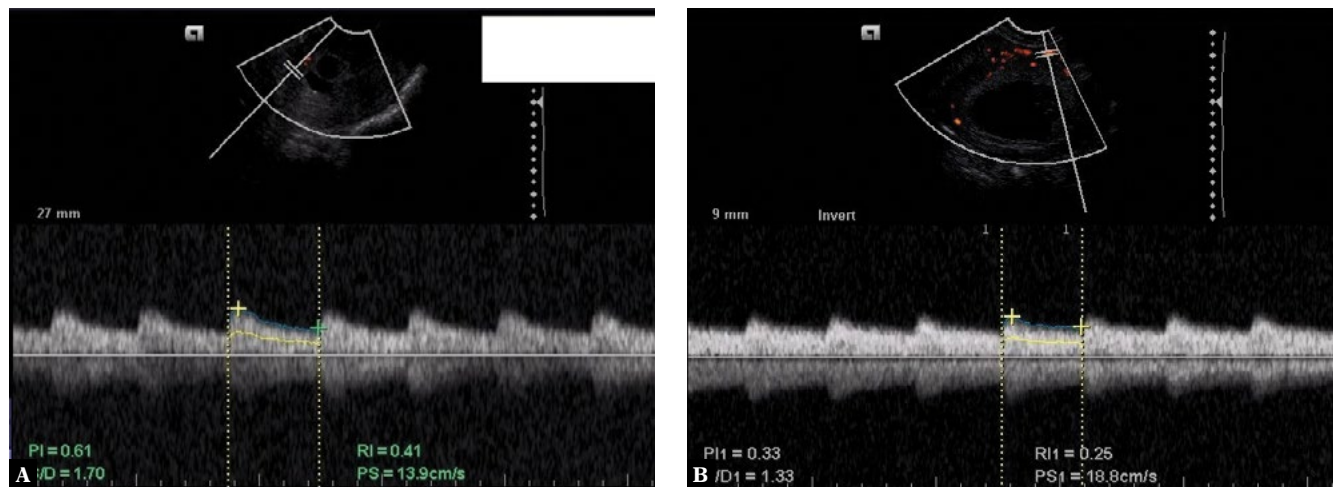


Fig. 2. Power Doppler waveform showing the spiral arteries flow pattern in **A.** case of threatened abortion at 5 weeks 2 days; **B.** normal case at 6 weeks

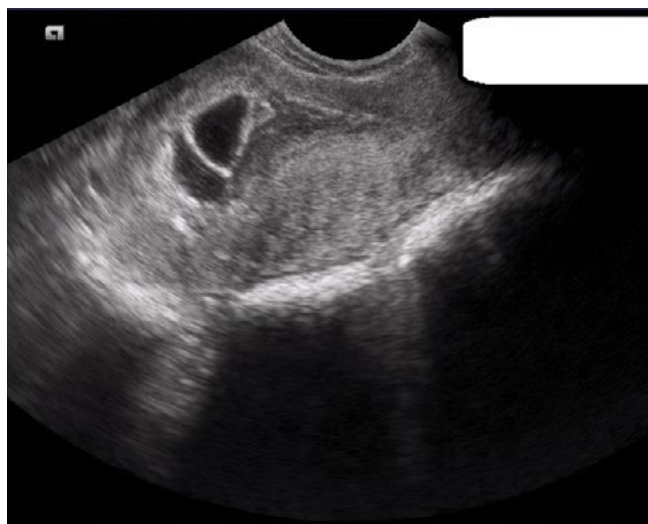

Fig. 3. Gray scale TVS (Trans-vaginal sonography) image of a patient presenting with pain lower abdomen and vaginal bleeding at 5 wk 2 days. (Video clip shows the corresponding power Doppler tracing)

group and 0.25 and 0.41 in the normal control group (Tab. 1). The difference in the RI and PI values in both the groups was statistically significant. However the difference in the S/D values between the two groups was not statistically significant (p value = 0.147).

Fig. 6 and Fig. 7 depict the distribution of PI and RI values in the two groups.

Table 1 summarizes the various demographic and Doppler indices in the two groups.

Each examination (ultrasound and Doppler examination) took about 5–8 minutes.

Discussion

Successful pregnancy depends upon the unhindered to and fro transfer of oxygen, nutrients and wastes in-between the maternal and fetal compartments. Crucial to this is

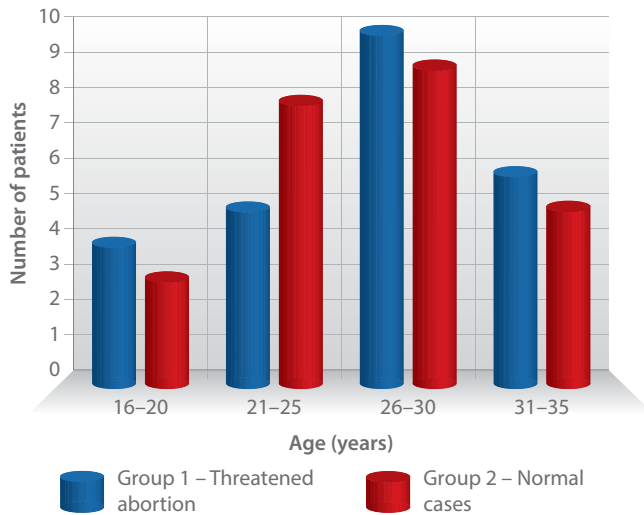


Fig. 4. Graphical representation of age of the patients in the two groups

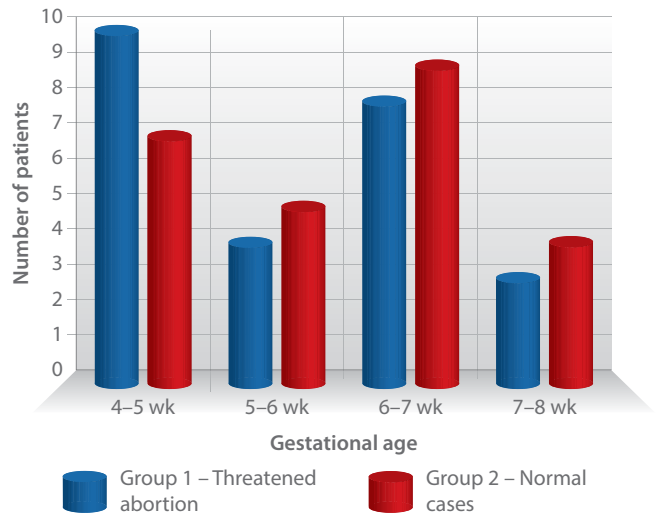


Fig. 5. Distribution by gestational age

the normal development of the uteroplacental circulation space in early pregnancy for which successful trophoblastic invasion of the maternal decidua, myometrium and the blood vessels is required^(2–5). During this process, the wall of the blood vessels, particularly the spiral arteries, are invaded by migrating extravascular trophoblast cells causing their progressive dilatation and delivery of blood to the intervillous space at even low pressures, thus ensuring adequate perfusion at all times. Any defect/deficiency in this normal process is implicated in many of the complications seen in pregnancy, such as early pregnancy failure, preeclampsia, intra-uterine growth restriction (IUGR), small for gestational age (SGA) fetuses. The role of spiral artery hemodynamics in the etiopathogenesis of infertility is well established in literature^(8,9). Uysal *et al.*⁽¹⁰⁾ have reported that that impedance of spiral artery blood flow in women with unexplained infertility was significantly higher than that of the fertile counterparts.

Histological studies have shown that in normal pregnancies with successful trophoblastic invasion, the trophoblastic cells extend into the decidual and myometrial segments, modifying the spiral arteries from small-caliber vasoreactive vessels into low-resistance, wide calibre vessels, thus supplying high amounts of blood to the placenta^(7,11–13).

With this in mind, researchers have sought to use ultrasound to evaluate the earliest signs of increased placental resistance with the aim of identifying pregnancies which are at highest risk for the development of these pathologies. It would be highly desirable to develop a screening method that would identify at-risk women before the second phase of placental development, when therapeutic intervention may still be useful. Studies have shown reduced rates of various complications like pre-eclampsia and IUGR when at-risk patients are put on aspirin treatment before 16 weeks of gestation, whereas similar interventions in later pregnancy has not been shown to alter these outcomes^(4,11,14).

Uteroplacental circulation is the earliest to be affected in pregnancy with demonstrable changes from week 4 onward⁽¹⁵⁾. Transvaginal Doppler ultrasound is a non-invasive and widely available screening method for disorders of placental function early in pregnancy and may be used to predict a number of obstetric complications that can be linked to defective placentation and implantation.

We carried out this study to demonstrate whether the possible modifications in blood flow patterns in spiral arteries can be picked up on trans-vaginal Doppler sonography carried in the mid first trimester (4–8 weeks) and to investigate whether these Doppler findings could predict adverse pregnancy outcome.

Ozkaya *et al.*⁽¹⁶⁾ in 2007 carried out Doppler sonographic examination of uteroplacental circulation in 105 pregnant women at 6–12 weeks of gestation with the aim to determine whether spectral Doppler measurements obtained from bilateral uterine, arcuate, radial, and spiral arteries in early gestation correlate with adverse pregnancy outcome. They found that PI and RI values were significantly higher in right uterine artery in females with adverse pregnancy outcomes than in women with normal obstetric outcome. Spiral artery PI and RI values were also higher, but the difference was not statistically significant. They concluded that transvaginal Doppler examination (in early pregnancy) can detect hemodynamic changes in uteroplacental circulation associated with subsequent adverse pregnancy outcomes.

In 2006, Nagy and Gardo⁽¹⁷⁾ compared spiral artery Doppler parameters between two groups (each comprising 30 patients) with complicated and uncomplicated pregnancies 8–12 weeks gestation. They found that the peak systolic velocity, the resistance index and also the pulsatile index were significantly higher in the complicated pregnancy group as compared to the normal control group. They advocated the use of spiral artery Doppler investigation for the noninvasive assessment of disturbances of trophoblast invasion in early pregnancy.

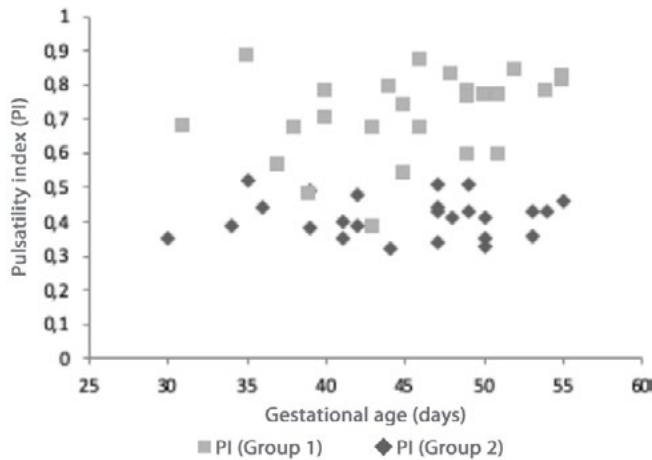


Fig. 6. Scatter diagram depicting the distribution of PI values in the two groups

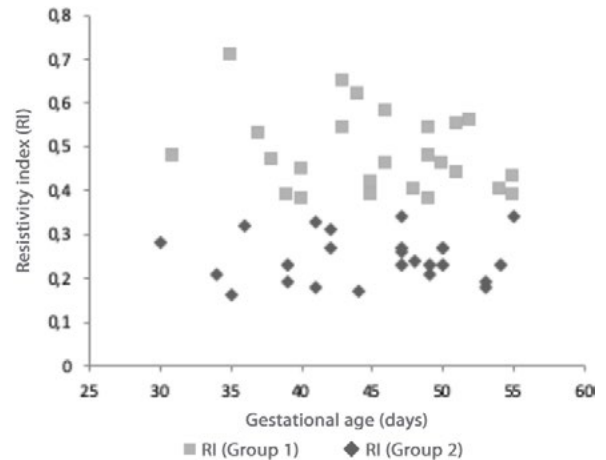


Fig. 7. Scatter diagram depicting the distribution of RI values in the two groups

The findings of our study (Tab. 1) support the use of spiral artery Doppler investigation (transvaginal) for the non-invasive evaluation of disturbances of trophoblastic invasion in early pregnancy (4–8 weeks). The results suggest that the both the pulsatility index (PI) as well as resistance index (RI) are significantly higher in patients presenting with features of threatened miscarriage as compared to those with uncomplicated pregnancies. These findings are in accordance with the ones in literature^(16–19). Hence the authors are of the opinion that Doppler investigation of spiral arteries may be a useful, non-invasive assessment of impaired trophoblast invasion in early pregnancy (4–8 weeks) in cases presenting with threatened miscarriage.

It will be worthwhile to mention that pulsed Doppler ultrasonography is technically difficult, especially with small vessels like spiral arteries and the procedure is operator-dependent⁽¹⁰⁾. This may be a limiting factor for its widespread use in routine clinical practice. In our study, all sonographic examinations were performed by the same investigator to avoid inter-observer variations.

Safety of Doppler in early pregnancy: Though no proven untoward effects have been associated with obstetric diagnostic ultrasound, it has generally been advised not to use Doppler in the first trimester due to concerns over possible thermal effects in the developing embryo/fetus unless specifically indicated^(20–23). To address this ethical issue of using Doppler ultrasound in normal pregnancies, all normal controls in our study were pregnant females (Group 2) who had requested for termination of pregnancy for various psychosocial reasons. Nonetheless, it is of vital importance to use control settings that keep thermal and mechanical indices as low as is feasible for achieving diagnostically useful information and in compliance with national and/or international regulations^(24–27). Additionally, ultrasound time should be limited and the ‘as low as reasonably achievable (ALARA)’ principle followed at all times. During the ultrasonographic examination procedures in our study, mechanical index (MI) was set at 0.82

and thermal index for soft tissues (TIs) was set at 0.7; these values are in accordance with the recommendations of the The British Medical Ultrasound Society Guidelines⁽²⁸⁾ for the safe use of diagnostic ultrasound equipment. Furthermore we excluded patients in whom examination could not be completed within 10 minutes to avoid prolonged exposure.

Limitations of our study

- Small sample size. Total number of patients were 50 (25 in each group). The number of patients was relatively low to uniformly extrapolate the results.
- We did not include/exclude anembryonic pregnancies in our study.

Therefore there is a need for more prospective study/(ies) that include a larger number of patients to better understand the biological significance of these results.

Tab. 1. The mean values of age, BMI, and spiral artery Doppler indices (S/D ratio, RI and PI) in threatened abortion group (Group 1) and in control group comprising normal pregnant females with no complaints (Group 2)

Parameter	Group I (n = 25) Mean ± SD	Group II (n = 25) Mean ± SD	p-value
Age	27.45 ± 3.27	26.72 ± 4.83	0.241
BMI	23.52 ± 2.37	24.63 ± 2.91	0.633
S/D ratio	1.82 ± 0.12	1.77 ± 0.24	0.147
RI	0.48 ± 0.08	0.25 ± 0.05	0.003 (significant)
PI	0.72 ± 0.04	0.41 ± 0.06	0.041 (significant)

BMI – body mass index; S/D – systolic to diastolic ratio; RI – resistance index; PI – pulsatility index; SD – standard deviation

Conclusions

In our study, we observed that despite similar demographic parameters in both groups, spiral artery PI and RI values in women presenting with vaginal bleeding were significantly higher than in normal control females. We concluded that transvaginal color Doppler sonography may be used to evaluate spiral arterial blood flow dynamics in early pregnancy (4–8 weeks gestation). Despite some technical limitations in assessing tiny vessels, like spiral arteries, and sonography being a highly operator-dependent procedure, this is a promising technique in assessing spiral arterial hemodynamic changes in early pregnancy, especially in high-risk patients. To increase the sensitivity to low blood flow in these tiny vessels, power Doppler may be more helpful. However, further studies are necessary to

clarify the biological significance of these observations and their clinical implications.

Conflict of interest

Authors do not report any financial or personal connections with other persons or organizations, which might negatively affect the contents of this publication and/or claim authorship rights to this publication.

All procedures were in accordance with the ethical standards of the responsible committee on human experimentation (institutional and national) and with the Helsinki Declaration of 1975, as revised in 2000. No animals were used during the study.

References

- Alcázar JL, Ruiz-Perez ML: Uteroplacental circulation in patients with first-trimester threatened abortion. *Fertil Steril* 2000; 73: 130–135.
- Deurloo KL, Spreuwenberg MD, Bolte AC, Van Vugt JM: Color Doppler ultrasound of spiral artery blood flow for prediction of hypertensive disorders and intra uterine growth restriction: a longitudinal study. *Prenat Diagn* 2007; 27: 1011–1016.
- Vahanian SA, Vintzileos AM: Placental implantation abnormalities: a modern approach. *Curr Opin Obstet Gynecol* 2016; 28: 477–484.
- Gebb J, Dar P: Colour Doppler ultrasound of spiral artery blood flow in the prediction of pre-eclampsia and intrauterine growth restriction. *Best Pract Res Clin Obstet Gynaecol* 2011; 25: 355–366.
- Mäkilä K, Tekay A, Jouppila P: Uteroplacental hemodynamics during early human pregnancy: a longitudinal study. *Gynecol Obstet Invest* 2004; 58: 49–54.
- Moser G, Huppertz B: Implantation and extravillous trophoblast invasion: From rare archival specimens to modern biobanking. *Placenta* 2017; 56: 19–26.
- Nanaev AK, Kosanke G, Kemp B, Frank HG, Huppertz B, Kaufmann P: The human placenta is encircled by a ring of smooth muscle cells. *Placenta* 2000; 21: 122–125.
- Practice Committee of the American Society for Reproductive Medicine: Effectiveness and treatment for unexplained infertility. *Fertil Steril* 2006; 86: S111–114.
- Düzgüner S, Ozkan MB, Küçüközkan T, Ozkaya E, Kara F, Balın IN *et al.*: Role of spiral artery Doppler to screen type 2 endometrial cancer cases. *J Turk Ger Gynecol Assoc* 2014; 15: 1–5.
- Uysal S, Ozbay EP, Ekinci T, Aksüt H, Karasu S, Işık AZ *et al.*: Endometrial spiral artery Doppler parameters in unexplained infertility patients: is endometrial perfusion an important factor in the etiopathogenesis? *J Turk Ger Gynecol Assoc* 2012; 13: 169–171.
- Pijnenborg R, Vercruyssen L, Hanssens M: The uterine spiral arteries in human pregnancy: facts and controversies. *Placenta* 2006; 27: 939–958.
- Weiss G, Sundl M, Glasner A, Huppertz B, Moser G: The trophoblast plug during early pregnancy: a deeper insight. *Histochem Cell Biol* 2016; 146: 749–756.
- Pijnenborg R, Vercruyssen L, Hanssens M: The uterine spiral arteries in human pregnancy: facts and controversies. *Placenta* 2006; 27: 939–958.
- Guzin K, Tomruk S, Tuncay YA, Naki M, Sezginsoy S, Zemheri E *et al.*: The relation of increased uterine artery blood flow resistance and impaired trophoblast invasion in pre-eclamptic pregnancies. *Arch Gynecol Obstet* 2005; 272: 283–288.
- Lyall F, Robson SC, Bulmer JN: Spiral artery remodeling and trophoblast invasion in preeclampsia and fetal growth restriction: relationship to clinical outcome. *Hypertension* 2013; 62: 1046–1054.
- Ozkaya U, Ozkan S, Ozeren S, Corakçi A: Doppler examination of uteroplacental circulation in early pregnancy: can it predict adverse outcome? *J Clin Ultrasound* 2007; 35: 382–386.
- Nagy S, Gardo S. P15.09: First-trimester Doppler assessment of spiral arteries in normal and abnormal pregnancies. *Ultrasound in Obstetrics & Gynaecology* 2006; 28: 601.
- Zhong Y, Tuuli M, Odibo AO: First-trimester assessment of placenta function and the prediction of preeclampsia and intrauterine growth restriction. *Prenatal Diagnosis* 2010; 30: 293–308.
- Gómez O, Figueras F, Fernández S, Bannas M, Martínez JM, Puerto B, *et al.*: Reference ranges for uterine artery mean pulsatility index at 11–41 weeks of gestation. *Ultrasound Obstet Gynecol* 2008; 32: 128–132.
- Helmy S, Bader Y, Koch M, Tiringier D, Kollmann C: Measurement of thermal effects of Doppler ultrasound: an in vitro study. *PLoS One*. 2015; 10: e0135717.
- Barnett SB, Maulik D, International Perinatal Doppler Society: Guidelines and recommendations for safe use of Doppler ultrasound in perinatal applications. *J Matern Fetal Med* 2001; 10: 75–84.
- Sheiner E, Abramowicz JS: A symposium on obstetrical ultrasound: is all this safe for the fetus? *Clin Obstet Gynecol* 2012; 55: 188–198.
- Torloni MR, Vedmedovska N, Merialdi M, Betran AP, Allen T *et al.*: Safety of ultrasonography in pregnancy: WHO systematic review of the literature and meta-analysis. *Ultrasound Obstet Gynecol* 2009; 33: 599–608.
- Meizner I: What do doctors understand regarding ultrasound safety during pregnancy?. *Harefuah* 2012; 151: 234–236.
- Salvesen KÅ, Lees C, Abramowicz J, Brezinka C, Ter Haar G, Maršál K: Safe use of Doppler ultrasound during the 11 to 13 + 6-week scan: is it possible? *Ultrasound Obstet Gynecol* 2011; 37: 625–628.
- Abramowicz JS, Kossoff G, Marsal K, Ter Haar G, International Society of Ultrasound in Obstetrics and Gynaecology Bioeffects and Safety Committee. Executive Board of the International Society of Ultrasound in Obstetrics and Gynaecology. Safety Statement, 2000 (reconfirmed 2003). International Society of Ultrasound in Obstetrics and Gynaecology (ISUOG). *Ultrasound Obstet Gynecol* 2003; 21: 100.
- Barnett SB, Ter Haar GR, Ziskin MC, Rott HD, Duck FA, Maeda K: International recommendations and guidelines for the safe use of diagnostic ultrasound in medicine. *Ultrasound Med Biol* 2000; 26: 355–366.
- Ter Haar G. The new British Medical Ultrasound Society Guidelines for the safe use of diagnostic ultrasound equipment. *Ultrasound* 2010; 18: 50–51.