

Porokeratosis of gluteal region: A case report

SAGE Open Medical Case Reports
Volume 10: 1–3
© The Author(s) 2022
Article reuse guidelines:
sagepub.com/journals-permissions
DOI: 10.1177/2050313X221139559
journals.sagepub.com/home/sco



Suraj Shrestha¹, Roshan Aryal¹ , Sushan Homagain¹,
Sansar Babu Tiwari², Buddha Rayamajhi³, Sudip Parajuli³
and Upama Paudel³

Abstract

Genitogluteal porokeratosis is a rare localized disorder of keratinization. Due to the rarity of the case and non-specific keratotic lesion, it is often misdiagnosed until a histological examination is performed. Treatment of this condition can be challenging, which comprises various topical and systemic drugs, lasers, cryotherapy, phototherapy, and also surgical intervention. Regular follow-up is necessary in the view of this disorder being a premalignant condition.

Keywords

Genitogluteal porokeratosis, porokeratosis, nummular eczema, lichen planus, dermatology

Date received: 29 May 2022; accepted: 31 October 2022

Introduction

Porokeratosis, a disorder of keratinization, is characterized clinically as typical keratotic papules or annular plaques which enlarge outwardly with a thread-like uplifted boundary.¹ Its histological hallmark is the formation of cornoid lamellae, which is a column of firmly contoured parakeratotic cells in the upper epidermis.^{2,3}

Genitogluteal porokeratosis is a rare form of porokeratosis which is usually pruritic, often aggravated by clothing friction, and maybe undetected for many years as it does not look like traditional porokeratosis in numerous cases; however, a biopsy is diagnostic.¹ Implication of the genital region and adjacent areas may occur as part of generalized porokeratosis occurring elsewhere on the body; but genitogluteal region porokeratosis is rare, and not many cases have been narrated in the literature.^{4–8} After the first case described in 1985, there have been no more than 50 reports of genitogluteal porokeratosis in the literature.¹

Here, we report a case of a male patient eventually diagnosed with genitogluteal porokeratosis after 5 years of misdiagnosis.

Case presentation

A 25-year-old male patient complained of itchy lesions on the buttocks for approximately 5 years. The examination revealed single, ulcerated, indurated, non-tender, plaque

present over the left perianal region as shown in Figure 1. There was no mucosal involvement. Systemic examination was normal. The patient received treatment with topical corticosteroids with a presumptive diagnosis of nummular eczema and lichen planus without any clinical improvement. The lesion was persistent even at 12 weeks of follow-up and thus, the previous topical therapy was stopped, and an incisional biopsy of the plaque was performed. The histological examination revealed cornoid lamellae of parakeratotic cells with an absent granular layer beneath them, and superficial dermis showed dense perivascular lymphocytic infiltrate as shown in Figure 2. Based on the clinical and histopathological findings, a definite diagnosis of porokeratosis was made. He was started on systemic isotretinoin and topical tazarotene gel. At 6 months of follow-up, the lesion had improved by about 25% compared to time of presentation.

¹Maharajgunj Medical Campus, Institute of Medicine, Kathmandu, Nepal

²Department of Pathology, Tribhuvan University Teaching Hospital, Kathmandu, Nepal

³Department of Dermatology, Tribhuvan University Teaching Hospital, Kathmandu, Nepal

Corresponding Author:

Roshan Aryal, Maharajgunj Medical Campus, Institute of Medicine, P.O. Box: 1524, Maharajgunj, Kathmandu, Nepal.
Email: roshanaryal7@gmail.com



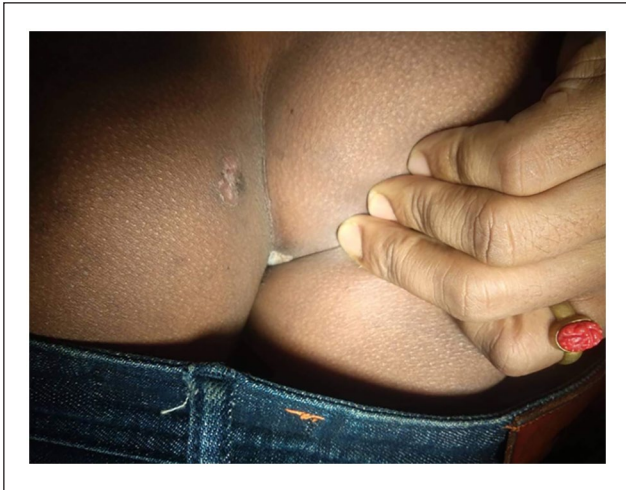

Figure 1. Single, ulcerated, indurated, plaque present over the left perianal region.

Discussion

Porokeratosis is an unconventional disorder of keratinization of uncertain cause and unforeseeable course with its keratotic papule or annular plaque.⁹ Histologically, the hallmark of porokeratosis is the cornoid lamella, which is a column of parakeratosis which frequently curves inside toward the core of the lesion with the base lacking the granular layer.^{2,3} Histological examination revealed similar findings in our case. The cornoid lamellae may be scarce to numerous in number depending on the various subtypes of porokeratosis.¹

Porokeratosis seems to be common in men and 90% of 22 cases highlighted by Takiguchi et al.¹⁰ were males aged between 27 and 84 years. Even after a century of its first description, etiology and pathogenesis are not well understood, but friction due to clothes may be an exacerbating part.¹ Autosomal dominant channeling and connected conditions like local and systemic immunosuppression have been described.¹¹⁻¹³ This condition undergoes undetected for many years due to presentation as abiding itchy verrucous plaques which are misdiagnosed as psoriasis, chronic eczema, lichen simplex chronicus, dermatophytosis, or candida infection.¹ Our patient was also misdiagnosed with nummular eczema and lichen planus for several years before a definitive diagnosis was made. The skin biopsy is crucial for the diagnosis, and features are diagnostic as previously mentioned.¹⁴ A definitive diagnosis in our patient was finally made after histological examination of the incised specimen from the lesion.

Among the various clinical types, porokeratosis restricted to the genitogluteal region is contemplated rarer and can be subclassified into three types, classical porokeratosis on the genital region, ptychotropic porokeratosis, and penoscrotal porokeratosis.¹ They differ in morphologic appearance of the lesions, sites involved, and age of presentation.¹ A proper

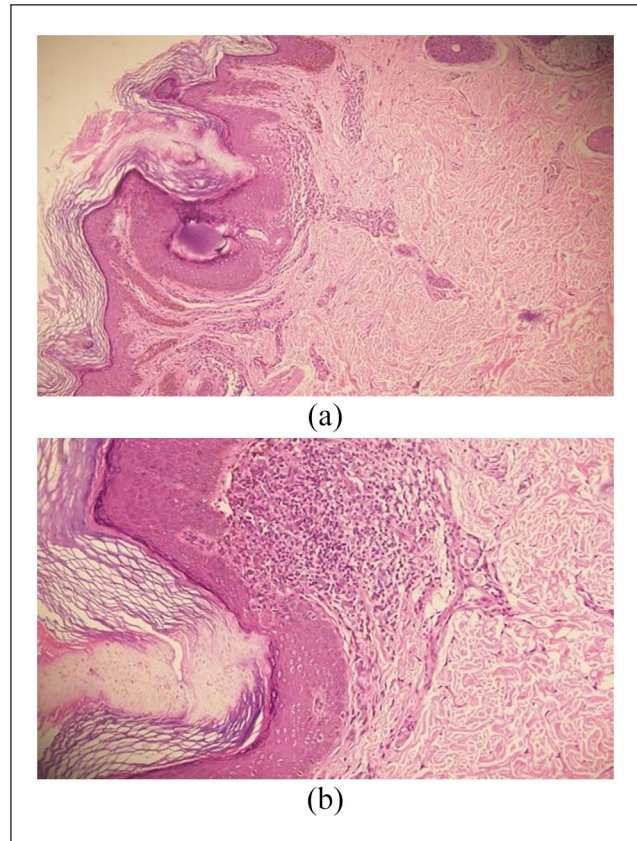


Figure 2. (a) Coronoid lamellae of parakeratotic cells with an absent granular layer beneath them and dense perivascular lymphocytic infiltrate in superficial dermis. (b) A high-power view of coronoid lamellae is delineated.

diagnosis of porokeratosis is crucial for both therapeutic and prognostic indications. According to a systematic review on the treatment of porokeratosis, the various therapies attempted and tested include topical and systemic steroids, antifungals, 5-fluorouracil, topical and systemic retinoids, imiquimod, topical vitamin D3 analogs, cryotherapy with liquid nitrogen, lasers, photodynamic therapy as well as surgical intervention.¹⁵ In our case, after the definitive diagnosis was made, the patient was started on systemic and topical retinoids. The only report of initial successful treatment, with the surgical removal of superficial tissue using a dermatome, was reported in a 25-year-old man who had an itchy plaque on the buttock for 8 years and was identified as porokeratosis on histopathological examination; however, there was a subsequent relapse.¹⁶ Till date, the most detailed description of genitogluteal porokeratosis obtained after review of information from various case reports and series has revealed more occurrences among men than women with most of the patients describing single or multiple pruritic verrucous papule or plaque/s.¹ As described in the same review, various topical and systemic medications and other modalities described above were tried for genitogluteal porokeratosis with variable response.¹ Porokeratosis is

regarded as a premalignant condition due to the presence of clonal proliferation, atypical keratinocyte maturation, dyskeratotic cells, and overexpression of p53; and huge, established and ulcerative porokeratotic lesions have developed malignancy; however, to date, evolution of tumor in genital porokeratosis has not been described.^{17–19} No malignant lesion has been detected in our case and the patient is under regular follow-up.

Conclusion

Although genitogluteal porokeratosis is a rare diagnosis, this report highlights that chronic eczematous lesions in specific areas unrelieved on topical medications should proceed for histopathological examination for a definitive diagnosis. Moreover, all cases of porokeratosis should be tracked up regularly in view of the possible malignant transformation.

Author contributions

S.B.T. and B.R. contributed to study concept, data collection, and medical and surgical therapy for the patient. S.S., R.A., and S.H. contributed to writing—original draft preparation, editing, and writing. S.B.T. is the senior author and manuscript reviewer. S.P. and U.P. thoroughly reviewed the manuscript to give the final shape. All the authors read and approved the final manuscript.

Availability of data and materials

The data that support the findings of this study are available from the corresponding author upon reasonable request.

Declaration of conflicting interests

The author(s) declared no potential conflicts of interest with respect to the research, authorship, and/or publication of this article.

Funding

The author(s) received no financial support for the research, authorship, and/or publication of this article.

Ethical approval

Our institution does not require ethical approval for reporting individual cases or case series.

Informed consent

Written informed consent was obtained from the patient for their anonymized information to be published in this article.

ORCID iD

Roshan Aryal  <https://orcid.org/0000-0002-4689-9264>

References

- Joshi R and Minni K. Genitogluteal porokeratosis: a clinical review. *Clin Cosmet Investig Dermatol* 2018; 11: 219–229.
- Leow YH, Soon YH and Tham SN. A report of 31 cases of porokeratosis at the National Skin Centre. *Ann Acad Med Singap* 1996; 25(6): 837–841.
- Sertznig P, von Felbert V and Megahed M. Porokeratosis: present concepts. *J Eur Acad Dermatol Venereol* 2012; 26(4): 404–412.
- Hayashi Y, Ozeki M, Ishizaki S, et al. Inguinal porokeratosis in a Japanese man. *Dermatol Pract Concept* 2013; 3(4): 29–31.
- Garg T, Ramchander Varghese B, Barara M, et al. Generalized linear porokeratosis: a rare entity with excellent response to acitretin. *Dermatol Online J* 2011; 17(5): 3.
- Watanabe T, Murakami T, Okochi H, et al. Ulcerative porokeratosis. *Dermatology* 1998; 196(2): 256–259.
- Broussard KC, Boyd A and Gloeckner Powers J. Thick intergluteal cleft and lower extremity plaques. *JAMA Dermatol* 2013; 149(9): 1099–1100.
- Vij A, Doherty SD, LeLeux TM, et al. Disseminated porokeratosis of Mibelli: a case report. *Dermatol Online J* 2010; 16(12): 12.
- Bolognia JL, Schaffer JV and Cerroni L. *Dermatology: 2-volume set*. London: Elsevier Health Sciences, 2017.
- Takiguchi RH, White KP, White CR Jr, et al. Verrucous porokeratosis of the gluteal cleft (porokeratosis ptychotropica): a rare disorder easily misdiagnosed. *J Cutan Pathol* 2010; 37(7): 802–807.
- Valdivielso-Ramos M. Genital porokeratosis. *Actas Dermosifiliogr* 2008; 99(3): 217–220.
- Sengupta S, Das JK and Gangopadhyay A. Porokeratosis confined to the genital area: a report of three cases. *Indian J Dermatol Venereol Leprol* 2008; 74(1): 80.
- Wanat KA, Gormley RH, Bennett DD, et al. Genitogluteal porokeratosis involving the scrotum: an unusual presentation of an uncommon disease. *J Cutan Pathol* 2012; 39(1): 72–74.
- Liang C, Batra P, Patel R, et al. Genital porokeratosis. *Dermatol Online J* 2009; 15(8): 23.
- Weidner T, Illing T, Miguel D, et al. Treatment of porokeratosis: a systematic review. *Am J Clin Dermatol* 2017; 18(4): 435–449.
- Scheiba N, Enk A, Proske S, et al. Porokeratosis ptychotropica: successful treatment with the dermatome. *Dermatol Surg* 2010; 36(2): 257–260.
- Otsuka F, Shima A and Ishibashi Y. Porokeratosis as a premalignant condition of the skin. Cytologic demonstration of abnormal DNA ploidy in cells of the epidermis. *Cancer* 1989; 63(5): 891–896.
- Magee JW, McCalmont TH and LeBoit PE. Overexpression of p53 tumor suppressor protein in porokeratosis. *Arch Dermatol* 1994; 130(2): 187–190.
- Sasson M and Krain AD. Porokeratosis and cutaneous malignancy. *Dermatol Surg* 1996; 22(4): 339–342.