

Received: 2011.01.14
Accepted: 2011.03.18
Published: 2011.09.01

The impact of laser irradiation on global stability in patients with vertebrobasilar insufficiency: A clinical report

Authors' Contribution:

- A** Study Design
- B** Data Collection
- C** Statistical Analysis
- D** Data Interpretation
- E** Manuscript Preparation
- F** Literature Search
- G** Funds Collection

Małgorzata Lukowicz^{1ADEFG}, Paweł Zalewski^{2BDF}, Irena Bulatowicz^{3AE},
Katarzyna Buszko^{4BG}, Jacek J. Klawe^{2EF}

¹ Department of Laser Therapy and Physiotherapy, Faculty of Health Sciences, Collegium Medicum – Bydgoszcz, Nicolaus Copernicus University, Torun, Poland

² Department of Hygiene and Epidemiology, Faculty of Health Sciences, Collegium Medicum – Bydgoszcz, Nicolaus Copernicus University, Torun, Poland

³ Department of Kinesitherapy and Medical Massage, Faculty of Health Sciences, Collegium Medicum – Bydgoszcz, Nicolaus Copernicus University, Torun, Poland

⁴ Department of the Theoretical Basis of Biomedical Sciences and Medical Information, Faculty of Health Sciences, Collegium Medicum – Bydgoszcz, Nicolaus Copernicus University, Torun, Poland

Source of support: Departmental sources

Summary

Background:

The purpose of our experiment was to determine whether laser stimulation can improve microcirculation in the posterior regions of the brain in patients with vertebrobasilar insufficiency (VBI).

Material/Methods:

We studied 25 patients (20 female, 5 male, mean age 64) diagnosed with chronic VBI. All were evaluated using the De Klyn test, followed by qualitative assessment of stability using a Berg Balance Scale and evaluation of global stability using an electronic balance platform. A CTL-1100 low power laser was used with standard parameters. We established a protocol for laser irradiation at 5 points along the vertebral artery in the cervical region bilaterally. Irradiation was performed 10 times over two weeks.

Results:

Significant improvement occurred after therapy in headache ($p=0.0005$), vertigo ($p<0.0000$), and tinnitus ($p=0.0387$). No significant differences were observed in nausea or nystagmus caused by head rotation. The Berg Balance Scale results showed significant differences in almost all features. There was a tendency towards improved stability in all parameters, and statistically significant differences in the total surface of support and the spread surface of support for the left foot.

Conclusions:

Laser stimulation as applied in this study can be useful in the treatment of patients with VBI. The main reason for improvement in global stability, balance, and other VBI symptoms is better blood perfusion.

key words:

vertebrobasilar artery • LLLT • VBI • Berg Balance Scale • De Klyn Test • Freeman platform • vascular smooth muscle cells (VSMCs)

Full-text PDF:

<http://www.medscimonit.com/fulltxt.php?ICID=881939>

Word count:

2093

Tables:

2

Figures:

6

References:

30

Author's address:

Małgorzata Lukowicz, Department of Laser Therapy and Physiotherapy, Collegium Medicum – Bydgoszcz, Nicolaus Copernicus University, M. Skłodowskiej-Curie 9 Str., 85-094 Bydgoszcz, Poland, e-mail: gosalukowicz@wp.pl

BACKGROUND

Vertebrobasilar insufficiency (VBI) is often observed in active persons in middle age. The main symptoms of this syndrome are balance disturbances [1]. Very often the patients do not present with any other symptoms except for positional vertigo and dizziness, so the differential diagnosis of its origin is very difficult [2]. Along with balance disturbances, transient focal neurological symptoms are sometimes observed, specific for the brain region supplied by the vertebrobasilar artery (VBA) [3,4]. Mechanical endogenous and exogenous factors, such as muscle tone disturbances, osteoarthritis [5], herniated cervical disc [6], inflammation, or arteriosclerosis, may cause VBI, due to restriction of blood flow in the VBA [4]. We often observe these symptoms during normal physical activity that particularly involve neck and shoulder movements. There are also descriptions of VBI symptoms associated with neck pain, torticollis, and stiff neck. Occasionally the onset of these symptoms has been reported after improper manipulations of the cervical spine [7].

Terret distinguishes the set of symptoms connected with VBI as follows:

- vertigo;
- diplopia;
- nausea;
- nystagmus;
- ataxia;
- dizziness;
- dysphagia.

The presence of these symptoms can influence social and occupational life, as well as the quality of life [3,4]. Unfortunately, many of the methods used to control VBI are often ineffective. Sometimes it is necessary to involve an interdisciplinary team, but this is very costly and time-consuming.

Low level laser therapy (LLLT) has gained recently popularity in the treatment of arterial occlusion. LLLT produces non-thermal (bio-stimulating) effects, due to an average power less than 500 mW. The biological effects of laser stimulation are observed at a cellular level, and are thought to stabilize the cell membrane, increase intracellular transport, and release endorphins and many other cytokines. The stimulation of the treated region is reported to cause the expansion of blood vessels and an increased blood flow volume. The increase in blood flow is probably caused by the vasodilator reflex via the central nervous system [8].

Exposure to external laser stimulation in patients with ischemic heart disease produces improved rheology of blood, a protective effect on the erythrocyte membrane [9] and an inhibition of lipid peroxidation [10]. Laser light illumination is also reported to reduce the re-stenosis rate after successful balloon angioplasty with coronary stent implantation [11]. The improvement of microcirculation after biomodulation with LLLT (780 nm) has been demonstrated by magnetic resonance imaging (MRI) [12].

LLLT is reported to enhance vasodilatation, as well as proliferation of microvasculature, and is also thought to increase the level of oxygen content in tissue [13]. Laser irradiation at 810 nm (10, 30 and 110 mW) has also been reported to inhibit the vascular contraction reaction induced by

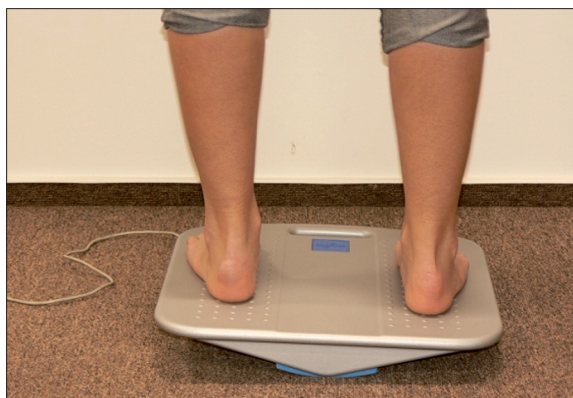

Figure 1. Patient during testing on the EasyTech LIBRA®.

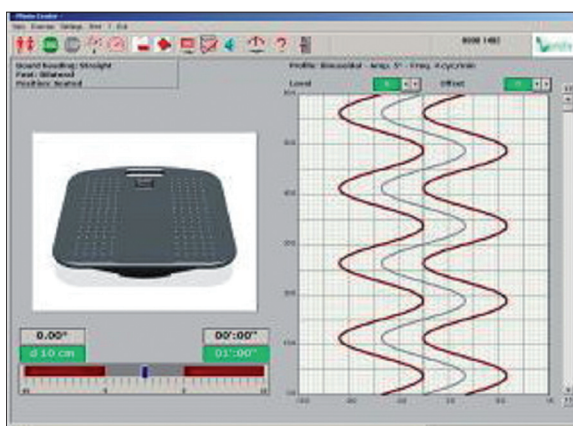


Figure 2. Stability testing on the EasyTech LIBRA® Freeman platform.

noradrenaline (NA) and phenylephrine (PHE), due to stimulation of nitric oxide release and guanyl cyclase [14]. There have also been reports of intravenous laser blood irradiation used to good effect in body-building athletes [15]. Positive effects have observed during laser therapy of venous ulcers (900 nm diode laser, pulsed) combined with radiofrequency (RF) current [16].

The main goal of our research was to evaluate the impact of LLLT of the vertebral artery bilaterally on VBI symptoms, balance, and global stability using manual tests, the Berg Balance Scale, and a Freeman's balance platform.

MATERIAL AND METHODS

We examined 25 patients diagnosed with chronic vertebrobasilar insufficiency (VBI), 20 females and 5 males, mean age 64 years. The patients were evaluated with De Klyn's diagnostic test, followed by a qualitative assessment of stability, using a Berg Balance Scale. This scale is composed of 14 tests evaluating mobility on a scale from 0 (worst) to 4 (best), taking into account the time and accuracy of the specific activity. The tests were done three times: before treatment, 30 minutes after the first laser application, and after ten stimulation sessions.

The next step was the evaluation of global stability, using a Freeman electronic balance platform, the EasyTech LIBRA® (Figures 1, 2). The test lasted for 30 seconds, during which time the patient's task was to maintain a normal upright

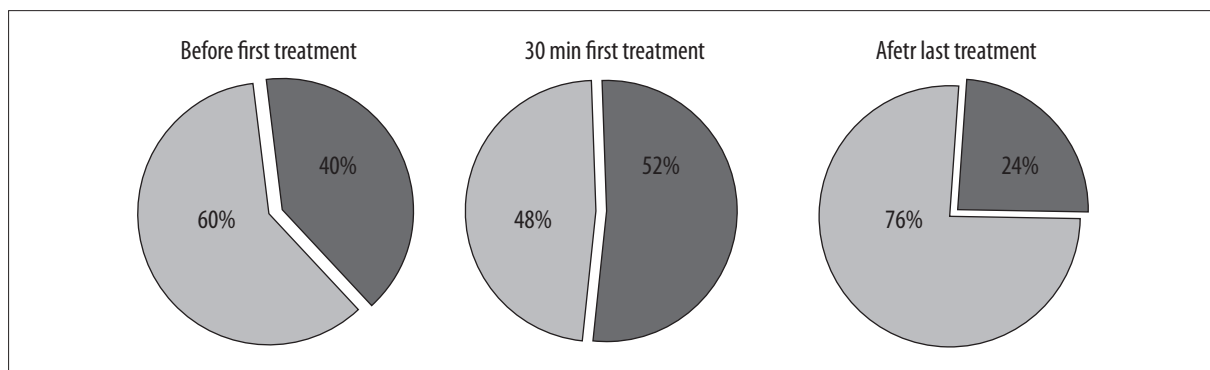


Figure 3. Headaches reported during the De Klyn test.

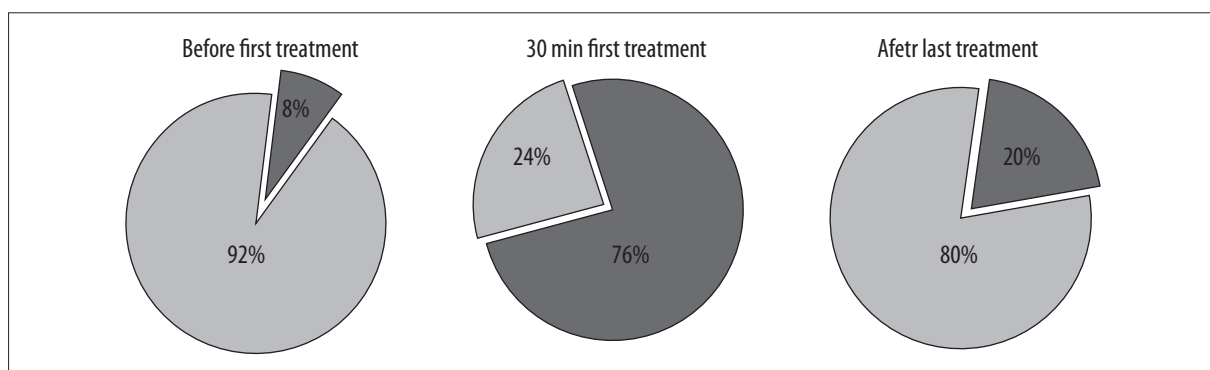


Figure 4. Vertigo reported during the De Klyn test.

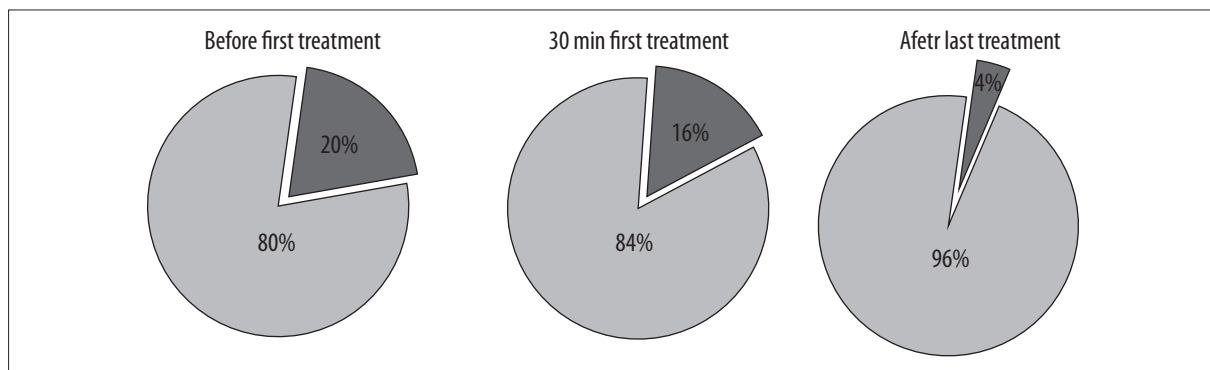


Figure 5. Tinnitus reported during the De Klyn test.

position on an unstable support plane. These tests were performed twice – once before and once after treatment.

Device and parameters

A CTL-1100 low power laser was used, with a probe of 810–830 nm, power of 100 mW, and energy density of ED=4 J/cm²; the wave was modulated into a frequency of 6 kHz. The laser probe at the top consisted of a 1 cm² quartz window, and delivered a collateral beam. We have established our own protocol, which involves irradiation with a laser beam at 5 points on the skin along the vertebral artery in the cervical region,

bilaterally, using delicate pressure. The irradiation was conducted 10 times: once a day from Monday to Friday for two weeks, with a weekend break. All subjective changes were noted.

Statistical analysis

The analysis of results from the De Klyn test before and after therapy was performed with Cochran’s Q test, while the results from the Berg Balance Scale were analyzed by calculating-the Spearman rank correlation coefficient. To evaluate the statistical significance of all three tests, the Friedman test was used, with the level of statistical significance assumed at p<0.05.

Table 1. Statistical analysis of the results from the Berg Balance Scale before and after therapy.

Balance feature	p
1. Sitting unsupported	0.0678
2. Change of position: sitting to standing	–
3. Change of position: standing to sitting	–
4. Transfers	–
5. Standing unsupported	–
6. Standing with eyes closed	0.1423
7. Standing with feet together	0.0468
8. Tandem standing	0.0033
9. Standing on one leg	0.0156
10. Turning trunk (feet fixed)	0.0002
11. Retrieving objects from floor	0.0019
12. Turning 360 degrees	0.0408
13. Stool stepping	0.0022
14. Reaching forward while standing	0.0002

RESULTS

The results of all three tests were combined in order to evaluate the impact of laser irradiation on blood supply in the posterior region of the brain. No side effects or complications were observed during therapy.

De Klyn’s test

During the test, the patients were asked to answer questions about their symptoms: headache, vertigo, tinnitus and nausea; the occurrence of nystagmus was also noted. We noticed a statistically significant reduction in complaints of headache ($p=0.0005$), vertigo ($p=0.0000$) and tinnitus ($p=0.0387$) after therapy. The results are presented in Figures 3–5.

We did not observe any statistically significant differences in such symptoms as nausea ($p=0.8187$, n.s.) and nystagmus ($p=0.3678$, n.s.) caused by head rotation.

Berg Balance Scale

Statistical analysis of the results from the Berg Balance Scale revealed statistically significant differences in almost all tested features (Table 1).

During the initial and final test, the patients received maximum scores for sitting unsupported and changing of position from sitting to standing. That is why we did not observe any statistically significant changes after treatment, due to the ceiling effect. These tasks were very simple for the patients.

The final evaluation of global stability, conducted on the EasyTech LIBRA® platform, was also analyzed statistically. We took into account the total surface of support, the spread surface of support, the extended time and the time

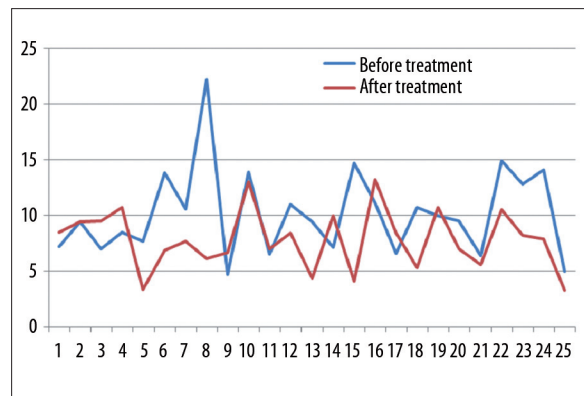


Figure 6. Results of global stability testing before and after 10 sessions of laser stimulation.

Table 2. Comparison between first assessment, 30 minutes after the first session, and final assessment for the left foot.

	Score	P
First assessment & 30 min after		
Total surface of support	153	0.798
Spread surface of support	128	0.530
Extended time	118	0.361
Time of reaction	118	0.543
30 min after & final assessment		
Total surface of support	105	0.122
Spread surface of support	115	0.475
Extended time	110	0.592
Time of reaction	112	0.638
First & final assessment		
Total surface of support	82	0.030
Spread surface of support	51	0.025
Extended time	73	0.082
Time of reaction	75	0.091

of reaction. We observed a tendency towards improvement in all parameters after ten sessions of laser irradiation, but a statistically significant difference was observed only in the total surface of support ($p=0.017$) and the spread surface of support for the left foot before and after therapy ($p=0.030$, $p=0.025$; Figure 6, Table 2). We did not observe any differences in any parameters when comparing results before and 30 minutes after the first session.

DISCUSSION

Vertebrobasilar insufficiency (VBI) is a condition characterized by insufficient blood supply to the posterior portion of the brain, which is responsible for balance, coordination, vision and other functions [17]. Two-thirds of patients with VBI experience dizziness as the most common symptom.

The most frequently reported accompanying symptoms in the studies by Grad and Baloh [18] were visual (diplopia, blindness, hallucinations). These are very alarming symptoms that usually bring the patient to consult a physician.

In differential diagnosis it is important to exclude Meniere's disease, migraine and labyrinthitis [19], and ischemic heart disease [10]. It is also very important to perform manual tests to check for arterial occlusion or disturbances in blood supply due to osteoarthritis. The most popular instrument used in the diagnosis of VBI is De Klyn's Test. The Berg Balance Test is often used to evaluate the level of balance disturbances occurring during simple activities of daily living [20]. We also try to evaluate quantitative data pertaining to balance disturbances that occur during posture support on an unstable platform (a Freeman Platform).

The problem of VBI is especially important if the patient is over 55 and has other stroke risk factors. Patients with these symptoms must quit smoking, lower the cholesterol level through diet, and exercise regularly. Drugs are often used to control blood pressure, block platelet function, and lower the cholesterol level. It is also possible to perform endovascular repair. The search is underway for other methods that may be useful in improving blood supply to the posterior regions of the brain.

The basic mechanisms of interactions between different wavelengths and tissues are still not fully understood. LLLT has been proven to accelerate collateral circulation and enhance microcirculation. Steg was the first to study *in vitro* the influence of argon laser (488–514.5 nm) and power supply below 100 mW on vascular smooth muscle cells (VSMCs) [21]. He noticed that lower doses of power supply (<100 mW) caused vasodilatation, and high doses (>1 W) caused vasoconstriction. Gal studied the influence of excimer laser working in a pulse or constant mode. The laser in pulse mode did not cause any reaction, but in constant mode caused vascular constriction [22]. Maegawa and Toshiyuki demonstrated the influence of infrared laser (830 nm) on vascular smooth muscle cells (VSMCs). They found that laser stimulation can cause major vasodilatation and increased arteriolar blood flow [23]. LLLT induced reduction of $[Ca^{2+}]$ in VSMCs and stimulated NO synthase [23]. NO can operate as a free radical or as an activator of guanyl cyclase (GC) [24]. Activation of GC leads to an increased level of cGMP. Some authors decline that the heme included in GC serves as a chromophore absorbing laser and ultraviolet light [22,25]. This consequently leads to an increased cGMP level and vasodilatation of smooth muscle cells. It is still unknown which wavelength is absorbed by these structures. We studied a laser wavelength of 830 nm because of its deep penetration and proven clinical effect. We tried to demonstrate that it penetrates through the skin and reaches the vascular wall, where it initiates biochemical changes.

Many authors have demonstrated the influence of laser stimulation on vasodilatation *in vivo*. Schaffer et al. irradiated the planta pedis of healthy volunteers [12], Teggi treated patients with Meniere's disease [26], Hirschl treated patients with Raynaud's phenomenon [27], and Trelles irradiated leg blood vessels with success [16]. Tullberg exposed the masseter muscle to a gallium-aluminium-arsenide laser because of muscle pain and demonstrated an increase

in microcirculation [28]. Raggi used a 630 nm wavelength to irradiate athletes' legs intravenously [15]. Mahikara irradiated the superficial temporal artery with CO₂ laser [8]. He concluded that 10 minutes after stopping irradiation, the diameter and blood flow volume of the artery had increased significantly. He also noticed the same changes on the contralateral side.

Our results with a diode laser at $\lambda=830$ nm support these observations. In De Klyn's test we observed a reduction in such symptoms as headache, vertigo and tinnitus after tens session of irradiation, due to better blood supply to the posterior regions of the brain. We did not observe any statistically significant changes 30 minutes after the first session. There were no changes in the occurrence of nausea or nystagmus.

We also noticed statistically significant improvement in balance tests. Patients performed almost all tasks better after treatment than before, probably due to vasodilatation caused by changes in the vascular wall. 10 days of therapy improved blood circulation in the region of the vestibular nuclei, the cerebellum and the cerebellar peduncle. The better the blood supply, the better the tissue perfusion and nourishment. There were no effects of a single session. In other words, transient vasodilatation is not sufficient to improve balance support. There must be better microcirculation in nerve tissue, causing more permanent changes [29,30]. This is presumably the reason why patients improve in balance tasks after 10 sessions of laser stimulation.

The final evaluation of global stability on the Freeman platform supported the foregoing observations. The patients improved in maintaining global stability on an unstable platform. Such improvement cannot be gained due to transient vasodilatation, but rather thanks to better perfusion of nerve tissue and increased oxygen content.

CONCLUSIONS

We can safely conclude that laser stimulation at 830 nm with a power supply of 100 mW can be a successful method in the treatment of patients with vertebrobasilar insufficiency. Our results suggest that the main reason for improvement after 10 days of therapy in global stability and balance, along with reduction of VBI symptoms, is better blood perfusion and an increased level of oxygen in brain tissue. The procedures we used turned out to be very sensitive in the evaluation of VBI symptoms.

REFERENCES:

1. Zalewski P, Bulatowicz I, Lukowicz M, Buszko M: Assessment of general body balance by using electronic platform after low-laser therapy in patients suffering from balance disorders. *Acta Bio-Opt et Info Med.* 2008; 14: 36–39
2. Moubayed SP, Saliba I: Vertebrobasilar insufficiency presenting as isolated positional vertigo or dizziness: a double-blind retrospective cohort study. *Laryngoscope*, 2009; 119(10): 2071–76
3. Huijbregts P, Vidal P: Dizziness in orthopaedic physical therapy practice: classification and pathophysiology. *J Man Manip Ther*, 2004; 12: 199–214
4. Markowski J, Gierek T, Kluczevska, Witkowska M: Assessment of vestibulocochlear organ function in patients meeting radiologic criteria of vascular compression syndrome of vestibulocochlear nerve – diagnosis of disabling positional vertigo. *Med Sci Monit*, 2011; 17(3): CR169–72

5. Ohsaka M, Takgami M, Koyanagi I et al: Cerebral ischemia originating from rotational vertebral artery occlusion caused by C5/6 spondylotic changes: a case report. *No Shinkei Geka*, 2009; 37(8): 797–802
6. Ujifuku K, Hayashi K, Tsunoda K et al: Positional vertebral artery compression and vertebrobasilar insufficiency due to a herniated cervical disc. *J Neurosurg Spine*, 2009; 11(3): 326–29
7. Foye PM: Pain, dizziness and cervical nervous system blood flow in cervical extension: Vascular correlations to beauty parlor stroke syndrome and salon sink radiculopathy. *Am J Phys Med Rehabil*, 2002; 81: 395–99
8. Makihara E, Masumi S: Blood flow changes of a superficial temporal artery before and after low-level laser irradiation applied to the temporomandibular joint area. *Jpn Prosthodont Soc*, 2008; 52: 167–70
9. Vasilev AP, Sekisova MA, Streltsova NN: Laser correction of microcirculation disorders in patients having CHD with hypercholesterolemia. *Klin Med (Mosk)*, 2005; 83: 33–37
10. Vasilev AP, Streltsova NN, Senatorov IuN: Efficacy of laser therapy in patients with ischemic heart disease. *Vopr Kurortol Fizioter Lech Fiz Kult*, 2003; 4: 10–13
11. Derkacz A, Protasiewicz M, Poręba R et al: Intracoronary low power laser irradiation during angioplasty procedure. Own experience. *Acta Bio-Optica et Inform Med.*, 2007; 13: 71–73
12. Schaffer M, Bonel H, Sroka R et al: Effects of 780 nm diode laser irradiation on blood microcirculation: preliminary findings on time-dependent T1-weighted contrast-enhanced magnetic resonance imaging (MRI). *J Photochem Photobiol B: Biol*, 2000; 54: 55–60
13. Mohammed Ihsan FR: Low-level laser therapy accelerates collateral circulation and enhances microcirculation. *Photomed & Laser Sur*, 2005; 23(3): 289–95
14. Mackiewicz-Milewska M, Talar J, Grzesk G et al: The role of nitric oxide in the modulation of arterial smooth muscle contraction evoked by activation of adrenoceptors during laser biostimulation. *Pol J Phys*, 2002; 2: 89–98
15. Raggi F, Vallesi G: Intravenous laser blood irradiation in sports medicine. *Schmerz & Akupunktur*, 2008; 3: 126–29
16. Trelles MA, Martin-Vazquez M, Trelles OR: Treatment effects of combined radio-frequency current and a 900 nm diode laser on leg blood vessels. *Lasers Surg Med.*, 2006; 38: 185–95
17. Horn LB: Differentiating between vestibular and nonvestibular balance disorders. *Neurology*, 1997; 21: 23–27
18. Furman JM, Whitney SL: Central causes of dizziness. *Phys Ther*, 2000; 80: 179–87
19. Kramer PD: ENG Report: Vascular diseases of the vestibular system. In: *Advancing the science of vestibular diagnostics*. Available via GN Otometrics. http://www.otometrics.com/resources/literature/eng_archives.htm. Accessed 15 Nov 2008
20. Thorbahn L, Newton R: Use of the Berg test to predict falls in elderly persons. *Phys Ther*, 1996; 76: 576–85
21. Steg PG, Gal D, Rongione AJ et al: Effect of argon laser irradiation on rabbit aortic smooth muscle: evidence for endothelium independent contraction and relaxation. *Cardiovasc Res*, 1988; 22: 747–53
22. Gal D, Steg G, Rongione AJ et al: Percutaneous delivery of low-level laser energy reverses histamine-induced spasm in arteriosclerotic Yucatan microswine. *Circulation*, 1992; 85: 756–68
23. Maegawa Y, Itoh T, Hosokawa T et al: Effects of near-infrared low-level laser irradiation on microcirculation. *Lasers Surg Med.*, 2000; 27: 427–37
24. Alosachie I, Godfraind T: The modulatory role of vascular endothelium in the interaction of agonists and antagonists with alpha-adrenoceptors in the rat aorta. *Br J Pharmacol*, 1988; 95: 619–29
25. Schwengel RH, Gregory KW, Hearme SE et al: Characterization of pulsed-dye laser-mediated vasodilatation in a rabbit femoral artery model of vasoconstriction. *Lasers Surg Med.*, 1993; 13: 284–95
26. Teggi R, Bellini C, Fabiano B, Bussi M: Efficacy of low-level laser therapy in Meniere's disease: a pilot study of 10 patients. *Photomed Laser Surg*, 2008; 26: 349–53
27. Hirschl M, Katzneschlager R, Francesconi C, Kund M: Low level laser therapy in primary Raynaud's phenomenon – results of a placebo controlled, double blind intervention study. *J Rheumatol*, 2004; 31: 2408–12
28. Tullberg M, Alstergren PJ, Ernberg MM: Effects of low-power laser exposure on masseter muscle pain and microcirculation. *Pain*, 2003; 105: 89–96
29. Danis CG, Krebs DE, Gill-Body KM: Relationship between standing posture and stability. *Phys Ther*, 1998; 78: 502–17
30. Ihsan MF: Low-level laser therapy accelerates collateral circulation and enhances microcirculation. *Photomed Laser Surg*, 2005; 23: 289–94