



Clinical effects of cisplatin plus recombinant human endostatin (rh-endostatin) intratumoral injection on malignant central airway obstruction: a retrospective analysis of 319 cases

Yunzhi Zhou, Yongping Gao, Nan Zhang, Xiaoli Li, Hui Wang, Shufang Wang, Jiankun Liu, Hong Gao, Hongwu Wang

Department of Respiratory Medicine, Emergency General Hospital, Beijing, China

Contributions: (I) Conception and design: H Wang, Y Zhou, Y Gao; (II) Administrative support: H Wang, Y Zhou; (III) Provision of study materials or patients: N Zhang, X Li, H Wang, S Wang, J Liu, H Gao; (IV) Collection and assembly of data: Y Gao, N Zhang, X Li, H Wang, S Wang, J Liu, H Gao; (V) Data analysis and interpretation: Y Zhou, Y Gao; (VI) Manuscript writing: All authors; (VII) Final approval of manuscript: All authors.

Correspondence to: Hongwu Wang. Department of Respiratory Medicine, Emergency General Hospital, Beijing 100028, China.

Email: wanghongwu2015@126.com.

Background: Primary lung cancer with severe central airway obstruction (CAO) is often life-threatening. In this study, we investigated the clinical efficacy and safety of cisplatin plus recombinant human endostatin (rh-endostatin) intratumoral injection in treatment of malignant central airway obstruction (MCAO) caused by primary squamous cell lung cancer.

Methods: We retrospectively analyzed patients with MCAO caused by primary squamous cell lung cancer treated with and without bronchoscopic intratumoral injection of cisplatin plus rh-endostatin between January 2007 and June 2016.

Results: A total of 206 patients received cisplatin plus rh-endostatin intratumoral injection, and 113 without injection. Dyspnea grade, degree of stenosis, quality of life and lung function of all patients were significantly improved at 1 week after treatment compared with baseline. Both groups achieved good airway patency (97.1% *vs.* 93.8%, $P=0.156$). Followed up at 2 months, all parameters were improved in the injection group compared with baseline, while no statistical differences were observed in the non-injection group ($P>0.05$). The injection group achieved airway patency in 155 (75.2%) of 206 patients, which was significantly superior to the non-injection group [20 (17.7%) of 113, $P<0.001$]. In addition, the restenosis rate of the injection group was lower compared with the non-injection group (22.5% *vs.* 81.1%, $P<0.001$, respectively). No serious complications were observed in two groups.

Conclusions: Cisplatin plus rh-endostatin intratumoral injection is effective and safe for the therapy of MCAO caused by primary squamous cell lung cancer.

Keywords: Cisplatin; recombinant human endostatin; intratumoral injection; lung cancer; airway obstruction

Submitted Mar 27, 2020. Accepted for publication Dec 21, 2020.

doi: 10.21037/jtd-20-1493

View this article at: <http://dx.doi.org/10.21037/jtd-20-1493>

Introduction

Lung cancer is the leading cause of morbidity and mortality among malignant tumors (1) with annually increasing prevalence in China (2,3). Primary lung cancer with severe central airway obstruction (CAO) is often life-

threatening (4). Treatments with laser, electrocautery, argon plasma coagulation and stent placement via bronchoscopy are effective in reducing airway stenosis caused by malignant central airway tumors (5,6), but the stenosis will recur in a short time (7). Cisplatin intratumoral injection is safe and effective in patients with

isolated hilar and mediastinal recurrence of lung cancer (8). However, whether cisplatin plus rh-endostatin combined intratumoral injection could be treated in MCAO patients remains unclear. We hypothesized that cisplatin plus rh-endostatin intratumoral injection is effective in reducing stenosis and improving dyspnea in MCAO. Thus, we investigated the efficacy and safety of cisplatin plus rh-endostatin intratumoral injection in treatment of MCAO caused by primary squamous cell lung cancer.

Methods

Study population

We retrospectively reviewed the medical records of all patients treated with and without cisplatin plus rh-endostatin intratumoral injection in MCAO caused by primary squamous cell lung cancer at the Emergency General Hospital (Beijing, China) between January 2007 and June 2016. The study was conducted in accordance with the Declaration of Helsinki (as revised in 2013) and informed consent was taken from all the patients.

Intratumoral injection

Subjects were administered midazolam (1–2 mg) plus sufentanil (5 mg) intravenously for general anesthesia (9). The rigid (STORZ, Germany) and soft bronchoscope (BF260, Olympus Inc., Osaka, Japan) were passed transorally for the treatment. The lesions in the bronchial wall were initially debulked through endobronchial (10). Patients in non-injection group only received interventional bronchoscopy to debulk the lesions and remove debris. Patients in injection group were treated with 20–40 mg of cisplatin (concentration of 5 mg/mL) and 15 mg of rh-endostatin (Endostar, Shandong Simcere-Medgenn Bio-Pharmaceutical Co., Ltd.) injected directly into the tumor after debulking. Cisplatin and Endostar were administered endoscopically to visible tumor tissue via a flexible 19-gauge Wang needle inserted directly into the tumor's root, including tumor and adjacent tissues. Each injection covered 4–6 sites depending on the size of the tumor. After injection, the bronchoscope was passed distally to the tumor and excess drug was suctioned from the distal airways to prevent the potential for alveolar toxicity secondary to residual drug. To ensure alleviate airway obstruction and increase a greater penetration to tumor, necrotic debris was removed before dosing at visit 2 and thereafter.

Measurements

The following data were retrospectively obtained from patients' medical records: demographic information, tumor distribution, degree of stenosis, Karnofsky performance scale (KPS) score (11), Eastern Cooperative Oncology Group (ECOG) score (12), dyspnea grade (13) and lung function test. The degree of airway obstruction (14) was initially assessed based on visual estimation by the bronchoscopists. The residual airway obstruction was estimated by visual assessment at 1 week and 2 months after the final dose by the same proceduralists. Expansion more than 50% ordinary diameter of the bronchus with malignant airway obstruction were accepted as procedure successes, while expansion below 50% were defined as failures (15). Restenosis was defined as tracheal diameter less than 50% after treatment. The complications were also evaluated.

Statistical analysis

Statistical analysis was conducted using SPSS 19.0 (SPSS Inc., Ill, USA). Numeric data were expressed as mean \pm standard deviation, and compared with *t*-test or Mann-Whitney test. Associations between response rates were conducted by the Pearson's chi-squared test. $P < 0.05$ was deemed statistically significant.

Results

Patient characteristics

From January 2007 to June 2016, we treated 319 patients who presented with symptomatic malignant airway obstruction of the trachea and/or major bronchus, histologically confirmed primary squamous cell lung cancer (*Figure 1*). A total of 206 patients received cisplatin plus Endostar intratumoral injection, and 113 without injection. Lung function was not evaluated in 20 patients due to severe symptoms. No significant differences were observed between the two groups at baseline (*Table 1*).

Treatment effect

Dyspnea grade, degree of stenosis, KPS score, ECOG score and lung function of all patients were significantly improved at 1 week after treatment compared with baseline (*Table 2*, $P < 0.05$). Both groups achieved good airway patency (97.1%

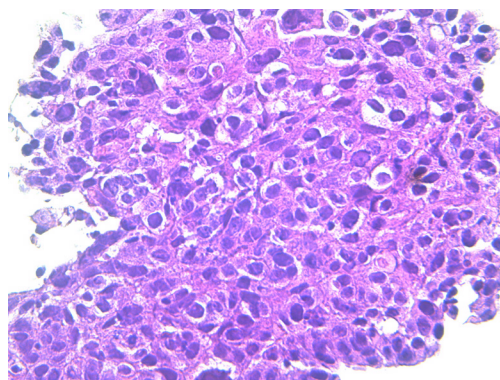


Figure 1 Primary squamous cell carcinoma of the trachea (HE staining, $\times 400$).

vs. 93.8%, $P=0.156$). There was no statistical difference in all the parameters between the two groups at 1 week ($P>0.05$).

Followed up at 2 months, dyspnea grade, degree of stenosis, quality of life and lung function were improved in the injection group compared with baseline ($P<0.05$), while no statistical differences were found in the non-injection group ($P>0.05$). The injection group achieved airway patency in 155 (75.2%) of 206 patients (Figure 2), which was significantly superior to the non-injection group [20 (17.7%) of 113, $P<0.001$]. In addition, the restenosis rate of the injection group was lower compared with the non-injection group (22.5% vs. 81.1%, $P<0.001$, respectively).

Table 1 Patient characteristics

Characteristics	Injection (n=206)	Non-injection (n=113)	P value
Age (years)	61.6 \pm 8.2	56.7 \pm 6.9	0.055
Gender (M/F)	188/18	99/14	0.299
BMI (kg/m ²)	23.7 \pm 3.3	24.1 \pm 4.6	0.214
Smoking status			0.891
Never smoker	64	33	
Ex-smoker	133	74	
Current smoker	9	6	
Tumor distribution(n)			
Trachea	84	50	–
Left main bronchus	105	61	–
Right main bronchus	63	30	–
Concurrent systemic Rx			0.490
Chemotherapy	125	73	
Radiation	0	0	
None	81	40	
Dyspnea grade	3.4 \pm 1.2	3.5 \pm 0.9	0.165
Degree of stenosis (%)	81.2 \pm 9.6	76.7 \pm 7.8	0.057
KPS	63.1 \pm 2.4	60.2 \pm 4.5	0.256
ECOG	2.6 \pm 0.8	2.3 \pm 0.6	0.059
FEV ₁ (L)	0.91 \pm 0.21	0.88 \pm 0.34	0.635
FEV ₁ /FVC (%)	50.17 \pm 7.15	53.16 \pm 4.70	0.301

Results are expressed as means \pm standard deviation. FEV₁, forced expiratory volume in 1 second; FVC, forced vital capacity; KPS, Karnofsky performance scale; ECOG, Eastern Cooperative Oncology Group; BMI, body mass index.

Table 2 Efficacy at 1 week and 2 months

Efficacy	Injection (n=206)		Non-injection (n=113)	
	1 week	2 months	1 week	2 months
Dyspnea grade	1.1±0.6	1.5±0.5	1.3±0.4	2.9±0.3
Degree of stenosis (%)	32.2±5.2	36.4±7.1	34.1±3.5	68.7±3.9
KPS	86.3±6.9	80.4±3.3	87.1±3.4	65.5±2.8
ECOG	0.6±0.4	0.9±0.3	0.7±0.4	2.1±0.3
FEV ₁ (L)	1.35±0.17	1.26±0.21	1.37±0.23	0.98±0.22
FEV ₁ /FVC (%)	59.16±5.25	57.25±3.46	58.24±3.13	53.78±5.32

Results are expressed as means ± standard deviation. FEV₁, forced expiratory volume in 1 second; FVC, forced vital capacity; KPS, Karnofsky performance scale; ECOG, Eastern Cooperative Oncology Group.

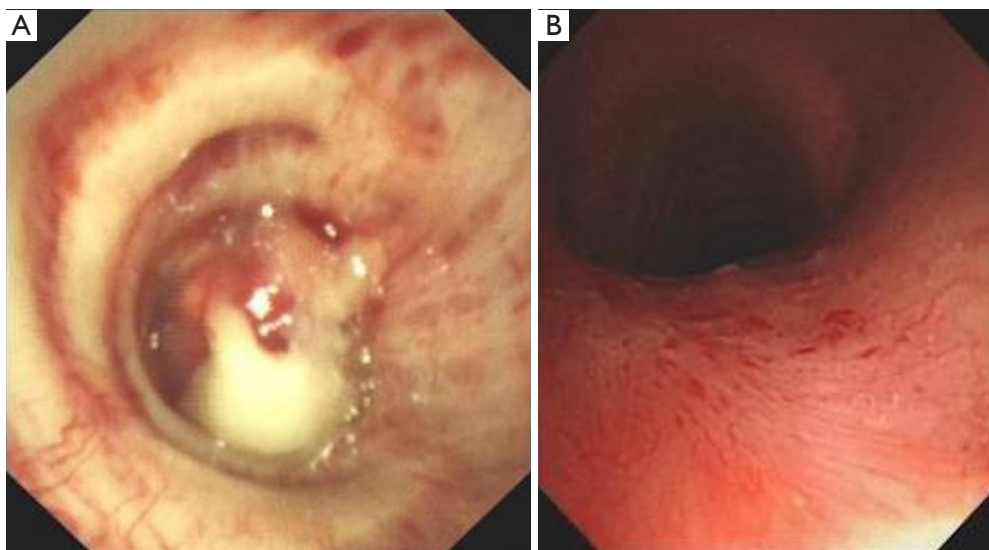


Figure 2 Intratumoral injection of primary squamous cell carcinoma of trachea. (A) Tumor visualization prior to treatment; (B) 2 months after treatment.

Table 3 Complications

Complication	Injection (n=206)	Non-injection (n=113)	P value
Mild hemorrhage	41 (19.9)	15 (13.3)	0.137
Nausea	36 (17.5)	10 (8.8)	0.101
Vomiting	11 (5.3)	8 (7.1)	0.530
Lung infection	2 (1.0)	1 (0.9)	0.939
Cough	60 (29.1)	41 (36.3)	0.189
Fever	14 (6.8)	10 (8.8)	0.506

Data presented as n (%).

Complications

There was no statistically significant difference between groups in terms of complications (*Table 3*). Patients had mild hemorrhage during the endobronchial treatment and were easily stopped by argon and/or cold saline. Gastrointestinal reaction was observed occasionally post treatment, which was improved after a single dose of metoclopramide administered by intramuscular injection. Three patients had lung infection post treatment and were cured in 7 days. A few patients had transient cough or low fever post-procedure, which were improved significantly in 3 days. No

local adverse effects such as fistula formation or mediastinal abscess were noted in the follow-up.

Discussion

Our results indicated that cisplatin plus rh-endostatin intratumoral injection could improve the patency of airways occluded by endobronchial malignant tumor. Cisplatin was commonly used for the treatment of lung cancer as a part of combination systemic chemotherapy (16), and it also had been used intralesionally for head, neck, liver cancers, esophageal cancers and gastric tumors (17-20). The present work confirmed and extended previously reported favorable experience with cisplatin intratumoral injection on lung cancer (21,22). Although Endostar was proved to be effective in treatment of lung cancer combined with another chemotherapy (23,24), there were no reports of MCAO treated with bronchoscopic intratumoral injection of Endostar, let alone combined with cisplatin.

In this study, cisplatin plus Endostar showed a good response in majority of patients. Therapeutic bronchoscopy has been shown to palliate symptoms, improve spirometry, functional capacity, quality of life and survival in patients with MCAO (25-27). Multiple techniques are often used for the recanalization of airway, but the stenosis will recur in 1 to 3 months (7). Our results showed that the rate of restenosis was less in intratumoral injection group when compared with debulking alone. Improvement in clinical benefit parameters supported the therapeutic potential of intratumoral injection and offered another choice for MCAO. Regarding safety, intratumoral injection was also well tolerated. Treatment with intratumoral injection did not increase adverse event.

The main limitation was the retrospective nature of the study, which resulted in selection bias. Furthermore, because of the short follow-up period, the long-term treatment effect was not available. Prospective multicenter randomized trials should be conducted to determine whether intratumoral injection combined with debulking is superior to debulking alone.

Conclusions

Our findings have highlighted significant therapeutic potential of cisplatin plus rh-endostatin intratumoral injection for MCAO caused by primary squamous cell lung cancer.

Acknowledgments

Funding: None.

Footnote

Data Sharing Statement: Available at <http://dx.doi.org/10.21037/jtd-20-1493>

Conflicts of Interest: All authors have completed the ICMJE uniform disclosure form (available at <http://dx.doi.org/10.21037/jtd-20-1493>). The authors have no conflicts of interest to declare.

Ethical Statement: The authors are accountable for all aspects of the work in ensuring that questions related to the accuracy or integrity of any part of the work are appropriately investigated and resolved. The study was conducted in accordance with the Declaration of Helsinki (as revised in 2013) and informed consent was taken from all the patients.

Open Access Statement: This is an Open Access article distributed in accordance with the Creative Commons Attribution-NonCommercial-NoDerivs 4.0 International License (CC BY-NC-ND 4.0), which permits the non-commercial replication and distribution of the article with the strict proviso that no changes or edits are made and the original work is properly cited (including links to both the formal publication through the relevant DOI and the license). See: <https://creativecommons.org/licenses/by-nc-nd/4.0/>.

References

1. He J, Gu D, Wu X, et al. Major causes of death among men and women in China. *N Engl J Med* 2005;353:1124-34.
2. She J, Yang P, Hong Q, et al. Lung cancer in China: challenges and interventions. *Chest* 2013;143:1117-26.
3. Chen W, Zheng R, Baade PD, et al. Cancer statistics in China, 2015. *CA Cancer J Clin* 2016;66:115-32.
4. Wang H, Zhang N, Li D, et al. Analysis of 881 cases of central airway cancer. *Chinese Journal of Tuberculosis and Respiratory Diseases* 2014;37:148-9.
5. Bolliger CT, Sutudja TG, Strausz J, et al. Therapeutic bronchoscopy with immediate effect: laser, electrocautery, argon plasma coagulation and stents. *Eur Respir J* 2006;27:1258-71.
6. Wang H, Zhang N, Li D, et al. *Zhongguo Fei Ai Za Zhi*

- 2016;19:854-8.
7. Tao M, Wang H, Zhou Y, et al. Interventional therapy by bronchoscope on trachea adenoid cystic carcinoma in end stage. *International Journal of Respiration* 2013;33:911-4.
 8. Mehta HJ, Jantz MA. Endobronchial Ultrasound-guided Intratumoral Injection of Cisplatin for the Treatment of Isolated Mediastinal Recurrence of Lung Cancer. *J Vis Exp* 2017;(120):54855.
 9. Cheng Q, Li L, Jia D. Anesthesia management of bronchoscope intervention complications. *Chinese Journal of Minimally Invasive Surgery* 2009;9:954-5.
 10. Wang H, Zhou Y, Li D, et al. Clinical application of video-assisted rigid bronchoscopy in the treatment of airway stenosis. *Zhongguo Fei Ai Za Zhi* 2011;14:367-72.
 11. Schag CC, Heinrich RL, Ganz PA. Karnofsky performance status revisited: reliability, validity, and guidelines. *J Clin Oncol* 1984;2:187-93.
 12. Oken MM, Creech RH, Tormey DC, et al. Toxicity and response criteria of the Eastern Cooperative Oncology Group. *Am J Clin Oncol* 1982;5:649-55.
 13. Stulberg RC, Adams L. *Text book of medicine(M)*. Philadelphia: Saunders, 1994:511-2.
 14. Freitag L, Ernst A, Unger M, et al. A proposed classification system of central airway stenosis. *Eur Respir J* 2007;30:7-12.
 15. Kızılgöz D, Aktaş Z, Yılmaz A, et al. Comparison of two new techniques for the management of malignant central airway obstruction: argon plasma coagulation with mechanical tumor resection versus cryorecanalization. *Surg Endosc* 2018;32:1879-84.
 16. Sandler AB, Nemunaitis J, Denham C, et al. Phase III trial of gemcitabine plus cisplatin versus cisplatin alone in patients with locally advanced or metastatic non-small-cell lung cancer. *J Clin Oncol* 2000;18:122-30.
 17. Burris HA 3rd, Vogel CL, Castro D, et al. Intratumoral cisplatin/epinephrine-injectable gel as a palliative treatment for accessible solid tumors: a multicenter pilot study. *Otolaryngol Head Neck Surg* 1998;118:496-503.
 18. Vogl TJ, Engelmann K, Mack MG, et al. CT-guided intratumoural administration of cisplatin/epinephrine gel for treatment of malignant liver tumours. *Br J Cancer* 2002;86:524-9.
 19. Monga SP, Wadleigh R, Adib H, et al. Endoscopic treatment of gastric cancer with intratumoral cisplatin/epinephrine injectable gel: a case report. *Gastrointest Endosc* 1998;48:415-7.
 20. Monga SP, Wadleigh R, Sharma A, et al. Intratumoral therapy of cisplatin/epinephrine injectable gel for palliation in patients with obstructive esophageal cancer. *Am J Clin Oncol* 2000;23:386-92.
 21. Celikoglu F, Celikoglu SI, York AM, et al. Intratumoral administration of cisplatin through a bronchoscope followed by irradiation for treatment of inoperable non-small cell obstructive lung cancer. *Lung Cancer* 2006;51:225-36.
 22. Mehta HJ, Begnaud A, Penley AM, et al. Restoration of Patency to Central Airways Occluded by Malignant Endobronchial Tumors Using Intratumoral Injection of Cisplatin. *Ann Am Thorac Soc* 2015;12:1345-50.
 23. Zhou S, Zuo L, He X, et al. Efficacy and safety of rh-endostatin (Endostar) combined with pemetrexed/ cisplatin followed by rh-endostatin plus pemetrexed maintenance in non-small cell lung cancer: A retrospective comparison with standard chemotherapy. *Thorac Cancer* 2018;9:1354-60.
 24. An J, Lv W. Endostar (rh-endostatin) versus placebo in combination with vinorelbine plus cisplatin chemotherapy regimen in treatment of advanced non-small cell lung cancer: A meta-analysis. *Thorac Cancer* 2018;9:606-12.
 25. Mudambi L, Miller R, Eapen GA. Malignant central airway obstruction. *J Thorac Dis* 2017;9:S1087-110.
 26. Ost DE, Ernst A, Grosu HB, et al. Therapeutic bronchoscopy for malignant central airway obstruction: success rates and impact on dyspnea and quality of life. *Chest* 2015;147:1282-98.
 27. Stratakos G, Gerovasili V, Dimitropoulos C, et al. Survival and Quality of Life Benefit after Endoscopic Management of Malignant Central Airway Obstruction. *J Cancer* 2016;7:794-802.

Cite this article as: Zhou Y, Gao Y, Zhang N, Li X, Wang H, Wang S, Liu J, Gao H, Wang H. Clinical effects of cisplatin plus recombinant human endostatin (rh-endostatin) intratumoral injection on malignant central airway obstruction: a retrospective analysis of 319 cases. *J Thorac Dis* 2021;13(2):1100-1105. doi: 10.21037/jtd-20-1493