



## Novel treatment of coronary artery fistulae concealing severe coronary artery lesion: using thrombus aspiration catheter as a delivery guide

Levent Korkmaz<sup>1</sup>, Zeydin Acar<sup>1</sup>, İhsan Dursun<sup>1</sup>, Ali Rıza Akyüz<sup>2</sup>, Ayca Ata Korkmaz<sup>3</sup>

<sup>1</sup>Department of Cardiology, Ahi Evren Thoracic And Cardiovascular Surgery Training And Research Hospital, Trabzon 61100, Turkey

<sup>2</sup>Department of Cardiology, Akçaabat Hackali Baba State Hospital, Trabzon 61300, Turkey

<sup>3</sup>Department of Radiology, Akçaabat Hackali Baba State Hospital, Trabzon 61300, Turkey

### Abstract

In this case report, we present the occlusion of multiple coronary artery fistulae originating from proximal left anterior descending (LAD) and right sinus valsalva and emptying to the pulmonary artery at the same place. We occluded LAD fistulae by using thrombus aspiration catheter as a delivery guide. To the best of our knowledge, this is the first case of occlusion of coronary fistulae with the help of thrombus aspiration catheter. Our experience may suggest that thrombus aspiration catheters can be used in treating coronary artery fistulae with difficult anatomy.

*J Geriatr Cardiol* 2014; 11: 90–92. doi: 10.3969/j.issn.1671-5411.2014.01.006

**Keywords:** Catheter; Coronary artery fistulae; Coronary angiography; Left anterior descending

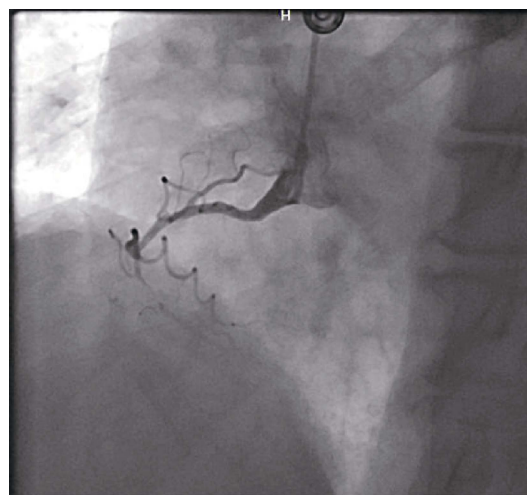
## 1 Introduction

Coronary artery fistulae (CAF) are abnormal connections between coronary arteries and cardiac chambers (coronary-cameral) or major intrathoracic vessel (arteriovenous).<sup>[1,2]</sup> Most coronary fistulae are congenital. In general, they are asymptomatic and discovered about 0.1% of adult patients undergoing routine coronary angiography. In rare cases, they may cause angina or symptoms related to the hemodynamic repercussions of significant arteriovenous shunt such as fatigue, dyspnoea and heart failure. Transcatheter closure of CAF is feasible and should be considered in symptomatic patients. In this case, we report a symptomatic patient with multiple CAF and significant left anterior descending artery stenosis that was concealed by CAF

## 2 Case report

A 83 years old man with diagnosis of unstable angina pectoris who underwent coronary angiography in a different hospital was referred to us for occlusion of CFA originating

from left anterior descending (LAD) and emptying to the pulmonary artery. He had huge CAF (Video 1) and subtotal stenosis of mid right coronary artery (RCA) lesion (Figure 1).



**Figure 1.** Coronary angiography showed subtotal stenosis of mid right coronary artery (RCA) lesion.

Decision of closure of fistulae with amplatzer vascular plug 4 and stenting of right coronary artery mid lesion was taken. At first, we aimed to treat mid RCA lesion. During the engagement of RCA ostium, another fistulae was detected (Video 2). It was originating from right sinus valsalva and most likely communicating to pulmonary artery. Then,

**Correspondence to:** Ali Rıza Akyüz, MD, Department of Cardiology, Akçaabat Hackali Baba State Hospital, Trabzon 61300, Turkey. E-mail: dralirizaakyuz@gmail.com

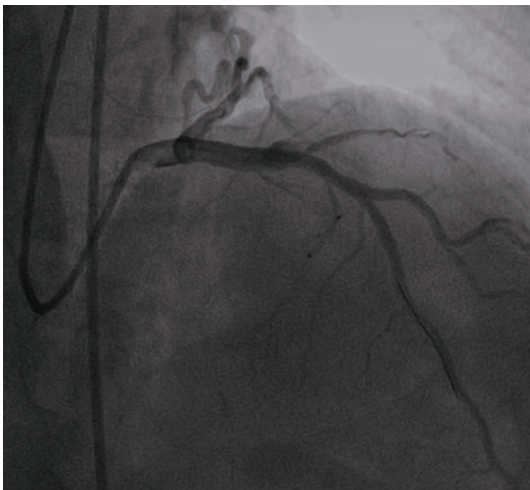
**Telephone:** +90-462-2277777 **Fax:** +90-462-22777 89

**Received:** November 25, 2013 **Revised:** March 2, 2014

**Accepted:** March 17, 2014 **Published online:** March 25, 2014

we engaged left coronary artery ostium with 7F Judkings guiding catheter. Sequential and simultaneous contrast injection demonstrated that both of fistulae were opening to the pulmonary artery at the same place (Video 3). We decided to occlude left sided CAF at first. Vigorous attempts were done to proceed multi-purpose and right Judkings catheter through fistulae. But we could not succeed. Then, we decided to use thrombus aspiration catheter (TAC) as a delivery guide. After wiring the fistula with the 0.014-inch guidewire, TAC was advanced over the guidewire. After the optimal position of aspiration catheter was obtained (Video 4), amplatzer vascular plug (AVP) was loaded into the aspiration catheter and advanced carefully. After the optimal device position was assured, vascular plug was released and control image demonstrated completely closure of fistulae and significant LAD stenosis just distal to the origin of fistulae that was not seen in previous coronary angiography (Video 5, 6). We gave nitroglycerine in order to be sure that this image was not due to the spasm. There was no effect of nitroglycerine and lesion was stented with 3.5 mm × 15 mm bare metal stent and postdilated with 4 mm × 12 mm noncompliant balloon. Final image was satisfactory. Because of high dose use of contrast media (about 300 mL) and patient renal function (creatinine was 1.6), the other CAF was untreated.

After a month later, patient was taken to the catheter laboratory for occlusion of second coronary to pulmonary artery fistulae. Control image demonstrated patent LAD stent and occluded fistulae (Figure 2). Vascular plug 2 was loaded in guiding catheter and was advanced as further as possible. After confirming the correct position of device (Video 7), it was released. Control image demonstrated totally occlusion of fistulae (Video 8).



**Figure 2.** Control image 3 months after intervention demonstrated patent LAD stent and occluded fistulae.

### 3 Discussion

Congenital coronary artery fistula is a rare malformation that may involve any or all coronary artery branches and any cardiac chamber. Elective closure of coronary artery fistula by surgery or percutaneous transcatheter technique is generally accepted in the presence of symptoms.<sup>[3]</sup> Although surgical ligation has been performed for CAF,<sup>[4]</sup> the transcatheter approach may be preferred over the surgical approach due to lower cost, shorter recovery time, and less morbidity, including avoidance of thoracotomy or sternotomy and cardiopulmonary bypass.<sup>[5]</sup> Multiple different transcatheter techniques have been used successfully including coils<sup>[6,7]</sup> detachable balloons<sup>[8,9]</sup> umbrellas<sup>[10]</sup> polyvinyl alcohol foam<sup>[11]</sup> and other occlusive devices.<sup>[12]</sup>

The vascular plug is made of nitinol, a shape memory alloy of nickel and titanium. It is generally loaded into diagnostic angiography catheters in order to advance the device to the target area. Eventhough we followed the same principles by using different types of catheters, we couldn't succeed to advance the catheter to the fistulae because of anatomical reasons. Therefore, we decided to use thrombus aspiration catheter as a delivery guide given that it is more flexible and easy to advance in coronary arteries. We loaded the device into TAC and advanced it to the fistulae with a bit difficulty.

According to the best of our knowledge, this is the first case of using TAC as a delivery guide for treating coronary fistulae. Thrombus aspiration catheters can be used in cases with difficult anatomy that prevents the diagnostic catheters advancing through fistulae.

### References

- 1 Mangukia CV. Coronary artery fistula. *Ann Thorac Surg* 2012; 93: 2084–2092.
- 2 Luo L, Kebede S, Wu S, *et al.* Coronary artery fistulae. *Am J Med Sci* 2006; 332: 79–84.
- 3 Jama A, Barsoum M, Bjamason H, *et al.* Percutaneous closure of congenital coronary artery fistulae: results and angiographic follow-up. *JACC Cardiovasc Interv* 2011; 4: 814–821.
- 4 Kamiya H, Yasuda T, Nagamine H, *et al.* Surgical treatment of congenital coronary artery fistulas: 27 years' experience and a review of the literature. *J Card Surg* 2002; 17: 173–177.
- 5 Zhu XY, Zhang DZ, Han XM, *et al.* Transcatheter closure of congenital coronary artery fistulae: immediate and long-term follow-up results. *Clin Cardiol* 2009; 32: 506–512.
- 6 Reidy JF, Anjos RT, Qureshi SA, *et al.* Transcatheter embolization in the treatment of coronary artery fistulas. *J Am Coll Cardiol* 1991; 18: 187–192.
- 7 Issenberg HJ. Transcatheter coil closure of a congenital coro-

- nary arterial fistula. *Am Heart J* 1990; 120: 1441–1443.
- 8 Hartnell GG, Jordan SC. Balloon embolisation of a coronary arterial fistula. *Int J Cardiol* 1990; 29: 381–383.
- 9 Skimming JW, Gessner IH, Victorica BE, *et al.* Percutaneous transcatheter occlusion of coronary artery fistulas using detachable balloons. *Pediatr Cardiol* 1995; 16: 38–41.
- 10 Perry SB, Rome J, Keane JF, *et al.* Transcatheter closure of coronary artery fistulas. *J Am Coll Cardiol* 1992; 20: 205–209.
- 11 Strunk BL, Hieshima GB, Shafton EP. Treatment of congenital coronary arteriovenous malformations with micro-particle embolization. *Cathet Cardiovasc Diagn* 1991; 22: 133–136.
- 12 McMahon CJ, Nihill MR, Kovalchin JP, *et al.* Coronary artery fistula. Management and intermediate-term outcome after transcatheter coil occlusion. *Tex Heart Inst J* 2001; 28: 21–25.