

Primary cardiac fibroma in infants: A case report and review of cases of cardiac fibroma managed through orthotopic heart transplant

Moises Rodriguez-Gonzalez¹, Alvaro A. Pérez-Reviriego¹, Elena Gómez-Guzmán²,
María Ángeles Tejero-Hernández², Alicia Zorrilla Sanz³, Israel Valverde⁴

¹Pediatric Cardiology Department, Puerta del Mar University Hospital, Cadiz, Spain, ²Pediatric Cardiology Department, Reina Sofia University Hospital, Córdoba, Spain, ³Department of Pathology and Laboratory Medicine Clinical Anatomic Pathology of Reina Sofia University Hospital, Córdoba, Spain, ⁴Pediatric Cardiology Unit, Virgen del Rocío University Hospital/Institute of Biomedicine of Sevilla (IBIS) of Seville, CIBER-CV, Seville, Spain

ABSTRACT

Cardiac fibromas (CF) are the second most common cardiac tumors in children. They can be aggressive tumors despite their benign histopathologic nature, accounting for the highest mortality rate among primary cardiac tumors. CF usually show a progressive growth and spontaneous regression is rare. Therefore, a complete surgical excision is the preferred therapeutic approach when patients become symptomatic or if mass-related life-threatening complications are anticipated, even in asymptomatic patients. However, some cases are not good candidates for surgical excision due to the impossibility of preserving a normal cardiac anatomy or function after the tumor resection. Orthotopic heart transplantation (OHT) can be an exceptional but adequate alternative for some giant unresectable CF in children. In this article, we report our experience with the case of a 7-month-old infant with a giant unresectable cardiac fibroma who was successfully managed through OHT.

Keywords: Cardiac fibroma, orthotopic heart transplant, infants.

INTRODUCTION

Cardiac fibromas (CF) are the second most common cardiac tumors (20%) in children. The clinical presentation includes heart murmurs, heart failure, ventricular arrhythmias, and even sudden cardiac death, but patients asymptomatic at presentation are also at risk of future complications. Complete surgical excision is the preferred therapeutic approach when patients become symptomatic or if mass-related life-threatening complications are anticipated, even in asymptomatic patients.^[1] However, some cases are not good candidates for surgical excision due to the impossibility to preserve a normal cardiac anatomy or function.^[2] In this article, we report our experience with the case of an infant with a giant unresectable cardiac fibroma that was successfully managed through orthotopic heart transplantation (OHT).

CASE REPORT

A previously healthy 7-month-old girl was referred to our pediatric cardiology outpatient clinic for evaluation of a heart murmur. She was asymptomatic. Prenatal echocardiographic studies showed no anomalies. The latest physical exam at 4 months of age was unremarkable. The 12-lead-electrocardiogram (ECG) showed no anomalies. The chest X-ray showed a global cardiomegaly. A transthoracic echocardiogram revealed a noncontractile heterogeneous solid large mass (35 mm × 40 mm) located at the muscular interventricular septum (IVS), which caused a moderate left ventricular outflow tract obstruction (LVOTO) [Figure 1]. The

This is an open access journal, and articles are distributed under the terms of the Creative Commons Attribution-NonCommercial-ShareAlike 4.0 License, which allows others to remix, tweak, and build upon the work non-commercially, as long as appropriate credit is given and the new creations are licensed under the identical terms.

For reprints contact: WKHLRPMedknow_reprints@wolterskluwer.com

How to cite this article: Rodriguez-Gonzalez M, Pérez-Reviriego AA, Gómez-Guzmán E, Tejero-Hernández MÁ, Sanz AZ, Valverde I. Primary cardiac fibroma in infants: A case report and review of cases of cardiac fibroma managed through orthotopic heart transplant. *Ann Pediatr Card* 2021;14:224-7.

Access this article online

Quick Response Code:



Website:

www.annalspc.com

DOI:

10.4103/apc.APC_78_20

Address for correspondence: Dr. Moises Rodriguez-Gonzalez, 34th of Ana de Viya Avenue, Cadiz PC 11100, Spain. E-mail: moirogo@gmail.com

Submitted: 19-Apr-2020

Revised: 30-May-2020

Accepted: 20-Oct-2020

Published: 10-Apr-2021

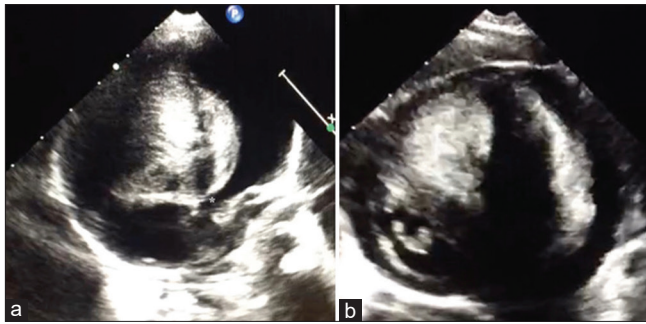


Figure 1: Transthoracic echocardiography. (a) corresponds to an apical 5-chamber view that revealed a giant mass (35 mm × 40 mm) located at the IVS involving the cardiac crux. The mass produces a narrowing of the left ventricular outflow tract, with a minimum diameter of 3 mm (asterisk). (b) corresponds to a posterior parasternal short axis view that shows the giant mass occupying practically all of the ventricular cavities. IVS: Interventricular septum

cardiac magnetic resonance imaging (MRI) findings were consistent with a giant CF on the IVS that produced a very extensive occupation of both ventricles with mechanical LVOTO [Figure 2]. The endomyocardial biopsy confirmed the CF [Figure 3]. The coronarography showed a displacement of the trajectory of the main coronary arteries, which were partially draped over the mass, with no perfusion defects. During the admission, the patient remained asymptomatic, but frequent ventricular ectopia and episodes of nonsustained ventricular tachycardia were recorded on the continuous ECG-monitoring. These episodes disappeared after starting propranolol 1 mg/kg/day.

Based on the occurrence of ventricular arrhythmias and the risk of sudden cardiac death, the decision of the multidisciplinary meeting was to favor surgical intervention over a conservative approach. Due to its location and size, surgical resection was excluded because of the potential risk of damaging essential cardiac structures and of leaving not enough residual functional myocardium. An OHT was selected as the definitive therapy. The patient was successfully transplanted through the bi-caval anastomosis technique at 11 months of age. The macroscopic examination of the explanted heart revealed a large fibrous, white, and nonencapsulated tumor (40 mm × 31 mm × 43 mm) localized within the IVS and bulging into both ventricles. The microscopic examination confirmed the diagnosis of CF [Figure 3]. At the latest follow-up (4 years old), the patient remained asymptomatic on treatment with tacrolimus and everolimus, without any complication.

DISCUSSION

CF can be aggressive tumors despite their benign histopathologic nature. Thus, they account for the highest mortality rate (20%–33%) among primary

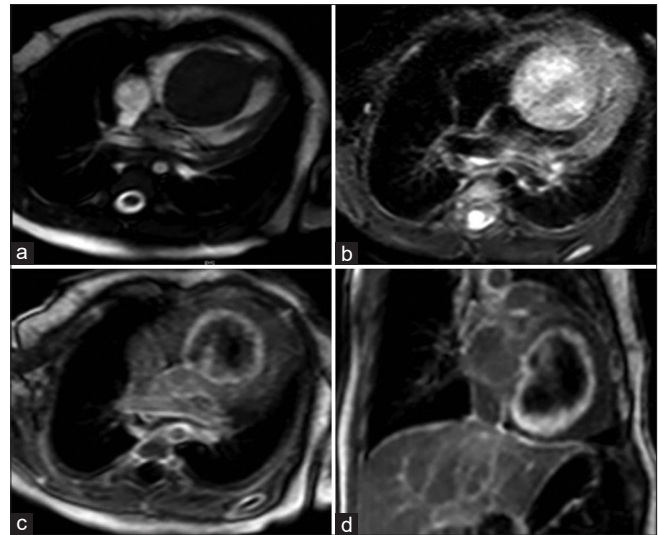


Figure 2: Cardiac magnetic resonance imaging. The cardiac magnetic resonance imaging showed a large solitary tumor confined at the IVS measuring 36 cm × 35 cm × 46 mm, occupying most of both ventricular cavities. The mass was homogeneously isointense on T1-weighted imaging (a), and slightly hyperintense on T2-weighted imaging (b), with no hypocaptant lesions inside. There was a heterogeneous hypercaptation in the external wall of the tumor, with internal hypocaptation in late gadolinium enhancement sequences (c and d)

cardiac tumors. Although CF can be encapsulated, they are usually nonencapsulated masses. This nature favors the infiltration and the replacement of the contiguous functioning myocardium and the conduction system, leading to low cardiac output and ventricular arrhythmias. CF has a high incidence of ventricular arrhythmia (64%–89%) and sudden cardiac death (10%–30%).^[2] CF usually grows progressively with somatic cardiac growth and spontaneous regression rarely occurs. Therefore, asymptomatic patients at presentation are also at risk of future complications. Thus, a timely and complete surgical resection has been advocated for asymptomatic cases if mass-related life-threatening complications are anticipated. This occurs in tumors of large size, IVS location, and producing inflow–outflow obstruction or ventricular arrhythmias. The main limitation of this approach is the location being near to essential cardiac structures, such as coronary arteries and the conduction system, which could be injured during the surgical procedure. Furthermore, in the case of large tumors, the resection may leave insufficient myocardial mass, causing severe impairment of the myocardial function. Of note, most cases of death, failure from weaning off cardiopulmonary bypass, and the need for postoperative extracorporeal membrane oxygenation support after surgical resection of CF are reported in large tumors involving the superior IVS and crux of the heart.^[3] Subtotal resection can also be a good option to avoid the damage of essential structures, but it could be concerning to leave some tumoral mass in the heart in

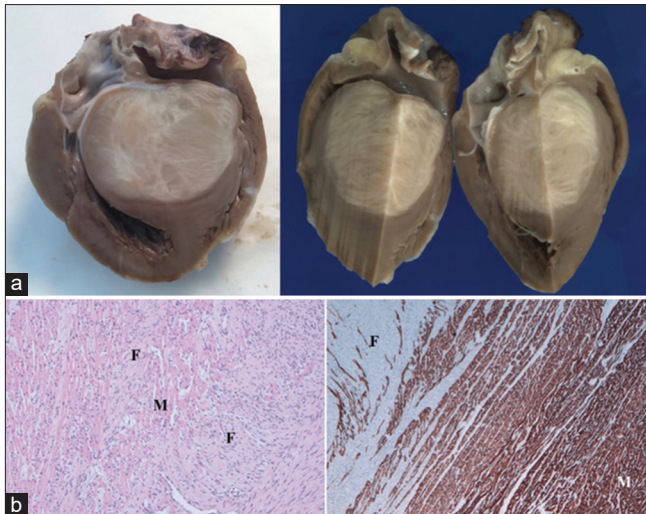


Figure 3: Pathology. (a) corresponds to the macroscopic examination. The explanted heart weighed 64 g, and contained a large (4 cm × 3.1 cm × 4.3 cm), nonencapsulated, solid, fasciculated, firm, and white/gray mass, without necrosis or cystic degeneration. The mass was localized within the interventricular septum and extended from the apex to the base, including the cardiac crux and compressing the coronary arteries. The tumor was bulging into both ventricles, occupying practically whole of both ventricular cavities. The (b)-left image corresponds to the microscopic examination of the tumor obtained by endomyocardial biopsy. The tumor was composed of monomorphic spindle cells arranged in a collagen stroma, with abundant elastic fibers, showing little or no atypia. The anatomopathological study showed infiltrate into the uninvolved cardiac muscle (M) as bands of fibroblasts (F) (H and E, ×100). The (b)-right image corresponds to the microscopic examination of the tumor in the explanted heart. The anatomopathological study revealed a cardiac muscle showing high immunoreactivity for desmin (m) which contracts with fibroblastic cells negativity (f) (Desmin, ×40). T: Tumor, LV: Left ventricle, RV: Right ventricle

those cases with documented ventricular arrhythmia as was the case for our patient. In these challenging cases, OHT may remain the only therapeutic option.

Our case constitutes one of the few published cases of CF managed by OHT in children [Table 1].

Similarly to our case, the OHT has always been indicated in patients with large size masses located at the IVS or the LV free wall, occupying a large percentage of the ventricular cavity and producing ventricular arrhythmias or heart failure. Furthermore, most OHTs have been performed in small infants younger than 2 years old. There has been no early mortality related to the surgical procedure. The long-term follow-up of most cases is limited due to the case report nature of publications, but most worrisome is that four patients died due to late OHT complications. Of note, in three cases a surgical resection was attempted before the OHT, and the three patients needed an urgent OHT due to severe ventricular dysfunction secondary to coronary artery damage or large myocardial mass resection.^[3,5,9] The only study that compares outcomes between OHT and surgical resection found a reduced long-term survival of patients managed by OHT.^[9] Therefore, the authors advised that surgical resection should be attempted whenever possible, even in large masses.

In summary, OHT can be an exceptional but adequate alternative for some giant unresectable CF in children. Complete surgical resection is the preferred therapeutic option for symptomatic patients or those asymptomatic patients perceived as high-risk cases for sudden death. If a surgical resection is going to be attempted for high-risk

Table 1: Characteristics of the cases of pediatric cardiac fibroma managed by orthotopic heart transplantation that we found in our literature review

Reference	Age at OHT	Tumor Location	Clinical presentation	Previous procedure	Urgent OHT	Outcomes
Jamieson et al. (1981)	17 years	LV free wall	?	-	-	Exitus (AR 75 months after OHT)
Marx et al. (1991)	2 years	LV free wall	?	-	-	Exitus (AR 8 months after OHT)
Valente et al. (1993)	2 months	LV free wall	?	-	-	Alive (36 months after OHT)
Michler et al. (1997)	3 months	LV free wall	?	-	-	Alive (105 months after OHT)
Beghetti et al. ^[4]	1 month	IVS	VA	-	-	Alive (4 months after OHT)
Stiller et al. ^[5]	5 months	LV free wall	CHF	Partial resection	Yes	Alive (20 months after OHT)
Waller et al. ^[6]	7 months	IVS	CHF	Systemic to pulmonary fistula	-	Alive (5.5 years after OHT)
Sharma et al. ^[7]	13 years	IVS	VA	Defibrillator implantation	-	Alive (2 years after OHT)
Kobayashi et al. ^[8]	6 months	IVS	CHF	-	-	Alive (3 years after OHT)
	7 months	IVS	CHF	-	-	Alive (19 months after OHT)
Padalino et al. ^[2]	?	?	CHF	-	-	Exitus (cerebral tumor 3 years after OHT)
	?	?	CHF	-	-	Exitus (AR 11 years after OHT)
	?	?	CHF	-	-	Alive (?) (mean follow-up in the study of 6.33 years)
Prakash Rajakumar et al. (2015) ^[9]	7 years	LV free wall	VA and CHF	Complete resection	Yes	Alive (18 months after OHT)
Liu et al. ^[10]	?	LV free wall	VA and CHF	-	-	Alive (2 years after OHT)
Delmo-Walter and Javier ^[3]	5 months	LV free wall	CHF	Complete resection	Yes	Alive (6 years after OHT)

Our case is not added to the table. ?: Data no available; CHF: Congestive heart failure, VA: Ventricular arrhythmia, OHT: Orthotopic heart transplantation, AR: Allograft rejection, LV: Left ventricular, IVS: Interventricular septum

tumors (IVS or cardiac crux location, large size, coronary compression), we think that it should be done in a center with an OHT program, to be ready for an urgent OHT if necessary.

Declaration of patient consent

The authors certify that they have obtained all appropriate patient consent forms. In the form the patient(s) has/have given his/her/their consent for his/her/their images and other clinical information to be reported in the journal. The patients understand that their names and initials will not be published and due efforts will be made to conceal their identity, but anonymity cannot be guaranteed.

Financial support and sponsorship

Nil.

Conflicts of interest

There are no conflicts of interest.

REFERENCES

1. Tzani A, Doulamis IP, Mylonas KS, Avgerinos DV, Nasioudis D. Cardiac tumors in pediatric patients: A systematic review. *World J Pediatr Congenit Heart Surg* 2017;8:624-32.
2. Padalino MA, Vida VL, Boccuzzo G, Tonello M, Sarris GE, Berggren H, *et al.* Surgery for primary cardiac tumors in children: Early and late results in a multicenter European Congenital Heart Surgeons Association study. *Circulation* 4 ed. 2012;126:22-30.
3. Delmo Walter EM, Javier MF. Primary cardiac tumors in infants and children: Surgical strategy and long-term outcome. *Ann Thorac Surg* 2016;102:2062-9.
4. Beghetti M, Gow RM, Haney I, Mawson J, Williams WG, Freedom RM. Pediatric primary benign cardiac tumors: A 15-year review. *Am Heart J* 1997;134:1107-14.
5. Stiller B, Hetzer R, Meyer R, Dittrich S, Pees C, Alexi-Meskishvili V, *et al.* Primary cardiac tumours: When is surgery necessary? *Eur J Cardiothorac Surg* 2001;20:1002-6.
6. Waller BR, Bradley SM, Crumbley AJ, Wiles HB, McQuinn TC, Bennett AT. Cardiac fibroma in an infant: Single ventricle palliation as a bridge to heart transplantation. *Ann Thorac Surg* 2003;75:1306-8.
7. Sharma K, Rohlicek C, Cecere R, Tchervenkov CI. Malignant arrhythmias secondary to a cardiac fibroma requiring transplantation in a Teenager. *J Heart Lung Transplant* 2007;26:639-41.
8. Kobayashi D, L'Ecuyer TJ, Aggarwal S. Orthotopic heart transplant: A therapeutic option for unresectable cardiac fibroma in infants. *Congenit Heart Dis* 2012;7:E31-6.
9. Prakash Rajakumar A, Ejaz Ahmed S, Varghese R, Kothandam S, Murmu UC, Sethuratnam R. Pediatric heart transplant for unresectable primary cardiac tumor. *Asian Cardiovasc Thorac Ann* 2017;25:207-9.
10. Liu X, Hong H, Zhang H, Xu Z, Liu J, Qiu L. Treatment strategies for primary tumors of the heart in children: A 10-year experience. *Ann Thorac Surg* 2015;100:1744-9.