

OPEN

Paraquat Poisoning in Patients With HIV Infection

A Case Report and Literature Review

Jun-Li Tsai, MD, Cheng-Hsu Chen, PhD, Ming-Ju Wu, PhD, and Shang-Feng Tsai, MD

Abstract: Paraquat poisoning is very severe. Most victims, including those who have ingested a small amount, will die from Paraquat poisoning. The cause of death in the majority of such cases is lung fibrosis. Paraquat poisoning in patients with positive human immunodeficiency virus (HIV) infection status has seldom been reported. Herein, we report a case of an HIV patient with Paraquat poisoning who had an excellent outcome even without standard treatment. Currently, only 3 such cases have been reported in the literature and in each case there was a good outcome, which was not expected according to predictive models. A possible mechanism may involve the relative lack of functional macrophages in HIV patients, which would tend to result in much less severe lung injury. None of the available predictive models of Paraquat poisoning appear to be appropriate for HIV patients.

Paraquat poisoning in HIV patients may have better survival due to less lung injury.

(*Medicine* 95(14):e3350)

Abbreviations: AKI = acute kidney injury, CT = computed tomography, CTX = cyclophosphamide, CXR = chest X-ray, HIV = human immunodeficiency virus, HP = hemoperfusion, MTP = methylprednisolone, PQ = paraquat, SCr = serum creatinine.

INTRODUCTION

Paraquat (PQ) poisoning has a dismal outcome even in those who ingest a small volume. There are multiple systems involved, among which, lung fibrosis is the most lethal. Acute respiratory distress syndrome is precipitated by high oxygen supplement due to free radical injury. Soon after PQ poisoning, lung fibrosis occurs. Most victims have a grave outcome after PQ poisoning but patients with human immunodeficiency virus (HIV) infection have rarely been reported. The small number of cases of HIV patients with PQ poisoning that have been reported in the literature had an excellent outcome, defying the expected

outcomes determined by the currently available predictive formulae. Herein, we report a patient with HIV infection who experienced severe PQ poisoning but survived with an excellent outcome. We provide a review of the literature on PQ poisoning in HIV patients.

CASE REPORT

A 30-year-old man with hepatitis C infection, HIV infection without treatment, and heroin addiction under methadone therapy (4 mg/d) presented to the emergency department 3 h after consuming 400 mL of herbicide containing 20% PQ due to suicide attempt. He did not have any mental disorder. There is no specific treatment for PQ poisoning. He poisoned himself after having an argument with his girlfriend. He had a severe sore throat after swallowing the herbicide. He received gastric lavage and drug screening revealed blood alcohol level of 127.9 mg/dL. His girlfriend witnessed the patient ingest PQ and confirmed that the swallowed fluid was PQ. The laboratory data showed serum creatinine (SCr) level of 0.8 mg/dL, Alanine transaminase (ALT) 122 U/L, and positive urine PQ test by colorimetry. Initially, he did not suffer from dyspnea and blood was well oxygenated (80 mm Hg of PaO₂ and 95% of SaO₂). Chest X-ray (CXR) on admission disclosed no lung infiltration. PQ concentration increased to 38 µg/mL in urine and up to 3 µg/mL in serum 3 h after PQ poisoning. He was transferred to the intensive care unit in preparation for hemoperfusion (HP) and a poor outcome was expected. After being informed he would likely suffer a poor outcome, he refused any treatment, including HP, infusion of steroid or cyclophosphamide (CTX), and O₂ therapy throughout the whole admission course. On day 3 of admission, he became dyspneic and showed expected desaturation (60.3 mm Hg of PaO₂ and 91.1% of SaO₂). Some infiltration over the lung bases was noted on CXR. Lung infiltration became more apparent over the lung bases suggesting greater alveolitis. Acute kidney injury (AKI) was also detected with elevation of SCr (6.9 mg/dL on 3rd day and 9.8 mg/dL on 5th day). However, the dyspnea and hypoxia improved from day 7 (74.1 mm Hg of PaO₂ and 95.3% of SaO₂) with improved renal dysfunction (2.5 mg/dL of SCr). In the 2nd week of admission, less dyspnea was found. Fourteen days after PQ poisoning, he was discharged without any complications, including normal renal function (1.2 mg/dL of SCr), clear CXR without lung fibrosis, no hypoxia (89 mm Hg of PaO₂ and 98.0% of SaO₂), and ALT of 56 U/L. During the whole course of admission, we only gave him intravenous fluid hydration and forced diuresis. The whole clinical course is summarized in Figure 1. This study had been approved by patient himself and he signed the informed consent.

DISCUSSION

Undoubtedly, PQ poisoning has a very high mortality rate because it typically causes multiple organ failure, especially lung fibrosis. According to the predictive model,¹ the chance

Editor: Sanket Patel.

Received: December 28, 2015; revised: March 11, 2016; accepted: March 15, 2016.

From the Department of Family Medicine (J-LT), Cheng Ching General Hospital; Division of Nephrology, Department of Internal Medicine (C-HC, M-JW, S-FT), Taichung Veterans General Hospital; School of Medicine (C-HC, M-JW, S-FT), China Medical University; Department of Life Science (C-HC, S-FT), Tunghai University; and Taichung; and Department of Medicine (S-FT), Nation Yang Ming University, Taipei, Taiwan.

Correspondence: Shang-Feng Tsai, Division of Nephrology, Department of Medicine, Taichung Veterans General Hospital, No. 160, Section 3, Chung-Kang Road, Taichung 407, Taiwan (e-mail: s881056@gmail.com).

The authors have no funding and conflicts of interest to disclose.

Copyright © 2016 Wolters Kluwer Health, Inc. All rights reserved.

This is an open access article distributed under the Creative Commons Attribution-NoDerivatives License 4.0, which allows for redistribution, commercial and non-commercial, as long as it is passed along unchanged and in whole, with credit to the author.

ISSN: 0025-7974

DOI: 10.1097/MD.0000000000003350

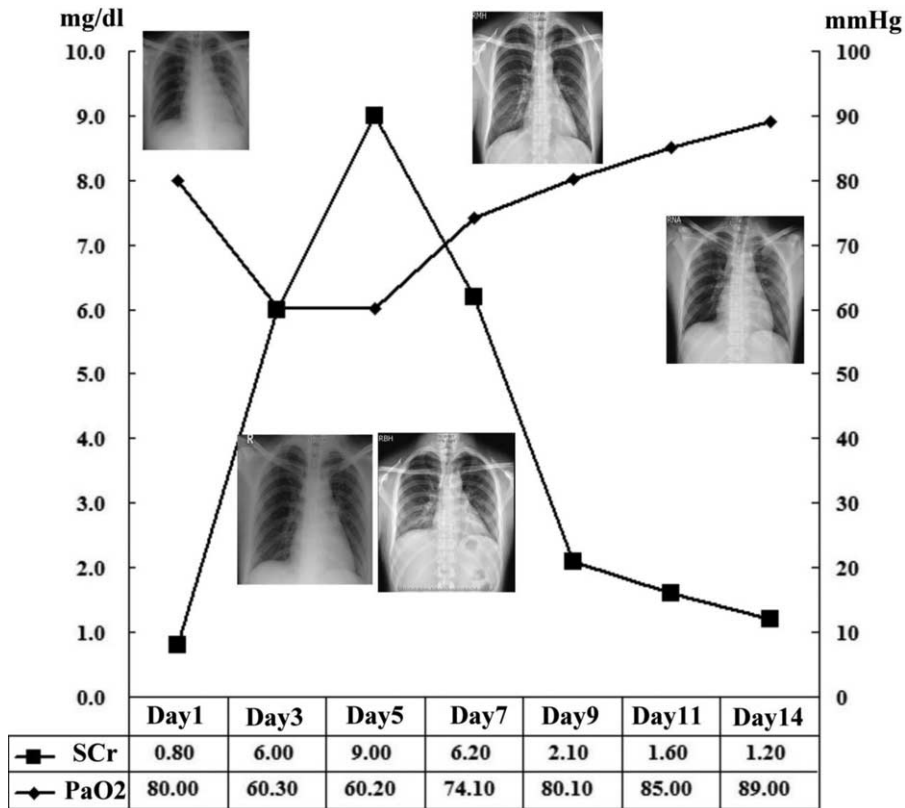


FIGURE 1. Clinical course while admission.

that this patient would survive was much <50%. However, he survived with resolution of AKI, hepatitis, and hypoxia. An important issue when investigating PQ poisoning is estimating the true amount that was ingested. A PQ poisoning victim may vomit some of the PQ due to stimulation of the esophagus and stomach. Furthermore, most PQ poisonings are due to suicide. People who attempt suicide by swallowing poison often overestimate the amount they have ingested, presumably for the purpose of seeking greater attention. In this patient, the dithionite test was strongly positive (3+) and there was severe ulceration, which taken together suggest that a significant volume of PQ was swallowed. Therefore, the reason for his survival was not due to a small amount of ingested PQ.

After performing an extensive search of the literature, only 3 cases of HIV patients with PQ poisoning were reported in PubMed (including the present case)^{2,3} (summarized in Table 1). The first study regarding PQ poisoning in an HIV patient was reported by Ragoucy-Sengler et al² who described a 26-year-old HIV positive man with severe paraquatemia. He also suffered from hypoxia, dyspnea, and AKI. Similarly, none of the available predictive tools predicted that he would survive. In addition, he did not receive regular treatment that is available in the current era, such as HP, methylprednisolone (MTP), and CTX. However, he fortunately survived after receiving only lavage and forced diuresis. The treatment course was similar to that observed in our patient. The CD4⁺ lymphocyte count of the patient was 380 cells/ μ L.³ The second case was reported this year by An-Dong Shang et al³ in which they describe a 34-year-old man with HIV infection and severe PQ poisoning. In

contrast to the first case² and our case, the patient received the current standard treatment, including HP, MTP, and CTX. He also survived with a good outcome despite the high serum concentration of PQ. All 3 cases are summarized in Table 1. A common feature of these 3 cases of HIV patients with severe PQ poisoning was low CD4⁺ lymphocyte level.

There are many indexes to predict the outcome after PQ poisoning, including a clinical index by Bismuch,⁴ a biological index by Yamaguchi,⁵ a PQ concentration index by Sawada⁶ and Jones,⁷ as well as a urinary dithionite test.⁸ The latest predictive tool is the volume ratio of ground glass opacity in early lung computed tomography (CT).⁹ In all 3 cases of HIV patients with PQ poisoning, only the second case received lung CT examination, in which the ratio was found to be far in excess of the cutoff value of 10.8%, which was suggested to be associated with a high mortality in a study by Kang et al.⁹ All of the indexes have different but acceptable powers to predict outcomes in PQ poisoning patients. However, all 3 cases were not predicted to survive in all of the above predictive models. Therefore, there are no available predictive formulae capable of predicting mortality in HIV patients with PQ poisoning.

Survival from PQ poisoning is possible and is mostly due to sparing of the lung. Under normal immune status, mechanisms of PQ toxicity have not been fully understood.¹⁰ The main potential mechanism is the production of superoxide radicals. The concentration of PQ in the lung after exposure rises progressively than other organs. Initially, it is the damage and destruction of alveolar epithelial cells causing edema

TABLE 1. Summary of Human Immunodeficiency Virus Patients With PQ Poisoning

Patient Data	Other Medical History	Amount of Exposed PQ (Patient's Allegation)	Serum Concentration of PQ	Predictive Mortality Rate, %	Presentation	Lung Involvement	Treatment	Immunological Status (CD4 ⁺ Lymphocyte), cells/ μ L	Outcome
26 y/o, male ² , 1996	Nil	300 mL, 20%	1.3 mg/L, 5 h after exposure	70 ⁵	Hypoxia, AKI	CXR: asymptomatic	Lavage, activated charcoal, forced diuresis	200	Survive and full recovery
34 y/o, male ³ , 2015	Nil	30 mL, 20%	2.17 mg/L, 10 h after exposure	79.5 ⁷	Hypoxia, AKI	CT: scattered flocculent pieces and ground glass shadow CXR: infiltration only, no fibrosis	HP, MTP, CTX, vitamin C, ambroxol, glutathione	380	Survive and full recovery
30 y/o, male (this case), 2015	HCV, methadone treatment	400 mL, 20%	3 mg/L, 3 h after exposure	>50 ¹	Hypoxia, AKI, hepatitis	CXR: infiltration only, no fibrosis	Lavage, forced diuresis	400	Survive and full recovery

AKI = acute kidney injury, CT = computed tomography, CTX = cyclophosphamide, CXR = chest X ray, HCV = hepatitis C virus, HP = hemoperfusion, MTP = methylprednisolone, PQ = paraquat.

and hemorrhage.¹¹ Then there are infiltration of myofibroblasts into the alveolar spaces and differentiation in fibroblasts with the production of collagen.¹² HIV can infect several types of immune cells; however, macrophages and CD4⁺ T lymphocytes cells are the principal targets.¹³ A significant proportion of macrophages in the mucosa of the lungs is productively infected with HIV.¹⁴ In HIV infection, multiple studies have identified extensive changes to macrophage phenotype, differentiation, and function.¹⁵ Furthermore, PQ-related lung injury is thought to occur through pulmonary alveolar macrophage.¹⁶ MTP pulse therapy is 1 of the standard treatments for suppressing reactive oxidative stress production by neutrophils and macrophages.¹⁷ Taken together, PQ-induced lung injury would be relieved due to the reduced macrophage function in HIV patients.

In conclusion, HIV positive status appears to confer a protective effect in patients with PQ poisoning as evidenced by the excellent outcomes found in the present case in cases reported in the literature even without standard treatment, and it was further shown that survival in such cases was not predicted using any of the current predictive models. The underlying molecular mechanism of this phenomenon requires further research.

REFERENCES

- Hart TB, Nevitt A, Whitehead A. A new statistical approach to the prognostic significance of plasma paraquat concentrations. *Lancet*. 1984;2:1222–1223.
- Ragoucy-Sengler C, Pileire B. Survival after paraquat poisoning in a HIV positive patient. *Hum Exp toxicol*. 1996;15:286–288.
- Shang AD, Lu YQ. A case report of severe paraquat poisoning in an HIV-positive patient: an unexpected outcome and inspiration. *Medicine*. 2015;94:e587.
- Bismuth C, Garnier R, Baud FJ. Paraquat poisoning. An overview of the current status. *Drug Safety*. 1990;5:243–251.
- Yamaguchi H, Sato S, Watanabe S, et al. Pre-embarkment prognostication for acute paraquat poisoning. *Hum Exp Toxicol*. 1990;9:381–384.
- Sawada Y, Yamamoto I, Hirokane T, et al. Severity index of paraquat poisoning. *Lancet*. 1988;1:1333.
- Jones AL, Elton R, Flanagan R. Multiple logistic regression analysis of plasma paraquat concentrations as a predictor of outcome in 375 cases of paraquat poisoning. *QJM*. 1999;92:573–578.
- Berry DJ, Grove J. The determination of paraquat (N,N'-dimethyl-4,4'-bipyridylum cation) in urine. *Clin Chim Acta*. 1971;34:5–11.
- Kang X, Hu DY, Li CB, et al. The volume ratio of ground glass opacity in early lung CT predicts mortality in acute paraquat poisoning. *PLoS ONE*. 2015;10:e0121691.
- Mohammadi-Karakani A, Ghazi-Khansari M, Sotoudeh M. Lisinopril ameliorates paraquat-induced lung fibrosis. *Clin Chim Acta*. 2006;367:170–174.
- Vijayaratnam GS, Corrin B. Experimental paraquat poisoning: a histological and electron-optical study of the changes in the lung. *J Pathol*. 1971;103:123–129.
- Smith LL, Rose MS. A comparison of the effects of paraquat and diquat on the water content of rat lung and the incorporation of thymidine into lung DNA. *Toxicology*. 1977;8:223–230.
- Iordanskiy S, Santos S, Bukrinsky M. Nature, nurture and HIV: the effect of producer cell on viral physiology. *Virology*. 2013;443:208–213.
- Shen R, Richter HE, Clements RH, et al. Macrophages in vaginal but not intestinal mucosa are monocyte-like and permissive to

- human immunodeficiency virus type 1 infection. *J Virol*. 2009;83:3258–3267.
15. Collini P, Noursadeghi M, Sabroe I, et al. Monocyte and macrophage dysfunction as a cause of HIV-1 induced dysfunction of innate immunity. *Curr Mol Med*. 2010;10:727–740.
16. Wong RC, Stevens JB. Paraquat toxicity in vitro. I. Pulmonary alveolar macrophages. *J Toxicol Environ Health*. 1985;15:417–429.
17. Fox DA, McCune WJ. Immunosuppressive drug therapy of systemic lupus erythematosus. *Rheum Dis Clin North Am*. 1994;20:265–299.