

*Original Article*

# Developmental Toxicity Studies with Pregabalin in Rats: Significance of Alterations in Skull Bone Morphology

Dennis C. Morse,<sup>1\*</sup> Judith W. Henck,<sup>2</sup> and Steven A. Bailey<sup>3</sup>

<sup>1</sup>Pfizer Worldwide Research and Development, Drug Safety Research and Development, Groton, Connecticut

<sup>2</sup>Toxicology Solutions Consulting LLC, Leeds, Utah

<sup>3</sup>Pfizer Worldwide Research and Development, Drug Safety Research and Development, Andover, Massachusetts

Pregabalin was administered to pregnant Wistar rats during organogenesis to evaluate potential developmental toxicity. In an embryo-fetal development study, compared with controls, fetuses from pregabalin-treated rats exhibited increased incidence of jugal fused to maxilla (pregabalin 1250 and 2500 mg/kg) and fusion of the nasal sutures (pregabalin 2500 mg/kg). The alterations in skull development occurred in the presence of maternal toxicity (reduced body weight gain) and developmental toxicity (reduced fetal body weight and increased skeletal variations), and were initially classified as malformations. Subsequent investigative studies in pregnant rats treated with pregabalin during organogenesis confirmed the advanced jugal fused to maxilla, and fusion of the nasal sutures at cesarean section (gestation day/postmating day [PMD] 21) in pregabalin-treated groups. In a study designed to evaluate progression of skull development, advanced jugal fused to maxilla and fusion of the nasal sutures was observed on PMD 20–25 and PMD 21–23, respectively (birth occurs approximately on PMD 22). On postnatal day (PND) 21, complete jugal fused to maxilla was observed in the majority of control and 2500 mg/kg offspring. No treatment-related differences in the incidence of skull bone fusions occurred on PND 21, indicating no permanent adverse outcome. Based on the results of the investigative studies, and a review of historical data and scientific literature, the advanced skull bone fusions were reclassified as anatomic variations. Pregabalin was not teratogenic in rats under the conditions of these studies. *Birth Defects Res (Part B)* 107:94–107, 2016. © 2016 The Authors Birth Defects Research Published by Wiley Periodicals, Inc.

**Key words:** *pregabalin; developmental toxicity; teratology*

## INTRODUCTION

Pregabalin (Pfizer, NY, USA) is a gamma-aminobutyric acid analog that binds with high affinity and selectivity to the  $\alpha 2\text{-}\delta$  subunit of voltage-gated calcium channels at nerve presynapses and modulates their activity (Stahl et al., 2013). This mode of action translates into anticonvulsant, analgesic, and anxiolytic effects. In the United States, Pregabalin (Lyrica®) is indicated as adjunctive treatment for partial seizures, for the treatment of pain associated with fibromyalgia, postherpetic neuralgia, and neuropathic pain associated with diabetic peripheral neuropathy and spinal cord injury (Pfizer, 2013). In Europe, it is indicated as adjunctive treatment for partial seizures, central and peripheral neuropathic pain, and generalized anxiety disorder (Pfizer, 2015).

As part of the nonclinical assessment, a series of oral developmental toxicity studies in Wistar rats were performed to assess the effects of pregabalin on pre- and postnatal development, to better characterize the observed findings of increased incidence of jugal fused to maxilla and fusion of the nasal sutures, and the potential impact

on skull development. In the mature rat skull, the jugal bone (known as the zygomatic or malar bone), together with the zygomatic/maxillary processes of the maxillary and temporal bones, form the zygomatic arch, which encircles the orbit of the eye (Makris et al., 2009). In the immature rat skull, the jugal bone is separate from the maxilla, but as development progresses and ossification advances, fusion of the zygomaticomaxillary suture between the jugal (zygomatic) bone and maxilla occurs and forms the lower portion of the orbit (Fig. 1). In Long-Evans rats, this closure is generally not present at the time of birth, and if it does occur, is an indication that ossification is advanced (Walker and Wirtschafter, 1957).

Additional Supporting Information may be found in the online version of this article.

\*Correspondence to: Dennis C. Morse, Pfizer Worldwide Research and Development, Drug Safety Research and Development, Groton, CT 06340.

E-mail: Dennis.Morse@pfizer.com

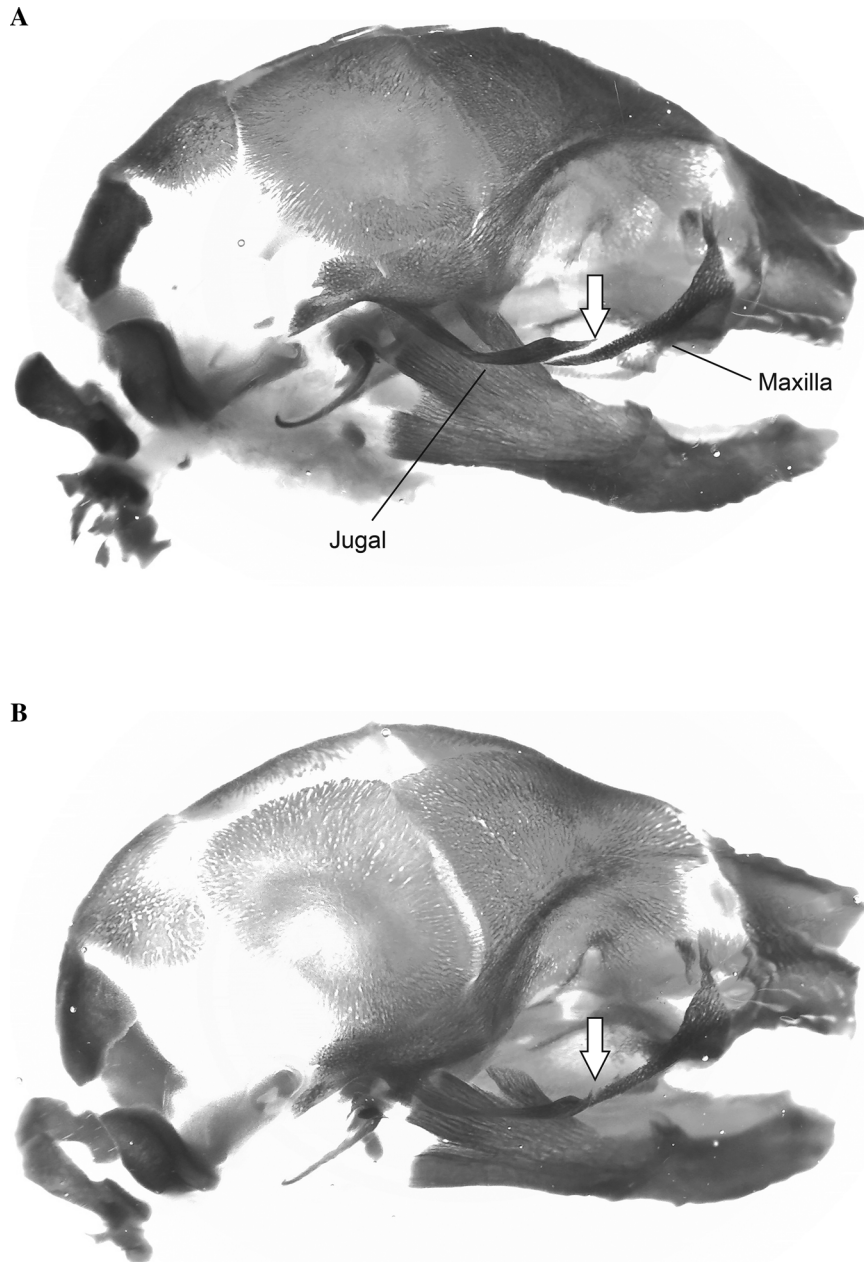
Received 03 December 2015; Accepted 10 March 2016

Published online in Wiley Online Library (wileyonlinelibrary.com/journal/

bdrb) DOI: 10.1002/bdrb.21175

This is an open access article under the terms of the Creative Commons Attribution NonCommercial License, which permits use, distribution and reproduction in any medium, provided the original work is properly cited and is not used for commercial purposes.

The copyright line of this article has been corrected after the original publication 13 April 2016



**Fig. 1.** Lateral view of the skull of gestation day (GD) 21 fetal rats. (A) Control fetus with unfused jugal bone and maxilla (arrow). (B) Fetus from female treated with pregabalin 2500 mg/kg/day with a fused jugal bone and maxilla (arrow).

Similarly, in the Long-Evans rat, the nasal bones are not fused at birth. However, fusion of this suture, as well as the zygomaticomaxillary suture, is apparent six days after birth in Long-Evans rats (Walker and Wirtschafter, 1957).

An important aspect of advanced ossification is the potential impact on subsequent skull morphology, and ultimately, on overall health. Classification of developmental anomalies has been the topic of many workshops and publications, with global input from academia, scientific institutes, regulatory agencies, and the chemical and pharmaceutical industries. Although definitions differ somewhat, most classification schemes recognize

structural anomalies as belonging to two major groups: malformation and variation. The working definition of malformation from the Parke-Davis and Pfizer laboratories applied in this article is as follows: developmental deviations that are (1) gross structural changes, (2) may be incompatible with life, and (3) are generally rare in control populations. The definition of variation applied in this article is as follows: structural alterations that occur more often than malformations and are considered to have no significant adverse effect on body conformation, function, or general well-being. These definitions are consistent with global efforts to harmonize terminology in developmental toxicology in a series of

workshops known as the Berlin Workshops (Chahoud et al., 1999).

Per discussion at the second Berlin Workshop, the observation of “fused” should be assigned to the malformation category regardless of frequency (Solecki et al., 2001). Concerns included unknown postnatal consequences and unknown significance in humans. In a survey sent to scientists active in the field of developmental toxicology, 100% of respondents felt that fused maxilla should be considered a malformation, while 80% felt that fused nasal bones should be categorized as such (Solecki et al., 2001). However, a “gray zone” has been discussed, including anomalies for which there is uncertainty regarding their ultimate importance, with the agreement that new knowledge and skills should be pursued to enable classification (Solecki et al., 2013). The current studies provide new knowledge on the increased incidence of two specific skull bone fusions, and their lack of impact on subsequent skull development and postnatal health.

This article presents results from four developmental toxicity studies with pregabalin in Wistar rats. The first is the embryo-fetal development study (EFD1), which was conducted to assess the developmental toxicity, including the teratogenic potential, of pregabalin. The second is the embryo-fetal development replication study (EFD2), which was conducted to evaluate the reproducibility of the skull bone findings from Study EFD1 and the histological characteristics associated with these findings. The third is the perinatal skull development study, which was conducted to determine the natural perinatal progression of the skull bone fusions and the possible effects of pregabalin on the progression of these fusions (on postmating day [PMD] 19–26). The fourth is the postnatal skull development study, which was conducted to assess the possible effects of pregabalin on the morphological development of the skull at postnatal day (PND) 21. In addition, data from Study EFD1 were reviewed relative to historical developmental toxicity data and a pre- and postnatal study in Wistar rats (Pfizer, unpublished data) to evaluate the impact of the observed morphological anomalies on postnatal health. The developmental anomalies of the skull identified in the original EFD1 study were originally classified as malformations, but were subsequently reclassified as variations. A weight of evidence approach is presented to support this reclassification, as well as the conclusion that pregabalin was not teratogenic in rats.

## MATERIALS AND METHODS

All studies adhered to guidelines for animal welfare (National Institutes of Health, 1985/1996) and were conducted according to the U.S. Food and Drug Administration (FDA) Good Laboratory Practice Regulations (FDA, 1988; 1994), with the exception that the investigative studies were not audited. The initial embryo-fetal toxicity study was conducted at Parke-Davis Pharmaceutical Research Division, Department of Pathology and Experimental Toxicology, Ann Arbor, MI, which was acquired by Pfizer in 2000. The three investigational developmental studies were conducted at Pfizer Global Research and Development, Ann Arbor Laboratories, Ann Arbor, MI. Design features of the four rat developmental toxicity studies are summarized in Table 1.

Female Wistar rats [CrI:(WI)BR] from Charles River Breeding Laboratories (Kingston, NY and Raleigh, NC) were used in these studies. Sexually mature females were mated with sexually mature males from the same strain and source. Determination of insemination by the presence of sperm in a vaginal smear was considered gestation day (GD) 0, which corresponded to PMD 0 in the perinatal skull development study, to correct for the overall length of development due to the variability in the day of birth (ranging from PMD 22–24).

Sperm-positive female Wistar rats were assigned to treatment groups. For the plasma drug concentration analysis conducted in Study EFD1, five females were assigned to a toxicokinetic (TK) subgroup of each treatment group using a block design. The remaining females in Study EFD1 and the successfully mated females in the other studies were randomly assigned to treatment groups. The rats were housed in individual stainless-steel wire mesh cages suspended over absorbent paper. In the perinatal and postnatal skull development studies, rats were moved to plastic cages at GD 20. Food (Purina Laboratory Diet No. 5002 Certified Rodent Chow<sup>®</sup>) and water were provided ad libitum, with the exception of Study EFD2 and the postnatal study, which provided food in weighed portions up to GD 21 and GD 20, respectively. Food was then provided ad libitum from GD 20 to PND 21 in the postnatal study. Environmental conditions were set to maintain temperature between 68–78°F and relative humidity between 30–75% in rooms with a 12 h light/dark cycle.

In all studies, rats were treated once daily by oral gavage (25 ml/kg) on GD 6–17. Each study included a vehicle control group that received an equivalent dose of 0.5% methylcellulose. In Study EFD2, untreated control groups enabled potential vehicle-related effects on the incidence of skull bone fusion to be examined. In Study EFD1, pregabalin doses of 500, 1250, and 2500 mg/kg were selected based on the results of an oral dose range-finding study in Wistar rats with a top dose of 2500 mg/kg (Pfizer, unpublished data). In Study EFD2, pregabalin was administered at doses of 50, 100, 250, 500, 1250, or 2500 mg/kg. Doses of  $\geq 500$  mg/kg were selected to reproduce the findings observed in Study EFD1. Doses of  $< 500$  mg/kg were selected based on the manifestation of developmental toxicity at these dose levels in subsequent pre- and postnatal development studies (Pfizer, unpublished data). In both the perinatal and postnatal skull development studies, a dose of pregabalin 2500 mg/kg was selected to match the highest dose used in Studies EFD1 and EFD2 to further characterize treatment-related skull bone findings observed in these studies.

In Study EFD1, blood was obtained from the TK subgroups on GD 15 for plasma drug concentration analysis. Blood samples were collected under anesthesia by orbital bleeding and placed into tubes containing sodium heparin. Samples were obtained from the control group 4 h post-dose and from the pregabalin-treated groups 0 (pre-dose), 1, 4, 7, and 12 h post-dose. The blood was centrifuged and the plasma was stored frozen until analyzed for pregabalin concentrations at the Pharmacokinetics and Drug Metabolism Department, Parke-Davis Pharmaceutical Research, Ann Arbor, MI, (now Pfizer) using a

Table 1  
Details of Study Designs

Study	Study objective	Weight (g), age (weeks) at GD 0	Study groups			Scheduled euthanasia	Body weight	Terminal necropsy and uterotomy	Fetal/offspring evaluation
			Dose group (mg/kg) <sup>a</sup>	No. of females/dose group	No. of females/dose group <sup>c</sup>				
Embryo-fetal development, initial (EFD1)	Assess initial developmental toxicity of pregabalin	220–308; 12–13	0 (vehicle), <sup>b</sup> 500, 1250, 2500	25 (5 TK/dose group) <sup>c</sup>	GD 16 (all TK females) GD 21 (all non-TK females)	Maternal female: GD 0, 6, 9, 12, 15, 18, 21 Fetal: termination (individual and placental weight; live fetus only)	Non-TK females: gross necropsy, uterotomy (no. of corpora lutea, location and status of implant site, sex of each live fetus)	Fetal: external, visceral, and skeletal malformations and variations	
			Untreated, 0 (vehicle), <sup>b</sup> 50, 100, 250, 500, 1250, 2500	25	GD 21 (all females)	Maternal female: GD 0, 6, 9, 12, 15, 18, 21 Fetal: not recorded	Maternal female: gross necropsy, uterotomy (no. of corpora lutea, location and status of implant site, sex of each live fetus)	Fetal: external and skeletal malformations and variations; histopathology examination	
Embryo-fetal development, replicate (EFD2)	Evaluate reproducibility of EFD1 skull bone findings	205–286; 12–13	Untreated, 0 (vehicle), <sup>b</sup> 50, 100, 250, 500, 1250, 2500	25	GD 21 (all females)			Fetal: external and skeletal malformations and variations; histopathology examination	
Perinatal skull development	Assess effects of pregabalin on perinatal skull development	188–279; 11	0 (vehicle), <sup>b</sup> 2500	10/dose group (termination on PMD 19, 24, 25, 26)	PMD 19, 24, 25, 26 (10 females/offspring)	Maternal female: PMD 0, 6, 9, 12, 15, 18, 21	Maternal female: uterotomy (location of implant site, sex of each live fetus)	Offspring: external and skeletal malformations and variations	
					PMD 20, 21, 22, 23 (20 females/offspring)	Fetal: termination (individual weight; live fetus only)	Maternal female: PMD 19, 24, 25, 26 (10 females/offspring) PMD 20, 21, 22, 23 (20 females/offspring)	Maternal female: uterotomy (location of implant site, sex of each live fetus)	Offspring: external and skeletal malformations and variations
Postnatal skull development	Assess effects of pregabalin on postnatal skull development	207–278; 11–12	0 (vehicle), <sup>b</sup> 2500	25	PND 21 (all females/offspring)		Maternal female: pregnancy status only	Offspring: external and skeletal malformations and variations	

<sup>a</sup>Pregnant rats were dosed daily by oral gavage on GD 6–17.

<sup>b</sup>Vehicle control groups received an equivalent dose of 0.5% MC.

<sup>c</sup>Five TK females per dose group were assigned for plasma drug concentration analysis. GD, gestation day; MC, methylcellulose; PMD, postmating day; PND, postnatal day; TK, toxicokinetic.

validated high-performance liquid chromatography procedure.

In all studies, maternal females were observed daily for clinical signs of toxicity, and body weights were recorded at appropriate intervals (Table 1). Maternal food consumption was only measured in Study EFD1 and recorded concomitantly with body weight. In the postnatal skull study, naturally delivered litters (designated PND 0) were evaluated for offspring sex, viability, clinical signs, and any external abnormalities. Offspring were observed daily for signs of abnormal appearance, and body weights were recorded on PND 0, 4, 7, 14, and 21.

All animals were euthanized in a CO<sub>2</sub> atmosphere. The TK females in Study EFD1 were euthanized on GD 16 with no gross necropsy examination. The non-TK females in Study EFD1 and all maternal females in Study EFD2 were euthanized on GD 21 and examined grossly (Table 1). In the perinatal study, females with litters and their offspring were designated for euthanasia as follows: 10 per treatment on PMD 19, 24, 25, and 26; and 20 per treatment on PMD 20, 21, 22, and 23. Based on previous research (Walker and Wirtschafter, 1957) and historical data (Pfizer, unpublished data), it was anticipated that closure of the sutures in controls would be rare on PMD 19 and at a high incidence on PMD 24–26. Therefore, a group size of 10 was expected to provide a suitable number of offspring for the analysis. In the postnatal study, the maternal females and all surviving offspring were euthanized on PND 21. Gross necropsies were not performed in the perinatal or postnatal skull development studies. Uterotomies were performed in Study EFD1, Study EFD2, and the perinatal skull development study to collect litter and fetal data (Table 1). Live term fetuses were not weighed in Study EFD2.

For all studies, the offspring were examined for external variations and malformations of the head, including the orbit. In EFD1, all fetuses were also examined by fresh dissection for visceral malformations and variations. In EFD2, half of the heads of the fetuses from each litter were fixed in formalin, and processed for light microscopy examination of the jugal sutures. The heads from the control groups and the 2500 mg/kg dose group were examined by light microscopy. Approximately two-thirds of fetuses/litter from EFD1, one-half of fetuses/litter from EFD2, and all offspring from both the perinatal and postnatal skull development studies were eviscerated, cleared, stained with Alizarin Red S, and examined for skeletal malformations and variations of the skull. Skeletal evaluation included an assessment of the suturae zygomaticomaxillaris (between jugal bone and maxilla) and nasofrontalis (between nasal bones). The findings described as jugal fused to maxilla and fusion of the nasal bones represent advanced ossification and development of connective tissue resulting in the early closure of the sutura zygomaticomaxillaris and the sutura nasofrontalis, respectively. For consistency this report uses the term “fusion” for this process.

For evaluation, this article uses laboratory-set evaluation criteria to define malformations as developmental deviations that are: (1) gross structural changes, (2) may be incompatible with life, and (3) are generally rare in control populations (Henck et al., 1992). Variations were defined as structural alterations that occur more often than

malformations and are considered to have no significant adverse effect on body conformation, function, or general clinical signs.

### Statistical Analyses

In Study EFD1, the class-wise significance level was allocated to each parameter proportionally by the inverse of the square root of the number of parameters in a class (Tukey et al., 1985). Most quantitative reproductive parameters were analyzed using Tukey’s sequential trend test using the rank dose scale and rank-transformed data (Park, 1985; Tukey et al., 1985), one- or two-tailed, at the 5% class-wise significance level. This trend test is equivalent to sequential application of Kruskal–Wallis one-way analysis of variance by ranks with the treatment effects being evaluated by dose-trend tests, which have contrast coefficients for equally spaced (ranked) treatment groups. If the high-dose linear trend test was not statistically significant, a test of trend reversal was performed at the 1% class-wise significance level. If the test of trend reversal test was statistically significant, then Dunnett’s test (Dunnett, 1955; 1964) was used to compare the treated groups with the vehicle control at the 5% class-wise significance level.

The percentage of fetuses in each litter with external, visceral, and skeletal malformations and variations, as well as skeletal ossification sites, were evaluated by applying weighted nonparametric Tukey’s sequential trend test to the vehicle control and 500, 1250, and 2500 mg/kg groups, at the 5% class-wise significance level in Study EFD1. The value of the weight variable was the number of fetuses examined. The analyses of percent litters with fetuses with variations or malformations were performed by sequential application of a Cochran–Armitage test (Armitage, 1955; Cochran, 1955) for linear trend in proportions at the 5% class-wise significance level, one-tailed. If the high-dose Cochran–Armitage test was not statistically significant, a nonlinearity test (Armitage, 1955; Cochran, 1955) was performed at the 1% class-wise significance level. If the nonlinearity test was statistically significant, then Fisher’s exact test, performed at the 5% class-wise significance level, one-tailed, was used to compare the treated groups with the vehicle control.

In Study EFD2, means and standard errors were calculated for maternal body weight and body weight change and standard necropsy parameters; inferential statistics were not conducted. In the perinatal and postnatal skull development studies, means and standard errors were calculated for maternal and offspring body weight and body weight change. In the perinatal skull development study, the mean percentage of offspring per litter with sutures closed was compared between vehicle control and pregabalin-treated groups for each PMD using the method of generalized estimating equations (Diggle et al., 1994). The significance level was adjusted for the number of PMDs examined.

## RESULTS

### Initial Embryo-Fetal Development Study (EFD1)

**Maternal.** There were no treatment-related deaths before scheduled study termination.

Table 2  
Mean Plasma Pregabalin Pharmacokinetic Values in Rats on GD 15 from Study EFD1

Plasma pregabalin parameters	Pregabalin dose (mg/kg/day), mean (SD)		
	500 (n = 4)	1250 (n = 5)	2500 (n = 4)
C <sub>max</sub> (μg/ml)	321 (74.3)	623 (93.9)	614 (119.2)
T <sub>max</sub> (h)	1.0 (0.0)	2.8 (1.6)	4.0 (2.4)
AUC <sub>0-24</sub> (μg•h/ml)	2055 (211.3)	6590 (1262.6)	9473 (1214.4)

AUC<sub>0-24</sub>, area under the plasma pregabalin concentration-time curve from 0–24 h; C<sub>max</sub>, maximum observed pregabalin concentration; EFD1, embryo-fetal development study (initial); GD, gestation day; SD, standard deviation; T<sub>max</sub>, time of C<sub>max</sub>.

Treatment-related maternal clinical signs that occurred in all pregabalin-treated groups were hypoactivity, tail chewing, and sore/discoloration, bruxism, and urine staining. Additional clinical signs at 1250 and 2500 mg/kg that occurred at a greater incidence than in controls were ataxia, chromodacryorrhea, and alopecia.

Body weight gain in the 2500 mg/kg group was significantly less than the control group by 26% during the treatment period (GD 6–18) and 30% less than the control group during the posttreatment period (GD 18–21), both  $p \leq 0.05$ . Food consumption in the 2500 mg/kg group was significantly less than the control group by 14% for the treatment period ( $p \leq 0.05$ ). Food consumption for the 500 and 1250 mg/kg groups was significantly reduced by 16 and 11%, respectively, compared with controls for the posttreatment period (both  $p \leq 0.05$ ).

The principal pharmacokinetic parameters of pregabalin on GD 15 are summarized in Table 2. Maternal exposure was demonstrated and area under the plasma concentration-time curve (AUC) showed a dose-proportional increase with pregabalin. The mean maximum plasma pregabalin concentration (C<sub>max</sub>) values increased with dose up to 1250 mg/kg but did not increase between doses of 1250 and 2500 mg/kg.

The incidence of gross pathological findings—which were correlates of the clinical observations such as alopecia and tail injury—were increased relative to the control group at 1250 and 2500 mg/kg. There were no other significant gross pathology findings observed at necropsy. No treatment-related effects were observed on numbers of corpora lutea, litter size, pre- and postimplantation losses, or on fetal sex ratio (Table 3).

**Fetal.** Mean body weight in male fetuses in the 2500 mg/kg dose group was significantly lower than the control group by 8% ( $p \leq 0.05$ ; Table 3). Fetal body weight for females treated at 2500 mg/kg was lower than control by 10%; although this difference was not statistically significant, the mean value for this group was outside that of concurrent and historical controls, and therefore was considered biologically significant.

There were no treatment-related external or visceral malformations or variations (Table 4). There were no treatment-related skeletal malformations. Initially classifying findings of jugal fused to maxilla and nasal bones fused as malformations resulted in a statistically significant increase in skeletal malformations at 1250 and 2500 mg/kg/day. However, after these findings were reclassified as variations based on the scientific data presented in this paper, the incidences of skeletal malformations in the pregabalin dose groups were consistent with the

control group. Statistically significant increases in skeletal variations occurred in the 1250 and 2500 mg/kg dose group ( $p = 0.002$  and  $p < 0.001$ , respectively). Jugal bone fused to maxilla (Fig. 1) occurred with a fetal incidence of 1.7, 0.6, 5.7, and 9.9% in the control, 500, 1250, and 2500 mg/kg dose groups, respectively (Table 5). Fused nasal bones occurred in the 2500 mg/kg dose group only with a fetal incidence of 5.5% and no occurrences in controls (Table 5). Of the 10 fetuses with fused nasal bones, two had fused jugal to maxilla (unilateral). The incidence of skeletal variations of the fetuses was significantly increased at 1250 and 2500 mg/kg doses due to the increased fusions of the sutures and other evidence of advanced ossification, including ossification of the middle phalanges and calcaneus, extra structures (including extra well-formed lumbar ribs), and rudimentary thoracic ribs. The overall litter incidence of all skeletal variations was significantly increased at all doses (Table 5). The overall fetal incidence of all skeletal variations was significantly increased at 1250 and 2500 mg/kg only. Although not statistically significant, ossification retardations were elevated at all pregabalin doses compared with controls; this was likely due to an increased incidence of unossified ventral tubercle of the atlas, although this was within historical control levels at 500 and 1250 mg/kg, and only slightly outside of historical controls at 2500 mg/kg.

### Replicate Embryo-Fetal Development Study (EFD2)

**Maternal.** In this study, the observed maternal toxicity, characterized by clinical signs (alopecia, salivation, urine staining, vaginal discharge, and chromodacryorrhea) and reduced body weight gain, was comparable with Study EFD1. There were no treatment-related deaths, nor were there apparent treatment-related gross pathological changes. No treatment-related effects were observed on numbers of corpora lutea, litter size, pre- and postimplantation losses, or on fetal sex ratio (Pfizer, unpublished data).

**Fetal.** No treatment-related external head or skull bone malformations were observed (Table 6). The fetal incidence of jugal fused to maxilla was increased eight- and 15-fold relative to vehicle-treated controls at 1250 and 2500 mg/kg doses, respectively. A treatment-related increase in fetuses with fusion of the nasal suture occurred at 2500 mg/kg. There were no histopathological abnormalities detected in the zygomatic arch from the high-dose, untreated, and vehicle control animals examined (Pfizer, unpublished data). Microscopic evaluation

Table 3  
Summary of Reproductive and Litter Data from Pregnant Rats in Study EFD1

Parameter	Vehicle/control	Pregabalin dose (mg/kg/day)		
	0	500	1250	2500
Total mated females, <i>n</i>	20	20	20	20
Total pregnant females, <i>n</i>	20	18	19	18
Total females with viable fetuses, <i>n</i> <sup>a</sup>	19	18	18	18
Total delivered early, <i>n</i>	1	0	1	0
No. of corpora lutea, mean ± SE	16.8 ± 1.09	16.9 ± 0.42	16.1 ± 0.51	17.2 ± 0.39
No. of implantation sites, mean ± SE	14.6 ± 0.93	15.0 ± 0.79	15.3 ± 0.60	16.0 ± 0.49
No. of resorptions, mean ± SE	0.9 ± 0.35	1.4 ± 0.35	1.2 ± 0.32	1.5 ± 0.35
No. live fetuses per litter, mean ± SE	13.6 ± 1.00	13.6 ± 0.83	14.2 ± 0.69	14.5 ± 0.52
No. of dead fetuses per litter, mean ± SE	0	0	0	0
Preimplantation loss, % <sup>b</sup>	11.3	11.7	4.7	6.8
Postimplantation loss, % <sup>c</sup>	6.7	10.3	7.8	9.2
Sex ratio, % male	60.4	49.7	48.0	53.4
Fetal body weight (g), mean ± SE				
Males	5.3 ± 0.13	5.4 ± 0.11	5.3 ± 0.14	4.9 ± 0.14*
Females	5.1 ± 0.14	5.0 ± 0.12	5.1 ± 0.15	4.6 ± 0.11
Placenta weight (g), mean ± SE	0.52 ± 0.05	0.51 ± 0.02	0.53 ± 0.02	0.50 ± 0.02

<sup>a</sup>Excludes litters delivered on GD 21.

<sup>b</sup>Preimplantation loss per litter = [(corpora lutea – implantation sites)/corpora lutea] × 100.

<sup>c</sup>Postimplantation loss per litter = [(implantation sites – viable fetuses)/implantation sites] × 100.

\**p* ≤ 0.05, different from vehicle control for trend test.

EFD1, embryo-fetal development study (initial); GD, gestation day; SE, standard error.

did not further characterize the degree of skull bone fusions due to the variability in sectioning, and the fibrous nature of the joint. However, there were no visible abnormalities.

### Perinatal Skull Development Study

**Maternal.** Because all animals were treated during the same gestation period, results were combined for all control groups and all pregabalin-treated groups. The maternal clinical signs of toxicity and reduced body weight gain observed in this study were similar to the findings from Studies EFD1 and EFD2. A decrease in the number of females with live litters was observed in the pregabalin-treated groups scheduled for euthanasia on PMD 24, 25, and 26 (Table 7). The day of birth (PND 0) ranged from PMD 22–24, with the majority (approximately 80%) of females delivering on PMD 22. Most females euthanized early were euthanized after giving birth, with the exception of one pregabalin-treated female that was euthanized on PMD 23 due to dystocia and seven additional pregabalin-treated females that were euthanized on PMD 22–24 because their litters were dead or cannibalized.

**Offspring.** Survival results were combined for all control groups and all pregabalin-treated groups. Mortality, cannibalization, and the number of missing offspring (presumed cannibalized) for PMD 22–26 was two-, three-, and sevenfold higher, respectively, than control at 2500 mg/kg, including the complete loss of 10 litters with the majority of deaths having occurred on PMD 22–24 (Table 7). This resulted in a low number of litters available for evaluation in the 2500 mg/kg groups on PMD 25 and 26 (five and six litters, respectively). Clinical findings were low in incidence or occurred in the control and

pregabalin-treated groups, and were therefore considered incidental. Mean terminal body weights were consistently lower for both male and female offspring from the 2500 mg/kg groups, ranging from 7–20% less than the control group mean.

Jugal fused to maxilla and fusion of the nasal sutures was not complete in all of the offspring on PMD 26 in either the vehicle control or pregabalin-treated group. The mean percentage of offspring per litter with jugal fused to maxilla was statistically significantly higher in the pregabalin-treated groups than in the control groups on PMD 20–25 (*p* < 0.05; Table 8). The mean percentage of offspring per litter with fusion of the nasal sutures was statistically significantly higher in the pregabalin-treated groups than in the control groups on PMD 21, 22, and 23 (*p* < 0.05; Table 8).

### Postnatal Skull Development Study

**Maternal.** Four females were euthanized before scheduled euthanasia (two in the control group due to poor clinical condition and two in the 2500 mg/kg dose group due to moribundity). Drug-related clinical signs in surviving females were similar to those observed in the previous study. During the overall treatment and posttreatment gestation periods, body weight gain of the pregabalin-treated females was 33 and 67% less than the control group mean, respectively.

**Offspring.** The number of offspring/litter that were dead (23/9), cannibalized (4/3), and missing (27/11) occurred at a higher incidence in the 2500 mg/kg dose group compared with the control group, although sufficient offspring (*n* = 214) and litters (*n* = 19) remained in this group for further evaluation. Two malformed control offspring and one malformed offspring in the 2500

Table 4  
External and Visceral Malformations and Variations in Study EFD1

Parameter	Vehicle/control		Pregabalin dose (mg/kg/day)					
			500		1250		2500	
No. of fetuses/litters examined	274/20		244/18		270/19		261/18	
No. of fetuses/litters with malformations	3/3		1/1		2/2		3/2	
No. of fetuses/litters with variations	1/1		1/1		1/1		3/3	
Percentage affected <sup>a</sup>	Fetuses	Litters	Fetuses	Litters	Fetuses	Litters	Fetuses	Litters
Malformations	1.1	15.0	0.4	5.6	0.7	10.5	1.1	11.1
Anal – atresia	0	0	0.4	5.6	0.4	5.3	0	0
Face – shorter than normal	0.4	5.0	0	0	0	0	0	0
Head								
Encephalocele	0	0	0	0	0	0	0.8	5.6
Exencephaly	0	0	0	0	0.4	5.3	0	0
Lower jaw – micrognathia	0.4	5.0	0	0	0	0	0	0
Fore and hind limbs – micromelia	0.4	5.0	0	0	0	0	0	0
Liver								
Fused lobes	0.4	5.0	0	0	0	0	0	0
Omphalocele	0	0	0	0	0	0	0.4	5.6
Tail – thread-like	0	0	0.4	5.6	0.4	5.3	0	0
Variations	0.4	5.0	0.4	5.6	0.4	5.3	1.1	16.7
Head – hematoma	0	0	0	0	0.4	5.3	0	0
Kidney								
Dilated pelvis	0	0	0.4	5.6	0	0	0.4	5.6
Reduced papilla and dilated pelvis	0.4	5.0	0	0	0	0	0	0
Liver – discoloration	0	0	0	0	0	0	0.8	11.1
Ureter – dilated	0.4	5.0	0	0	0	0	0.4	5.6

<sup>a</sup>Fetuses may be included in  $\geq 1$  category.

EFD1, embryo-fetal development study (initial); SE, standard error.

mg/kg dose group were euthanized on the day of birth. Malocclusion and an asymmetrically shaped head were observed clinically in one 2500 mg/kg offspring on PND 19–21. External examination confirmed these findings, which correlated with skeletal variations of misshapen left frontal and parietal bones (Table 10). The jugal bone and maxilla bones were fused bilaterally and the nasal bones were unfused in this animal. Clinical signs of dyspnea, hypoactivity, and/or discoloration occurred before death in some offspring. Dyspnea was observed in two offspring on PND 0 that died on PND 3. Dyspnea was not observed in the offspring with fused nasal sutures. Misshapen nasal turbinates were also not observed in any offspring. Unscheduled deaths in the 2500 mg/kg group occurred predominately on PND 0–1, and no deaths occurred after PND 4. On PND 0, 4, 7, 14, and 21, body weights of offspring in the 2500 mg/kg dose group were 8, 12, 12, 8, and 6% less than offspring from the control group, respectively. Overall body weight gain (PND 0–21) of offspring in the 2500 mg/kg group was 6% less than the control group (Table 9).

The offspring incidence of bilateral fusion of the jugal bone and maxilla on PND 21 was 98.9 and 93.1% in the control and 2500 mg/kg groups, respectively. One of the two control litters and all three litters at the 2500 mg/kg dose with offspring with unilateral or bilateral sutures open had been over-processed, resulting in deterioration of the specimens, and therefore, it is likely that the open jugal sutures are an artifact (Table 10). The offspring incidence of fusion of the nasal suture was 1.1 and 4.1% in the control and 2500 mg/kg groups, respectively. No other

remarkable findings were observed at skeletal examination on PND 21.

## DISCUSSION

Pregabalin was demonstrated to be developmentally toxic in an embryo-fetal development study in rats given 500, 1250, and 2500 mg/kg/day. Developmental toxicity was characterized by reduced fetal body weight at the high dose, and overall increased litter incidence of skeletal variations (mainly advanced ossification) at all doses. However, at the low dose (500 mg/kg/day), individual skeletal variations were below historical control values. The low dose was associated with a maternal plasma exposure ( $AUC_{0-24}$ ) approximately 17-times the expected human exposure (123  $\mu\text{g}\cdot\text{h}/\text{ml}$ ) at the maximum recommended clinical dose of 600 mg/day (Pfizer, 2013). Based on the reclassification of advanced skull bone fusions as anatomic variations, rather than malformations, pregabalin was shown not to be teratogenic when administered to female Wistar rats on GD 6–17 at the highest dose tested, 2500 mg/kg/day, in four developmental toxicity studies. The 2500 mg/kg dose was associated with a maternal plasma exposure ( $AUC_{0-24}$ ) approximately 77-times the expected human exposure at the maximum recommended dose.

In the initial embryo-fetal development study (EFD1), increased incidences of jugal fused to maxilla, and fusion of the nasal sutures were observed in fetuses from female Wistar rats treated with 1250 and 2500 mg/kg, and with 2500 mg/kg, respectively, compared with controls.



Table 5  
Skeletal Malformations and Variations in Study EFD1

Parameter	Vehicle/control		Pregabalin dose (mg/kg/day) (No. of fetuses/litters)					
			500		1250		2500	
No. of fetuses/litters examined	180/19		168/18		174/18		181/18	
No. of fetuses/litters with malformations	8/6		0/0		2/2		0/0	
No. of fetuses/litters with variations	55/16		74/18		101/18		109/18	
No. of fetuses/litters with retardations	45/11		45/14		54/16		57/15	
Percentage affected <sup>a</sup>	Fetuses	Litters	Fetuses	Litters	Fetuses	Litters	Fetuses	Litters
Malformations	4.4	31.6	0	0	1.1	11.1	0	0
Fore and hind limbs – bent	0.6	5.3	0	0	0	0	0	0
Pectoral girdle – bent	0.6	5.3	0	0	0	0	0	0
Pelvic girdle – bent	0.6	5.3	0	0	0	0	0	0
Ribs – fused	0.6	5.3	0	0	0	0	0	0
Skull								
Agenesis	0	0	0	0	0.6	5.6	0	0
Malformed bone(s)	1.1	10.5	0	0	0.6	5.6	0	0
Sternum								
Fused sternebrae/costal cartilage	0.6	5.3	0	0	0	0	0	0
Malformed (sternoschisis)	0.6	5.3	0	0	0	0	0	0
Vertebral column								
Agenesis sacral vertebrae	0	0	0	0	0.6	5.6	0	0
Fusion of thoracic arches	0.6	5.3	0	0	0	0	0	0
Malformed	1.1	10.5	0	0	0.6	5.6	0	0
One less presacral vertebra	1.7	10.5	0	0	0	0	0	0
Skeletal variations	30.6	84.2	44.0	100*	58.0*	100*	60.2*	100*
Digits – middle phalanges ossified	0	0	0.6	5.6	8.0	16.7	14.4	33.3
Limbs – calcaneus ossified	15.6	26.3	16.1	44.4	29.9	50.0	23.2	33.3
Ribs								
Wavy	2.2	15.8	4.8	16.7	7.5	33.3	2.8	16.7
Extra well-formed lumbar ribs	0	0	1.8	16.7	2.3	11.1	6.1	38.9
Rudimentary cervical rib	0	0	4.2	11.1	3.4	22.2	2.2	22.2
Rudimentary thoracic rib	11.7	52.6	22.0	72.2	23.6	88.9	34.3	88.9
Skull								
Jugal bone fused to maxilla	1.7	10.5	0.6	5.6	5.7	22.2	9.9	55.6
Nasal bones fused	0	0	0	0	0	0	5.5	22.2
Sternum – asymmetric form	1.1	10.5	3.0	27.8	1.1	11.1	3.9	2.8
Vertebral column – extra presacral vertebrae	0	0	0.6	5.6	0	0	0	0
Ossification retardations	25.0	57.9	26.8	77.8	31.0	88.9	31.5	83.3
Ribs – hypoplastic	0.6	5.3	0	0	0	0	0	0
Skull								
Unossified hyoid bone	1.7	10.5	0	0	0	0	0	0
Hypoplastic	6.7	42.1	1.8	11.1	3.4	16.7	0.6	5.6
Vertebral column								
Bifid thoracic centra	0.6	5.3	0	0	0.6	5.6	0.6	5.6
Concave/convex thoracic centra	2.2	15.8	0.6	5.6	1.1	11.1	0.6	5.6
Figure-8-shaped thoracic centra	0	0	0.6	5.6	0	0	0.6	5.6
Hypoplastic thoracic, lumbar centra	0.6	5.3	0	0	0	0	0	0
Unossified ventral tubercle of the atlas	17.8	47.4	25.0	77.8	27.0	83.3	30.4	83.3
Unossified thoracic centrum	0.6	5.3	0	0	0	0	0	0
Thoracic vertebrae misaligned	0.6	5.3	0	0	0	0	0	0
Sacral centrum bifid	0	0	0	0	0.6	5.6	0	0

<sup>a</sup>Fetuses may be included in  $\geq 1$  category; statistical comparisons for treated versus vehicle control.

\* $p \leq 0.05$  for trend test, one-tailed.

EFD1, embryo-fetal development study (initial).

Using laboratory-set evaluation criteria, these alterations in skull development were initially classified as malformations and occurred in the presence of maternal toxicity and developmental toxicity.

Three subsequent investigative studies in pregnant Wistar rats treated with pregabalin during organogenesis were conducted to further characterize the skull morphological changes and the subsequent impact on devel-

opment. Study EFD2, conducted to evaluate the reproducibility of the skull bone findings and further characterize the skull morphological changes, replicated the increased incidence of jugal fused to maxilla at the 1250 and 2500 mg/kg doses, and of the nasal suture at the 2500 mg/kg dose, and also demonstrated no visible abnormalities in the region of the zygomaticomaxillary suture via light microscopy. In the perinatal skull development

Table 6  
Summary of Rat Head External and Skull Findings in Study EFD2

Parameter	Control		Pregabalin dose (mg/kg/day)					
	Untreated	Vehicle	50	100	250	500	1250	2500
	Fetuses							
External findings								
No. of fetuses examined, <i>n</i>	333	303	307	334	298	303	324	287
Total with malformations (%)	0	0.3	0	0	0	0	0	0.3
Total with variations (%)	0	0	0	0.9	0	0	0	0
Skeletal findings								
No. of fetuses examined, <i>n</i>	170	157	158	173	154	158	168	149
Total with malformations (%)	0	0	0	0	0	0	0	0.7 <sup>a</sup>
Total with variations (%)	2.4	1.3	5.7	1.7	2.6	3.2	10.7	24.8
Jugal bone fused to maxilla (%)	2.4	1.3	4.4	1.7	2.6	3.2	10.1	19.5
Bilateral (%)	0	0.6	0.6	0.6	0	0	3.6	6.0
Right (%)	2.4	0.6	3.2	1.2	1.3	1.3	3.0	4.7
Left (%)	0	0	0.6	0	1.3	1.9	3.6	8.7
Nasal bones fused (%)	0	0	1.9	0	1.3	0	0.6	10.7
Total with ossification retardations (%)	4.1	12.7	8.2	6.4	8.4	5.1	3.0	4.0
	Litters							
External findings								
No. of litters examined, <i>n</i>	24	23	23	25	23	23	24	23
Total with malformations (%)	0	4.3	0	0	0	0	0	4.3
Total with variations (%)	0	0	0	12.0	0	0	0	0
Skeletal findings								
No. of litters examined, <i>n</i>	24	23	23	25	23	23	24	23
Total with malformations (%)	0	0	0	0	0	0	0	4.3 <sup>a</sup>
Total with variations (%)	12.5	8.7	17.4	8.0	17.4	17.4	54.2	60.9
Jugal bone fused to maxilla (%)	12.5	8.7	17.4	8.0	17.4	17.4	50.0	52.2
Bilateral (%)	0	4.3	4.3	4.0	0	0	25.0	26.1
Right (%)	12.5	4.3	13.0	8.0	8.7	8.7	16.7	21.7
Left (%)	0	0	4.3	0	8.7	13.0	25.0	26.1
Nasal bones fused (%)	0	0	4.3	0	8.7	0	4.2	30.4
Total with ossification retardations (%)	25	60.9	21.7	20.0	26.1	26.1	16.7	17.4

<sup>a</sup>A single incidence of malformed/fused mandible. EFD2, embryo-fetal development study (replicate).

study, conducted to assess the progression of skull development and the potential impact of prenatal pregabalin exposure, jugal fused to maxilla, and fusion of the nasal sutures was not complete in all of the offspring by PMD 26 in either the control or pregabalin-treated groups. However, treatment of females with pregabalin 2500 mg/kg, from GD 6–17, resulted in an increased incidence of jugal fused to maxilla and fusion of the nasal sutures based on periodic assessment from PMD 19–26. In the postnatal skull development study, conducted to assess the persistence of pregabalin-induced skull bone effects and the potential impact on postnatal health and clinical signs, no malformations of the skull, and in particular, of the orbital and nasal bones, were observed in 21-day-old offspring. In addition, no drug-related difference was observed in the incidence of jugal fused to maxilla. Malocclusion and an asymmetrically shaped head were observed clinically in one 2500 mg/kg offspring on PND 19–21. While the left parietal and frontal bones of this animal were misshapen, the zygomaticomaxillary suture was closed bilaterally. Given the high incidence of the closure of zygomaticomaxillary suture at 2500 mg/kg, it is unlikely that this would result in just one animal with misshapen cranial bones. If premature fusion had occurred, it did not adversely affect the morphological development of the

offspring. Similarly, the fusion of nasal sutures in a small percentage of control and pregabalin-treated animals had no effect on normal skull development, since this fusion was not associated with any malformation. The combined morphologic data from these studies support the classification of increased incidence of jugal fused to maxilla, and fusion of the nasal sutures, as anatomic variations, rather than malformations.

Additional manifestations of developmental toxicity, including mortality, clinical signs, and growth reduction, were considered in the overall evaluation of pregabalin-induced morphologic changes. In Study EFD1, lower fetal body weights occurred at 2500 mg/kg. However, despite the treatment-related effect on intrauterine growth, there appeared to be no effect on intrauterine survival. In contrast, postnatal survival was lower at 2500 mg/kg compared with the control groups in the perinatal and postnatal skull development studies. In the perinatal study, seven litters had no live offspring and one female was moribund at delivery due to dystocia. The majority of offspring deaths within litters occurred on PMD 22–24, generally on the day of birth. Only a few offspring in this study had clinical signs (hypoactive, cool to touch), and these animals did not have fused sutures. No clinical signs or deaths occurred in any group on PMD 25 or 26. In the

Table 7  
Summary of Maternal Reproductive Parameters and Offspring Death in the Perinatal Skull Development Study

PMD	Cohort by scheduled euthanasia day (PMD) <sup>a</sup>							
	19	20	21	22	23	24	25	26
No. of animals, <i>n</i>	10	20	20	20	20	10	10	10
	Maternal reproductive parameters							
Vehicle control group, <i>n</i>								
Gravid	9	20	19	20	20	10	10	10
Moribund	0	0	0	0	0	0	0	0
Animals with no live offspring	0	0	0	1	0	0	0	0
Viable litters at scheduled termination	9	20	19	19	20	10	10	10
Pregabalin 2500 mg/kg group, <i>n</i>								
Gravid	10	20	20	20	20	10	10	10
Moribund	0	0	0	0	0	0	1	0
Animals with no live offspring	0	0	0	0	0	2	4	4
Viable litters at scheduled termination	10	20	20	20	20	8	5	6
	Offspring mortality and clinical observations							
Vehicle control group, <i>n</i>								
Hypoactive	—	—	—	3	—	—	—	—
Dead, cannibalized	—	—	—	8	9	1	—	—
Missing	—	—	—	—	3	1	—	—
Cool to touch	—	—	—	1	—	—	—	—
Pregabalin 2500 mg/kg group, <i>n</i>								
Hypoactive	—	—	—	—	1	—	—	—
Dead, cannibalized	—	—	—	11	18	16	—	—
Missing	—	—	—	1	18	8	1	—
Cool to touch	—	—	—	—	1	—	—	—
Skin discolored	—	—	—	—	1	—	—	—
Bruising base of tail	—	—	—	1	—	—	—	—

<sup>a</sup>PMD 19 corresponds to GD 19. Natural delivery of litters (PND 0) occurs on approximately PMD 22.

— Finding not observed.

GD, gestation day; PMD, postmating day; PND, postnatal day.

postnatal study, offspring deaths in the pregabalin-treated group occurred predominately on the day of birth or PND 1.

A pre- and postnatal development (PPND) study was also conducted with pregabalin (Pfizer, unpublished data). Although detailed results of this study are not reported herein, a few points are salient to the current discussion. In this study, pregabalin (dose range 50–2500 mg/kg/day) was administered by oral gavage to female Wistar rats from implantation (GD 6) through weaning of their offspring (PND 20). Consistent with the perinatal and postnatal studies, offspring survival was greatly reduced at 2500 mg/kg, as well as at 1250 mg/kg, with the majority of postnatal deaths occurring at birth or shortly thereafter. Total litter death occurred at 2500 mg/kg by PND 3. Early postnatal mortality in these studies may have resulted from direct toxicity due to pregabalin exposure in utero or via the milk. Plasma pregabalin TK parameters increased with dose, but were less than dose proportional over the entire dose range. Pregabalin milk concentrations ranged from 0.7–1.6-times the plasma pregabalin concentrations at 4 h post-dose. However, it should be noted that offspring mortality was not a likely outcome of advanced jugal fused to maxilla or of the nasal bones, based on the lack of clinical signs associated with facial dysmorphogenesis in offspring that died (Pfizer, unpublished data).

Maternal toxicity may have contributed to the neonatal mortality following gestational administration of pregabalin. Maternal mortality, clinical signs related to central nervous system disruption, and reduced body weight gain, were evident in all studies described herein, including the two in which observation was continued into the postnatal period. Several females in the perinatal study had dead litters. Three of these females lost weight (up to 49.7 g) and had body weight gain below their overall pregabalin group means during the posttreatment period of GD 18–21 (7.4–83% of the mean; data not shown). Although some of these females also had reduced body weight gain relative to their overall group mean during the treatment period, the greater difference occurred during the late gestation period. In contrast, for the PPND study, although abnormal maternal care was noted at 2500 mg/kg, and dystocia, hypoactivity, and urine staining were observed at 1250 and 2500 mg/kg (Pfizer, unpublished data), no correlations were apparent between litter death and maternal clinical signs. Litters died whether females were hypoactive around the time of parturition or not, and although three females at 2500 mg/kg were not nesting or nursing, the majority of females in this group displayed normal maternal care on the day of parturition, but still had total litter death. The potential role of maternal toxicity in increasing the incidence of jugal fused to maxilla and fusion of the nasal bones is unknown,

Table 8  
Summary of Offspring Skull Findings in the Perinatal Skull Development Study

PMD <sup>a</sup>	Vehicle/control			Pregabalin 2500 mg/kg		
	Litter percentage, mean ± SE <sup>b</sup>	Incidence <sup>c</sup>		Litter percentage, mean ± SE <sup>b</sup>	Incidence <sup>c</sup>	
		Fetal/pup	Litter		Fetal/pup	Litter
Jugal fused to maxilla						
19	0.85 ± 0.85	1/123	1/9	2.02 ± 1.36	2/118	2/10
20	1.20 ± 0.66	3/255	3/20	8.75 ± 2.68*	19/244	10/20
21	0.84 ± 0.58	2/244	2/19	11.0 ± 4.18*	24/251	11/20
22	3.59 ± 1.31	9/273	7/19	15.7 ± 4.32*	33/228	11/20
23	4.91 ± 2.04	11/245	6/20	24.2 ± 4.81*	54/230	17/20
24	4.25 ± 2.00	6/133	4/10	16.4 ± 5.94*	17/95	5/8
25	8.56 ± 3.13	11/124	5/10	45.7 ± 9.41*	28/63	5/5
26	7.04 ± 2.44	9/131	6/10	31.9 ± 15.1	18/65	4/6
Fusion of nasal sutures						
19	0.85 ± 0.85	1/123	1/9	2.45 ± 1.70	3/118	2/10
20	0.00 ± 0.00	0/255	0/20	4.54 ± 2.60	7/244	5/20
21	0.00 ± 0.00	0/243	0/19	10.8 ± 2.76*	26/251	14/20
22	0.71 ± 0.50	2/272	2/19	10.4 ± 4.21*	23/228	9/20
23	0.00 ± 0.00	0/245	0/20	9.43 ± 3.44*	19/230	8/20
24	0.77 ± 0.77	1/132	1/10	8.01 ± 4.61	7/95	3/8
25	2.00 ± 2.00	2/124	1/10	10.1 ± 3.33	6/63	4/5
26	1.58 ± 1.07	2/131	2/10	2.78 ± 2.78	2/65	1/6

<sup>a</sup>PMD 19 corresponds to GD 19. Natural delivery of litters (PND 0) occurs on approximately PMD 22.

<sup>b</sup>Mean ± SE of the percentage of fetus/pup within each litter with the skull finding.

<sup>c</sup>Number of fetus/pup or litters affected per total number of fetus/pup or litters examined.

\*Significantly different from vehicle control,  $p \leq 0.05$ .

GD, gestation day; PMD, postmating day; PND, postnatal day; SE, standard error.

although a thorough review of the scientific literature did not reveal such an association.

The advanced skull bone fusions originally identified in Study EFD1 were compared with historical fetal data from unpublished studies conducted in Wistar rats to additionally support the conclusion that they fail to meet the three criteria for classification as malformations: (1) gross structural changes, (2) may be incompatible with life, and (3) are generally rare in occurrence. First, the fusions represent the early closure of the zygomaticomaxillary suture and nasal suture, which is a subtle structural difference and not a gross structural change. In the PPND study in Wistar rats described previously (Pfizer, unpublished data), no abnormalities of the face or head were observed in neonates or in animals that survived to adulthood, nor was facial dysmorphogenesis noted in the offspring that died in studies in which postnatal observation occurred. Second, the early fusion of the sutures is not incompatible with life. As mentioned previously, offspring mortality was potentially due to a combination of direct toxicity and maternal toxicity, in addition to the fact that no facial anomalies were observed in offspring that died. There was also a high incidence of jugal fused to maxilla on approximately PND 5, and there were no deaths in the postnatal study from PND 4–21. Fusion of the nasal bones did not result in changes of the nasal turbinates. Third, the incidence of jugal fused to maxilla was observed in historical controls

and is not a rare occurrence in the Wistar rat fetus. Fetal data from nine unpublished studies conducted in Wistar rats (Supporting Information Table S1) reviewed alongside Study EFD1 showed the jugal fused to maxilla, generally unilateral in occurrence, had a variable intrastudy background incidence, with an overall incidence of approximately 0.6% on GD 21 (9/1528 fetuses). Huntingdon Life Sciences (Suffolk, UK) indicated a single incidence of jugal fused to maxilla recorded as “increased/precocious ossification” in control animals on GD 20 in three studies during 2014–2015 in Wistar rats (1.6%) and 0 in 15 studies in Sprague Dawley CD rats during the same period (D. Coulby, personal communication, 2015). Fusion of the nasal bones was not observed in any of the subsequent teratology studies in the Pfizer historical database at Ann Arbor laboratories.

Lorke (Lorke, 1977) proposed more specific criteria for skeletal malformations, rated as: (1) absence of important bones, parts of bone, or parts of the bony system; (2) distinct bendings, shortenings, or cracks of bones or bony systems; (3) markedly asymmetric structure of normally symmetric bones or ossification centers; (4) fusion of bones which in healthy animals are distinctly separate; and (5) bone clefts. Of particular interest is criterion 4, because in the case with pregabalin, all fusions were of bones that are normally fused in adult animals.

The impact of premature fusion of the jugal to maxilla on the growth of the nasomaxillary complex has

Table 9  
Offspring Body Weight and Weight Change in the  
Postnatal Skull Development Study

	Vehicle/control	Pregabalin 2500 mg/kg/day
	Mean ± SE	
Body weight (g)		
PND 0	6.14 ± 0.03	5.63 ± 0.13
PND 4	10.45 ± 0.07	9.18 ± 0.12
PND 7	15.25 ± 0.11	13.46 ± 0.18
PND 14	28.93 ± 0.18	26.60 ± 0.29
PND 21	48.21 ± 0.34	45.14 ± 0.46
Body weight change (g)		
PND 0–21	42.06 ± 0.30	39.36 ± 0.43

PND, postnatal day; SE, standard error.

been previously studied in 2-week-old guinea pigs in which unilateral premature fusion of the zygomaticomaxillary suture was produced by immobilization with an adhesive. No gross anatomic asymmetry of the facial complex as a whole was observed, which was attributed to periosteal bone deposition in the maxilla on the fused side and periosteal bone resorption in corresponding areas on the nonfused side. These compensatory changes served to offset any developmental asymmetry that might have occurred (Thimaporn et al., 1990). Interestingly, of the animals that survived the operation, there was no effect on postoperative weight gain.

Other skeletal variations, such as bent long limb bones, bent scapula, and wavy ribs, have been shown to resolve in the postnatal period (Kimmel et al., 2014). In a longitudinal micro-computed tomography study of bent long bones in Wistar rat offspring at PND 0, 7, 21, and 80, a complete recovery of bent long bones, including the scapula, was observed within the first 3 weeks

(De Schaepdrijver et al., 2014). In a pilot longitudinal investigation in Han Wistar rats, an increased incidence of bent long bones and scapula observed on GD 20 was no longer present on PND 21 (Mitchard and Stewart, 2014). In rat teratogenicity studies, prenatal exposure to aspirin doubled the incidence of lumbar rudimentary ribs at birth that declined to essentially zero by PND 60 (Wickramaratne, 1988). In a pre- and postnatal skeletal developmental study in Sprague–Dawley rats, ethylene glycol (EC) was administered during organogenesis to determine the permanence of EC-induced skeletal variations and malformations. The incidence of malformations (in particular bipartite ossification sites of the thoracic centra) increased through PND 21 but were greatly decreased or not evident by PND 63, suggesting that perinatal skeletal abnormalities may not always be permanent (Marr et al., 1992). Further research into the mechanisms responsible for the appearance of skeletal variations, as well as additional longitudinal investigations into ontogeny and postnatal resolution, would aid the interpretation of developmental toxicity studies for human risk assessment.

Data reviewed in this paper, combined with a review of the scientific literature and historical data, indicate that while a dose-related increase in the incidence of skull bone fusions occurred in fetuses from females treated with pregabalin 1250 or 2500 mg/kg, these fusions represented advanced ossifications that were not incompatible with life and did not result in facial dysmorphogenesis based on evaluation of offspring. Advanced jugal fused to maxilla and fusion of the nasal bones was reclassified from malformations to variations, and therefore, pregabalin was no longer considered teratogenic in rats. This is consistent with findings from embryo-fetal development studies that administered pregabalin once daily to albino mice (up to 2500 mg/kg) and New Zealand White rabbits (up to 1250 mg/kg) during organogenesis, and are

Table 10  
Incidence of External and Skeletal Variations on PND 21 in the Postnatal Skull Development Study

	Vehicle/control	Pregabalin 2500 mg/kg/day
External variations		
No. of fetuses/litters examined	283/22	214/19
Misshapen head	0/0	1/1 <sup>a</sup>
Skeletal variations		
No. of fetuses/litters examined	284/22	214/19
Left frontal skull misshapen	0/0	1/1 <sup>a</sup>
Left parietal misshapen	0/0	1/1 <sup>a</sup>
Jugal fused to maxilla		
Suture closed, bilateral	281/22	197/19
Suture closed, unilateral	1/1 <sup>b,c</sup>	0/0 <sup>d</sup>
Suture open, bilateral	1/1	0/0 <sup>d,e</sup>
Suture open, unilateral	1/1 <sup>c</sup>	0/0 <sup>d</sup>
Fusion of nasal sutures		
Suture closed	3/3	10/6
Suture open	281/22	204/19

<sup>a</sup>External findings in same offspring correspond with malocclusion and asymmetrically shaped head observed on PND 19–21.

<sup>b</sup>Includes specimen damaged on one side, unable to evaluate.

<sup>c</sup>Excludes one specimen overprocessed.

<sup>d</sup>Excludes six specimens overprocessed.

<sup>e</sup>Excludes 11 specimens overprocessed.

PND, postnatal day.

presented in a companion paper (Morse, 2016). Under the conditions of these studies, pregabalin was not teratogenic in mice or rabbits.

In conclusion, pregabalin administration in the rat resulted in developmental toxicity, including maternal toxicity, decreased fetal body weight, and increased skeletal variations. There was no evidence of increased malformations related to pregabalin administration, and therefore, it is not considered teratogenic in rats.

### CONFLICT OF INTEREST

The initial embryo-fetal toxicity study conducted in 1993 was sponsored by Parke-Davis Pharmaceutical Research that was acquired by Pfizer in 2000. The three investigational developmental studies were sponsored by Pfizer, which was involved in the study design; the collection, analysis, and interpretation of the data; the writing of the report; and the decision to submit the paper for publication. Dennis Morse and Steve Bailey are full-time employees of Pfizer and hold stock and/or stock options in Pfizer. Judith Henck was an employee of Parke-Davis Pharmaceutical Research (now Pfizer) during the initial embryo-fetal study and subsequent analyses; she currently holds no stock and/or stock options in Pfizer. Medical writing support was provided by Penny Goringe, MSc, of Engage Scientific Solutions and funded by Pfizer.

### ACKNOWLEDGMENTS

The authors would like to thank Gregg Cappon (Pfizer) for providing critical review of the manuscript.

### REFERENCES

Armitage P. 1955. Tests for linear trends in proportions and frequencies. *Biometrics* 11:375–386.

Chahoud I, Buschmann J, Clark R, Druga A, Falke H, Faqi A, Hansen E, Heinrich-Hirsch B, Hellwig J, Lingk W, Parkinson M, Paumgarten FJ, Pfeil R, Platzek T, Scialli AR, Seed J, Stahlmann R, Ulbrich B, Wu X, Yasuda M, Younes M, Solecki R. 1999. Classification terms in developmental toxicology: need for harmonisation. Report of the Second Workshop on the Terminology in Developmental Toxicology Berlin, 27–28 August 1998. *Reprod Toxicol* 13(1):77–82.

Cochran W. 1955. Some methods for strengthening the common chi-square test. *Biometrics* 11:375–386.

De Schaepdrijver L, Delille P, Geys H, Boehringer-Shahidi C, Vanhove C. 2014. In vivo longitudinal micro-CT study of bent long limb bones in rat offspring. *Reprod Toxicol* 46:91–97.

Diggle P, Liang K, Zeger S. 1994. The analysis of longitudinal data. New York: Oxford University Press.

Dunnett C. 1955. A multiple comparison procedure for comparing several treatments with a control. *J Am Stat Assoc* 50:1096–1121.

Dunnett C. 1964. New tables for multiple comparisons with a control. *Biometrics* 20:482–491.

FDA. 1988. Good laboratory practice regulations for nonclinical laboratory

studies. Code of Federal Regulations (CFR) (April 1). Washington, DC: US Food and Drug Administration.

FDA. 1994. Good Laboratory practice regulations for nonclinical laboratory studies. Code of Federal Regulations (CFR) (March 21) 56FR12300. Washington, DC: US Food and Drug Administration.

Henck JW, Brown SL, Anderson JA. 1992. Developmental toxicity of CI-921, an anilinoacridine antitumor agent. *Fund Appl Toxicol* 18(2): 211–220.

Kimmel CA, Garry MR, DeSesso JM. 2014. Relationship between bent long bones, bent scapulae, and wavy ribs: malformations or variations? *Birth Defects Res Part B Dev Reprod Toxicol* 101(5):379–392.

Lorke D. 1977. Evaluation of skeleton. In: Neubert D, Merker HJ, Kwasi-groch TE, editors. *Methods in prenatal toxicology*. Stuttgart: Georg Thieme. p 52–71.

Makris SL, Solomon HM, Clark R, Shiota K, Barbellion S, Buschmann J, Ema M, Fujiwara M, Grote K, Hazelden KP, Hew KW, Horimoto M, Ooshima Y, Parkinson M, Wise LD. 2009. Terminology of developmental abnormalities in common laboratory mammals (Version 2). *Birth Defects Res Part B Dev Reprod Toxicol* 86(4):227–327.

Marr MC, Price CJ, Myers CB, Morrissey RE. 1992. Developmental stages of the CD (Sprague-Dawley) rat skeleton after maternal exposure to ethylene glycol. *Teratology* 46(2):169–181.

Mitchard T, Stewart J. 2014. Reduced post-natal development versus pre-natal incidence of bent long bones and scapulae in a preliminary investigation using the Han Wistar rat. *Reprod Toxicol* 45:39–44.

Morse DC. 2016. Embryo-fetal developmental toxicity studies with pregabalin in mice and rabbits. *Birth Defects Res Part B DOI: 10.1002/bdrb.21174*

National Institutes of Health. 1985./1996). *Guide for the care and use of laboratory animals*. NIH Publication. Washington, DC: The National Academies Press.

Park Y. 1985. Nonparametric sequential trend test. *Proceedings of the Tenth Annual SAS Users Group International Conference*. Reno, Nevada. p 809–813.

Pfizer. 2013. LYRICA® US prescribing information. Pfizer.

Pfizer. 2015. LYRICA® EU summary of product characteristics. Pfizer.

Solecki R, Barbellion S, Bergmann B, Burgin H, Buschmann J, Clark R, Comotto L, Fuchs A, Faqi AS, Gerspach R, Grote K, Hakansson H, Heinrich V, Heinrich-Hirsch B, Hofmann T, Hubel U, Inazaki TH, Khalil S, Knudsen TB, Kudicke S, Lingk W, Makris S, Muller S, Paumgarten F, Pfeil R, Rama EM, Schneider S, Shiota K, Tamborini E, Tegelenbosch M, Ulbrich B, van Duijnhoven EA, Wise D, Chahoud I. 2013. Harmonization of description and classification of fetal observations: achievements and problems still unresolved: report of the 7th Workshop on the Terminology in Developmental Toxicology Berlin, 4–6 May 2011. *Reprod Toxicol* 35:48–55.

Solecki R, Burgin H, Buschmann J, Clark R, Duverger M, Fialkowski O, Guittin P, Hazelden KP, Hellwig J, Hoffmann E, Hofmann T, Hubel U, Khalil S, Lingk W, Mantovani A, Moxon M, Muller S, Parkinson M, Paul M, Paumgarten F, Pfeil R, Platzek T, Rauch-Ernst M, Scheevenbos A, Seed J, Talsness, CE, Yasuda M, Younes M, Chahoud I. 2001. Harmonisation of rat fetal skeletal terminology and classification. Report of the Third Workshop on the Terminology in Developmental Toxicology. Berlin, 14–16 September 2000. *Reprod Toxicol* 15(6): 713–721.

Stahl SM, Porreca F, Taylor CP, Cheung R, Thorpe AJ, Clair A. 2013. The diverse therapeutic actions of pregabalin: is a single mechanism responsible for several pharmacological activities? *Trends Pharmacol Sci* 34(6):332–339.

Thimaporn J, Goldberg JS, Enlow, DH. 1990. Effects of unilateral premature fusion of the zygomatic suture on the growth of nasomaxillary complex. *J Oral Maxillofac Surg* 48(8):835–841.

Tukey JW, Ciminera JL, Heyse JF. 1985. Testing the statistical certainty of a response to increasing doses of a drug. *Biometrics* 41(1):295–301.

Walker DG, Wirtschafter ZT. 1957. *The genesis of the rat skeleton: a laboratory atlas*. Springfield, IL: Charles C. Thomas.

Wickramaratne GA. 1988. The post-natal fate of supernumerary ribs in rat teratogenicity studies. *J Appl Toxicol* 8(2):91–94.